

CASE REPORT

Open Access



Rat bite fever due to *Streptobacillus notomytis* complicated by meningitis and spondylodiscitis: a case report

Suchada Pongsuttiyakorn¹, Witchuda Kamolvit², Sunee Limsrivanichakorn², Arissa Phothisirisakulwong³ and Walaiporn Wangchinda^{1*}

Abstract

Background: Only three other cases of rat bite fever caused by *Streptobacillus notomytis* in humans have been reported since this species was identified in 2015. Data specific to the differences in clinical features and geographic distribution between *S. notomytis* infection and *S. moniliformis* infection are scarce. All previous cases of human *S. notomytis* infection were reported from Japan. This is the first case of *S. notomytis* infection reported from outside of Japan.

Case presentation: A 72-year-old Thai woman was admitted to Siriraj Hospital (Bangkok, Thailand)—Thailand's largest university-based national tertiary referral center—in August 2020 with fever, myalgia, and polyarthralgia for 3 days, and gradually decreased consciousness for the past 1 day. Physical examination and laboratory investigations revealed septic arthritis of both knee joints, meningitis, and hepatitis. She was initially misdiagnosed as rheumatoid arthritis in the elderly since the initial investigations were unable to detect a causative pathogen. However, *S. notomytis* infection was later confirmed by polymerase chain reaction amplification of a part of the 16S rRNA gene and sequencing from synovial fluid. Her clinical course was also complicated by spondylodiscitis and epidural abscess caused by *S. notomytis*, which was detected from tissue biopsy. Therefore, rat bite fever in this patient manifested as meningitis, septic polyarthritis, hepatitis, and spondylodiscitis. The patient was treated with intravenous ceftriaxone then switched to oral amoxicillin with complete recovery.

Conclusions: The clinical manifestations of *S. notomytis* infection are similar to those demonstrated in *S. moniliformis* infection. This case also showed that arthritis caused by *S. notomytis* mimics rheumatoid arthritis, and that meningitis and spondylodiscitis are potential coexisting complications that can be found in *S. notomytis* infection.

Keywords: Rat bite fever, *Streptobacillus*, *Streptobacillus notomytis*, Meningitis, Spondylodiscitis

Background

Streptobacillus is a genus of fastidious Gram-negative bacteria having forms that include filaments, chains, and curved rods. *Streptobacillus moniliformis* is

predominantly found in the upper respiratory tract of rat, and is known as the main pathogenic cause of rat bite fever [1]. Since 2014, four novel species named *Streptobacillus canis*, *Streptobacillus notomytis*, *Streptobacillus felis*, and *Streptobacillus rattus* have been described according to the genomic studies of *Streptobacillus* [2, 3]. Herein, we present a case of *S. notomytis* infection causing polyarthrititis, meningitis, and spondylodiscitis. To the best of our knowledge, this is the first case report of

*Correspondence: walaiporn.wan@mahidol.ac.th

¹ Division of Infectious Diseases and Tropical Medicine, Department of Medicine, Faculty of Medicine Siriraj Hospital, Mahidol University, 2 Wanglang Road, Bangkoknoi, Bangkok 10700, Thailand
Full list of author information is available at the end of the article



human *S. notomytis* infection to be reported outside of Japan.

Case presentation

A 72-year-old Thai woman was admitted to Siriraj Hospital (Bangkok, Thailand) in August 2020 with gradually decreasing consciousness over the preceding 1 day. During the preceding 3 days, she had fever, myalgia, pain, and swelling involving both knees and all joints of both hands. Her medical history was unremarkable except for cervical degenerative disc disease with spine surgery 15 years earlier.

The patient was febrile and drowsy on admission, and physical examination revealed neck stiffness without focal neurological deficits. Arthritis was noted at both knees, both wrists, and all joints of both hands. She had no rashes, and other examinations were unremarkable.

Laboratory investigation is shown in Table 1. Computed tomography of brain was normal. Lumbar puncture was performed and the CSF results are demonstrated in Table 1. Synovial fluid of both knees drawn by arthrocentesis was slightly turbid with a nucleated cell count of 12,900/uL with 94% neutrophils, and nucleated cell count of 69,300/uL with 95% neutrophils from the left knee and right knee, respectively. The patient was initially diagnosed with acute bacterial meningitis and polyarticular bacterial septic arthritis. After taking blood culture, high-dose intravenous ceftriaxone was administered for empirical treatment.

After 1 week of ceftriaxone treatment, the patient started to regain consciousness, but her fever and polyarthritis were not improved. The aerobic and anaerobic cultures of blood, CSF, initial synovial fluid, and four-repeated synovial fluid were all negative. FilmArray® Meningitis/Encephalitis Panel test (The BioFire®,

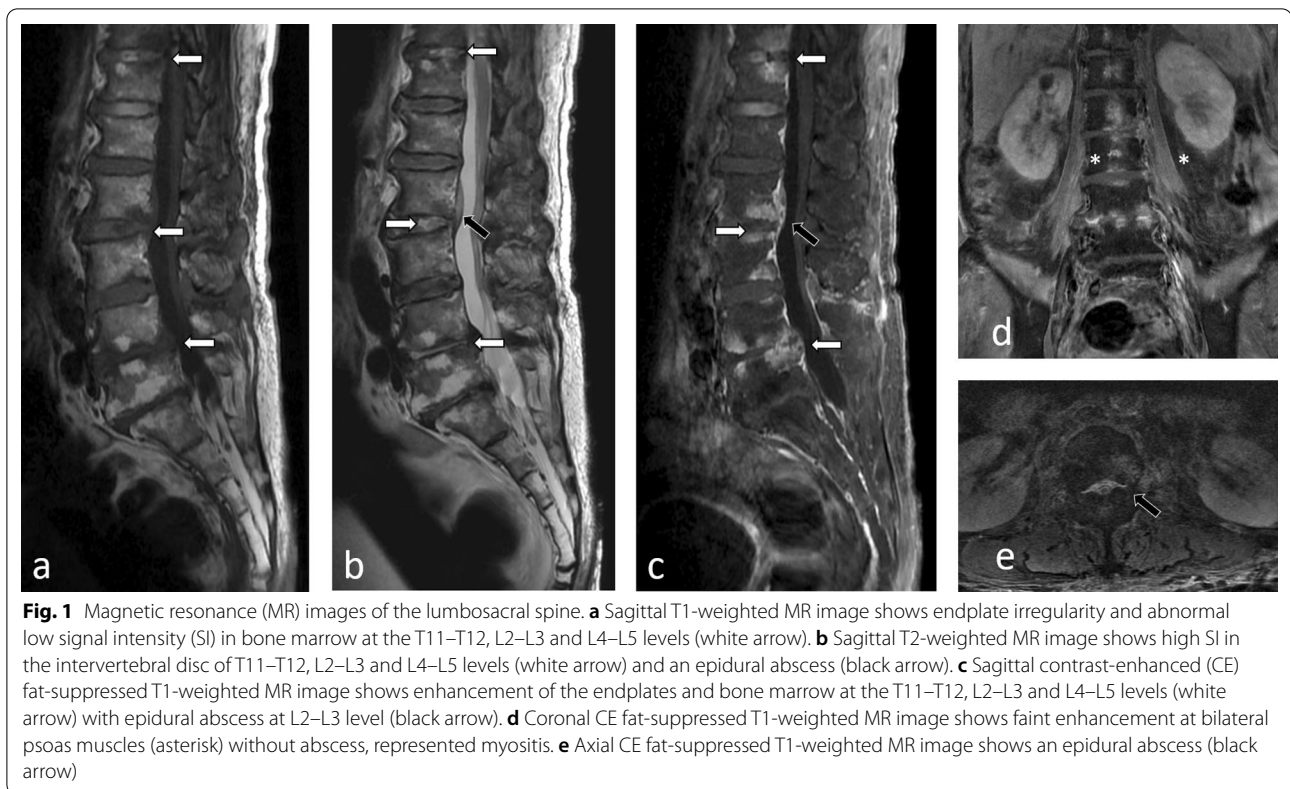
BioMérieux) of CSF was negative. PCR amplification of a part of the 16S rRNA gene followed by sequencing of initial synovial fluid was unable to detect bacterial DNA. However, PCR amplification of 16S rRNA of CSF was not performed. Since autoimmune disease was a differential diagnosis, a rheumatologist was consulted. Dexamethasone was prescribed for treatment of suspected rheumatoid arthritis in the elderly. PCR amplification of a part of the 16S rRNA gene and sequencing of repeated synovial fluid from right knee was performed allowing the detection and identification of *Streptobacillus notomytis*. Singleplex PCR assay was undertaken in a final volume of 50 µL using Taq PCR Master Mix (Qiagen) with a final concentration of 0.2 µM for each primer. The two pairs of primers used in the assay were 16S-F1 5'-AGAGTTTGATCMTGG CTCAG-3', 16S-R5 5'-GCGTGGACTACCAGGGTA TC-3' and 16S-F3 5'-CGGCTAACTCCGTGCCAG CA-3', 16S-R1 5'-ACGGYTACCTTGTTACGACT-3'. The amplification conditions were 94 °C for 5 min, followed by 30 cycles of 94 °C for 30 s, 56 °C for 45 s and 72 °C for 1 min 30 s, and final extension for 7 min. PCR products were sequenced in both directions by Sanger sequencing and submitted to GenBank under Accession number MZ676036. Rat bite fever due to *S. notomytis* was diagnosed and dexamethasone was discontinued. From retrospective history-taking, the patient denied any recent travel or animal bite, but she stated that there was group of rats living in her living area.

During the second week of hospitalization, the patient complained of low back pain. Magnetic resonance imaging of the LS spine revealed findings compatible with T11–T12, L2–L3, and L4–L5 spondylodiscitis and epidural abscess (Fig. 1). Open debridement and biopsy were then performed. The pathologic findings showed acute suppurative inflammation. Tissue culture for bacteria, mycobacteria and fungi showed negative results; however, PCR amplification and sequencing detected *S. notomytis*. Therefore, rat bite fever in this patient manifested as meningitis, septic polyarthritis, and spondylodiscitis. The diagnosis of meningitis in this patient was made by only clinical presentations of alteration of consciousness with meningeal irritation sign; however, this could be overinterpreted since the CSF findings that showed mild elevation of cell count and decrease of glucose ratio could be from parameningeal inflammation from spondylodiscitis and epidural abscess. Abnormal liver tests at presentation were also then suspected as reflecting hepatitis due to rat bite fever.

The patient was treated with intravenous ceftriaxone for 35 days with partial recovery with a subsequent switch to oral amoxicillin 2 g/day for an additional 12 weeks. Arthritis affecting both hands and knees improved,

Table 1 Laboratory blood and CSF-data

Laboratory test	Patient results	Normal values
Blood		
White blood cell count	18,900/µL	4400–10,300/µL
Neutrophil	86%	40–73%
C-reactive protein	211.6 mg/L	< 5 mg/L
Alanine aminotransferase	60 IU/L	0–33 IU/L
Alkaline phosphatase	669 IU/L	35–104 IU/L
Creatinine	2.49 mg/dL	0.51–0.95 mg/dL
Cerebrospinal fluid		
Nucleated cell count	10/µL	
Neutrophils	75%	
Protein	89 mg/dL	15–45 mg/dL
Glucose	58 mg/dL	40–70 mg/dL
CSF-to-blood glucose ratio	0.36	



C-reactive protein and liver enzymes decreased to within normal range, and the patient completely recovered.

Discussion and conclusions

Streptobacillus notomytis is a novel species in the *Streptobacillus* genus that can cause rat bite fever; however, human infection by this species is rare. Only three cases have been reported since its discovery, and all three cases were reported from Japan [4–6]. The case reported herein is the first human case of *S. notomytis* infection reported from outside of Japan, and the first case reported from Thailand. The disease distribution appears to predominate in Asia, which is similar to rat bite fever caused by *Spirillum minus* [7]. In contrast, the disease distribution of rat bite fever caused by *S. moniliformis* does not restrict in any specific geographic area [8]. This finding could be explained by the hypothesis that the black rats (*Rattus rattus*) which are reported to be naturally colonized with *S. notomytis* commonly confined to warmer areas such as Asia and Africa, whereas the Norway rats (*Rattus norvegicus*) which are commonly colonized with *S. moniliformis* tend to be found in cooler regions and urban areas [4, 9]. *S. notomytis* and *S. moniliformis* infection in humans are believed to be underdiagnosed because it is a fastidious bacterium that requires special conditions for culture, and because PCR, which

plays an important role in the diagnosis of *S. notomytis*, is not available in some centers. *S. notomytis* was first isolated in the Asia–pacific region in a spinifex hopping mouse in Australia, and in black rats in Japan [10]. However, *S. notomytis* was also isolated from house rats in a German zoo [11]. Therefore, the true incidence and area distribution of this microorganism is not yet known.

Streptobacillus moniliformis is transmitted to humans via the bite, scratch, or indirect contact of rats, and also via ingestion of food or water contaminated with rat excrement. The epidemiological link between rat exposure and human *S. notomytis* infection was confirmed in previous study [6]. No finding or evidence of *S. notomytis* harboring in any other types of animals has been published. Even though the exact cause of infection in our case remains unclear, the most likely cause is the group of rats that the patient had reported living in her living area.

Rat bite fever caused by *S. moniliformis* is typically characterized by fever, arthralgia and skin rash. Other complications, such as meningitis, endocarditis, hepatitis, and/or focal abscess, can be present in some patients [12]. Mortality in untreated patients is approximately 10% [12]. The demographic, clinical, and diagnostic details, treatment, and outcome compared among the four reported patients with *S. notomytis* infection are summarized in Table 2. Fever and arthritis were the

Table 2 Demographic, clinical, and diagnostic details, treatment, and outcome compared among the four reported patients with *Streptobacillus notomytis* infection

	Fukushima et al. 2018 [4]	Ogawa et al. 2018 [6]	Kusuda et al. 2019 [5]	The present case 2020
Age (years)	67	94	67	72
Gender	Female	Female	Male	Female
City, country	Okinawa, Japan	Nara, Japan	Tokyo, Japan	Bangkok, Thailand
Comorbidities	Hypertension Dyslipidemia	None	Hypertension	Cervical spondylosis
Clinical manifestations	Fever Rash Polyarthritits	Fever Oligoarthritits	Fever Rash Polyarthritits	Fever Polyarthritits Meningitis Hepatitis Spondylodiscitis
Positive specimens	Blood Pus	Synovial fluid Intraoral swab from rats in the patient's house	Blood	Synovial fluid Tissue biopsy from disc L4–L5
Identification technique	Culture and PCR	Culture and PCR	Culture and PCR	PCR
Treatment	Ampicillin 16 days	Ceftriaxone 15 days Ampicillin/sulbactam 14 days Minocycline	Meropenem 14 days	Ceftriaxone 30 days Amoxicillin 12 weeks
Outcome	Complete recovery	Died from <i>Acinetobacter baumannii</i> pneumonia	Complete recovery	Complete recovery

main symptoms in all cases. Our case is the first case that demonstrated meningitis, spondylodiscitis and epidural abscess as complications of *S. notomytis* infection. Our case also suggests that rat bite fever caused by *S. notomytis* presents similar clinical manifestation as those observed in rat bite fever caused by *S. moniliformis*. Moreover, rheumatoid-like polyarthritits that was initially misdiagnosed in this case has also been reported in patients with *S. moniliformis* infection [13–15]. Besides *S. notomytis*, *S. felis* is another novel species of *Streptobacillus* genus that has been reported causing rat bite fever in humans. The presentation of human *S. felis* infection from single reported case was also indistinguishable from human *S. moniliformis* infection [16].

Similar to *S. moniliformis*, *S. notomytis* was reported to be susceptible to many classes of antibiotics [4–6]. Since culture was unable to detect the organism in our case, susceptibility testing could not be performed. However, our patient's responsiveness to ceftriaxone indicates pathogen susceptibility. The slow response that required a longer duration of treatment is likely due to multiple sites of infection.

In summary, we have reported a case of rat bite fever caused by *S. notomytis* that was diagnosed by PCR from both synovial fluid from the right knee, and from tissue biopsy from the vertebral disc. This case demonstrates that complicated diseases, such as meningitis, spondylodiscitis, and epidural abscess can be found in *S. notomytis* infection—similar to *S. moniliformis*

infection. These infections have been misdiagnosed as autoimmune disease due to manifestations that mimic rheumatoid arthritis. The diagnosis is difficult and molecular diagnosis is needed, especially in patients with no history of animal contact.

Abbreviations

CSF: Cerebrospinal fluid; PCR: Polymerase chain reaction; LS: Lumbosacral; T: Thoracic; L: Lumbar.

Acknowledgements

The authors gratefully acknowledge the patient profiled in this report for granting us permission to disclose details relating to her case.

Authors' contributions

SP and WW conducted the clinical follow-up and drafted the manuscript; WK and SL supervised the identification of the causative pathogen; and, AP provided radiological data. All authors read and approved the final manuscript, and are in agreement to submit this report for journal publication.

Funding

This was an unfunded study.

Availability of data and materials

The sequence of 16S rRNA was submitted to GenBank under accession number MZ676036.

Declarations

Ethics approval and consent to participate

This case report was exempted from the requirement to obtain ethical approval by the Scientific Ethics Committee of the Siriraj Institutional Review Board (SIRB), Faculty of Medicine Siriraj Hospital, Mahidol University, Bangkok, Thailand.

Consent for publication

Written informed consent to publish case-related details and images was obtained from the patient profiled in this report. A copy of that document is available for review from the corresponding author upon request.

Competing interests

All authors declare that they have no competing interests.

Author details

¹Division of Infectious Diseases and Tropical Medicine, Department of Medicine, Faculty of Medicine Siriraj Hospital, Mahidol University, 2 Wanglang Road, Bangkoknoi, Bangkok 10700, Thailand. ²Department of Microbiology, Faculty of Medicine Siriraj Hospital, Mahidol University, Bangkok, Thailand. ³Division of Diagnostic Radiology, Department of Radiology, Faculty of Medicine Siriraj Hospital, Mahidol University, Bangkok, Thailand.

Received: 29 April 2021 Accepted: 22 September 2021

Published online: 28 September 2021

References

- Paegle RD, Tewari RP, Bernhard WN, Peters E. Microbial flora of the larynx, trachea, and large intestine of the rat after long-term inhalation of 100 per cent oxygen. *Anesthesiology*. 1976;44(4):287–90.
- Eisenberg T, Nicklas W, Mauder N, Rau J, Contzen M, Semmler T, et al. Phenotypic and genotypic characteristics of members of the genus *Streptobacillus*. *PLoS ONE*. 2015;10(8):e0134312.
- Eisenberg T, Heydel C, Prenger-Berninghoff E, Fawzy A, Kling U, Akimkin V, et al. *Streptobacillus canis* sp. nov. isolated from a dog. *Int J Syst Evol Microbiol*. 2020;70:2648–56.
- Fukushima K, Yanagisawa N, Imaoka K, Kimura M, Imamura A. Rat-bite fever due to *Streptobacillus notomys* isolated from a human specimen. *J Infect Chemother*. 2018;24(4):302–4.
- Kusuda T, Ryoko A, Yoshishige M, Tanaka M, Yoshida A, Kikuchi K, et al. Erosive polyarthritis caused by sepsis due to a novel species of *Streptobacillus notomys*. *Mod Rheumatol Case Rep*. 2020;4(1):95–8.
- Ogawa Y, Kasahara K, Lee ST, Ito T, Hasegawa H, Hirose S, et al. Rat-bite fever in human with *Streptobacillus notomys* infection, Japan. *Emerg Infect Dis*. 2018;24(7):1377–9.
- Conlon CP, Woodhouse AF. Oxford textbook of medicine. Rat bite fevers (*Streptobacillus moniliformis* and *Spirillum minus* infection). Oxford: Oxford University Press; 2020.
- Wullenweber M. *Streptobacillus moniliformis*—a zoonotic pathogen. Taxonomic considerations, host species, diagnosis, therapy, geographical distribution. *Lab Anim*. 1995;29(1):1–15.
- Julius RS, Bretschneider H, Chimimba CT, Bastos ADS. Prevalence and diversity of the *Streptobacillus* rat-bite fever agent, in three invasive, commensal *Rattus* species from South Africa. *Yale J Biol Med*. 2021;94(2):217–26.
- Eisenberg T, Glaeser SP, Ewers C, Semmler T, Nicklas W, Rau J, et al. *Streptobacillus notomys* sp. nov., isolated from a spinifex hopping mouse (*Notomys alexis* Thomas, 1922), and emended description of *Streptobacillus Levaditi* et al. 1925, Eisenberg et al. 2015 emend. *Int J Syst Evol Microbiol*. 2015;65(12):4823–9.
- Michel V, Ulber C, Pöhle D, Köpke B, Engel K, Kaim U, et al. Clinical infection in house rats (*Rattus rattus*) caused by *Streptobacillus notomys*. *Antonie Van Leeuwenhoek*. 2018;111(10):1955–66.
- Elliott SP. Rat bite fever and *Streptobacillus moniliformis*. *Clin Microbiol Rev*. 2007;20(1):13–22.
- Holroyd KJ, Reiner AP, Dick JD. *Streptobacillus moniliformis* polyarthritis mimicking rheumatoid arthritis: an urban case of rat bite fever. *Am J Med*. 1988;85(5):711–4.
- Torres A, Cuende E, De Pablos M, Lezaun MJ, Michaus L, Vesga JC. Remitting seronegative symmetrical synovitis with pitting edema associated with subcutaneous *Streptobacillus moniliformis* abscess. *J Rheumatol*. 2001;28(7):1696–8.
- Rumley RL, Patrone NA, White L. Rat-bite fever as a cause of septic arthritis: a diagnostic dilemma. *Ann Rheum Dis*. 1987;46(10):793–5.
- Matt U, Schmiedel J, Fawzy A, Trauth J, Schmidt K, Vogel K, et al. Infection in a young immunocompetent male caused by *Streptobacillus felis*, a putative zoonotic microorganism transmitted by cats. *Clin Infect Dis*. 2021;72(10):1826–9.

Publisher's Note

Springer Nature remains neutral with regard to jurisdictional claims in published maps and institutional affiliations.

Ready to submit your research? Choose BMC and benefit from:

- fast, convenient online submission
- thorough peer review by experienced researchers in your field
- rapid publication on acceptance
- support for research data, including large and complex data types
- gold Open Access which fosters wider collaboration and increased citations
- maximum visibility for your research: over 100M website views per year

At BMC, research is always in progress.

Learn more biomedcentral.com/submissions

