

# Custom ocular prosthesis in rehabilitation of a child operated for retinoblastoma

Department of Prosthodontics, Faculty of Dental Sciences, King George's Medical University, Lucknow, Uttar Pradesh, <sup>1</sup>Clove Dental, New Delhi, India

Vinit Shah, Lakshya Yadav, Mayank Singh, Smriti Kharbanda<sup>1</sup>

## ABSTRACT

A maxillofacial prosthodontist forms an important link in the interdisciplinary management of a patient with anophthalmosis. Prosthetic management of an anophthalmic defect aims to deliver a well-fitting ocular prosthesis that can mimic the original eye as closely as possible, and thus restoring the patient's self-confidence and thereby rehabilitating them in the society. The fabrication of a custom ocular prosthesis is a demanding art. This case report presents a simplified technique for the fabrication of a custom ocular prosthesis for a child who had lost his eye to enucleation following retinoblastoma. Early and effective rehabilitation of the defect goes a long way in restoring the self-image of a child in its early character building age.

**Key words:** Ocular implants, ocular prosthesis, quality of life, retinoblastoma

## Address for correspondence:

Dr. Mayank Singh,  
Department of Prosthodontics,  
Faculty of Dental Sciences,  
King George's Medical University,  
Lucknow - 226 003,  
Uttar Pradesh, India.  
E-mail: dr\_mayank1983@  
yahoo.co.in

## INTRODUCTION

Retinoblastoma is a highly malignant tumor of the eye that manifests most often in the first 3 years of life. It is the most common intraocular malignancy in children. It accounts for 2.5–4% of all childhood cancers in most developed countries while substantially higher rates are occurring in developing countries.<sup>[1]</sup> Studies from India, show a two- to three-fold higher incidence of tumors of the eye (the majority of which will be retinoblastoma in children <15 years of age).<sup>[2]</sup> The survival rate is about 95% in developed countries, but only about 50% worldwide. This could be attributed to delay in presentation due to ignorance, poverty, illiteracy, alternative systems of medicine, and lack of access to healthcare resources in developing countries.

Enucleation is the choice of treatment for unilateral intraocular retinoblastoma. Surgical procedures for the removal of an eye are classified into three

general categories: Evisceration, enucleation, and exenteration.<sup>[3]</sup> Considerations in the prosthetic treatment of ocular and orbital defects have been reported.<sup>[4]</sup> The loss of an eye can lead to significant functional and psychosocial impacts affecting the sociometric stability. The loss of an eye due to congenital malformation, tumor treatment, or trauma can lead to serious functional, physical as well as psychological effects. However with the advancement in ophthalmic surgery and ocular prosthetics, the anophthalmic patient can be rehabilitated very effectively.<sup>[5]</sup> Patient satisfaction with an ocular prosthesis is relatively high.<sup>[6]</sup> Generally a conformer is advised during the initial 6 weeks; however, early insertion of the ocular prosthesis has been found to improve the quality of life.<sup>[7]</sup> A custom ocular prosthesis is individually constructed and characterized to match the patient's natural eye, but it is a time-consuming process and a difficult art to master.

This is an open access article distributed under the terms of the Creative Commons Attribution-NonCommercial-ShareAlike 3.0 License, which allows others to remix, tweak, and build upon the work non-commercially, as long as the author is credited and the new creations are licensed under the identical terms.

**For reprints contact:** reprints@medknow.com

**How to cite this article:** Shah V, Yadav L, Singh M, Kharbanda S. Custom ocular prosthesis in rehabilitation of a child operated for retinoblastoma. Natl J Maxillofac Surg 2015;6:232-6.

Access this article online	
<b>Quick Response Code:</b> 	<b>Website:</b> www.njms.in
	<b>DOI:</b> 10.4103/0975-5950.183871

The following case report describes a simple yet effective method of fabricating a custom ocular prosthesis for a young child operated for retinoblastoma.

## CASE REPORT

A 6-year-old boy was referred to the Department of Prosthodontics from the Department of Pediatric Surgery for the prosthetic rehabilitation of an enucleated right eye [Figure 1]. The detailed anamnesis and careful study of the records revealed that the patient had reported to the Department of Ophthalmology with the loss of vision in the right eye. The diagnostic workup led to the diagnosis of retinoblastoma of the right eye. The right eye was enucleated and a hydroxyapatite orbital implant placed at the time of surgery. After satisfactory healing, the patient was now referred for prosthetic management.

A detailed examination of the enucleation socket revealed healthy tissue bed [Figure 2]. The socket bed had reasonable movement due to the underlying implant, and the case was deemed fit for the fabrication of a custom ocular prosthesis. The treatment plan was explained to the patient's guardian, and written consent was obtained for the same. The child was a bit timid and apprehensive probably because of the psychological effects of surgery and anophthalmia at the tender age. The steps involved in the fabrication were demonstrated to the child, so as to win his confidence and cooperation during the procedure.

To begin with, the anophthalmic socket of the right eye was cleaned of debris and secretions. An impression of the socket was made with irreversible hydrocolloid mixed with cold water and loaded in a thin consistency in a syringe. A stock conformer was modified suitably to act as a custom impression tray. During the impression making, the patient was instructed to fix the gaze at a distant object. The set impression was gently removed from the socket and inspected for accuracy [Figure 3]. The impression was later boxed and poured in dental stone (Kala Stone, Kalabhai Pvt. Ltd., Mumbai, India) using the 2 pour technique. The set cast was retrieved and prepared for the fabrication of wax pattern. Separating media was applied to the cast, and molten wax (Modeling Wax, Dental Products of India Ltd., Mumbai, India) was poured into the defect part of the cast. The wax pattern was carved to achieve an arbitrary contour of the eye. The fit of the wax pattern was checked in the patient and extension of the wax pattern in the fornices evaluated. The contour of the pattern was adjusted to match the contralateral eye [Figure 4]. Upon satisfactory carving of the wax pattern, the challenge is to replicate the position of the iris. Fabrication of a custom painted iris is painstaking and technique demanding.

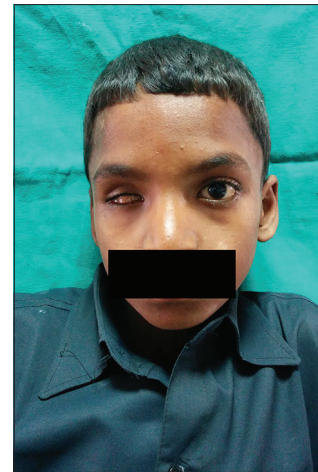

Figure 1: Preoperative view showing anophthalmic right eye

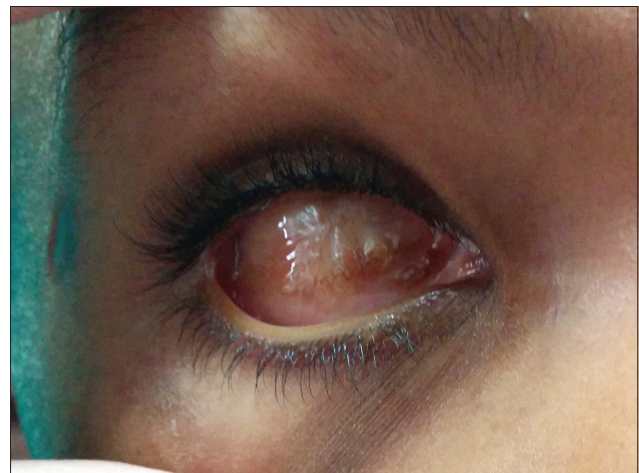

Figure 2: Detailed inspection of the enucleated socket

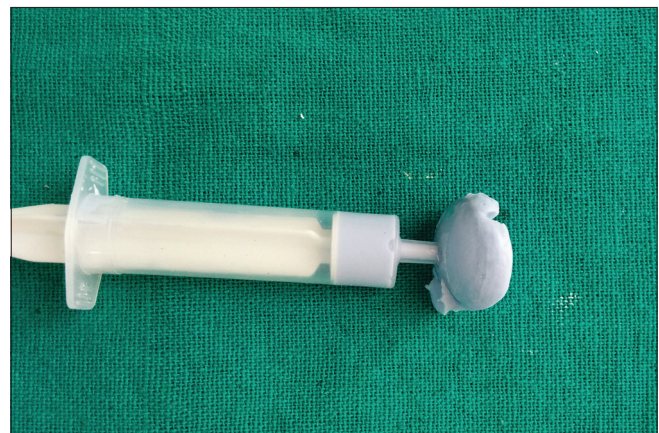


Figure 3: Impression made in irreversible hydrocolloid

Hence, a color matched iris was retrieved from a stock prosthesis [Figure 5]. The location of the iris was marked on the wax pattern while the patient has fixed the gaze on a distant object. The sock iris was incorporated in the wax pattern and the contours of the wax pattern readjusted [Figure 6]. The wax pattern was finally tried

in the patient and assessed in terms of fit and accuracy in fixed gaze as well as functional movements [Figure 7]. The finalized wax pattern was prepared for investment and processing. A stump made of clear self-cure polymethyl methacrylate (PMMA) was attached to the iris, so as to maintain its orientation during processing. The prepared wax pattern was invested in a special ocular flask and dewaxed [Figure 8]. Red nylon fibers were used for characterization of vessels on the scleral surface and heat cured tooth colored PMMA (Dental Products of India Ltd., Mumbai, India) of an appropriate shade was mixed and packed into the dewaxed mold cavity. The flask was packed and allowed to bench cure before curing it in boiling water for 1 h. The cured pattern was retrieved from the flask and finished. The surface of the prosthesis was reduced uniformly by about 0.5 mm and reinvested using heat-cured clear PMMA. The cured prosthesis was retrieved, finished, and polished [Figure 9]. The finished prosthesis was disinfected and inserted into the ocular socket and assessed for fit [Figure 10]. The patient was instructed to wet the prosthesis before insertion. The prosthesis can be worn day and night with the need to

clean once a day with soap water. Finally, the importance of regular follow-up was reinstated.

## DISCUSSION

Our knowledge of the outside world depends on our modes of perception. Eyes are one of the most specialized and developed sensory organs of the body. Loss of an eye has a deep effect on the psyche of a patient. In the present case report, the surgery and the loss of an eye had a significant psychological impact on the patient. The parents reported peer rejection and the subject's disorientation from going to school and other group play activities. Therefore, fabrication of an ocular prosthesis was of significant importance in rehabilitation, which could further ensure to improve the psyche of the patient with the primary foci on child's peer acceptance.

The placement of an ocular implant at the time of surgery helped in maintaining the volume of the defect, and significantly improved the mobility of the prosthesis. An

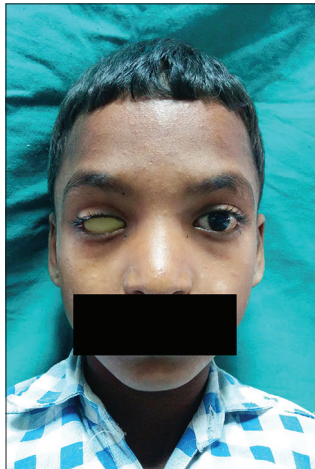

Figure 4: Wax pattern trial




Figure 5: Iris retrieved from stock ocular prosthesis

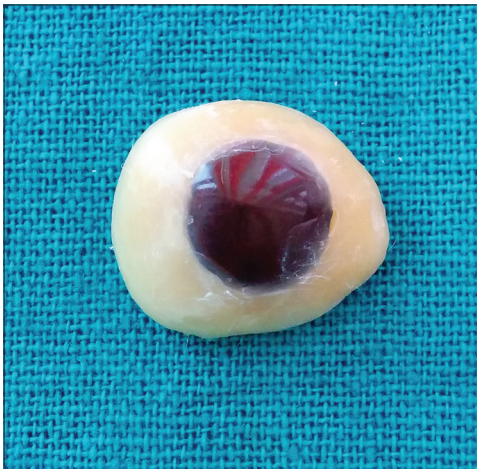

Figure 6: Finalized wax pattern

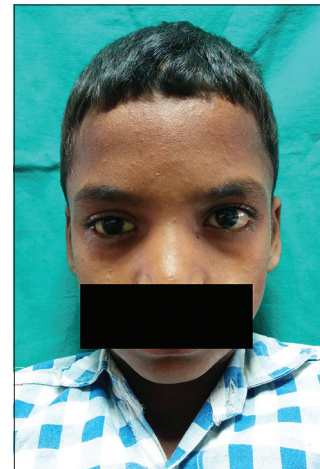

Figure 7: Final wax pattern try-in

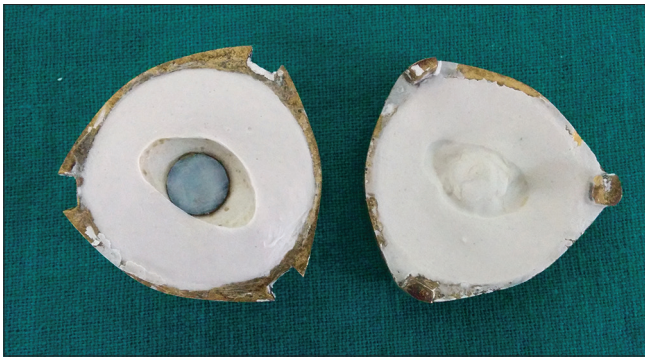

Figure 8: Prosthesis invested and dewaxed in an ocular flask

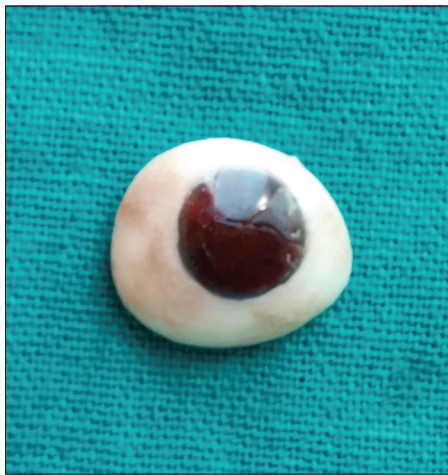

Figure 9: Finished prosthesis

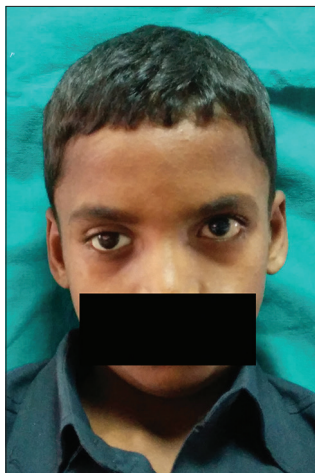

Figure 10: Finished prosthesis delivered to the patient

implant attached to the ocular muscles gives a degree of movement to the prosthetic eye as well. The implants are most commonly classified as nonintegrated (nonporous) and integrated (porous).<sup>[8]</sup> A nonintegrated implant has no unique system for attachment to the extraocular muscles and do not allow for organic tissues into their structure. They include PMMA, glass, or silicone spheres. PMMA is the material of choice among nonintegrated

implants. An integrated implants, by the virtue of being porous, allows for fibrovascular ingrowth throughout the implant. They may be made of hydroxyapatite, aluminum oxide, or polyethylene.

In the replacement of a missing eye, fabrication of a custom ocular prosthesis is favored over a stock eye. However, the fabrication of a custom ocular prosthesis can be a demanding art. The steps in fabrication were simplified to achieve excellent results with minimal resources. Furthermore, various impression procedures have been reported in the literature;<sup>[9-15]</sup> irreversible hydrocolloid was preferred in this case for its acceptable surface reproducibility and ease of manipulation. The use of color matched iris from a stock prosthesis eliminated the need for complex artistic iris painting. The heat cured PMMA was best suited for the case as the young patient was prone to accidentally dropping and damaging the prosthesis.

## CONCLUSION

The management of a young patient with retinoblastoma is an interdisciplinary challenge. The prosthodontist plays an important role by fabricating a well-crafted ocular prosthesis and in-turn rehabilitating the patient on emotional as well as the social front.

## Declaration of patient consent

The authors certify that they have obtained all appropriate patient consent forms. In the form the patient(s) has/have given his/her/their consent for his/her/their images and other clinical information to be reported in the journal. The patients understand that their names and initials will not be published and due efforts will be made to conceal their identity, but anonymity cannot be guaranteed.

## Financial support and sponsorship

Nil.

## Conflicts of interest

There are no conflicts of interest.

## REFERENCES

1. Shields CL, Shields JA. Diagnosis and management of retinoblastoma. *Cancer Control* 2004;11:317-27.
2. Arora RS, Eden TO, Kapoor G. Epidemiology of childhood cancer in India. *Indian J Cancer* 2009;46:264-73.
3. Perman KI, Baylis HI. Evisceration, enucleation, and exenteration. *Otolaryngol Clin North Am* 1988;21:171-82.
4. Parr GR, Goldman BM, Rahn AO. Surgical considerations in the prosthetic treatment of ocular and orbital defects. *J Prosthet Dent* 1983;49:379-85.
5. Beumer J, Marunick MT, Esposito SJ. Maxillofacial Rehabilitation:

- Prosthodontic and Surgical Management of Cancer-Related, Acquired, and Congenital Defects of the Head and Neck. Hanover Park: Quintessence Publication; 2011.
6. Song JS, Oh J, Baek SH. A survey of satisfaction in anophthalmic patients wearing ocular prosthesis. *Graefes Arch Clin Exp Ophthalmol* 2006;244:330-5.
  7. Chin K, Margolin CB, Finger PT. Early ocular prosthesis insertion improves quality of life after enucleation. *Optometry* 2006;77:71-5.
  8. Shome D, Honavar SG, Raizada K, Raizada D. Implant and prosthesis movement after enucleation: A randomized controlled trial. *Ophthalmology* 2010;117:1638-44.
  9. Bartlett SO, Moore DJ. Ocular prosthesis: A physiologic system. *J Prosthet Dent* 1973;29:450-9.
  10. Brown KE. Fabrication of an ocular prosthesis. *J Prosthet Dent* 1970;24:225-35.
  11. Maloney B. Development of impression fitting equipment: A new technique. *J Am Soc Ocularists* 1979;9:32-3.
  12. Engelmeier RL. Autoclavable custom-made metal impression trays to improve infection control. *J Prosthet Dent* 1987;58:121-2.
  13. Sykes LM, Essop AR, Veres EM. Use of custom-made conformers in the treatment of ocular defects. *J Prosthet Dent* 1999;82:362-5.
  14. Ow RK, Amrith S. Ocular prosthetics: Use of a tissue conditioner material to modify a stock ocular prosthesis. *J Prosthet Dent* 1997;78:218-22.
  15. Mathews MF, Smith RM, Sutton AJ, Hudson R. The ocular impression: A review of the literature and presentation of an alternate technique. *J Prosthodont* 2000;9:210-6.