

# A case of COVID-19–related acute genital ulceration in a male

International Journal of STD &amp; AIDS

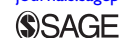2022, Vol. 33(6) 622–624

© The Author(s) 2022

Article reuse guidelines:

[sagepub.com/journals-permissions](https://sagepub.com/journals-permissions)

DOI: 10.1177/09564624221085726

[journals.sagepub.com/home/std](https://journals.sagepub.com/home/std)

Abdurrahman Kaya, MD<sup>1</sup>  and Sibel Yıldız Kaya, MD<sup>2</sup>

## Abstract

COVID-19 is a viral infection which can present with various clinical manifestations. While it primarily affects the respiratory tract, several other manifestations including skin involvements have been reported. Dermatologic manifestations are uncommon, and its prevalence is not well-known. In COVID-19, there have been two reports of acute genital ulceration to date, and both are female. Here, we report a male patient with COVID-19 complicated by acute genital ulceration in the course of the illness.

## Keywords

Genital ulcer, scrotum, COVID-19

Date received: 6 January 2022; revised: 4 February 2022; accepted: 14 February 2022

## Introduction

Acute genital ulceration (AGU), known as Lipschutz ulcer or juvenile gangrenous vasculitis of the scrotum, is a rare condition. The latter corresponds to the male-counterpart of the former.<sup>1,2</sup> It typically affects sexually inactive adolescent girls and is characterized by the rapid onset of painful, necrotic ulcerations of the vulva or lower vagina. It is very rare in men and manifests as scrotal ulcers.<sup>3</sup> The ulcers are well-demarcated with a fibrinous, necrotic, or purulent center. It has been associated with acute Epstein–Barr virus (EBV) infection and other viral and bacterial infections.<sup>4</sup> However, in many cases, a cause cannot be determined. Herein, we described a case of non-sexually acquired genital ulcer in a male.

## Case report

A 35-year-old male was admitted with complaints of a 3-day history of painful genital ulcers and fever. He presented also dry cough and rhinorrhea for the last 7 days. His clinician prescribed a course of amoxicillin–clavulanate (2 g/daily) for possible bacterial infection. On examination, the patient was in good general condition and fully cooperative. A single and soft painful ulcer with a necrotic crust was present on the left side of the scrotum (Figure 1). He was married and had no recent risky sexual behavior. The previous medical history was unremarkable for medications and trauma. In addition, the patient had no urinary symptoms and denied a history of sexually transmitted infections. Laboratory values were as follows: white blood cells count: 9600 cells/McL, with 43% neutrophilia and

48% lymphocytosis and C-reactive protein: 6 mg/L (0–5); sedimentation rate: 30 mm/hour; and procalcitonin was normal. On subsequent evaluation, Fournier gangrene was considered unlikely by urology colleagues. A sample was taken from the wound. As the findings were suggestive of a viral infection, a throat swab test was performed for SARS-CoV-2. Gram staining did not reveal any microorganisms, and the culture for bacterial pathogens was sterile. Serologies for syphilis, human immunodeficiency virus, hepatitis B virus, toxoplasmosis, *Cytomegalovirus*, *Mycoplasma pneumoniae*, *Chlamydia trachomatis*, and herpes simplex virus (HSV) type 1 and 2 were unremarkable. Heterophile antibody agglutination testing was negative, and there was evidence of prior EBV infection (VCA IgG positive, IgM negative). The swab sample tested positive for SARS CoV-2 by polymerase chain reaction. A diagnosis of non-sexually acute genital ulceration was made, and topical anesthetics and acetaminophen for pain control were initiated. No additional treatment was administered. Five days later, the pain was relieved and the ulcer had rapidly improved (Figure 2). The patient's

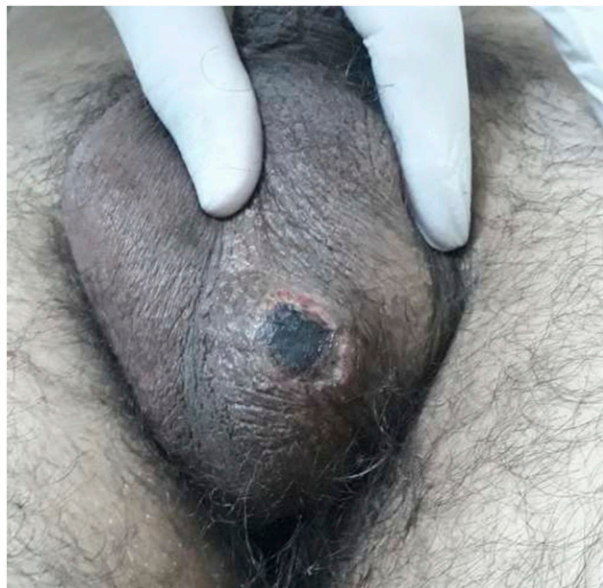
<sup>1</sup>Department of Infectious Diseases, Istanbul Training and Research Hospital, Istanbul, Turkey

<sup>2</sup>Department of Infectious Diseases, Cerrahpasa School of Medicine, Istanbul University-Cerrahpasa, Istanbul, Turkey

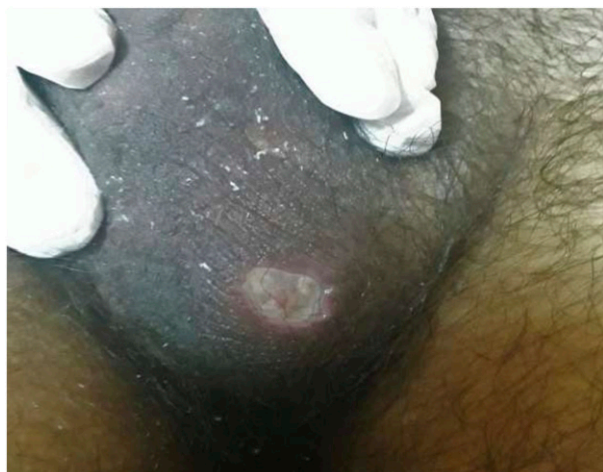
## Corresponding author:

Abdurrahman Kaya, Department of Infectious Disease, Istanbul Training and Research Hospital, Orgeneral Abdurrahman Nafiz Gürman, Street No: 24, Istanbul 34098, Turkey.

Email: [dr.abdkaya@hotmail.com](mailto:dr.abdkaya@hotmail.com)



**Figure 1.** A single and painful ulcer with a necrotic crust.



**Figure 2.** The appearance of the ulcer on the fifth day of treatment.

condition progressed favorably without complications, and no recurrences have been observed for 4 months.

## Discussion

Most genital ulcers are caused by sexually transmitted infections. In the United States, the most common cause of genital ulcer disease is HSV, followed by syphilis.<sup>5</sup> In populations of men who have sex with men, outbreaks of lymphogranuloma venereum have also been reported.<sup>6</sup> On rare occasions, ulcers can result from non-infectious etiologies including drug reactions, Behçet's disease, neoplasms, Crohn's disease, and trauma.<sup>7</sup> In this case, there were no risk factors and clinical signs for the above conditions.

AGU is a non-sexually related genital ulcer for which intense pain is the main complaint. Its diagnosis is mainly clinical after exclusion of other causes of genital ulcers. It is based on detailed history and complete physical examination. Laboratory analysis may be necessary to rule out other causes of genital ulceration. Evidence of primary EBV infection supports the diagnosis of AGU.<sup>8</sup> Most frequently, it may be preceded by flu-like illness or mononucleosis-like symptoms.<sup>9</sup> The treatment is mainly symptomatic and includes local hygiene, wound care, and pain control. The condition is self-limiting, and healing occurs spontaneously with no recurrences, usually in 2 weeks.

In a patient with COVID-19, Falkenhain-López et al. reported the first case of AGU who presented with vulvar ulcers in a healthy woman.<sup>10</sup> She had dry cough and rhinorrhea before admission. Her lesions evolved to resolution after a course of corticosteroid treatment. The second one was described in a 13-year-old Caucasian girl with a history of recurrent oral aphthae.<sup>11</sup> She failed a course of oral corticosteroids and improved with colchicine. Ulceration and edema resolved within 6 weeks. Contrary to both cases, our patient was male and recovered without the need for additional treatments.

The exact pathogenesis of AGU is not fully understood. The ulcer is considered to be associated with a hypersensitivity reaction to a recent viral or bacterial infection, resulting in deposition of immune complex in the dermal vessels, complement activation, micro thrombosis, and tissue necrosis.<sup>12,13</sup> The histologic findings in biopsies of acute genital ulcers are often non-specific and include necrosis of the epithelium with a polymorphic dermal infiltrate of neutrophils and CD8<sup>+</sup> mononuclear cells.<sup>14</sup>

In conclusion, despite AGU being a benign condition, the acute manifestation is often distressing and alarming for both patients and physicians. It can appear in male patients and could be triggered by SARS-CoV-2, as in other virus infections.

## Author Note

All authors meet the ICMJE authorship criteria

## Declaration of Conflicting Interests

The author(s) declared no potential conflicts of interest with respect to the research, authorship, and/or publication of this article.

## Funding

The author(s) received no financial support for the research, authorship, and/or publication of this article.

## ORCID iD

Abdurrahman Kaya  <https://orcid.org/0000-0003-2100-3035>

## References

1. Chen W and Plewig G. Lipschütz genital ulcer revisited: is juvenile gangrenous vasculitis of the scrotum the male counterpart? *J Eur Acad Dermatol Venereol* 2019; 33: 1660–1666.
2. Jimenez-Cauhe J, Gil-Redondo R, Dominguez-Santas M, et al. Juvenile gangrenous vasculitis of the scrotum: the male counterpart of Lipschütz ulcer? *J Eur Acad Dermatol Venereol* 2019; 33: e459–461.
3. Aguayo-Carreras P, Pérez-López I, Molina-Leyva A, et al. Acute genital ulcer in a male. *Med Cutan Ibero Lat Am* 2019; 46: 213–214.
4. Lehman JS, Bruce AJ, Wetter DA, et al. Reactive nonsexually related acute genital ulcers: review of cases evaluated at mayo clinic. *J Am Acad Dermatol* 2010; 63: 44–51.
5. Roett MA, Mayor MT and Uduhiri KA. Diagnosis and management of genital ulcers. *Am Fam Physician* 2012; 85: 254–262.
6. Convery C and Kent JB. 374. Lymphogranuloma venereum (LGV) outbreak among people living with HIV (PLWH): michigan, 2015-2018. *Open Forum Infect Dis* 2019; 6: S195–S196.
7. Sehgal VN, Pandhi D and Khurana A. Nonspecific genital ulcers. *Clin Dermatol* 2014; 32: 259–274.
8. Halvorsen JA, Brevig T, Aas T, et al. Genital ulcers as initial manifestation of Epstein-Barr virus infection: two new cases and a review of the literature. *Acta Derm Venereol* 2006; 86: 439–442.
9. Mourinha V, Costa S, Urzal C, et al. Lipschütz ulcers: uncommon diagnosis of vulvar ulcerations. *BMJ Case Rep* 2016; 2016: bcr2015214338.
10. Falkenhain-López D, Agud-Dios M, Ortiz-Romero PL, et al. COVID-19-related acute genital ulcers. *J Eur Acad Dermatol Venereol* 2020; 34: e655–e656.
11. Krapf JM, Casey RK and Goldstein AT. Reactive non-sexually related acute genital ulcers associated with COVID-19. *BMJ Case Rep* 2021; 14: e242653.
12. Sárdy M, Wollenberg A, Niedermeier A, et al. Genital ulcers associated with Epstein-Barr virus infection (ulcus vulvae acutum). *Acta Derm Venereol* 2011; 91: 55–59.
13. Huppert JS. Lipschutz ulcers: evaluation and management of acute genital ulcers in women. *Dermatol Ther* 2010; 23: 533–540.
14. Farhi D, Wendling J, Molinari E, et al. Non-sexually related acute genital ulcers in 13 pubertal girls: a clinical and microbiological study. *Arch Dermatol* 2009; 145: 38–45.