

Unusual communications of the brachial plexus

Sarika Rachel Tigga, Surbhi Wadhwa¹, Preeti Goswami¹

Department of Anatomy, ESIC Medical College and Hospital, NIT, NH3, Faridabad, Haryana, ¹Department of Anatomy, Maulana Azad Medical College, New Delhi, India

ABSTRACT

The knowledge of innervation of pectoral muscles is important to surgeons performing breast surgeries, axillary lymph node dissection, harvesting pectoralis major/minor for flaps, and during neurotization procedures where the pectoral nerves are particularly at risk. The present case describes the innervation of the pectoral muscles solely by a nerve trunk arising from the ansa pectoralis (AP) - the loop of medial and lateral pectoral nerves. Interestingly, there was also a communication between the AP and roots forming the median nerve. It is imperative for the operating surgeons to be aware of these rare variations in order to prevent denervation and subsequent atrophy of the pectoral musculature.

Key words: Ansa pectoralis, brachial plexus, lateral pectoral nerve, medial pectoral nerve, median nerve

Submission: 06-12-2014 **Accepted:** 03-09-2015

INTRODUCTION

The brachial plexus supplies the upper extremity and is formed by the fusion of the anterior primary rami of the cervical (C5-8) and the first thoracic (T1) spinal nerves. The five roots fuse to form three trunks which further branch into anterior and posterior divisions behind the clavicle. These divisions reunite to form the medial, lateral, and posterior cords arranged around the axillary artery. The medial pectoral nerve (MPN) arises from the medial cord (C8, T1), usually pierces and supplies the pectoralis minor (PMi). A few branches of MPN also supply pectoralis major (PMj). The lateral pectoral nerve (LPN) carries fibers from C5-7 to supply the PMj. LPN communicates with the MPN to form a loop - the ansa pectoralis (AP), in front of the thoracoacromial artery (TAA) and hence LPN also supplies the PMi. Thus, pectoral muscles are normally supplied by LPN, MPN, and sometimes terminal branches from AP (superior, middle,

and inferior pectoral nerves) may also innervate these muscles.^[1,2] Though some researchers have reported the AP to be absent, others have reported a 100% incidence in their studies. If AP is present, it connects MPN with the LPN in front of the first or second part of axillary artery; however, it is mostly distal to the lateral thoracic artery (LTA).^[3-5] Loukas *et al.* in 28% specimens found the AP directly connecting the LPN and MPN. The MPN may be connected to the anterior divisions of the upper trunk (5%), middle trunk (25%) or to the deep branch of the LPN (42%).^[2,3] Aszmann *et al.* reported the AP arising from the deep branch of the middle pectoral nerve.^[5] Such anatomical variability in the formation of the AP are not known to affect the limb functions, but knowledge of such variations are essential in the evaluation of unexplained sensory and motor loss after trauma and surgical explorations.

CASE REPORT

During routine dissection of an embalmed 70-year-old male cadaver, a variant pattern of the brachial plexus was

Address for correspondence: Dr. Sarika Rachel Tigga,
Department of Anatomy, ESIC Medical College and Hospital,
NIT, NH3, Faridabad, Haryana, India.
E-mail: sarika.rachel@gmail.com

Access this article online

Quick Response Code:



Website:

www.ijabmr.org

DOI:

10.4103/2229-516X.174021

This is an open access article distributed under the terms of the Creative Commons Attribution-NonCommercial-ShareAlike 3.0 License, which allows others to remix, tweak, and build upon the work non-commercially, as long as the author is credited and the new creations are licensed under the identical terms.

For reprints contact: reprints@medknow.com

How to cite this article: Tigga SR, Wadhwa S, Goswami P. Unusual communications of the brachial plexus. *Int J App Basic Med Res* 2016;6:68-70.

encountered in the left side. The skin and subcutaneous tissue were dissected off, and the exposed pectoral muscles were reflected toward their insertion. Branches of the axillary artery were inspected and later trimmed for better visualization of the cords. The LPN arose by a single root from the lateral cord, just distal to the origin of the TAA, and measured 2.8 cm in length. The MPN originated from the medial cord just distal to the LTA and was 3.3 cm in length. LPN and MPN united to form a loop - the AP, anterior to the second part of the axillary artery. This loop was immediately distal to the TAA. From the AP, a conjoint nerve trunk arose which was 3.2 cm in length. This conjoint nerve trunk pierced the deep surface of PMi to supply it; thereafter it branched and supplied the PMj [Figure 1]. Concurrently, in the brachial plexus, a nerve communication (Nc) existed between the lateral cord and the medial root of median nerve (MrM). This further communicated (C) with the conjoint trunk from the AP [Figure 2]. Thereafter the fibers of MrM and the lateral root of median nerve (LrM) united at the junction of upper and middle one-third of the arm to form the median nerve (MN).

The right side brachial plexus was found to be normal.

DISCUSSION

We describe a rare variant, wherein the entire LPN and MPN initially united to form the AP, which solely supplied the pectoral muscles through a common trunk. The pectorals did not receive any direct branches from the LPN or MPN. We observed LPN to emerge from the lateral cord by a single root lateral to the second part of the axillary artery. LPN may arise by a single root from the lateral cord or by two to three roots from the anterior divisions of upper and middle trunks.^[2,3]

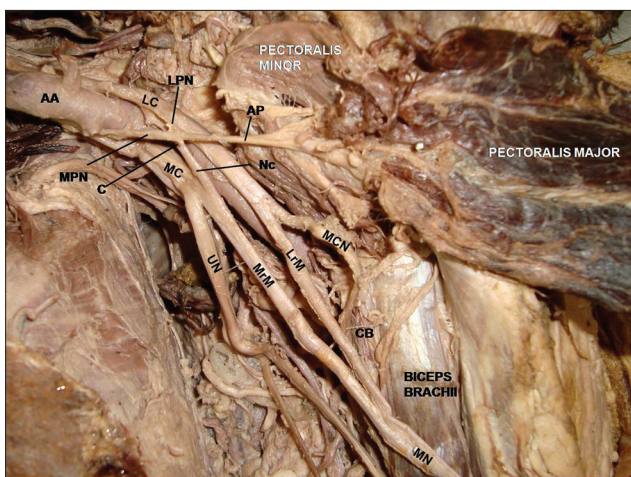


Figure 1: Nerve communication (Nc) - between the medial root of median nerve (MrM and lateral cord (LC); communication (C) - between ansa pectoralis (AP) and nerve communication (MC: Medial cord; MPN: Medial pectoral nerve, LPN: Lateral pectoral nerves, LrM: Lateral root of median nerve, AA: Axillary artery, CB: Coracobrachialis, MCN: Musculocutaneous nerve, UN: Ulnar nerve)

MPN branched off the medial cord, arising just distal to the LTA by a single root. The MPN may arise from the medial cord (25% - Loukas et al.; 49.3% - Porzionato et al.) or from the anterior division of the lower trunk (43.8% - Porzionato et al.; 75% - Loukas et al.)^[3,4]

Certain authors have observed AP to have 100% incidence in their studies while others have found it to be absent.^[3-5] In the present report, the MPN and LPN communicated in front of the second part of axillary artery to form the AP. A single nerve trunk originated from the AP to supply the pectoral muscles and also communicated with the MN. Afshar and Gopalipour observed a similar single nerve trunk from the AP, but it supplied the muscular axillary arch of latissimus dorsi.^[6] Gupta et al. also reported a loop communication between MPN and LPN with a pseudoganglion like thickening.^[7]

Variations of the brachial plexus may arise due to alterations in the migration of muscles derived from somites into the early upper limb mesenchymal primordium leading to modifications of the primitive segmental arrangement of nerves.^[8] The anomalous innervation of the pectorals becomes particularly important while performing an axillary breast augmentation, wherein an implant is placed between the pectorals or during lymph node dissection procedures, though injury to few of the nerve branches of either pectorals usually leads to little consequence.^[9] The pectoralis muscle island flaps are used for head, neck, and axillary reconstructive surgeries and currently neuromuscular blockade of pectoral muscles is being employed for pain relief by decreasing the muscle tone in orthopedic procedures such as shoulder dislocation.^[5,10] Such surgical procedures may be tricky in cases like ours, as an inadvertent sacrifice of the nerve by

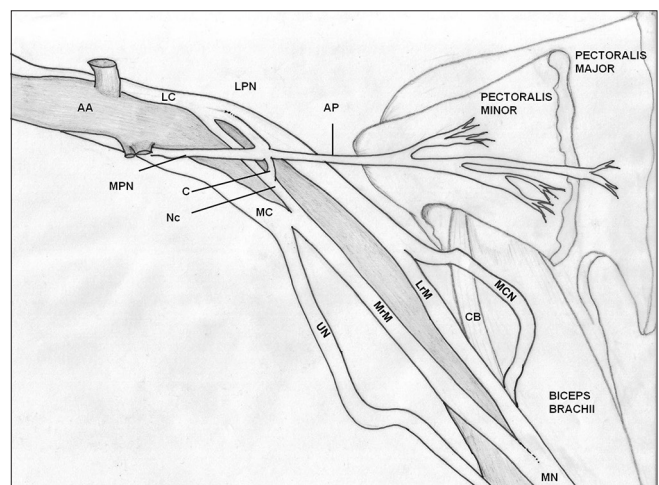


Figure 2: Diagrammatic representation of the dissection highlighting the nerve communication (Nc) receiving a twig from the conjoint trunk (C) of ansa pectoralis (MC: Medial cord, MPN: Medial pectoral nerve, LPN: Lateral pectoral nerve, LrM: Lateral root of median nerve, AA: Axillary artery, CB: Coracobrachialis, MCN: Musculocutaneous nerve, UN: Ulnar nerve)

an unaware surgeon would lead to atrophy of both muscles because of a common nerve supply.

In the brachial plexus, MN formation has been frequently reported to be variable with communications with other nerves being common.^[7,11] In our present study, a Nc existed between the MrM and LrM. This communication also received fibers from AP, which were probably destined to form the MN and hitch-hiked through one of the pectoral nerves to reach it.

Injury to such rare communications of the brachial plexus could result in an unexplained atrophy of the pectorals and/or unexplained loss of power in few muscles supplied by MN.

Financial support and sponsorship

Nil.

Conflicts of interest

There are no conflicts of interest.

REFERENCES

1. Johnson D, Collins P. Pectoral girdle, shoulder region and axilla. In:

- Standring S, editor. Gray's Anatomy. 40th ed. Edinburgh: Elsevier/Churchil Livingstone; 2005. p. 818-21.
2. Lee KS. Anatomic variation of the spinal origins of lateral and medial pectoral nerves. *Clin Anat* 2007;20:915-8.
 3. Loukas M, Louis RG Jr, Fitzsimmons J, Colborn G. The surgical anatomy of the ansa pectoralis. *Clin Anat* 2006;19:685-93.
 4. Porzionato A, Macchi V, Stecco C, Loukas M, Tubbs RS, De Caro R. Surgical anatomy of the pectoral nerves and the pectoral musculature. *Clin Anat* 2012;25:559-75.
 5. Aszmann OC, Rab M, Kamolz L, Frey M. The anatomy of the pectoral nerves and their significance in brachial plexus reconstruction. *J Hand Surg Am* 2000;25:942-7.
 6. Afshar M, Ghalipour MJ. Innervation of muscular axillary arch by a branch from pectoral loop. *Int J Morphol* 2005;23:279-80.
 7. Gupta M, Goyal N, Kaur H. Anomalous communications in the branches of brachial plexus. *J Anat Soc India* 2005;54:22-5.
 8. In: Sadler TW, editor. Langman's Medical Embryology. Skeletal system. 11th ed., Ch. 9. New Delhi: Wolters Kluwer (India) Pvt. Ltd.; 2010. p. 152-3.
 9. Gonçalves Ade V, Teixeira LC, Torresan R, Alvarenga C, Cabello C. Randomized clinical trial on the preservation of the medial pectoral nerve following mastectomy due to breast cancer: Impact on upper limb rehabilitation. *Sao Paulo Med J* 2009;127:117-21.
 10. David S, Balaguer T, Baque P, Peretti FD, Valla M, Lebreton E, et al. The anatomy of the pectoral nerves and its significance in breast augmentation, axillary dissection and pectoral muscle flaps. *J Plast Reconstr Aesthet Surg* 2012;65:1193-8.
 11. Badawoud MH. A study on the anatomical variations of median nerve formation. *Bahrain Med Bull* 2003;25:1-5.