

Original Article

Tumors of Bilateral Streak Gonads in Patients with Disorders of Sex Development Containing Y Chromosome Material

Fumi Matsumoto¹, Kenji Shimada¹, and Shinobu Ida²

¹*Department of Urology, Osaka Medical Center and Research Institute for Maternal and Child Health, Osaka, Japan*

²*Department of Gastroenterology, Nutrition and Endocrinology, Osaka Medical Center and Research Institute for Maternal and Child Health, Osaka, Japan*

Abstract. The presence of Y chromosome material in patients with disorders of sex development (DSD) has been associated with a high risk of gonadoblastoma. Therefore, gonadectomy is recommended in females with bilateral streak gonads and Y chromosome material. The aim of this study was to present our experience with prophylactic gonadectomy in those patients and evaluate their risk of gonadal tumors. We reviewed the charts of 11 female patients who had bilateral gonadectomy (by laparoscopically in 9 patients, by laparotomy in 2 patients) between 1991 and 2012 at our hospital. Seven patients with Turner syndrome (TS) who carry a Y mosaic karyotype in peripheral blood, 3 patients with Swyer syndrome and one patient with Frasier syndrome were included. All patients had an unambiguous female phenotype. Age at surgery and follow-up ranged from 2 to 23 (mean 11) and 0.5 to 20 (mean 8) yr, respectively. Pathologic examination revealed gonadal tumors in 6 of 11 patients (56%), including 4 with TS, the youngest of which was 2 yr old, one with Swyer syndrome and one with Frasier syndrome. A gonadoblastoma was detected in 8 gonads, and an association of dysgerminoma with gonadoblastoma was detected in 2 gonads. Imaging studies showed no metastasis, and the postoperative course was uneventful in all patients. In our series of DSD patients with bilateral streak gonads and Y chromosome material, the risk of gonadal tumor was high. Considering the early occurrence of gonadoblastoma and its high potential for malignant transformation, early prophylactic gonadectomy is strongly recommended.

Key words: gonadoblastoma, streak gonad, disorders of sex development, Y chromosome

Introduction

Disorders of sex development (DSD) are defined as congenital conditions in which development of chromosomal, gonadal or anatomical sex is atypical (1). The overall occurrence is estimated to be one in 4500 to 5000 live births (1). In specific group of DSD patients, i.e., those bearing Y chromosome material, an increased risk of gonadal tumor

Received: November 6, 2013

Accepted: April 10, 2014

Corresponding author: Dr. Fumi Matsumoto, Department of Urology, Osaka Medical Center and Research Institute for Maternal and Child Health, 840 Murodocho, Izumi, Osaka 594-1101, Japan

E-mail: fumim@mch.pref.osaka.jp

This is an open-access article distributed under the terms of the Creative Commons Attribution Non-Commercial No Derivatives (by-nc-nd) License <<http://creativecommons.org/licenses/by-nc-nd/3.0/>>.

has been reported(1–3). The gonadoblastoma (GB) composed of germ cells and stromal cells, which is the in situ germ cell malignancy of the ovary and dysgenetic gonad, has the potential to progress towards invasive germ cell tumor (GCT) in 60% of the cases, particularly dysgerminoma, and less frequently, towards components of other tumors, such as embryonic carcinoma, teratoma, yolk sac tumor and choriocarcinoma (4, 5). Traditionally, the prevalence of GB and GCT in patients with Y chromosome material is estimated to be larger than 30% (6, 7). However, the reported prevalences may vary due to limited numbers of the patients. In this study, we present our experience with prophylactic gonadectomy in patients with bilateral streak gonads and Y chromosome material and our assessment of the risk of gonadal tumor development.

Subjects and Methods

We reviewed the charts of 11 female patients who had bilateral gonadectomy (by laparoscopically in 9 patients, by laparotomy in 2 patients) between 1991 and 2012 at our hospital. All patients were suspected to have bilateral streak gonads by endocrinological examination and imaging studies preoperatively. Seven patients with Turner syndrome (TS) who carry a Y mosaic karyotype, 3 patients with Swyer syndrome and one patient with Frasier syndrome were included. Karyotyping was performed by classical cytogenetic analysis using peripheral blood lymphocytes. No patient with Swyer syndrome had mosaicism (all 3 patients had a 46,XY karyotype) or syndromic features. In a 46,XY patient with Frasier syndrome, analysis of the WT1 gene confirmed a mutation, IVS9+4C>T. All patients had an unambiguous female phenotype. Operative findings showed bilateral streak gonads located in the abdominal cavity in all cases. Age at surgery and follow-up ranged from 2 to 23 (mean 11) and 0.5 to 20 (mean 8) yr, respectively.

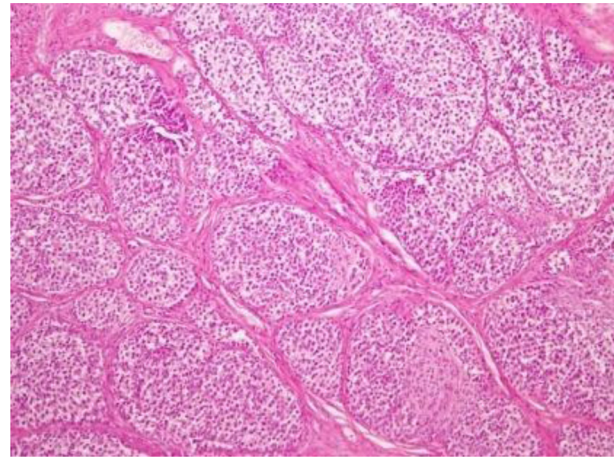


Fig. 1. Dysgerminoma with gonadoblastoma in the left gonad of case#6.

Results

Pathologic examination revealed gonadal tumors in 6 of 11 patients (56%), including 4 of 7 patients (57%) with TS, one of 3 patients (33%) with Swyer syndrome and the one patient with Frasier syndrome. The youngest patient was a 2-yr-old girl with TS. Four of these 6 patients (67%) had bilateral tumors. A gonadoblastoma was detected in 8 gonads, in 5 patients, and an association of dysgerminoma with gonadoblastoma (Fig.1) was detected in 2 gonads, in 2 patients (Table 1). Imaging studies performed after surgery, including a thoracoabdominal computerized tomography scan, revealed no sign of metastasis in the 2 patients in which an association of dysgerminoma with gonadoblastoma was detected. The postoperative course was uneventful in all of 11 patients.

Discussion

The risk of gonadal tumor is an important factor in the management of patients with DSD. DSD patients with Y chromosome material in particular have an increased risk of developing an invasive GCT. The reported prevalence of GB and invasive GCT varies, but it is estimated to

Table 1 Characteristics of the patients with bilateral streak gonads

Case	Disorder	Karyotype	Symptom	Age at gonadectomy	Gonadal lesion (Rt)	Gonadal lesion (Lt)
1	Turner	45,X/46,XY	Short stature	9 yr 10 mo	No tumor	No tumor
2	Turner	45,X/45,X,t(15;Y)(p11.2;q11.2)	Short stature	2 yr 11 mo	GB	GB
3	Turner	45,X/46,XY	Low weight	5 yr 5 mo	No tumor	No tumor
4	Turner	45,X/46,XY	Short stature	10 yr 3 mo	GB	GB
5	Turner	45,X/46,XY	Short stature	11 yr 6 mo	GB+dys	No tumor
6	Turner	46,X,+der(15)/46,XY	Short stature	15 yr 4 mo	GB	GB+dys
7	Swyer	46,XY	Amenorrhea	17 yr 3 mo	No tumor	No tumor
8	Swyer	46,XY	Aamenorrhea	23 yr 6 mo	No tumor	GB
9	Turner	45,X/46,XY	Short stature	10 yr 6 mo	No tumor	No tumor
10	Swyer	46,XY	Short stature	4 yr 5 mo	No tumor	No tumor
11	Frasier	46,XY	Proteinuria	12 yr 0 mo	GB	GB

GB indicates gonadoblastoma; dys, dysgerminoma.

be over 30% in patients with gonadal dysgenesis and is often bilateral (6–8). Therefore, in the consensus statement in 2006 (1), prophylactic gonadectomy was recommended in patients with bilateral streak gonads containing Y chromosome material, because hormonal production and fertility were not expected.

TS is one of the most common chromosomal abnormalities in humans, and is present in 1:2000 newborns with a female phenotype (9). Although TS is characterized by sex chromosome monosomy (45,X), several mosaicism of both the X and Y chromosome is found in up to 50% of patients (9, 10). In routine cytogenetic analysis the Y chromosome or Y-specific sequence is present in about 5% of the patients with TS (9).

Brant *et al.* (11) reported that GB was detected in 3 of 7 patients (43%) with TS carrying Y mosaicism. No invasive GCT was found in their series of prophylactic gonadectomy, whereas an association of dysgerminoma was detected in a half of our TS patients with GB. It is possible that a difference in screening methods for Y chromosome material may influence the results. Using molecular techniques such as fluorescence in situ hybridization or polymerase chain reaction, the detection of low frequency cell lines and possible structural anomalies is improved (12–14). Some authors reported that

polymelase chain reaction is more effective than cytogenetic analysis for detecting hidden Y chromosome material (13, 14). However, Cools *et al.* (8) reported that the prevalence of GB in patients with TS having hidden Y chromosome material is low (11.6%, 5 out of 43 patients). Therefore, we only performed standard lymphocyte karyotyping.

In 1955, Swyer described two cases of sex reversal that had a 46,XY karyotype and had primary amenorrhea, tall stature, female external genitalia and normal Mullerian structures (15). Patients with Swyer syndrome have bilateral streak gonads and are also known as a member of pure gonadal dysgenesis. A deletion in the DNA-binding region of the SRY gene is found in 10–20% of the affected patients. The incidence of this condition is estimated to be 1:80,000 birth (16). The risk of gonadal tumor (GB and dysgerminoma) in patients with Swyer syndrome has been estimated to be 15–30% (1). In our study GB was detected in one of 3 patients (33%).

Pure gonadal dysgenesis is the consequence of an abortive development of the fetal testis. In some cases the mutations in specific genes, such as SRY, SOX9, SF1, DAX1, WT1, or other unknown genes involved in testis differentiation are reported (17). Frasier syndrome, characterized by gonadal dysgenesis in 46,XY individuals and

nephropathy, is caused by mutations in the WT1 gene (18). These mutations occur mainly in the donor splice site within intron 9 and lead to a relative reduction in the production of the +KTS WT1 isoform, which has been shown to be important in gonadal development (19). The incidence of 46,XY Frasier syndrome is unknown because it is difficult to distinguish it from Denys-Drash syndrome, another overlapping disease caused by WT1 gene mutations, is difficult and little data is available (20). Since Frasier *et al.* (21) reported the first case in 1964, more than 60 cases have been reported (20, 22, 23). The prevalence of GB in patients with Frasier syndrome is very high. Taking into consideration the previous literature, and the as one patient in our series, GB was detected 22 of 45 patients (49%) with Frasier syndrome (23), and the risk of GCT was estimated to be 60% (1). Because of the limitations of chemotherapy in patients with renal insufficiency, early gonadectomy is recommended.

GB commonly occurs in the second decade of life but can develop in children with gonadal dysgenesis as early as age of 9 mo (24). In our study the youngest patient was 2 yr and 11 mo old, and two other patients were diagnosed with GB associated with dysgerminoma as teenagers. Therefore gonadectomy should be considered soon after the diagnosis of streak gonad is made in females with Y chromosome material.

The limitations of this study include its small sample size and the heterogeneous etiology of materials. However, our results may contribute to the better understandings of these very rare conditions.

Conclusions

In our series, the overall prevalence of gonadal tumor in patients with bilateral streak gonads containing Y chromosome material was 56%. Considering the early occurrence of gonadoblastoma and its high potential for malignant transformation, prophylactic

gonadectomy is strongly recommended soon after diagnosis.

References

1. Hughes IA, Houk C, Ahmed SF, Lee PA, LWPES Consensus Group ESPE Consensus Group. Consensus statement on management of intersex disorders. *Arch Dis Child* 2006;91: 554–63. [[Medline](#)] [[CrossRef](#)]
2. Nelson CP, Gearhart JP. Current views on evaluation, management, and gender assignment of the intersex infant. *Nat Clin Pract Urol* 2004;1: 38–43. [[Medline](#)] [[CrossRef](#)]
3. Mendonca BB, Domenice S, Arnhold IJ, Costa EM. 46,XY disorders of sex development (DSD). *Clin Endocrinol (Oxf)* 2009;70: 173–87. [[Medline](#)]
4. Saenger P. Clinical review 48: The current status of diagnosis and therapeutic intervention in Turner's syndrome. *J Clin Endocrinol Metab* 1993;77: 297–301. [[Medline](#)]
5. Looijenga LH, Stoop H, de Leeuw HP, de Gouveia Brazao CA, Gillis AJ, van Roozendaal KE, *et al.* POU5F1 (OCT3/4) identifies cells with pluripotent potential in human germ cell tumors. *Cancer Res* 2003;63: 2244–50. [[Medline](#)]
6. Manuel M, Katayama PK, Jones Jr HW. The age of occurrence of gonadal tumors in intersex patients with a Y chromosome. *Am J Obstet Gynecol* 1976;124: 293–300. [[Medline](#)]
7. Verp MS, Simpson JL. Abnormal sexual differentiation and neoplasia. *Cancer Genet Cytogenet* 1987;25: 191–218. [[Medline](#)] [[CrossRef](#)]
8. Cools M, Drop SL, Wolffenbuttel KP, Oosterhuis JW, Looijenga LH. Germ cell tumors in the intersex gonad: old paths, new directions, moving frontiers. *Endocr Rev* 2006;27: 468–84. [[Medline](#)] [[CrossRef](#)]
9. Lippe B. Turner syndrome. *Endocrinol Metab Clin North Am* 1991;20: 121–52. [[Medline](#)]
10. Mathur A, Stekol L, Schatz D, MacLaren NK, Scott ML, Lippe B. The parental origin of the single X chromosome in Turner syndrome: lack of correlation with parental age or clinical phenotype. *Am J Hum Genet* 1991;48: 682–6. [[Medline](#)]
11. Brant WO, Rajimwale A, Lovell MA, Travers

- SH, Furness PD 3rd, Sorensen M, *et al.* Gonadoblastoma and Turner syndrome. *J Urol* 2006;175: 1858–60. [[Medline](#)] [[CrossRef](#)]
12. Maciel-Guerra AT, Paulo JD, Santos AP, Guaragna-Filho G, Andrade JG, Siviero-Miachon AA, *et al.* The use of fluorescence in situ hybridization in the diagnosis of hidden mosaicism: apropos of three cases of sex chromosome anomalies. *Arq Bras Endocrinol Metabol* 2012;56: 545–51. [[Medline](#)] [[CrossRef](#)]
 13. Bianco B, Lipay MV, Melaragno MI, Guedes AD, Verreschi IT. Detection of hidden Y mosaicism in Turner's syndrome: importance in the prevention of gonadoblastoma. *J Pediatr Endocrinol Metab* 2006;19: 1113–7. [[Medline](#)] [[CrossRef](#)]
 14. Sallai A, Sólyom J, Dobos M, Szabó J, Halász Z, Ságodi L, *et al.* Y-chromosome markers in Turner syndrome: Screening of 130 patients. *J Endocrinol Invest* 2010;33: 222–7. [[Medline](#)] [[CrossRef](#)]
 15. Swyer GI. Male pseudohermaphroditism: a hitherto undescribed form. *BMJ* 1955;2: 709–12. [[Medline](#)] [[CrossRef](#)]
 16. Michala L, Goswami D, Creighton SM, Conway GS. Swyer syndrome: presentation and outcomes. *BJOG* 2008;115: 737–41. [[Medline](#)] [[CrossRef](#)]
 17. Fallat ME, Donahoe PK. Intersex genetic anomalies with malignant potential. *Curr Opin Pediatr* 2006;18: 305–11. [[Medline](#)] [[CrossRef](#)]
 18. Barboux S, Niaudet P, Gubler MC, Grünfeld JP, Jaubert F, Kuttann F, *et al.* Donor splice-site mutations in WT1 are responsible for Frasier syndrome. *Nat Genet* 1997;17: 467–70. [[Medline](#)] [[CrossRef](#)]
 19. Hammes A, Guo JK, Lutsch G, Leheste JR, Landrock D, Ziegler U, *et al.* Two splice variants of the Wilms' tumor 1 gene have distinct functions during sex determination and nephron formation. *Cell* 2001;106: 319–29. [[Medline](#)] [[CrossRef](#)]
 20. Guaragna MS, Lutaif AC, Bittencourt VB, Piveta CS, Soardi FC, Castro LC, *et al.* Frasier syndrome: four new cases with unusual presentations. *Arq Bras Endocrinol Metabol* 2012;56: 525–32. [[Medline](#)] [[CrossRef](#)]
 21. Frasier SD, Bashore RA, Mosier HD. Gonadoblastoma associated with pure gonadal dysgenesis in monozygous twins. *J Pediatr* 1964;64: 740–5. [[Medline](#)] [[CrossRef](#)]
 22. Bache M, Dheu C, Doray B, Fothergill H, Soskin S, Paris F, *et al.* Frasier syndrome, a potential cause of end-stage renal failure in childhood. *Pediatr Nephrol* 2010;25: 549–52. [[Medline](#)] [[CrossRef](#)]
 23. Sinha A, Sharma S, Gulati A, Sharma A, Agarwala S, Hari P, *et al.* Frasier syndrome: early gonadoblastoma and cyclosporine responsiveness. *Pediatr Nephrol* 2010;25: 2171–4. [[Medline](#)] [[CrossRef](#)]
 24. Dumić M, Jukić S, Batinica S, Ille J, Filipović-Grcić B. Bilateral gonadoblastoma in a 9-month-old infant with 46,XY gonadal dysgenesis. *J Endocrinol Invest* 1993;16: 291–3. [[Medline](#)] [[CrossRef](#)]