

ORAL PRESENTATION

Open Access

PINOT NOIR: Pulmonic INSufficiency imprOvement with Nitric Oxide Inhalational Response

Stephen Hart², Ganesh Devendra², Yuli Y Kim⁶, Scott D Flamm^{1,5*}, Sagar Kalahasti^{5,1}, Janine Arruda³, Esteban Walker⁴, Thananya Boonyasiranant¹, Michael Bolen^{1,5}, Randolph M Setser¹, Richard Krasuski⁵

From 15th Annual SCMR Scientific Sessions
Orlando, FL, USA. 2-5 February 2012

Background

Tetralogy of Fallot (TOF) repair and pulmonary valvotomy for pulmonary stenosis (PS) often lead to progressive pulmonary insufficiency (PI), right ventricular enlargement and dysfunction. This study assessed whether the pulmonary regurgitant fraction measured by cardiac magnetic resonance imaging (CMR) could be reduced by a selective pulmonary vasodilator.

Methods

Patients with at least moderate PI by echocardiography undergoing a clinically indicated CMR study were prospectively enrolled. Patients with a RV-PA conduit or residual pulmonic stenosis were excluded. Ventricular volume and blood flow sequences were obtained at baseline and after administration of 40ppm inhaled nitric oxide (iNO). Eleven Sixteen patients (11 with repaired TOF and 5 with repaired PS) completed the protocol with adequate data for analysis.

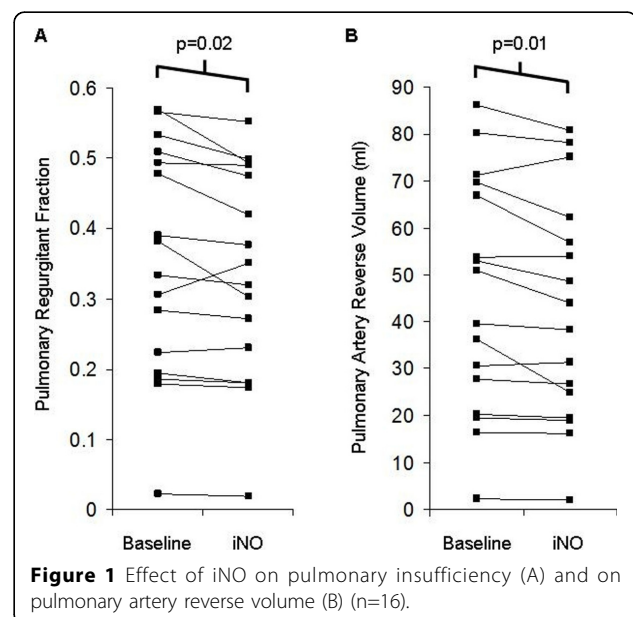
Results

The median age [range] was 35 [19 - 46] years, BMI was 26 ± 5 kg/m² (mean \pm standard deviation), 50% were women and 75% were in NYHA class I. Right ventricular end diastolic volume index for the cohort was 157 ± 33 mL/m², end systolic volume index was 93 ± 20 mL/m² and right ventricular ejection fraction was $40 \pm 6\%$. Baseline pulmonary regurgitant volume was 45 ± 25 mL/beat and regurgitant fraction was $35 \pm 16\%$. During administration of iNO, regurgitant volume was reduced by an average of $6 \pm 9\%$ ($p=0.01$) and regurgitant fraction

was reduced by an average of $5 \pm 8\%$ ($p=0.02$). No statistically significant changes were observed in stroke volume, ejection fraction or cardiac output for either the left or right ventricle.

Conclusions

iNO administration appears to reduce the regurgitant fraction in patients with at least moderate PI suggesting a potential role for selective pulmonary vasodilator therapy in these patients.



¹Cardiovascular Imaging Laboratory, Cleveland Clinic, Cleveland, OH, USA
Full list of author information is available at the end of the article

Funding

Cleveland Clinic Imaging Institute Research Council.

Author details

¹Cardiovascular Imaging Laboratory, Cleveland Clinic, Cleveland, OH, USA.

²Lerner College of Medicine of Case Western Reserve University, Cleveland Clinic, Cleveland, OH, USA. ³Pediatric Cardiology, Cleveland Clinic, Cleveland, OH, USA. ⁴Quantitative Health Sciences, Cleveland Clinic, Cleveland, OH, USA.

⁵Cardiovascular Medicine, Cleveland Clinic, Cleveland, OH, USA. ⁶Hospital of the University of Pennsylvania and Children's Hospital of Philadelphia, University of Pennsylvania, Philadelphia, PA, USA.

Published: 1 February 2012

doi:10.1186/1532-429X-14-S1-O73

Cite this article as: Hart et al.: PINOT NOIR: Pulmonic INSufficiency imprOvement with Nitric Oxide Inhalational Response. *Journal of Cardiovascular Magnetic Resonance* 2012 **14**(Suppl 1):O73.

**Submit your next manuscript to BioMed Central
and take full advantage of:**

- Convenient online submission
- Thorough peer review
- No space constraints or color figure charges
- Immediate publication on acceptance
- Inclusion in PubMed, CAS, Scopus and Google Scholar
- Research which is freely available for redistribution

Submit your manuscript at
www.biomedcentral.com/submit

