



## Case report

## Secondary encephalocele in an adult leading to subdural empyema

Taylor Wang<sup>a</sup>, Asif Uddin<sup>a,\*</sup>, Neville Mobarakai<sup>a</sup>, Ronit Gilad<sup>b</sup>, Mark Raden<sup>b</sup>, Soriya Motivala<sup>c</sup><sup>a</sup> Department of Medicine, Staten Island University Hospital, 475 Seaview Avenue, Staten Island, NY 10305, USA<sup>b</sup> Department of Neurosurgery, Staten Island University Hospital, 475 Seaview Avenue, Staten Island, NY 10305, USA<sup>c</sup> Department of Radiology, Staten Island University Hospital, 475 Seaview Avenue, Staten Island, NY 10305, USA

## ARTICLE INFO

## Article history:

Received 10 June 2020

Received in revised form 14 July 2020

Accepted 15 July 2020

## Keywords:

Abscess

Empyema

Meningitis

Encephalocele

Neural tube defect

Craniotomy

## ABSTRACT

Brain abscesses are an uncommon but potentially fatal infection. They can spread directly from an adjacent source or hematogenously from a distant source. Encephaloceles represent a rare form of neural tube defects that can potentially be complicated by the development of meningitis or brain abscess. We report a case of a 63-year-old female who presented with bilateral lower extremity weakness and was ultimately found to have a *Streptococcus pneumoniae* subdural empyema and an associated frontal lobe encephalocele extending through the left frontal sinus. She was treated with surgical drainage, intravenous antimicrobials, and ultimately surgical repair of the encephalocele. This report highlights a unique presentation of brain abscess. Clinicians should be aware of this potential infectious complication of a neural tube defect.

© 2020 The Author(s). Published by Elsevier Ltd. This is an open access article under the CC BY-NC-ND license (<http://creativecommons.org/licenses/by-nc-nd/4.0/>).

## Introduction

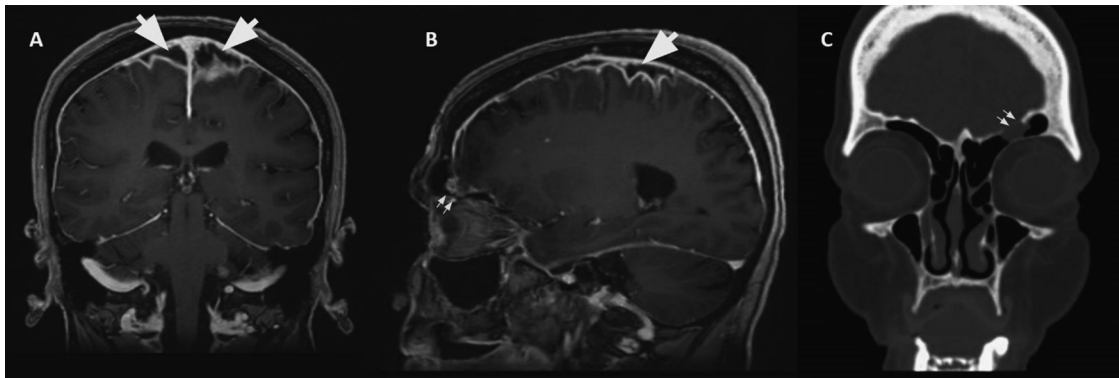
An encephalocele is defined as a herniation of brain tissue. It can be present at birth or acquired after certain insults to the brain such as trauma, surgery, hydrocephalus, and chronic sinusitis. One of the complications of encephaloceles is intracerebral infection caused by bacterial invasion of the meninges and brain parenchyma resulting in meningitis and brain abscesses and/or empyema. A 63-year-old female presented to our hospital with a complaint of bilateral lower extremity weakness and history of fever. Neuroimaging revealed a left frontal lobe encephalocele. The encephalocele was complicated by bi-hemispheric subdural empyema worse on the left causing persistent lower extremity weakness and foot drop. Left parietal craniotomy and abscess evacuation was performed and *Streptococcus pneumoniae* was identified in the aspirate. She was treated with intravenous (IV) ceftriaxone for six weeks and physical therapy with subsequent resolution of her weakness. A left frontal craniotomy and definitive repair of encephalocele were performed. The patient's repeat brain imaging revealed obliteration of the encephalocele and resolution of the leptomeningeal enhancement and edema. She has had no further sequelae.

## Case Presentation

A 63-year-old female with no significant past medical history presented with bilateral lower extremity numbness causing her to trip while walking. It had contributed to two recent mechanical falls at home. She denied any recent head trauma, back trauma, or loss of consciousness. In our emergency room, she was noted to have a temperature of 101.8 F and a white blood cell count of 16,800 cells/uL. On physical examination, the patient was noted to have intact motor strength in bilateral upper extremities with mildly decreased sensation and strength in the bilateral lower extremities. She had no changes in her mental status and no signs of meningismus. The initial diagnostic work-up which included blood and urine cultures as well as computed tomography (CT) of the head did not reveal a source of infection. The patient also underwent magnetic resonance imaging (MRI) of the spine survey without contrast that failed to reveal any source of her weakness and fever. She underwent MRI of the brain with IV contrast which showed leptomeningeal and dural enhancement, parenchymal edema involving the frontal and parietal lobes, and subdural enhancement concerning for subdural empyema (Fig. 1, A and B). Also a small left frontal lobe encephalocele was noted extending through the posterior wall of the left frontal sinus. A lumbar puncture was done and the CSF showed 23 nucleated cells/ $\mu$ L, glucose 62 mg/dL, protein 152 mg/dL and was culture negative.

Neurosurgery was consulted and the patient underwent a left craniotomy with brain biopsy and aspiration of her subdural

\* Corresponding author at: 475 Seaview Avenue, Staten Island, NY 10305, USA.  
E-mail address: [auddin@northwell.edu](mailto:auddin@northwell.edu) (A. Uddin).



**Fig. 1.** MRI of the brain with and without contrast (A, B); Maxillofacial CT without contrast (C).

A: Coronal view demonstrating bilateral subdural rim-enhancing fluid collection (arrows) consistent with a subdural empyema.

B: Sagittal view demonstrating the subdural rim-enhancing fluid collection (arrow) and the encephalocele (double arrow), an outpouching of brain tissue through a bony defect into the frontal sinus.

C: Coronal view of a maxillofacial CT outlining the bony defect at the base of the skull/roof of the frontal sinus (double arrow), where there is a protrusion of brain tissue through the defect, consistent with an encephalocele.

empyema. Vancomycin, meropenem, and metronidazole were initiated for empiric treatment. Bacterial culture of the abscess revealed *Streptococcus pneumoniae* with a minimum inhibitory concentration of 0.016  $\mu\text{g/mL}$  to penicillin. Antimicrobial therapy was de-escalated to ceftriaxone after sensitivities were resulted. The source of the patient's infection was presumed to be her encephalocele after bacterial seeding from the sinuses. Of note, the patient denied any history of trauma, chronic sinus disease, nor CSF rhinorrhea. After surgery, the patient was discharged with six weeks of IV ceftriaxone. She returned for an elective left frontal craniotomy and definitive repair of her encephalocele once her infection had resolved (Fig. 1C). She was placed on a subsequent four-week course of IV ceftriaxone and metronidazole per infectious disease post-operatively. She had complete resolution of her neurologic deficit and no further sequelae. Follow-up MRI showed repair of the encephalocele, resolution of pachymeningeal enhancement and parenchymal edema.

## Discussion

An encephalocele is the herniation of brain tissue and meninges through a defect of the cranium. It is a type of open neural tube defect caused by a disturbance between neural and surface ectoderm during neural tube closure, likely before 45–50 days embryonic age [9,11]. The incidence of encephaloceles is approximately 1 in 10,000 live births although it is more prevalent in Southeast Asia, where the prevalence is 1 in 5000 live births [10,12]. Secondary encephaloceles presenting later in life can result from traumatic injury, surgery, hydrocephalus, and chronic sinusitis [13]. Secondary encephaloceles, such as the one in this case, are more difficult to identify because they are not evidently present in physical examination.

Encephaloceles are classified by locations: fronto-ethmoidal, basal, occipital, and the cranial vault. Each can be subdivided into more precise classes. Approximately 80 % of encephaloceles are located in the occipital area. Frontoethmoidal encephaloceles include nasal-frontal, naso-ethmoidal, and naso-orbital. Basal encephaloceles include trans-ethmoidal, trans-sphenoidal, sphenoid-ethmoidal, sphenoid-maxillary, and fronto-sphenoidal encephaloceles [10]. Although larger defects can appear as facial masses, diagnosis is established with neuroimaging. CT scan without contrast can visualize the bony defect and MRI of the head without contrast can identify the herniated contents inside the sac [9]. Meninges exposed to sinuses or external environments are at high risk as direct inoculation of bacteria into the brain parenchyma can occur. In

addition, brain herniation disrupts the brain integrity leading to a high risk (approximately 52 %) of developing disability, hydrocephalus, and intracranial abnormalities [14]. A nationwide population-based cohort study also demonstrated a high risk (32 % compared to 2% in population controls) of new-onset epilepsy until 10 years after acute infection due to brain abscesses [15]. Secondary encephalocele resulting in cranial infection is a rare entity in the literature. Encephaloceles have been found to be associated with recurrent meningoencephalitis secondary to direct pathogen entry into the central nervous system. *S. pneumoniae* was ultimately cultured in our patient. This bacterium is the most common pathogen causing intracranial infection associated with an encephalocele [17].

A brain abscess is a focal suppurative infection of the brain parenchyma, typically surrounded by a vascularized capsule [1]. Major predisposing factors include infection at the adjacent structures such as middle ear, sinuses (mastoid sinuses, paranasal sinuses, frontal sinuses), head trauma or post-neurosurgical procedures, and bacteremia or pyogenic infection at distant sites [1]. Common clinical presentation of brain abscesses include headache (49 %–97 %), mental status change (28 %–91 %), focal neurologic deficits (22 %–66 %), and fever (32 %–79 %) [2]. Our patient presented with fever until hospital day 5 and persistent lower extremity numbness, but had no complaints of headache, altered mental status, history of CSF rhinorrhea, or meningismus.

The most common pathogenic mechanism of brain abscess formation is spread from a contiguous focus of infection, such as otitis media, mastoid or paranasal sinusitis [2]. They are singular, localized, and close to the source of infection. Contiguous spread accounts for one-third to half of the brain abscesses [1,3]. Common causative agents are polymicrobial, mainly *Streptococcus* sp., *Staphylococcus aureus*, Enterobacteriaceae, and anaerobes [5]. Hematogenous spreading contributes to about 25%–40% of brain abscesses and they often present as multiple abscesses in the brain. Patients with infectious endocarditis and pulmonary or dental abscesses are at high risk. Common organisms found in these abscesses are *Staphylococcus aureus*, oral *Streptococcus* sp., and anaerobes [5]. In patients who recently undergo neurosurgical procedures, the causative agents are mostly skin flora such as *Staphylococcus* spp. and gram-negative bacilli [4].

The recommended diagnostic test for intracranial abscess or empyema is CT with contrast enhancement due to its ability to rapidly detect abscess location and size. MRI can demonstrate early abscesses more accurately and differentiate abscesses from brain tumors. Gram stain and culture of the aspirate from the abscesses can identify the causative agent(s). Positive blood culture is only

found in 10 % of intracranial infection cases [3]. LP is generally advised against in patients with brain abscesses, mainly due to the risk of herniation [6]. Therefore, LP should only be performed when all the contraindications have been ruled-out (i.e., no mass effect, no increased intracranial pressure, no tonsillar herniation, no coagulation disorder) [7]. Although LP are frequently performed, CSF cultures are rarely positive (10 % in 4 case series) because the bacteria is enclosed inside of the capsule [16]. Peripheral blood test can reveal elevated white blood cell count, erythrocyte sedimentation rate (ESR) and C-reactive protein (CRP) [1].

Treatment for brain abscesses and/or empyema consists of prompt neurosurgical evacuation and high-dose parenteral antimicrobials. Limited case series show an overall mortality rate of 48 % with antimicrobial treatment alone [8]. Modern neurosurgical techniques allow stereotactic aspiration of almost all brain abscesses greater than 1 cm in diameter. If the abscess is superficial, then resection should be considered [3]. The aspirate is valuable to determine the antimicrobials for targeted therapy. Empirical antimicrobials include metronidazole and at least a third-generation or fourth-generation cephalosporin if there is a high suspicion of *Pseudomonas* spp. Patients with penetrating head injury and post-neurosurgical procedures will require both *Pseudomonas* spp. and methicillin-resistant *Staphylococcus aureus* (MRSA) coverage therefore vancomycin and anti-pseudomonal cephalosporins such as ceftazidime and cefepime are necessary. After the organism has been identified, antimicrobials should be tailored based on the sensitivities. Typical duration of antimicrobial treatment is 6–8 weeks. Neuroimaging is also recommended to evaluate the effectiveness of treatment on a monthly or bimonthly basis, or sooner if there are signs of clinical deterioration [1,3]. In the case of encephalocele causing meningitis, abscess, or empyema, repair of the cranial vault and dura must also be performed to prevent recurrence and further complications.

## Conclusion

Late-onset encephalocele causing meningitis, abscess and/or empyema formation are rare. We reported a case in which the patient presented only with fever, weakness and numbness of the lower extremities without the usual signs of meningoencephalitis and intracranial infection. In patients with an encephalocele and fever meningoencephalitis should be considered. Treatment consists of prompt recognition, appropriate antimicrobial therapy, and definitive repair of the encephalocele to prevent recurrent meningitis.

## Declaration of Competing Interest

The Authors declares that there is no conflict of interest.

## Funding source

This research did not receive any specific grant from funding agencies in the public, commercial, or not-for-profit sectors.

## CRedit authorship contribution statement

**Taylor Wang:** Conceptualization, Investigation, Writing - original draft, Writing - review & editing. **Asif Uddin:** Conceptualization, Investigation, Writing - original draft, Writing - review & editing. **Neville Mobarakai:** Conceptualization, Supervision, Writing - review & editing. **Ronit Gilad:** Conceptualization, Supervision. **Mark Raden:** Conceptualization, Supervision. **Soriaya Motivala:** Conceptualization, Supervision, Writing - review & editing.

## References

- [1] Roos KL, Tyler KL. Meningitis, encephalitis, brain abscess, and empyema. In: Kasper D, Fauci A, editors. Harrison's infectious diseases. third edition New York, NY: McGraw-Hill Education Medical.; 2017 (pp. 334–360).
- [2] Tunkel AR. Brain abscess. In: Bennett J, Dolin R, Blaser M, editors. Principles and practices of infectious disease. eighth edition Philadelphia, PA: Elsevier/Sanders; 2015. p. 1164–76.
- [3] Brouwer MC, Tunkel AR, van de Beek D. Brain abscess. N Engl J Med 2014;371(18):1758. doi:http://dx.doi.org/10.1056/NEJMc1410501.
- [4] Yang KY, Chang WN, Ho JT, Wang HC, Lu CH. Postneurosurgical nosocomial bacterial brain abscess in adults. Infection 2006;34(5):247–51. doi:http://dx.doi.org/10.1007/s15010-006-5607-5.
- [5] Sonnevile R, Ruimy R, Benzonana N, et al. An update on bacterial brain abscess in immunocompetent patients. Clin Microbiol Infect 2017;23(9):614–20. doi:http://dx.doi.org/10.1016/j.cmi.2017.05.004.
- [6] Qureshi HU, Habib AA, Siddiqui AA, Mozaffar T, Sarwari AR. Predictors of mortality in brain abscess. J Pak Med Assoc 2002;52(3):111–6.
- [7] Engelborghs S, Niemantsverdriet E, Struyfs H, et al. Consensus guidelines for lumbar puncture in patients with neurological diseases. Alzheimers Dement (Amst) 2017;8:111–26. doi:http://dx.doi.org/10.1016/j.dadm.2017.04.007 Published 2017 May 18.
- [8] Hsiao SY, Chang WN, Lin WC, et al. The experiences of non-operative treatment in patients with bacterial brain abscess. Clin Microbiol Infect 2011;17(4):615–20. doi:http://dx.doi.org/10.1111/j.1469-0691.2010.03264.x.
- [9] Hoving EW. Nasal encephaloceles. Childs Nerv Syst 2000;16(10-11):702–6. doi:http://dx.doi.org/10.1007/s003810000339.
- [10] Tirumandas M, Sharma A, Gbenimacho I, et al. Nasal encephaloceles: a review of etiology, pathophysiology, clinical presentations, diagnosis, treatment, and complications. Childs Nerv Syst 2013;29(5):739–44. doi:http://dx.doi.org/10.1007/s00381-012-1998-z.
- [11] Rapport 2nd RL, Dunn Jr RC, Alhady F. Anterior encephalocele. J Neurosurg 1981;54(2):213–9. doi:http://dx.doi.org/10.3171/jns.1981.54.2.0213.
- [12] Barros FC, Barros HA, Júnior HM, Taitson PF. Primary occipital encephalocele in an elderly patient. J Craniofac Surg 2016;27(3). doi:http://dx.doi.org/10.1097/SCS.0000000000002458 e252–e253.
- [13] Oh BH, Lee OJ, Park YS. Secondary adult encephalocele with abscess formation of calcified frontal sinus mucocoele. Childs Nerv Syst 2016;32(7):1327–31. doi:http://dx.doi.org/10.1007/s00381-015-3002-1.
- [14] Lo BW, Kulkarni AV, Rutka JT, et al. Clinical predictors of developmental outcome in patients with cephaloceles. J Neurosurg Pediatr 2008;2(4):254–7. doi:http://dx.doi.org/10.3171/PED.2008.2.10.254.
- [15] Bodilsen J, Dalager-Pedersen M, van de Beek D, Brouwer MC, et al. Long-term mortality and epilepsy in patients after brain abscess: a nationwide population-based matched cohort study [published online ahead of print, 2019 Nov 27]. Clin Infect Dis 2019. doi:http://dx.doi.org/10.1093/cid/ciz1153 ciz1153.
- [16] Chun CH, Johnson JD, Hofstetter M, Raff MJ. Brain abscess. A study of 45 consecutive cases. Medicine (Baltimore) 1986;65(6):415–31.
- [17] Tebruegge M, Curtis N. Epidemiology, etiology, pathogenesis, and diagnosis of recurrent bacterial meningitis. Clin Microbiol Rev 2008;21(3):519–37. doi:http://dx.doi.org/10.1128/CMR.00009-08.