

Preoperative Routine Cold-water Immersion for Lipedema Reduction Surgery

Jaime S. Schwartz, MD*

Eva Danesh, BA†

Noah Danesh, MPH‡

Arash Raghebi, BS*

Jonah Danesh†

Justin West, MD*

Summary: Routine cold-water immersion (CWI) is typically suggested to reduce inflammation, a hallmark property of lipedema. Lipedema is a connective tissue disorder with a genetic component that presents with a disproportionate distribution of nodules in the extremities. This case report explores the impact of routine CWI on the effectiveness of lipedema reduction surgery (LRS) and manual lipedema extraction, as part of the SMiLE technique (softening, mobilization, liposuction, and extraction). A 59-year-old woman with lipedema presented for LRS of the anterior legs. In the prior 5 months, the patient engaged in daily CWI. During LRS, there was a remarkable amount of lipedema nodules readily extracted compared with a typical patient. The patient's 5 months of routine CWI resulted in improved quality of life and decreased lipedema symptoms, and may have contributed to the quantity and ease of nodule extraction during LRS. (*Plast Reconstr Surg Glob Open* 2024; 12:e6367; doi: [10.1097/GOX.00000000000006367](https://doi.org/10.1097/GOX.00000000000006367); Published online 5 December 2024.)

A 59-year-old woman diagnosed with lipedema presented for lipedema reduction surgery (LRS) of the anterior legs. Her body mass index was 46.0, and her weight was 272 lb. Her medical history includes secondary lymphedema, hypermobile joints, endometrial cancer, and hysterectomy.

The patient noticed lipedema symptoms developing during hormonal events, including puberty and pregnancy, which is common.¹ With menopause, she experienced a significant increase in lipedema and its impact on her quality of life, including more pain and the need for a walker at the start of 2023.

Lipedema is known to have a genetic component.^{2,3} The patient observed several family members with body types similar to lipedema, but none have formal diagnoses.

This patient's LRS was unique for the remarkable amount of nodules readily released through manual extraction during the softening, mobilization, liposuction, extraction (SMiLE) technique. (See Video 1 [online], which displays manual lipedema extraction [MLE] being performed on the patient. The ease, amount, and constancy of extraction of these nodules

is unlike that in typical LRS.) The technique involves 4 steps: softening with tumescent fluid until complete turgor and exsanguination are reached, tissue mobilization through massage, power-assisted lymphatic-sparing liposuction (LSL), and MLE of nodules through massage along the long axis of the limb toward incision sites. This approach goes beyond performing only LSL, addressing nodules that LSL alone would not remove due to their size and firmness. (See Video 2 [online], which displays the importance of using the SMiLE technique and expanding beyond liposuction for LRS. Liposuction alone would not be able to remove many of the larger and firmer nodules.)

The SMiLE technique includes a final extraction step to release nodules remaining after liposuction. However, in this patient, nearly all tissue was readily extracted during the initial mobilization step. We generally consider this stage as preparation for liposuction and final manual extraction, typically seeing only occasional spontaneous nodule release. In this case, most nodules were easily removed at this step.

In our extensive experience with patients with lipedema, many have tried nonsurgical interventions, but this is the first patient to engage in consistent cold-water immersion (CWI), suggesting that CWI may have contributed to the profound ease of her LRS.

CWI—bathing in cold water or ice—includes water temperatures ranging from -2°C to 20°C .⁴ From January

From the *Private Practice, Total Lipedema Care, Beverly Hills, CA;

†Division of Undergraduate Education, University of California, Los Angeles, Los Angeles, CA; and ‡Keck School of Medicine, University of Southern California, Los Angeles, CA.

Received for publication June 19, 2024; accepted October 8, 2024.

Copyright © 2024 The Authors. Published by Wolters Kluwer Health, Inc. on behalf of The American Society of Plastic Surgeons. This is an open-access article distributed under the terms of the [Creative Commons Attribution-Non Commercial-No Derivatives License 4.0 \(CCBY-NC-ND\)](https://creativecommons.org/licenses/by-nc-nd/4.0/), where it is permissible to download and share the work provided it is properly cited. The work cannot be changed in any way or used commercially without permission from the journal.

DOI: [10.1097/GOX.00000000000006367](https://doi.org/10.1097/GOX.00000000000006367)

Disclosure statements are at the end of this article, following the correspondence information.

Related Digital Media are available in the full-text version of the article on www.PRSGlobalOpen.com.

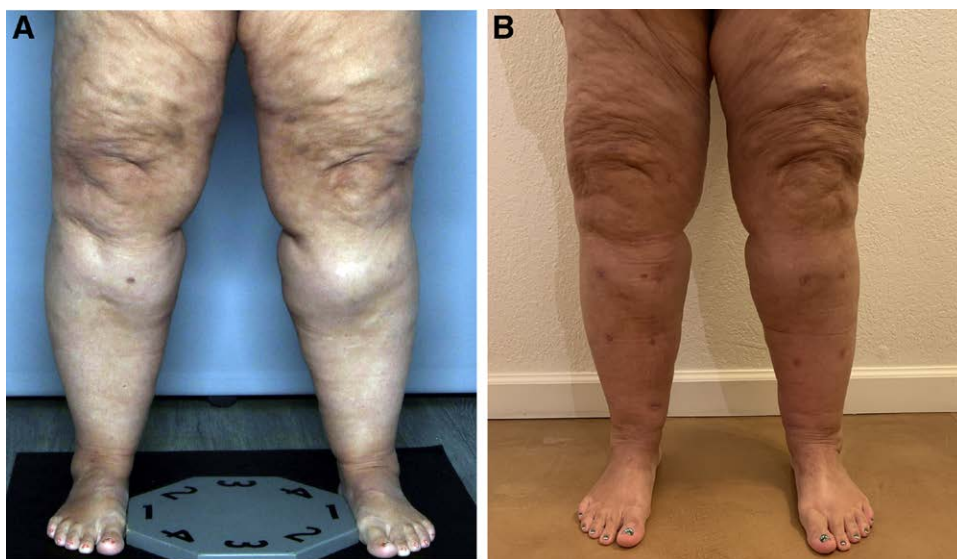


Fig. 1. Images showing the patient's legs before and after surgery. A, Before lipedema reduction surgery using the manual lipedema extraction technique. B, Six weeks postsurgery, after significant lipedema tissue removal, which had previously caused increased leg size and heaviness.

2024 until her LRS at the end of May 2024, (Fig. 1) the patient engaged in a regular CWI routine crafted by her care team. She immersed herself in her pool, which was around 13°C, nearly every day. Initially, her sessions lasted 60 seconds, but she quickly worked up to 10–20 minutes daily. While in the water, she often walked across the pool and performed stretches, including leg lifts and other movements she could not do outside the pool.

From August 2023 until her May LRS, she received manual lymphatic drainage treatments twice a week. In February 2024, she added deep tissue massage to her routine, which mimics the motions and intensity of the massage and mobilization aspects of the SMiLE technique. By March, she began noticing more nodules breaking up and becoming more noticeable. Her massage therapist reported that initially, it felt like working with a solid mass, but after daily CWI and regular massage therapy, she could identify and isolate nodules.

The patient's weight decreased from 286.5 lb in December to 271.5 lb in May without a change in her diet. Her mobility improved, and she developed a more stable gait. She could perform reciprocal stair climbing, which she had been unable to do since 2021. Notably, although she had relied on a walker for over a year, immediately before surgery she only required it for standing or walking for long periods.

DISCUSSION

This patient's case stands out due to the unique combination of her reduced pain before surgery, the ease with which the nodules were removed during the SMiLE mobilization step, and the remarkable ratio of nodules removed.

In this patient's case, liposuction and MLE of the legs removed 1400 mL aspirate and 1300 mL nodules, respectively, nearly a 1:1 ratio (Fig. 2). However, liposuction in a typical case removes significantly more tissue from the legs

as aspirate than nodules manually removed. On the basis of 20 randomly selected patients who generally match the patient's demographic—aged 50–69 years with an average body mass index of 37.9—who underwent LRS with the primary author, the average amount of tissue removed from the legs through liposuction and MLE is 1052 mL aspirate and 148 mL nodules, respectively, a ratio of 7:1. We suggest this might be due to long-term regular exposure to cold temperatures, which has been shown to reduce inflammation and pain.^{4,5} Lipedema progression is related to inflammation,⁶ which causes tissue fibrosis and pain.⁷ Inflammation in lipedema is also associated with hypoxic conditions within affected adipose tissue due to insufficient backflow and excess interstitial fluid. Both hypoxia and inflammation are believed to contribute to the significant pain endured by those with lipedema.⁷ Therefore, reducing inflammation could alleviate lipedema symptoms and potentially improve quality of life. Combined with regular and thorough massage, less inflammation could also lead to the loosening and isolation of lipedema nodules. This reduced inflammatory environment could explain the increased ease of removing lipedema nodules during the SMiLE technique. Further research should explore whether CWI affects the volume of tissue available for removal or the amount readily available to be manually extracted. The patient's decrease in weight and improved mobility are suggested to result from her routine, particularly the potential combination of increased movement enabled by being in the water and decreased inflammation resulting from the coldness. Additional research must be conducted to determine if these changes resulted directly from the cold water or indirectly due to the incorporated exercise routine but can still be attributed to the CWI immersion process.

The impact of CWI has not yet been explored with lipedema, but its benefits have been demonstrated with obesity and other metabolic diseases.⁵ The patient's results suggest

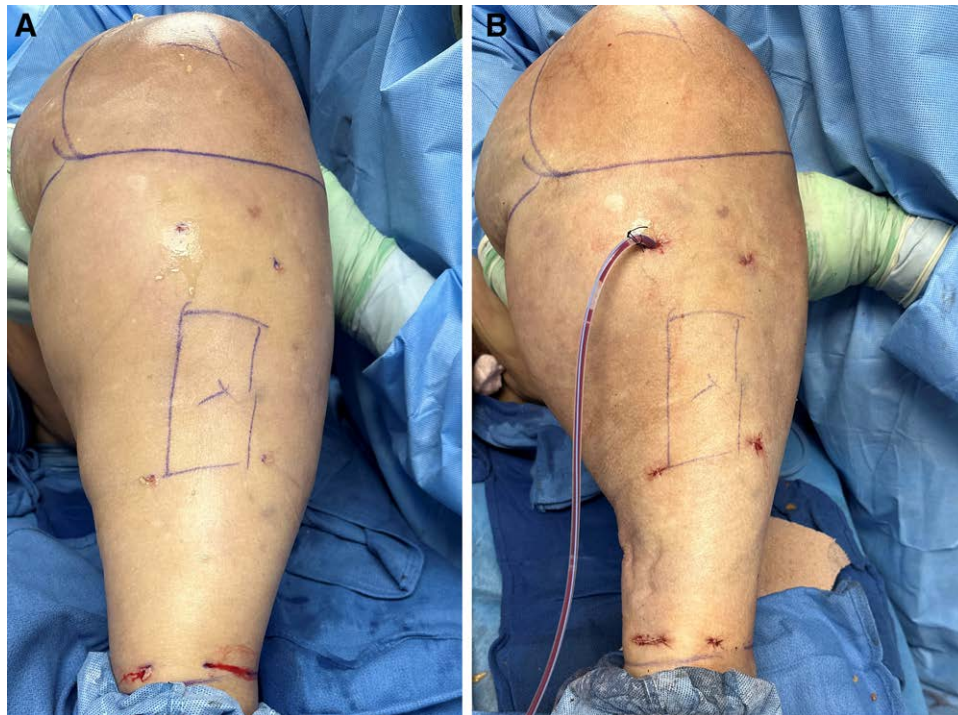


Fig. 2. Images showing the patient's left leg before and after liposuction and manual lipedema extraction. A, The patient's leg immediately before. B, Images of the patient's left leg immediately after, demonstrating tissue reduction.

that CWI could potentially be a valuable adjunct therapy to LRS, enhancing the symptomatic relief and improvements to the quality of life and ambulation it already provides.⁸

Precautions with CWI should be taken for individuals with a history of vascular conditions, including pulmonary embolism and Raynaud disease. Further research should examine the safety profile of routine CWI and its impact with and without manual lymphatic drainage and deep tissue massage to determine if this is a consistent finding. On the basis of further study, this practice may potentially be incorporated into the preoperative regimen for LRS with SMiLE to decrease patient inflammation and ensure more comprehensive removal of lipedema nodules during surgery.

Jaime S. Schwartz, MD

Total Lipedema Care
240 South La Cienega Boulevard, Suite 200
Beverly Hills, CA 90211
E-mail: drschwartz@drjaimeschwartz.com

DISCLOSURE

The authors have no financial interest to declare in relation to the content of this article.

REFERENCES

1. Katzer K, Hill JL, McIver KB, et al. Lipedema and the potential role of estrogen in excessive adipose tissue accumulation. *Int J Mol Sci*. 2021;22:11720.
2. Child AH, Gordon KD, Sharpe P, et al. Lipedema: an inherited condition. *Am J Med Genet A*. 2010;152A:970–976.
3. Michelini S, Herbst KL, Precone V, et al. A multi-gene panel to identify lipedema-predisposing genetic variants by a next-generation sequencing strategy. *J Pers Med*. 2022;12:268.
4. Esperland D, de Weerd L, Mercer JB. Health effects of voluntary exposure to cold water—a continuing subject of debate. *Int J Circumpolar Health*. 2022;81:2111789.
5. Leppäluoto J, Westerlund T, Huttunen P, et al. Effects of long-term whole-body cold exposures on plasma concentrations of ACTH, beta-endorphin, cortisol, catecholamines and cytokines in healthy females. *Scand J Clin Lab Invest*. 2008;68:145–153.
6. Poojari A, Dev K, Rabiee A. Lipedema: insights into morphology, pathophysiology, and challenges. *Biomedicine*. 2022;10:3081.
7. Herbst KL, Kahn LA, Iker E, et al. Standard of care for lipedema in the United States. *Phlebology*. 2021;36:779–796.
8. Wright T, Babula M, Schwartz J, et al. Lipedema reduction surgery improves pain, mobility, physical function, and quality of life: case series report. *Plast Reconstr Surg Glob Open*. 2023;11:e5436.