

Received: 2022.05.25

Accepted: 2022.07.21

Available online: 2022.08.30

Published: 2022.10.04

Complicated Massive Left Ventricular Thrombus and Surgical Treatment

Authors' Contribution:

Study Design A
Data Collection B
Statistical Analysis C
Data Interpretation D
Manuscript Preparation E
Literature Search F
Funds Collection G

ABEF **Sedat Pasli**
ADE **Markus Kamler**
CD **Rizwan Malik**
AE **Jerry Easo**

Department of Thoracic and Cardiovascular Surgery, West German Heart and Vascular Center, University of Duisburg-Essen, Essen, Germany

Corresponding Author: Sedat Pasli, e-mail: drsedatpasli@gmail.com

Financial support: None declared

Conflict of interest: None declared

Patient: Female, 74-year-old
Final Diagnosis: Thrombosis
Symptoms: Dyspnea
Medication: —
Clinical Procedure: —
Specialty: Cardiac Surgery

Objective: Rare disease

Background: Left ventricular thrombus formation is a serious complication of cardiac diseases and may result in acute embolic events. Early diagnosis and prompt treatment are crucial steps in preventing complications. There is a lack of consensus when it comes to therapy recommendations such as treatment with anticoagulation, thrombolysis, or surgical thrombectomy.

Case Report: A 74-year-old woman presented with acute peripheral ischemia in the left and right lower limbs. After running a diagnostic workup, we found a history of fatigue and dyspnea in the preceding 2 weeks; and an echocardiographic examination revealed a large floating mass in the left ventricle with a severely reduced LV ejection fraction of 10-15%. Coronary heart disease was diagnosed with stenosis of the circumflex artery and posterior branch of the right coronary artery, but not necessitating acute treatment.

The decision to operate on our patient was based on the acute situation and mobile form of the thrombi as to prevent further thromboembolic complications, and the surgical procedure was performed via a median sternotomy using a left ventricular apical approach due to the size and deep embedment in the ventricular trabeculae.

Conclusions: To date there is no standardized therapy in the guidelines for treatment of LV thrombi. Surgical thrombectomy can be performed in patients with mobile and protruding thrombi. In such cases surgery should be performed immediately due to the high risk of systemic embolism.

Keywords: Heart Ventricles • Thromboembolism • Thrombosis


Full-text PDF: <https://www.amjcaserep.com/abstract/index/idArt/937341>



984



4



19



Background

Left ventricular thrombus formation is a serious complication of cardiogenic diseases such as myocarditis or myocardial infarction, followed by inflammatory reactions of the myocardium resulting in excessive coagulopathy. Thrombi in the cavities of the heart often result in acute embolic events that can have cerebral effects, or systemic embolic events with increased morbidity and mortality when left untreated [1-4], thus necessitating a clearly defined stringent treatment algorithm to prevent serious complications of left ventricular thrombus. We report a rare case of a 74-year-old woman with a combination of pathologies due to a massive thrombus in the left ventricle including acute peripheral ischemia, cardiac decompensation, and combined valve pathology, treated successfully via a left ventricular apical approach.

Case Report

A 74-year-old woman presented with acute peripheral ischemia in the left and right lower limbs, necessitating emergent thromboembolectomy followed by extensive fasciotomy due to acute ischemia. Diagnostic workup revealed a history of fatigue and dyspnea in the preceding 2 weeks. Echocardiographic examination demonstrated a large mass of 4.5×4.2 cm in the left ventricle, in parts adhering to the apex and septum, floating in other parts (Figures 1, 2). LV ejection fraction was severely reduced to 10-15%, the apical portions of the left ventricle were akinetic, and the end-diastolic ventricular diameter was 65 mm. Mild mitral and tricuspid regurgitation was noted. Pulmonary artery pressure was elevated at 40 mmHg and coronary angiography revealed 2-vessel disease with 60% circumflex stenosis and 80% stenosis of the small right posterior branch without need for acute therapy (Figures 3, 4). A PCI treatment of the marginal branch stenosis was planned for a later intervention.

An immediate decision for emergent surgical embolectomy led to referral, and upon admission the patient presented with cardiogenic shock requiring inotrope medication in high doses. The patient presented with troponin levels of 517 µg/L and CK-Mb levels of 73 U/L, postulating a possible prior myocardial infarct as etiogenetic for thrombus formation.

The surgical procedure was performed via a median sternotomy. After establishment of extracorporeal circulation, cross clamp and antegrade cardioplegia with cold crystalloid solution was delivered via the aortic root for myocardial protection. After incision of the LV apex, a large 4.5×4.2 cm thrombus was found to be broadly attached to the septal and lateral wall, with thrombus deeply attached in the trabecular muscles. There was no need for coronary reconstruction via the

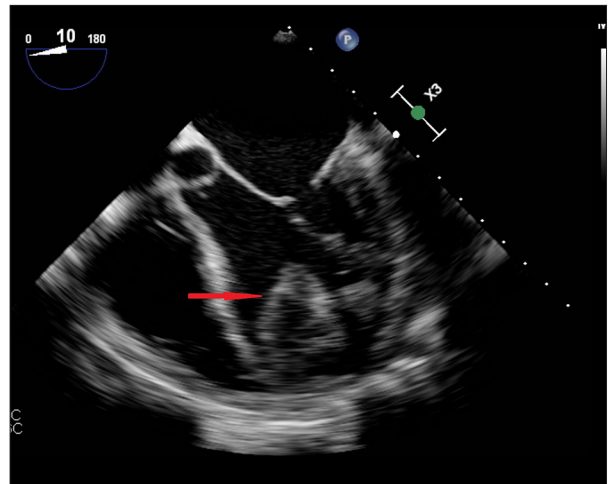


Figure 1. Echocardiographic assessment of LV thrombus localization: Illustration of a 4.5×4.2 cm thrombus localized in the apex of the left ventricle.

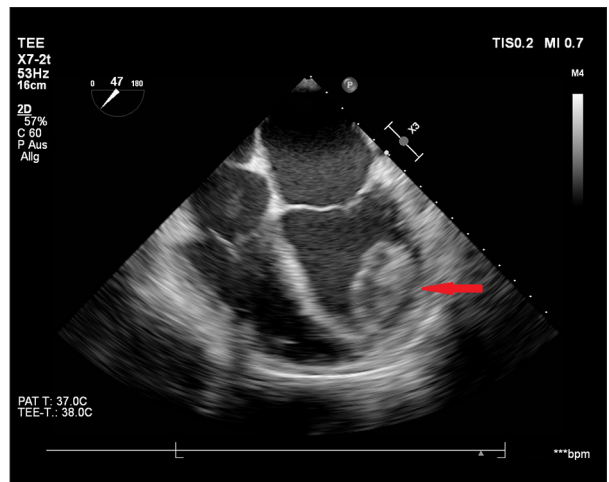


Figure 2. Thrombus adherence to LV wall: Apical 4-chamber view of the left ventricular thrombus with deep septal and trabecular position.

anatomical approach. Thrombus age was approximately 10–14 days, with older and newer portions. Thorough and meticulous extraction was performed, cleaning and flushing of the ventricle was tedious, but the surgery was straight-forward and the postoperative course was without any complications.

In the postoperative echocardiographic examination, the left ventricle was observed to be completely free from thrombus, and decreased left ventricular contractility and akinesia at the apex remained identical to the preoperative function. Coagulation disorders were excluded by additional laboratory tests.

The histopathological examination demonstrated fresh thrombus material with typical stratification without endocardium

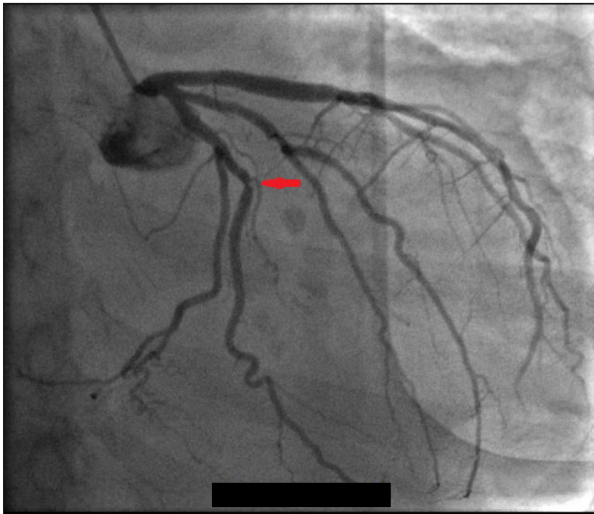


Figure 3. Coronary angiography of the circumflex artery: Illustration of a 60% circumflex stenosis highlighted by arrow.

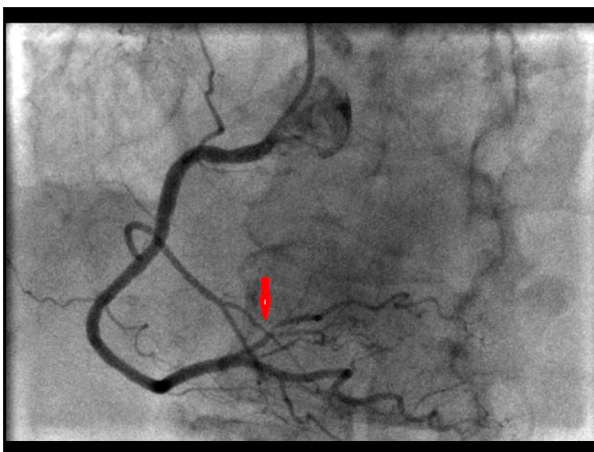


Figure 4. Coronary angiography of the right coronary artery: Illustration of a 80% stenosis of the small right posterior branch highlighted by arrow.

parts. Postoperatively, the patient had an uneventful hospital stay. Lower limb extended fasciotomy and postischemic oedema were treated with vacuum therapy until secondary closure of the wound. She was transferred to her referring hospital on postoperative day 12.

Discussion

Left ventricular thrombus formation is a complication in patients with wall motion abnormalities, usually following myocardial infarction, dilated cardiomyopathy, or myocarditis. Syndromes resulting in hypercoagulopathy such as protein S and C deficiency and antiphospholipid syndrome have also been involved in LV thrombus formation in muscular dystrophies, Behcet's

disease, and Loeffler's endocardial fibrosis, among others [5-7]. Reports show that LV thrombus increases the risk of peripheral embolization, as in our patient [1,8], particularly in patients with thrombus protrusion into the ventricular cavity and also in cases of increased mobility [9,10].

Early diagnosis and prompt treatment are crucial to prevent complications. Although echocardiography is the most frequently used diagnostic method, a study has shown that magnetic resonance imaging has the highest sensitivity and specificity for LV thrombus diagnosis in comparison with a transthoracic echocardiography [3]. Other reports show improved echocardiographic sensitivity to large protruding LV thrombi when the clinical indication was specifically for LV thrombus evaluation [11].

To date there is no standardized therapy in the guidelines for treatment of LV thrombi. Surgical thrombectomy, treatment with low molecular weight or unfractionated heparin, new oral anticoagulation therapy, and thrombolysis are various options with a wide spectrum of results. Several studies show a very high rate of systemic embolic complications after treatment with fibrinolytics, with consequent high risk of hemorrhagic events [7,12-14]. There have been few studies on the surgical treatment of LV thrombi and are mostly case reports or case series showing none of these patients to develop thromboembolism after surgical treatment [15,16]. The decision to operate on our patient was based on the mobility of the thrombi and to prevent further thromboembolic complications.

Due to several reasons, we decided to perform the surgical procedure via the left ventricular apex. The magnitude of the thrombus and the deep embedding in the trabeculae was deemed technically more challenging using a transmitral approach. The akinetic apex and the severely reduced left ventricular contractility supported the concept of a left ventricular approach, with the goal of reducing left ventricular dimension and thus possibly improving the left ventricular morphology. Alternative approaches such as via a left atriotomy [17,18] or through the aorta in concomitant aortic valve surgeries [19] have been described but were not implemented due to the above reasons.

Conclusions

Since there are no evidence-based guidelines for the treatment of LV thrombi, individual treatment options based on the risk of surgery, embolization, and bleeding must be considered. Surgical thrombectomy can be performed in patients with mobile and protruding thrombi. Surgery should be performed without delay due to the high risk of systemic embolism.

Declaration of Figures' Authenticity

All figures submitted have been created by the authors who confirm that the images are original with no duplication and have not been previously published in whole or in part.

References:

1. Haugland JM, Asinger RW, Mikell FL, et al. Embolic potential of left ventricular thrombi detected by two-dimensional echocardiography. *Circulation*. 1984;70:588-98
2. Stratton JR and Resnick AD. Increased embolic risk in patients with left ventricular thrombi. *Circulation*. 1987;75:1004-11
3. Srichai MB, Junor C, Rodriguez LL, et al. Clinical, imaging, and pathological characteristics of left ventricular thrombus: A comparison of contrast-enhanced magnetic resonance imaging, transthoracic echocardiography, and transesophageal echocardiography with surgical or pathological validation. *Am Heart J*. 2006;152(1):75-84
4. Hartman RB, Harrison EE, Pupello DF, et al. Characteristics of left ventricular thrombus resulting in perioperative embolism. *J Thorac Cardiovasc Surg*. 1983;86:706-9
5. Wilensky RL, Jung SC. Thromboembolism in patients with decreased left ventricular function: Incidence, risk, and treatment. *J Cardiovasc Risk*. 1995;2(2):91-96
6. Tilling L, Becher H. The vanishing vast ventricular thrombus. *Eur J Echocardiogr*. 2007;8(1):67-70
7. Leick J, Szardien S, Liebetrau C, et al. Mobile left ventricular thrombus in left ventricular dysfunction: Case report and review of literature. *Clin Res Cardiol*. 2013;102(7):479-84
8. van Dantzig JM, Delemarre BJ, Bot H, Visser CA. Left ventricular thrombus in acute myocardial infarction. *Eur Heart J*. 1996;17(11):1640-45
9. Ciaccheri M, Castelli G, Cecchi F, et al. Lack of correlation between intracavitary thrombosis detected by cross sectional echocardiography and systemic emboli in patients with dilated cardiomyopathy. *Br Heart J*. 1989;62(1):26-29
10. Fuster V, Halperin JL. Left ventricular thrombi and cerebral embolism. *N Engl J Med*. 1989;320(6):392-94
11. Weinsaft JW, Kim HW, Crowley AL, et al. LV thrombus detection by routine echocardiography: Insights into performance characteristics using delayed enhancement CMR. *JACC Cardiovasc Imaging*. 2011;4(7):702-12
12. Mallory R, Balcezak T. Treatment of mobile left ventricular thrombus with low-molecular-weight heparin. *N Engl J Med*. 1999;341(14):1082-83
13. Keren A, Goldberg S, Gottlieb S, et al. Natural history of left ventricular thrombi: Their appearance and resolution in the post hospitalization period of acute myocardial infarction. *J Am Coll Cardiol*. 1990;15(4):790-800
14. Sari I, Davutoglu V, Soydinc S, et al. Fibrinolytic treatment in left ventricular mobile thrombi with low ejection fraction: Results and follow-up of seven cases. *J Thromb Thrombolysis*. 2008;25:293-96
15. Lee JM, Park JJ, Jung HW, et al. Left ventricular thrombus and subsequent thromboembolism, comparison of anticoagulation, surgical removal, and antiplatelet agents. *J Atheroscler Thromb*. 2013;20(1):73-93
16. Nili M, Deviri E, Jortner R, et al. Surgical removal of a mobile, pedunculated left ventricular thrombus: Report of 4 cases. *Ann Thorac Surg*. 1988;46(4):396-400
17. Tanaka D, Unai S, Diehl JT, Hirose H. Surgical removal of a large mobile left ventricular thrombus via left atriotomy. *World J Clin Cases*. 2014;2(2):32-35
18. Early GL, Ballenger M, Hannah H 3rd, Roberts SR. Simplified method of left ventricular thrombectomy. *Ann Thorac Surg*. 2001;72:953-54
19. Williamson C, Sheehan LB, Venesy DM, D'Agostino RS. Transaortic, video-assisted removal of a mobile left ventricular apical thrombus in a patient with aortic stenosis and severe left ventricular dysfunction. *J Thorac Cardiovasc Surg*. 2016;151:e1-3