



## Oncology

# An Explanatory Case on the Limitations of Lymph Node Staging in Recurrent Prostate Cancer



Marco Bandini\*, Giorgio Gandaglia, Nicola Fossati, Francesco Montorsi, Alberto Briganti

Division of Oncology/Unit of Urology, URI, IRCCS Ospedale San Raffaele, Milan, Italy

## ARTICLE INFO

## Article history:

Received 18 January 2017

Received in revised form

3 February 2017

Accepted 9 February 2017

## Keywords:

Prostate cancer

PSMA PET/CT

Salvage lymph nodes dissection

USPIO-MRI

## ABSTRACT

We describe the case of a 54-year-old man with nodal recurrence prostate cancer after radical prostatectomy, salvage external-beam radiotherapy and salvage lymph node dissection. The patient was evaluated with a lymphotropic ultrasmall superparamagnetic particles of iron oxide (USPIO)-MRI and a  $^{68}\text{Ga}$  radiolabelled prostate specific membrane antigen (Ga68-PSMA) PET-CT scan which enhanced persistent localized nodal disease. The patient was then considered for a second robot-assisted extended S-LND. Differently from preoperative imaging, pathology report revealed a wide nodal involvement mirroring a metastatic disease. The current manuscript is an explanatory case on the limitations of lymph node imaging in prostate cancer recurrence.

© 2017 The Authors. Published by Elsevier Inc. This is an open access article under the CC BY-NC-ND license (<http://creativecommons.org/licenses/by-nc-nd/4.0/>).

## Introduction

Approximately 30% of PCa patients experience BCR after primary treatment. The lymph nodes are common sites of recurrence.

Novel imaging modalities allow for the accurate detection of the site of recurrence. Particularly, PSMA PET-CT and the USPIO-MRI emerged as valid tools in the setting of recurrent PCa. Of note, these imaging modalities might guide metastases-directed approaches as the SLND.

The current manuscript represents the first report describing a robot-assisted S-LND based on the results of preoperative PSMA PET-CT and USPIO-MRI. At the same time, this is an explanatory case on the limitations of LN imaging in PCa recurrence.

## Case report

The report began in November 2010 when the patient underwent robotic assisted radical prostatectomy with bilateral pelvic lymph node dissection because of biopsy diagnoses of PCa. The final pathology documented a pT3aN0R0 adenocarcinoma of the

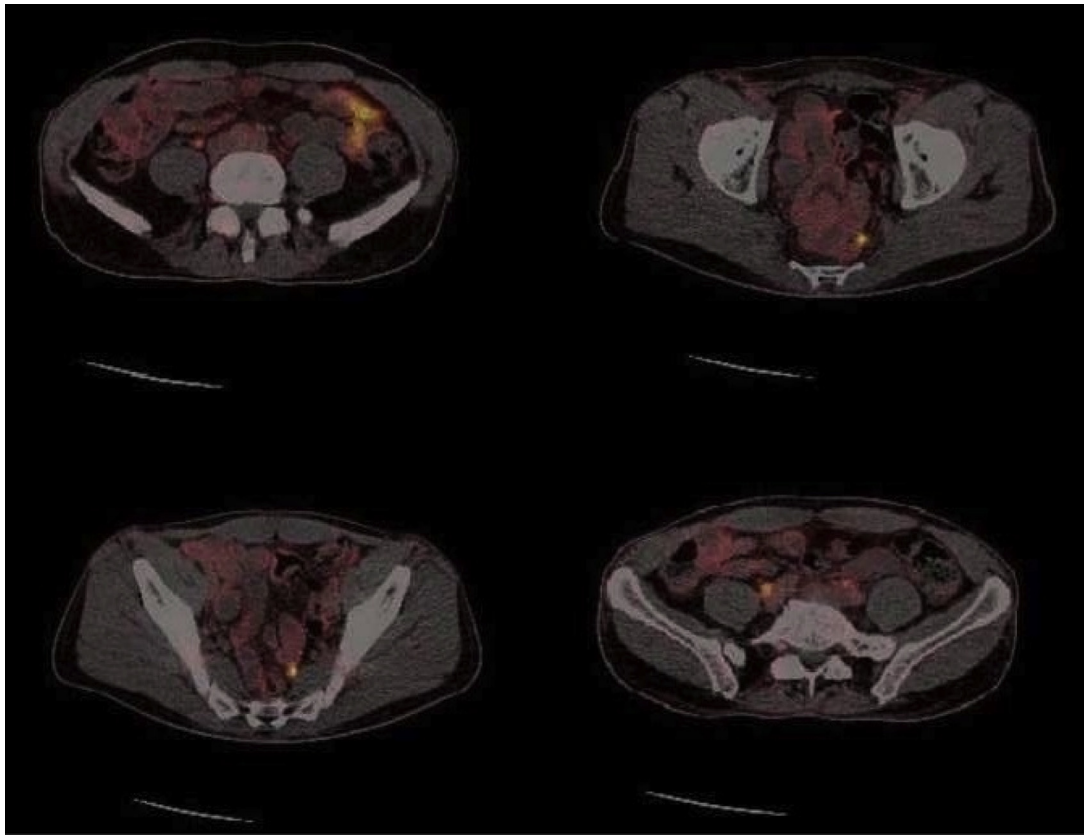
prostate, GS 7 (4 + 3), with 22 LNs removed. Serum PSA was undetectable after surgery ( $<0.001$  ng/mL). Approximately 27 months later, the patient experienced biochemical recurrence (BCR), defined as two consecutive PSA  $\geq 0.2$  ng/mL. The patient received salvage external-beam radiotherapy (S-EBRT) targeted to the prostatic fossa and the pelvic area. The PSA value 6 weeks after S-EBRT decreased from 0.38 to 0.12 ng/mL. In March, 2015 the patient experienced a further rise of the serum PSA levels to 1.56 ng/mL. A PET-CT scan with  $[^{11}\text{C}]\text{choline}$  was then performed. This imaging modality identified 1 left common iliac LN suspicious for metastases and other LNs with uncertain uptake close to internal and external iliac artery bilaterally (Fig. 1). Subsequently, the patient received a robot-assisted S-LND on November 2015. Overall, 7 nodes were removed from left bifurcation of the aorta and the left internal/external iliac nodes. Moreover, 5 LNs were removed contralaterally. At final pathology, three common iliac nodes out of twelve were positive for PCa metastases. PSA was still detectable 6 weeks after surgery. When the patient was firstly referred to our center the PSA level was 6.2 ng/mL. The patient did not receive any androgen deprivation therapy and/or chemotherapy before. He was not taking any medication, he was asymptomatic, and he had no relevant comorbidities.

The patient was evaluated with the PSMA-PET. The baseline investigation with choline showed an uptake of radionuclide at the lymph nodes close to the aorta and the common iliac vessel bilaterally. Two other positive nodes were reported over the left psoas muscle. Moreover, the PSMA-PET scan (Fig. 1) showed an additional uptake into the pre-sacral lymph nodes. No other

*Abbreviations:* PCa, prostate cancer; LN/s, lymph node/s; PSA, prostate specific antigen; PSMA, radiolabeled prostate specific membrane antigen; USPIO, lymphotropic ultrasmall superparamagnetic particles of iron oxide; SLND, salvage lymph node dissection; RP, radical prostatectomy; S-EBRT, salvage external-beam radiotherapy; BCR, biochemical recurrence.

\* Corresponding author. Fax: +39 02 2643 7298.

E-mail address: [bandini.marco@hsr.it](mailto:bandini.marco@hsr.it) (M. Bandini).



**Figure 1.** PSMA PET/CT (radiolabeled prostate specific membrane antigen Ga68-PSMA) scan performed in order to improve accuracy of lymph nodes metastases localization before second SLND: basically, the same lymph nodes previously identified with [11-C]choline are also highlight with PSMA however, an additional uptake into the pre-sacral lymph nodes is highlighted.

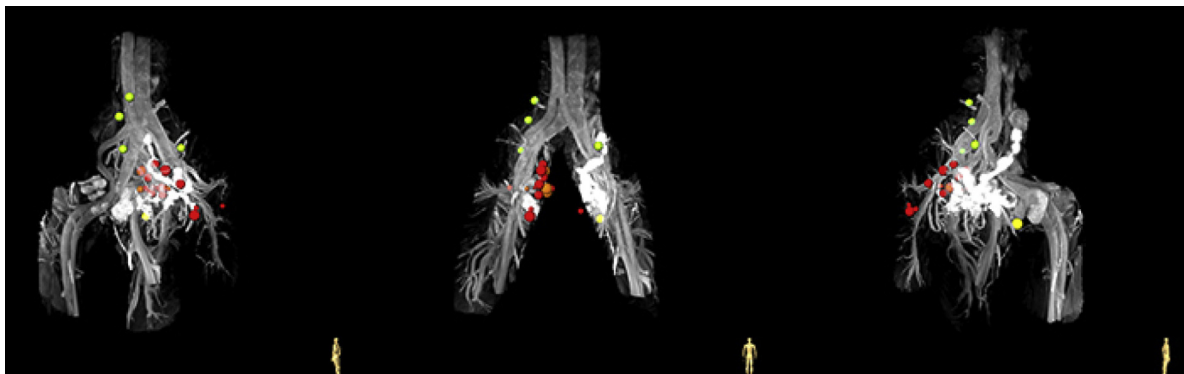pathologic uptakes in the prostatic fossa or in other soft tissues were reported. In addition, the patient underwent an USPIO-MRI that was prescribed by a different physician. The USPIO-MRI detected 15 nodes suspected for metastases. These nodes were predominantly located at the left pre-sacral region and in the dorsal pelvis (Fig. 2). The five largest pelvic lymph nodes detected with USPIO-MRI were positive also with PSMA PET-CT.

On April, the 28th, the patient underwent a second robot-assisted SLND. Operative time was 4 h 43 min and blood loss was 250 ml. The dissection template included residual lymphatic tissue in the pelvic nodal stations, as well as the tissue located between the aortic bifurcation and the origin of the renal arteries.

Forty-four of the 76 LNs removed in the procedure contained metastatic cells from the PCa. Metastases were found even outside the areas of positivity of PET/CT scan and USPIO-MRI. The patient was revalued 40 days after surgical operation and we observed an incomplete decrease in PSA levels to 2.2 ng/mL. Androgen deprivation therapy (ADT) was then initiated.

## Discussion

Up to 30% of men with PCa treated with surgery would experience BCR during follow-up.<sup>1</sup> The administration of ADT, which is the standard of care in the presence of metastatic PCa,<sup>2</sup> is debated in



**Figure 2.** USPIO (ultrasmall superparamagnetic particles of iron oxide)-MRI: this frame highlight different kinds of lymph nodes suspected for metastases. Summarily, the USPIO-MRI detected 15 nodes suspected for metastases. These nodes were predominantly located at the left pre-sacral region and in the dorsal pelvis. Green: no metastasis; Light green: probably no metastasis; Yellow: uncertain; Orange: probably metastasis; Red: certain metastasis.

case of recurrence limited to the LNs. On the other hand, metastases-directed therapies could delay the use of systemic therapies, preserving quality of life and potentially improving oncologic outcomes.

Selected patients with LNs relapse limited to the regional and/or retroperitoneal nodes might not be affected by a systemic disease and the removal of metastases could be associated with oncologic benefits. In particular, the administration of SLND might delay the use of systemic therapies in selected patients, improving oncologic outcomes and preserving quality of life. However, available data support the oncologic role of SLND only in men with a low number of positive lymph nodes who achieve a biochemical response after this procedure.<sup>3</sup> Conversely, in case of extensive disease in the pelvic and retroperitoneal stations surgery alone is unlikely to obtain a biochemical response and systemic therapies should be considered in a multimodal approach.<sup>2</sup>

On the other hand, the surgical management of nodal metastases still represents an experimental procedure that should be proposed only when LN recurrences are suspected. To fill this lack, molecular medicine led to the development of novel imaging modalities that allow for an accurate detection of the metastatic site in the setting of recurrent PCa. Ga68-PSMA demonstrated a particularly higher accuracy in the identification PCa nodal metastasis.<sup>4</sup> Similarly, the combination of USPIO-enhanced MRI and DW-MRI depicted optimal performance characteristics in detecting lymph node metastases.<sup>5</sup> At the best of authors' knowledge this is the first available report in the literature describing surgical salvage treatments administered on the basis of these advanced imaging modalities. Our case was able to highlight the limitation of imaging as the guide for metastases-directed therapy in PCa patients. Indeed, several LNs that did not show uptake at PSMA PET/CT scan and USPIO-MRI were positive for metastatic PCa cells at final pathology. On the other hand, an anatomically defined extended LN dissection that includes the pelvic and retroperitoneal stations was able to identify a substantially higher number of positive LNs as compared to what observed at preoperative imaging.

## Conclusion

Based on this case report, extended SLND allow for a correct nodal staging of patients with suspected lymph node recurrences even when molecular imaging was ineffective. Despite a complete biochemical response was not achieve for our patients, the consequently accurate evaluation of nodal tumor burden and of the number of positive nodes might have important clinical implications for the administration of further therapies.

## Conflict of interest

None declare.

## Acknowledgements

None financial grants and other funding have been acknowledged.

## References

1. Pound CR, Partin AW, Eisenberger MA, et al. Natural history of progression after PSA elevation following radical prostatectomy. *JAMA*. 1999;281:1591–1597.
2. Sweeney CJ, Chen Y-H, Carducci M, et al. Chemohormonal therapy in metastatic hormone-sensitive prostate cancer. *N Engl J Med*. 2015;373:737–746.
3. Suardi N, Gandaglia G, Gallina A, et al. Long-term outcomes of salvage lymph node dissection for clinically recurrent prostate cancer: results of a single-institution series with a minimum follow-up of 5 years. *Eur Urol*. 2015;299–309.
4. Evangelista L, Briganti A, Fanti S, et al. New clinical indications for 18F/11C-choline, new tracers for positron emission tomography and a promising hybrid device for prostate cancer staging: a systematic review of the literature. *Eur Urol*. 2016;70:161–175.
5. Birkhäuser FD, Studer UE, Froehlich JM, et al. Combined ultrasmall superparamagnetic particles of iron oxide-enhanced and diffusion-weighted magnetic resonance imaging facilitates detection of metastases in normal-sized pelvic lymph nodes of patients with bladder and prostate cancer. *Eur Urol*. 2013;64:953–960.