

Avascular necrosis in children with cerebral palsy after reconstructive hip surgery

L. Phillips¹
K. Hesketh¹
E. K. Schaeffer^{1,2}
J. Andrade¹
J. Farr¹
K. Mulpuri^{1,2}

Abstract

Purpose Progressive hip displacement is one of the most common orthopaedic pathologies in children with cerebral palsy (CP). Reconstructive hip surgery has become the standard treatment of care. Reported avascular necrosis (AVN) rates for hip reconstructive surgery in these patients vary widely in the literature. The purpose of this study is to identify the frequency and associated risk factors of AVN for reconstructive hip procedures.

Methods A retrospective analysis was performed of 70 cases of reconstructive hip surgery in 47 children with CP, between 2009 and 2013. All 70 cases involved varus derotation osteotomy (VDRO), with 60% having combined VDRO and pelvic osteotomies (PO), and 21% requiring open reductions. Mean age at time of surgery was 8.82 years and 90% of patients were Gross Motor Function Classification System (GMFCS) 4 and 5. Radiographic dysplasia parameters were analysed at selected intervals, to a minimum of one year post-operatively. Severity of AVN was classified by Kruczynski's method. Bivariate statistical analysis was conducted using Chi-square test and Student's t-test.

Results There were 19 (27%) noted cases of AVN, all radiographically identifiable within the first post-operative year. The majority of AVN cases (63%) were mild to moderate in severity. Pre-operative migration percentage (MP) ($p = 0.0009$) and post-operative change in MP ($p = 0.002$) were the most significant predictors of AVN. Other risk factors were: GMFCS level ($p = 0.031$), post-operative change in NSA ($p = 0.02$) and concomitant adductor tenotomy (0.028).

Conclusion AVN was observed in 27% of patients. Severity of displacement correlates directly with AVN risk and we suggest that hip reconstruction, specifically VDRO, be performed early in the 'hip at risk' group to avoid this complication.

Cite this article: Phillips L, Hesketh K, Schaeffer EK, Andrade J, Farr J, Mulpuri K. Avascular necrosis in children with cerebral palsy after reconstructive hip surgery. *J Child Orthop* 2017;11:326-333. DOI 10.1302/1863-2548.11.170078

Keywords: cerebral palsy; hip displacement; avascular necrosis; varus derotation osteotomy; reimer's migration percentage

Introduction

Progressive hip displacement is one of the most common orthopaedic pathologies in children with cerebral palsy (CP). The incidence and severity of hip displacement in CP is directly related to the degree of gross motor function. Using the Gross Motor Function Classification Score (GMFCS), Soo et al identified the incidence of hip displacement as 0% for children with GMFCS level 1 and 90% for those with GMFCS level 5.¹ A displaced hip can result in pain, reduced range of motion, skin breakdown, difficulty with perineal hygiene, difficulty with seating and positioning, and may contribute to the development of scoliosis and pelvic obliquity.²⁻⁵ Reconstructive surgery has become the standard of care in treating progressive subluxation and dislocation of the hip in this population.⁶⁻⁹ Reported complication rates for hip reconstructive surgery in patients with CP have varied dramatically (0% to 81%).^{8,10-18} There has been minimal attention paid to the development of avascular necrosis (AVN) as a complication of hip reconstructions. The incidence of AVN reported within the literature is in the range of 0% to 69%.^{10,11,14,15,17-20} This variation has made it difficult to quantify and determine the true impact of AVN on children with CP. Idiopathic AVN has been reported to cause pain, limited range of motion (ROM) and an altered gait pattern.²¹ In children with developmental dysplasia of the hip (DDH), Roposch et al reported that there is a large variation in the clinical presentation of AVN.²¹ Severe forms lead to hip pain and premature debilitating osteoarthritis, while mild forms may have minimal deformity and dysfunction.²¹ The pathology itself and the clinical effects of AVN in children with CP have yet to be determined.

¹Department of Orthopaedic Surgery, BC Children's Hospital, Vancouver, BC, Canada

²Department of Orthopaedics, University of British Columbia and Department of Orthopaedic Surgery, BC Children's Hospital, Vancouver, BC, Canada

Correspondence should be sent to: Dr K. Mulpuri, Department of Orthopaedic Surgery, BC Children's Hospital, 1D66-4480 Oak Street, Vancouver, BC, Canada.
E-mail: kmulpuri@cw.bc.ca

Diagnosis of AVN is based on radiographic images and clinical symptoms, which is a highly subjective process dependent upon the individual surgeon. There is currently no standardised, rigorous method for the objective diagnosis of AVN. Additionally, the quantification of pain and symptoms within the CP population is particularly challenging; therefore, the clinical relevance of AVN may be underestimated in these patients.

The purpose of this study is to identify the frequency and associated risk factors of AVN for reconstructive hip procedures in children with CP.

Patients and methods

A retrospective review was performed of children with CP surgically treated for hip subluxation at a single institution between 2009 and 2013. Further inclusion criteria were: patients aged 2 to 18 years; diagnosis of CP regardless of subtype; varus derotation osteotomy (VDRO) as the primary surgical treatment; and minimum follow-up of one year. Patients with insufficient follow-up, soft-tissue procedures only, salvage procedures or pre-operative evidence of AVN were excluded from the study.

All procedures were performed by one of two surgeons at our institution and consisted of VDRO with or without adjunctive procedures. These adjunctive procedures included adductor tenotomy, pelvic osteotomy and open reduction. When required, soft-tissue releases were completed first, followed by VDRO through a standard lateral, sub-vastus approach. A relative shortening of the femur was performed in all cases through the resection of a wedge of bone for the purpose of the VDRO, but this was not of standardised length. Dega osteotomy was the preferred pelvic osteotomy where performed. All open reductions were done through an anterior approach. While there was variability in method and duration of post-operative immobilisation, the majority of patients were placed in a Spica or Petrie cast for approximately four weeks followed by long-term splinting.

A detailed analysis of clinical and radiological data was performed on all children meeting the inclusion criteria prior to surgery, and post-operatively at six months, one year and two years.

Radiological evaluation was completed independently by two orthopaedic surgeons using standardised antero-posterior (AP) and frog-leg lateral radiographs of the pelvis. To determine concordance of radiographic diagnosis of AVN between our reviewers, inter-observer reliability calculations were performed. Across all radiographs included in the study at all time points, substantial agreement (Kappa = 0.76) was seen between our two reviewers. Specifically, at the one-year time point for AVN assessment, almost perfect agreement (Kappa = 0.86) was seen.

Radiographic parameters collected included: Reimer's migration percentage (MP),²³ acetabular index (AI),²⁴ Hilgenreiner's epiphyseal angle (HEA),²⁵ neck shaft angle (NSA)²⁶ and pelvic obliquity (PO). The presence and severity of AVN was evaluated according to Kruczynski's classification, a method relying on plain radiographs and combining previous works of AVN in DDH.²⁷

Frequency tables were constructed for all categorical variables and descriptive statistics were calculated for all measurement variables. A combination of Chi-square and two-sample t-tests were used to compare AVN with categorical and radiographic predictors. Confidence intervals for the difference in means were constructed for all measurement predictors.

Results

We reviewed all cases of reconstructive hip surgery over a four-year period at our institution, where VDRO was the primary procedure in patients with CP. After eliminating patients with insufficient follow-up and 11 cases of pre-morbid AVN, there were 70 reconstructive hip surgeries in 47 patients available for final analysis (Fig. 1).

Pre-operative patient demographics are shown in Table 1. The 31 patients were male and 16 patients were female. There were ten unilateral right hips, 15 unilateral left hips, 22 bilateral cases and one revision procedure. The mean age at time of surgery was 8.82 years (3.02 to 17.3). In total, 43 of the children (91%) were GMFCS levels 4 and 5. Given the universal lack of consensus diagnosing topographic subtype of CP we intentionally did not report or analyse this factor.

In addition to a VDRO, Dega osteotomy was performed in 60% (42 hips) of the cases, 21% (15 hips) required open reductions, and 70% (49 hips) had adductor releases. Of note, many of these patients had previous isolated adductor releases therefore explaining why it was not performed in all cases as an adjunct. Only a few hips (n = 14) required comprehensive reconstructions requiring all of the above. The mean post-operative follow-up was 2.73 years (1.0 to 6.72).

The mean pre-operative Reimer's MP of our entire cohort measured 60%. This improved radiographically to an average MP of 11%, at six-month post-operative follow-up. The mean pre-operative AI was 32.4° and was corrected by an average of 8.9° to 23.7° at the same follow-up. This improvement in AI was influenced by a concomitant pelvic osteotomy. AI improved by an average of 14.8° (95% confidence interval (CI) 11.3 to 18.3) in hips that also underwent a pelvic osteotomy compared with 0.6° (95% CI -1.4 to 2.6) in hips that did not. NSA averaged 155° pre-operatively and was corrected to 116°. HEA changed from a mean pre-operative 10° to 53°. Pelvic

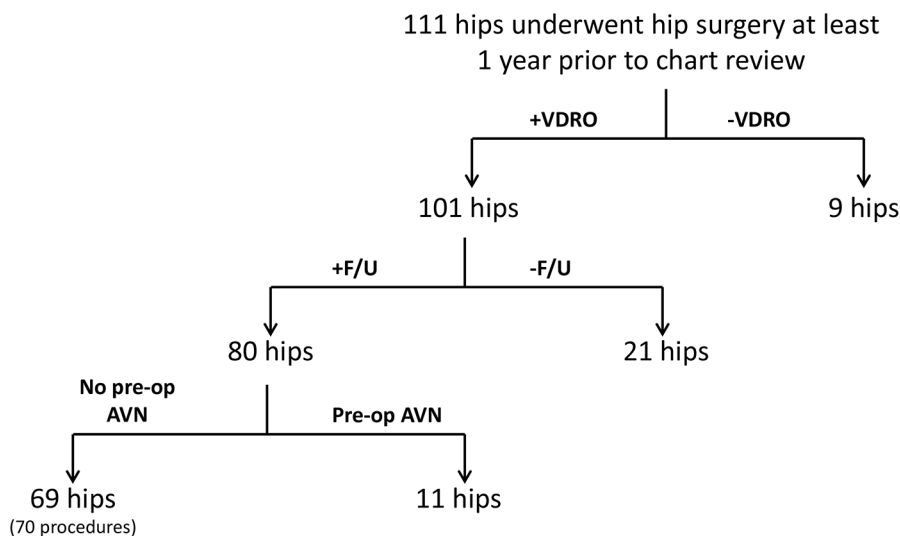


Fig. 1 All hips in CP patients undergoing surgery at a single institution between 2009 and 2013. Included hips underwent a varus derotation osteotomy (VDRO), with at least one year of post-operative follow-up with no evidence of pre-operative avascular necrosis.

Table 1. Patient demographics.

Patient demographics	n = 47
<i>Gender</i>	
Male	31
Female	16
<i>Age (yrs)</i>	
Mean at surgery	8.82
<i>GMFCS level</i>	
2	1
3	3
4	17
5	26
<i>Surgical hips</i>	
Right	10
Left	15
Bilateral	22

obliquity remained relatively unchanged after hip reconstruction.

A total of 19 (27%) hips were identified to have radiographic signs of AVN, all occurring within the first post-operative year. All but one case of AVN was present in patients with GMFCS 4 or 5. There were three GMFCS 5 patients with bilateral AVN after bilateral hip procedures involving VDRO and adductor releases.

The severity of AVN was evaluated using a classification described by Kruczynski in 1987 (Table 2).²⁷ The majority of the identified cases (63%) of AVN had mild-to-moderate epiphyseal changes only. At the two-year follow-up, eight cases showed radiographic evidence of healing, while 11 cases of AVN persisted at last follow-up. Examples of AVN

Table 2. Classification of avascular necrosis (AVN) by the Kruczynski method.²⁷

AVN type	Description	Hips
1	Involvement of epiphysis, no fragmentation, mild changes	5
2	Involvement of epiphysis with fragmentation, moderate changes	7
3	Involvement of epiphysis and lateral part of metaphysis, severe changes	1
4	Involvement of epiphysis and medial metaphysis, severe changes	3
5	Involvement of epiphysis and whole metaphysis, severe changes	3

of varying severity and resolution from this patient cohort are shown in Figure 2.

Risk factors showing a statistically significant correlation with the development of AVN included: higher pre-operative Reimer's MP ($p = 0.0009$); larger immediate change in MP ($p = 0.002$) and NSA ($p = 0.02$) (Table 3); and concomitant adductor tenotomy ($p = 0.028$) (Table 4). Additionally, a higher pre-operative NSA was suggestive of AVN development, but did not reach statistical significance ($p = 0.079$).

There was also evidence of a relationship between higher GMFCS level and development of AVN when comparing patients at levels 1 to 3 with patients at levels 4 to 5 ($p = 0.031$); however, when comparing only level 4 with level 5 patients, this did not reach significance ($p = 0.052$).

There was no relationship between AVN and sex, affected side, concomitant pelvic osteotomy, open reduction or any other soft-tissue procedures (Table 3).

Other noted complications included: three fragility fractures (4.3%); three pressure sores (4.3%); and one

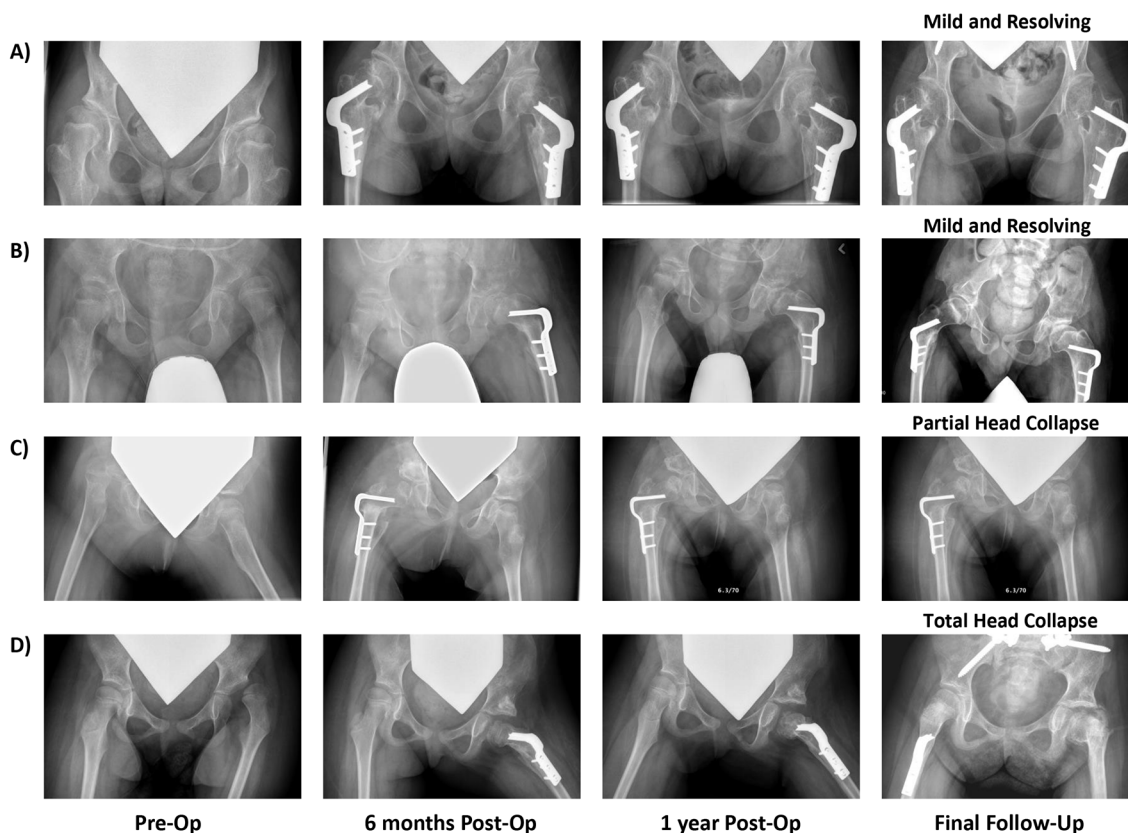


Fig. 2 Examples of radiographic avascular necrosis (AVN) progression following varus derotation osteotomy (VDRO), depicting (A) resolution of AVN, (B) mild AVN, (C) AVN with partial head collapse and (D) AVN with total head collapse; all at final follow-up.

infection (1.4%). There was one hip with a recurrent subluxation requiring re-operation.

Discussion

The reported incidence of AVN of the femoral head in children with CP after hip reconstruction is in the range of 0% to 69%.^{10,11,13,18,20,28-30} A recent systematic review³¹ on the subject revealed that most authors simply comment on the presence or absence of AVN in their complications, without further detail. Interestingly, the reported rates in our study as well as three others where AVN was the primary outcome measure are among the highest within the literature at 27% to 69%.^{10,11,18} Koch et al reported an incidence of 68.7%, Stasikelis 46% and Khalife 37%.

There are no universally accepted criteria for diagnosing AVN, nor is the underlying mechanism fully understood. Therefore, making the diagnosis of AVN can be challenging and requires subjective judgment. This is made more difficult in CP where it is common to see irregular femoral head geometry,¹¹ flattening from chronic subluxation,⁷ decreased bone density particularly in non-ambulatory patients and iatrogenic deformities such as coxa vara from surgical treatments. The literature does not suggest that

any efforts have been made to create a separate diagnostic or classification system for AVN in children with CP. The most commonly used systems, including Bucholz and Ogden,³² Kalmachi and MacEwen,³³ and the lesser known Kruczynski²⁷ classification, have been extrapolated from DDH literature. These classification systems all pose the same limitations of being based on plain radiography *versus* MRI, possible poor inter- and intra-observer reliability because of subjective interpretation, failure to provide information about mechanism/aetiology, difficulty interpreting the clinical significance and prognosis, lack of correlation with long-term outcome and lack of validation in children with CP. This points to the necessity of a standardised diagnostic and classification criteria for AVN of the femoral head in CP, as this deficiency has surely contributed to the wide variability in reported incidence.

Osteonecrosis of the femoral head is a progressive process due to multiple factors affecting the blood supply of the femoral head and the disruption of the synthesis of the bone component.³⁴ Two commonly proposed mechanisms of femoral head ischemia are extrinsic blood vessel compression/injury and excessive pressure on the femoral head, both of which prevent perfusion.³⁵ Despite the unclear mechanisms contributing to collapse, factors

Table 3. Comparison of presence of avascular necrosis (AVN) with respect to measurement predictors.

Predictor	Mean (95% CI)		t-test p-value
	AVN = Yes (n = 19)	AVN = No (n = 57)	
Age at last follow-up (yrs)	12.3 (10.7-13.9)	11.2 (10.2-12.2)	0.24
Age at surgery (yrs)	8.9 (7.3-10.4)	8.7 (7.8-9.6)	0.87
<i>Pre-operative measures</i>			
MP	77.3 (66.5-88.0)	53.9 (45.7-62.2)	0.0009
AI	34.6 (28.9-40.4)	31.5 (29.1-34.0)	0.31
NSA	159.7 (153.2-166.3)	153.4 (150.3-156.5)	0.079
HEA	11.9 (2.5-21.4)	9.3 (6.0-12.5)	0.58
PO	3.9 (2.4-5.4)	5.2 (4.0-6.3)	w
<i>Post-operative change (Δ) (pre-op – six months post-op)</i>			
ΔMP	66.8 (53.4-80.2)	41.9 (32.5-51.3)	0.002
ΔAI	10.1 (4.5-15.8)	8.4 (5.0-11.7)	0.62
ΔNSA	47.2 (38.0-56.3)	35.5 (32.1-39.0)	0.02
ΔHEA	45.8 (33.3-58.3)	41.0 (35.2-46.8)	0.52
ΔPO	-0.8 (-3.3-1.6)	-1.3 (-2.6-0.03)	0.89

MP, migration percentage; AI, acetabular index; NSA, neck shaft angle; HEA, Hilgenreiner's epiphyseal angle; PO, pelvic obliquity.

Table 4. Comparison of presence of avascular necrosis (AVN) with respect to categorical predictors.

Categorical predictor (p-value)	AVN = Yes (n = 19) % Hips (# Hips)
<i>Gender (0.112)</i>	
Male	22 (10)
Female	38 (9)
<i>GMFCS (0.031)</i>	
1-3	14 (1)
4-5	29 (18)
<i>Hip side (0.292)</i>	
Left	32 (12)
Right	21 (7)
<i>Pelvic osteotomy (0.154)</i>	
No	18 (5)
Yes	33 (14)
<i>Open reduction (0.543)</i>	
No	25 (14)
Yes	33 (5)
<i>Adductor release (0.028)</i>	
No	8 (2)
Unilateral	57 (8)
Bilateral	41 (9)

affecting bone necrosis have been found to be related to significant biomechanical changes and physical stress in the load-bearing area of the femoral head.³⁶

As it was not the purpose of this study to determine causation, we can only speculate regarding aetiology. It

is, however, a reasonable hypothesis that surgically reducing a severely displaced hip could produce compression of the femoral head itself or its blood supply, especially in the setting of inadequate femoral shortening. We cannot exclude surgical technique as a cause, but were unable to compare surgeon-specific rates of AVN in our cohort because of the small percentage (13%) of procedures performed by one of the two surgeons.

An essential element in making the diagnosis of AVN is allowing passage of sufficient time for changes to manifest on a radiograph. This was a retrospective review and while our average follow-up was 2.73 years, we had a number of rapidly evolving cases of AVN, which is in conflict with the previously proposed diagnostic criteria of Salter,³⁷ where a minimum of one year is required to diagnose AVN. These cases could represent a pseudo-osteonecrosis state with transient epiphyseal mechanical deformation or growth modulation post reduction, but this cannot be confirmed within the confines and limitations of this retrospective study. As of yet, we do not have any terminology or nomenclature to distinguish this process from AVN.

There were several, further limitations to this study. First, AVN is inherently a subjective outcome measure that may be impacted by timing and radiograph positioning. A lack of rigorous, standardised positioning for routine AP radiographs may have interfered with the interpretation. However, we mitigated this subjectivity by having two independent reviewers rate each radiograph included in the study and they demonstrated substantial to near-perfect agreement. Second, being retrospective in nature, we were prevented from establishing the long-term clinical,

functional or health-related significance of AVN as a complication of hip reconstruction. The majority of our cases of AVN were of mild and moderate severity, as classified by Kruczynski.²⁷ Previous authors have reported that limited involvement of the epiphysis alone results in minimal deformity and little long-term dysfunction.^{32,33,38,40} Koch et al¹¹ noted a strong correlation between post-operative pain and the severity of the grade of AVN following hip reconstructions in CP. However, quantification of pain and disability in children with CP is a controversial topic and there is a paucity of literature on quality of life related to AVN following hip reconstruction.

We have identified pre-operative risk factors for the development of AVN as higher Reimer's MP, VDRO performed with concomitant adductor tenotomy, and larger operative corrections in MP and NSA, all of which highlight the chronicity and severity of hip displacement. We further witnessed an increased incidence of AVN in children of higher GMFCS levels, which is consistent with existing literature correlating worsening hip dysplasia and prognosis in children with higher GMFCS levels.^{19,41-43}

We had a mixed group of CP subtypes and intentionally did not analyse this as a separate factor. Several studies have shown that GMFCS levels are more correlated to hip displacement than topographic CP subtype. Thus, our results were not likely affected by this variable.⁴⁴

We conclude that the severity of hip displacement correlates directly with the risk of AVN – a theory which is supported by Koch et al.¹¹ We have shown that severity of dislocation, as determined by MP, is the most significant predictor of AVN following hip reconstruction in CP. The same risk factor was identified as being significant by Khalife et al¹⁰ in their group of 89 neuromuscular hips undergoing femoral varus osteotomy. Their group also found older age to be a risk factor, which we did not replicate. Stasikelis et al¹⁸ found that the only risk factor was concomitant pelvic osteotomy in their group of 94 VDROs. Koch et al¹¹ has the highest published incidence of AVN, 68.7%, in a group of GMFCS 4 and 5 children with dislocated hips, all of which underwent open reductions, femoral and pelvic osteotomy. While our cohort had a spectrum of hip displacement, open reduction did not appear to be a risk factor for AVN.

Our findings support proponents of early intervention in the 'hip at risk' group to prevent poor outcome.^{3,4} In fact, our data would suggest that a delay in hip reconstruction beyond a Reimer's MP of 65% is associated with a higher rate of post-operative AVN. Therefore, we recommend in cases of progressive hip displacement that reconstructive procedures be performed within a safe range, namely a Reimer's MP of 40% to 60%, to avoid AVN of the femoral head. We appreciate, however, that the clinical significance of developing AVN and the subsequent impact on the quality of life of patients with CP remains uncertain and warrants further study.

There is significant variability in the reported incidence of AVN of the femoral head after hip reconstructions in CP. While this could be a result of the heterogeneity of studies, it is surely confounded by the lack of a systematic identification process of AVN in these patients. Our incidence of 27% is similar to the higher reported rates in other studies looking at AVN as a primary outcome. We conclude that the severity of hip displacement correlates directly with the risk of AVN and suggest that hip reconstruction, specifically VDRO, be performed early in the 'hip at risk' group to avoid this potentially devastating complication. There is a need for large group prospective data on this subject in order to identify true predictors of AVN and its relationship to quality of life.

Received 9 September 2016; accepted after revision 25 June 2017.

COMPLIANCE WITH ETHICAL STANDARDS

FUNDING STATEMENT

No benefits in any form have been received or will be received from a commercial party related directly or indirectly to the subject of this article.

No funding was received for this study.

OA LICENCE TEXT

This article is distributed under the terms of the Creative Commons Attribution-Non Commercial 4.0 International (CC BY-NC 4.0) licence (<https://creativecommons.org/licenses/by-nc/4.0/>) which permits non-commercial use, reproduction and distribution of the work without further permission provided the original work is attributed.

ETHICAL STATEMENT

Ethical Approval: All procedures performed in studies involving human participants were in accordance with the ethical standards of the institutional and/or national research committee and with the 1964 Helsinki Declaration and its later amendments or comparable ethical standards.

Informed Consent: As a retrospective study, a waiver of informed consent was approved by the institutions ethical review board.

ICMJE CONFLICT OF INTEREST STATEMENT

KM has received research grants from the International Hip Dysplasia Institute, Pega Medical, Depuy (Johnson & Johnson) and Allergan. None are specific to this study. LP, KH, ES, JA and JF declare no conflicts of interest.

REFERENCES

1. **Soo B, Howard JJ, Boyd RN, et al.** Hip displacement in cerebral palsy. *J Bone Joint Surg [Am]* 2006;88-A:121-129.
2. **Connelly A, Flett P, Graham HK, Oates J.** Hip surveillance in Tasmanian children with cerebral palsy. *J Paediatr Child Health* 2009;45:437-443.
3. **Dobson F, Boyd RN, Parrott J, Nattrass GR, Graham HK.** Hip surveillance in children with cerebral palsy. Impact on the surgical management of spastic hip disease. *J Bone Joint Surg [Br]* 2002;84-B:720-726.

4. **Hägglund G, Andersson S, Düppe H, et al.** Prevention of dislocation of the hip in children with cerebral palsy. The first ten years of a population-based prevention programme. *J Bone Joint Surg [Br]* 2005;87-B:95-101.
5. **Hägglund G, Lauge-Pedersen H, Wagner P.** Characteristics of children with hip displacement in cerebral palsy. *BMC Musculoskelet Disord* 2007;8:101.
6. **Canavese F, Gomez H, Kaelin A, Ceroni D, de Coulon G.** Percutaneous pelvic osteotomy and intertrochanteric varus shortening osteotomy in nonambulatory GMFCS level IV and V cerebral palsy patients: preliminary report on 30 operated hips. *J Pediatr Orthop B* 2013;22:1-7.
7. **Miller F, Girardi H, Lipton G, et al.** Reconstruction of the dysplastic spastic hip with peri-iliac pelvic and femoral osteotomy followed by immediate mobilization. *J Pediatr Orthop* 1997;17:592-602.
8. **Robb JE, Brunner R.** A Dega-type osteotomy after closure of the triradiate cartilage in non-walking patients with severe cerebral palsy. *J Bone Joint Surg [Br]* 2006; 88-B:933-937.
9. **Shore BJ, Yu X, Desai S, et al.** Adductor surgery to prevent hip displacement in children with cerebral palsy: the predictive role of the Gross Motor Function Classification System. *J Bone Joint Surg [Am]* 2012;94-A:326-334.
10. **Khalife R, Ghanem I, El Hage S, Dagher F, Kharrat K.** Risk of recurrent dislocation and avascular necrosis after proximal femoral varus osteotomy in children with cerebral palsy. *J Pediatr Orthop B* 2010;19:32-37.
11. **Koch A, Jozwiak M, Idzior M, Molinska-Glura M, Szulc A.** Avascular necrosis as a complication of the treatment of dislocation of the hip in children with cerebral palsy. *Bone Joint J* 2015;97-B:270-276.
12. **Luegmair M, Vuillerot C, Cunin V, Sailhan F, Berard J.** Slotted acetabular augmentation, alone or as part of a combined one-stage approach for treatment of hip dysplasia in adolescents with cerebral palsy: results and complications in 19 hips. *J Pediatr Orthop* 2009;29:784-791.
13. **McNerney NP, Mubarak SJ, Wenger DR.** One-stage correction of the dysplastic hip in cerebral palsy with the San Diego acetabuloplasty: results and complications in 104 hips. *J Pediatr Orthop* 2000;20:93-103.
14. **Noonan KJ, Walker TL, Kayes KJ, Feinberg J.** Varus derotation osteotomy for the treatment of hip subluxation and dislocation in cerebral palsy: statistical analysis in 73 hips. *J Pediatr Orthop B* 2001;10:279-286.
15. **Root L, Laplaza FJ, Brouman SN, Angel DH.** The severely unstable hip in cerebral palsy. Treatment with open reduction, pelvic osteotomy, and femoral osteotomy with shortening. *J Bone Joint Surg [Am]* 1995;77-A:703-712.
16. **Sankar WN, Spiegel DA, Gregg JR, Sennett BJ.** Long-term follow-up after one-stage reconstruction of dislocated hips in patients with cerebral palsy. *J Pediatr Orthop* 2006;26:1-7.
17. **Stasikelis PJ, Lee DD, Sullivan CM.** Complications of osteotomies in severe cerebral palsy. *J Pediatr Orthop* 1999;19:207-210.
18. **Stasikelis PJ, Ridgeway SR, Pugh LI, Allen BL Jr.** Epiphyseal changes after proximal femoral osteotomy. *J Pediatr Orthop B* 2001;10:25-29.
19. **Lonstein JE, Beck K.** Hip dislocation and subluxation in cerebral palsy. *J Pediatr Orthop* 1986;6:521-526.
20. **Song HR, Carroll NC.** Femoral varus derotation osteotomy with or without acetabuloplasty for unstable hips in cerebral palsy. *J Pediatr Orthop* 1998;18:62-68.
21. **Roposch A, Wedge JH, Riedl G.** Reliability of Bucholz and Ogden classification for osteonecrosis secondary to developmental dysplasia of the hip. *Clin Orthop Relat Res* 2012;470:3499-3505.
22. **Hesketh K, Sankar W, Joseph B, Narayanan U, Mulpuri K.** Inter-observer and intra-observer reliability in the radiographic diagnosis of avascular necrosis of the femoral head following reconstructive hip surgery in children with cerebral palsy. *J Child Orthop* 2016;10:143-147.
23. **Reimers J.** The stability of the hip in children. A radiological study of the results of muscle surgery in cerebral palsy. *Acta Orthop Scand Suppl* 1980;184:1-100.
24. **Sharp IK.** Acetabular dysplasia: The Acetabular Angle. *J Bone Joint Surg [Br]* 1961;43-B:268-272.
25. **Hilgenreiner H.** Early diagnosis and early treatment of congenital dislocation of the hip. *Med Klin* 1925;21:1385-1388.
26. **Foroohar A, McCarthy JJ, Yucha D, Clarke S, Brey J.** Head-shaft angle measurement in children with cerebral palsy. *J Pediatr Orthop* 2009;29:248-250.
27. **Kruczynski J.** Avascular necrosis of the proximal femur in developmental dislocation of the hip. Incidence, risk factors, sequelae and MR imaging for diagnosis and prognosis. *Acta Orthop Scand Suppl* 1996;268:1-48.
28. **Al-Ghadir M, Masquijo JJ, Guerra LA, Willis B.** Combined femoral and pelvic osteotomies versus femoral osteotomy alone in the treatment of hip dysplasia in children with cerebral palsy. *J Pediatr Orthop* 2009;29:779-783.
29. **Huh K, Rethlefsen SA, Wren TA, Kay RM.** Surgical management of hip subluxation and dislocation in children with cerebral palsy: isolated VDRO or combined surgery? *J Pediatr Orthop* 2011;31:858-863.
30. **Mubarak SJ, Valencia FG, Wenger DR.** One-stage correction of the spastic dislocated hip. Use of pericapsular acetabuloplasty to improve coverage. *J Bone Joint Surg [Am]* 1992;74-A:1347-1357.
31. **Hesketh K, Leveille L, Mulpuri K.** The frequency of AVN following reconstructive hip surgery in children with cerebral palsy: a systematic review. *J Pediatr Orthop* 2016;36:e17-e24.
32. **Bucholz RW, Ogden JA.** Patterns of ischemic necrosis of the proximal femur in nonoperatively treated congenital hip disease. *The Hip: Proceedings of the Sixth Open Scientific Meeting of the Hip Society*. St. Louis, MO: CV Mosby Co;1978:43-63.
33. **Kalamchi A, MacEwen GD.** Avascular necrosis following treatment of congenital dislocation of the hip. *J Bone Joint Surg [Am]* 1980;62-A:876-888.
34. **Moya-Angeler J, Gianakos AL, Villa JC, Ni A, Lane JM.** Current concepts on osteonecrosis of the femoral head. *World J Orthop* 2015;6:590-601.
35. **Luedtke LM, Flynn JM, Pill, SG.** A review of avascular necrosis in developmental dysplasia of the hip and contemporary efforts at prevention. *U Penn Orthop J* 2000;13:22-28.
36. **Motomura G, Yamamoto T, Yamaguchi R, et al.** Morphological analysis of collapsed regions in osteonecrosis of the femoral head. *J Bone Joint Surg [Br]* 2011;93-B:184-187.
37. **Salter RB, Kostuik J, Dallas S.** Avascular necrosis of the femoral head as a complication of treatment for congenital dislocation of the hip in young children: a clinical and experimental investigation. *Can J Surg* 1969;12:44-61.

38. **Brougham DI, Broughton NS, Cole WG, Menelaus MB.** Avascular necrosis following closed reduction of congenital dislocation of the hip. Review of influencing factors and long-term follow-up. *J Bone Joint Surg [Br]* 1990;72-B:557-562.
39. **Ryan MG, Johnson LO, Quanbeck DS, Minkowitz B.** One-stage treatment of congenital dislocation of the hip in children three to ten years old. Functional and radiographic results. *J Bone Joint Surg [Am]* 1998;80-A:336-344.
40. **Thomas IH, Dunin AJ, Cole WG, Menelaus MB.** Avascular necrosis after open reduction for congenital dislocation of the hip: analysis of causative factors and natural history. *J Pediatr Orthop* 1989;9:525-531.
41. **Bleck EE.** The hip in cerebral palsy. *Orthop Clin North Am* 1980;11:79-104.
42. **Carr C, Gage JR.** The fate of the nonoperated hip in cerebral palsy. *J Pediatr Orthop* 1987;7:262-267.
43. **McCarthy RE, Simon S, Douglas B, Zawacki R, Reese N.** Proximal femoral resection to allow adults who have severe cerebral palsy to sit. *J Bone Joint Surg [Am]* 1988;70-A:1011-1016.
44. **Hägglund G, Lauge-Pedersen H, Wagner P.** Characteristics of children with hip displacement in cerebral palsy. *BMC Musculoskelet Disord* 2007;8:101-106.