



INTERNAL DRAINAGE OF SUBRETINAL FLUID DURING CHANDELIER-ASSISTED SCLERAL BUCKLING

Emmanuel Ankamah, OD,*† Martin J. Siemerink, MD,‡ Philip J. Polkinghorne, MD,‡ John M. Nolan, PhD,† Eugene Ng, MD*†

Purpose: To describe the surgical technique of internal drainage of subretinal fluid as an adjunct to chandelier-assisted scleral buckling for the repair of rhegmatogenous retinal detachment.

Methods: The technique of internal drainage with a sharp needle or cannula through a trocar is described and shown in a Supplemental Digital Content 1 (see Video, <http://links.lww.com/ICB/A87>).

Results: Three patients (3 eyes) underwent scleral buckling for rhegmatogenous retinal detachment repair. Subretinal fluid was drained using the internal drainage approach in all cases. All three patients had successful reattachment of retina with improvement in visual function. No complications were reported related to vitreous loss, retinal incarceration, or redetachment following primary surgery.

Conclusion: Internal drainage of subretinal fluid during chandelier-assisted scleral buckling is a useful technique that can be considered for repairing rhegmatogenous retinal detachment.

RETINAL CASES & BRIEF REPORTS 16:77–80, 2022

*From the *Institute of Eye Surgery, UPMC Whitfield, Butlerstown Co, Waterford, Ireland; †Nutrition Research Centre Ireland, School of Health Science, Waterford Institute of Technology, West Campus, Carriganore House, Waterford, Ireland; and ‡Department of Ophthalmology, University of Auckland, Auckland, New Zealand.*

Despite the advent of vitrectomy and advances of surgical instrumentation, scleral buckling remains a successful technique to manage rhegmatogenous retinal detachment. The characteristics of

retinal detachments most suited for scleral buckling differ from that of vitrectomy. Young (phakic) patients with detachments from inferior breaks without posterior vitreous detachment and dialysis detachments are the most compelling cases to treat with a buckle. Unlike vitrectomy, scleral buckling does not interfere with a patient's lens and vitreous detachment status. A vitrectomy set up is also associated with a higher cost because it includes a vitrector and associated infusion lines connected to a vitrectomy machine's cassette.¹

Scleral buckling surgery aims to reestablish anatomical adhesion of the neurosensory retina to the retinal pigment epithelium by indenting the sclera at the site of the primary break, through accurate placement of a silicon or sponge explant. This reduces the ocular circumference, reducing traction and preventing further subretinal fluid (SRF) accumulation. Using chandelier endoillumination and a wide-angle visualization system during the procedure improves visualization of the peripheral retina during training, localization of retinal tears, and positioning of the scleral buckle, thereby possibly reducing the rate of retinal redetachment.²

None of the authors has any financial/conflicting interests to disclose.

Supplemental digital content is available for this article. Direct URL citations appear in the printed text and are provided in the HTML and PDF versions of this article on the journal's Web site (www.retinajournal.com).

This is an open-access article distributed under the terms of the Creative Commons Attribution-Non Commercial License 4.0 (CCBY-NC), where it is permissible to download, share, remix, transform, and buildup the work provided it is properly cited. The work cannot be used commercially without permission from the journal.

Reprint requests: Eugene Ng, MD, Institute of Eye Surgery, UPMC Whitfield, Butlerstown Co, Waterford, X91 DH9W, Ireland; e-mail: eugene@ioes.ie

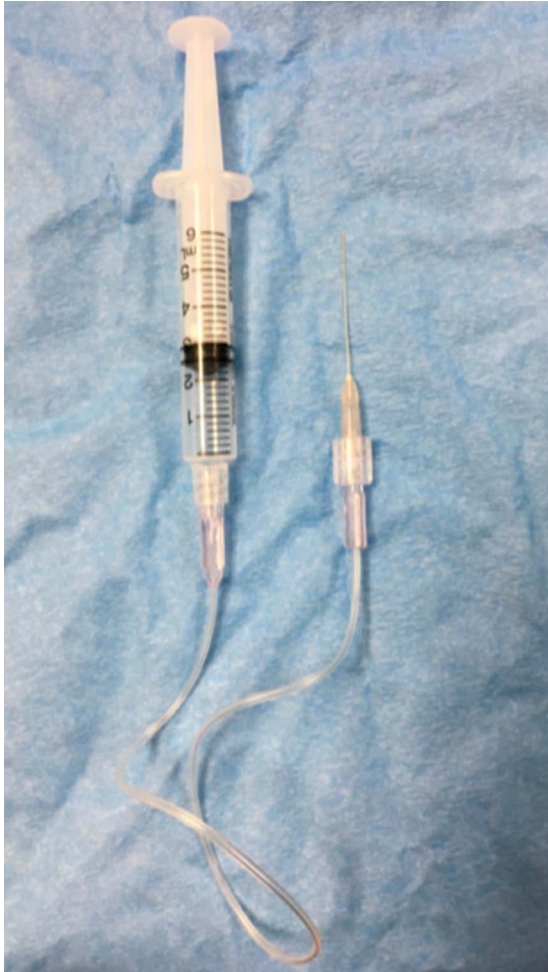

Fig. 1. Aspiration cannula, line, and syringe setup.

have merit both in terms of ensuring anatomical and functional success. Theoretically, internal retinal drainage of SRF should reduce these complications. We report a technique of internal drainage of SRF during chandelier-assisted scleral buckling surgery.

Surgical Technique

The technique described can be performed as part of buckling surgery in patients with rhegmatogenous retinal detachment caused by retinal dialysis and retinal holes. Chandelier-assisted scleral buckling was performed as previously described.³ A valved trocar (Alcon, Fort Worth, TX), positioned three-clock hours from the primary tear, was inserted through the pars plana. A 25-gauge aspiration cannula (Sterimedix, Worcestershire, United Kingdom) attached to an extension line (lectrocath, Vygon, France) was flushed with 3 mL of balanced salt solution (BSS) with an attached 5.0-mL syringe (Figure 1). Alternatively, instead of a cannula and trocar, a 25-gauge needle with the line and syringe setup can be directly inserted through the pars plana to drain SRF from a retinal dialysis when localization of the SRF is easy and repeated aspiration is not necessary.

In cases of retinal dialysis, the needle/cannula was directed anterior to the dialysis edge. In cases of atrophic holes, the cannula was initially directed toward the optic nerve, through the posterior hyaloid face then swept anteriorly toward the retinal break. The tip of the aspiration cannula was then advanced into the subretinal space through the retinal break. These maneuvers minimized the risk of aspirating vitreous. Care is required when attempting to release inadvertently aspirated vitreous via injection of BSS because unless significant amount of SRF has already been aspirated, a small amount of BSS can result in significant increase in intraocular pressure. When a large volume of SRF had been aspirated, a further injection of fresh BSS was used to fill the vitreous cavity. This ensured that a large

External transscleral drainage of SRF as part of scleral buckling surgery improves surgical success. However, this maneuver can be complicated by hypotony, retinal perforation and incarceration, vitreous loss, and subretinal hemorrhage. Subretinal fluid can extend to lie under the macula in macular-off retinal detachments and limit visual recovery. A technique to reduce these risks would

Table 1. Clinical Characteristics of Patients Who Underwent Chandelier-Assisted Internal Drainage Scleral Buckling

Case No.	Age, year	Sex	PVD Status	Degree of Myopia (SER)	RDMorphology	Snellen Visual Acuity		Follow-up (Months)	Complications
						Preoperation	Postoperation		
1	46	Female	Attached	High (-7.50 D)	Chronic macula on RD; two inferior atrophic holes	6/9	6/7.5	20	None
2	26	Male	Attached	Low (-1.00 D)	Acute macula off RD; infratemporal retinal dialysis	6/36	6/7.5	9	None
3	32	Male	Attached	Low (-1.50 D)	Macula off RD; inferior retinal round hole	6/36	6/18	6	None

D, diopters; PVD, posterior vitreous detachment status at optic disk as determined by preoperative optical coherence tomography; RD, retinal detachment; SER, spherical equivalent refraction.

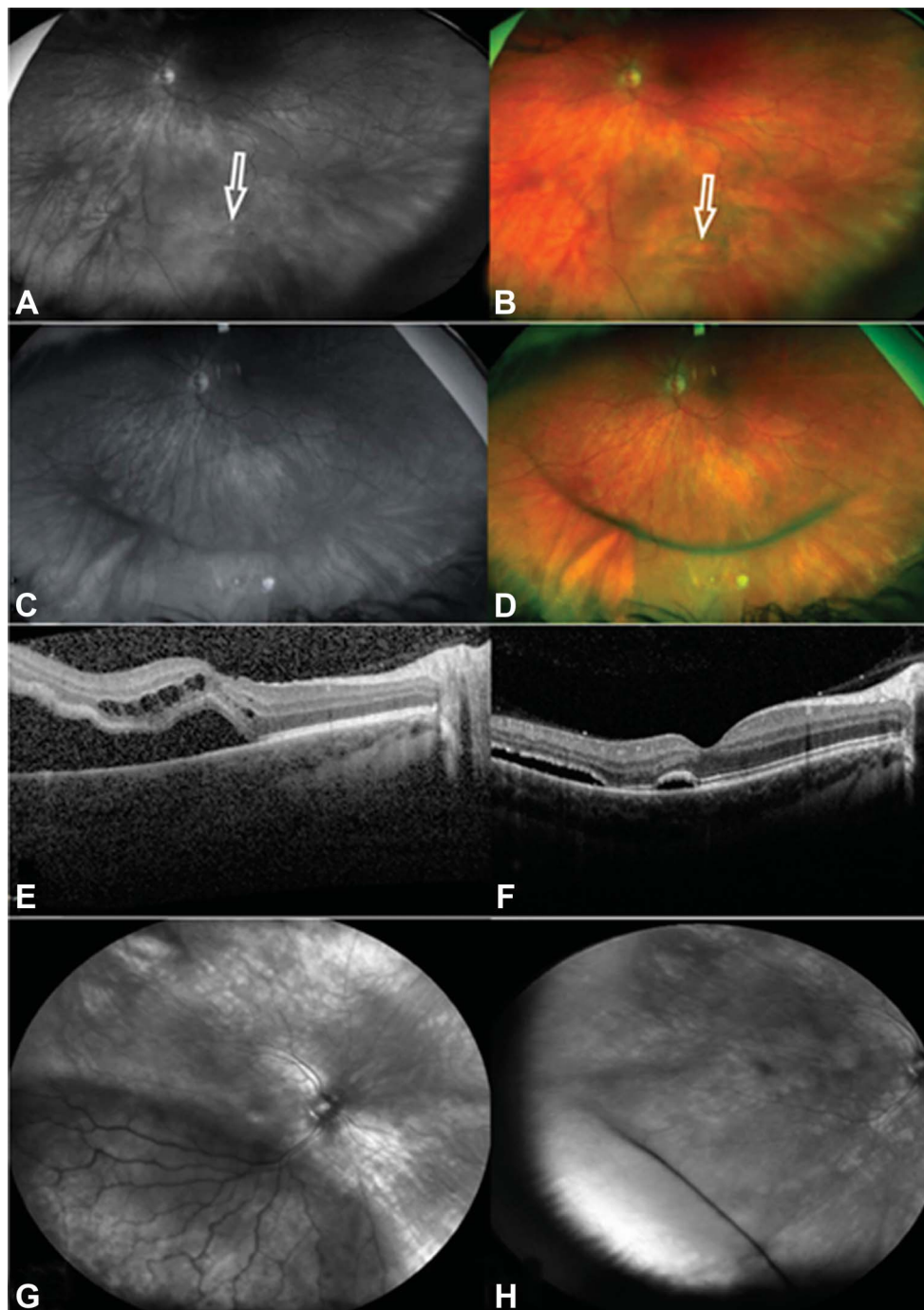


Fig. 2. A and B. Ultra-wide-field images (A: red reflectance; B: pseudo color) showing chronic macula on retinal detachment with inferior atrophic holes (white arrow). C and D. One-hour postoperative images illustrating successful reattachment of peripheral inferior retina (C: red reflectance; D: pseudo color). E. Presurgery macula optical coherence tomography image illustrating fovea off status. F. Week 1 optical coherence tomography image demonstrating typical macular configuration following retinal reattachment surgery. G. Wide-field image of retinal detachment cause by dialysis. H. Postoperative wide-field image depicting reattached retina.

amount of retinal pigment epithelial cells and subretinal debris were not reintroduced into the vitreous cavity.

Results

We have performed this technique in 3 patients (3 eyes), who were younger than 50 years, myopic, and had clear crystalline lenses: one had retinal dialysis,

and the other two had inferior round retinal holes. Successful anatomical reattachment and postoperative visual function improvement were achieved in all patients following primary surgery (Table 1 and Figure 2). There was no subretinal or vitreous hemorrhage related to the internal draining technique. No new peri- or postoperative retinal tears, choroidal detachments, vitreoretinal incarceration, or endophthalmitis occurred.

Discussion

Scleral buckling remains a common procedure for the repair of primary rhegmatogenous retinal detachment, especially among young phakic patients. According to Hilton,⁴ drainage of SRF as part of a buckling procedure for rhegmatogenous retinal detachment repair does not yield significant success over a buckling procedure without drainage of SRF. Notwithstanding this, the 2017 Preference and Trends Survey of the American Society of Retina Specialists has indicated that 55% of vitreoretinal surgeons globally perform external sub-retinal drainage for more than 50% of all primary scleral buckle procedures.⁵

All variations of external drainage technique (suture needle, argon laser, modified needle, Charles technique, or Schepens drainage)^{6,7} involve penetration of the highly vascular choroid and the inability to fully control the rate of and ultimately stop SRF drainage. Conversely, internal drainage of SRF does not involve penetration of the choroid, remains under active control of the surgeon, and can be stopped instantaneously when required. Given the increasing adoption of vitrectomy for retinal detachments, internal drainage is an intuitive procedure that surgeons are already comfortable performing, and with the advent of chandelier illumination for scleral buckling, internal drainage can also be used for scleral buckling. In fact, one may argue that internal drainage is a compelling alternative to surgeons or fellows with limited experience in the technique of external drainage.

Our “syringe and line” setup allows accidental aspiration of vitreous to be released. It also allows the aspiration cannula to be isolated from the force applied to the aspirating syringe, therefore allowing very accurate, prolonged placement. Repeated SRF drainage can be performed using a valved trocar set up to avoid multiple entry sites. A vitrectomy machine setup to control aspiration with the foot pedal allows the other hand to be available for indentation of far peripheral breaks or frees up a scrub assistant but is associated with increased surgical cost. With this technique, cryopexy was performed before SRF drainage. Traditionally, cryopexy theoretically increases the risk of subretinal hemorrhage, but when internal drainage is used, this technique allows for the removal of lysed retinal pigment epithelium cells.⁸ It is worth mentioning that this technique shares some similarities with transvitreal fine needle aspiration biopsy, where a sharp needle is pushed through formed vitreous to biopsy a tumor.⁹

Another advantage of internal drainage is the ability to control intraocular pressure with gas or BSS through the valved trocar without the need for multiple injections. This is particularly helpful to titrate buckle height, improve the ease of suturing or tightening the buckle after cryopexy, and prevent hypotony (with its related consequences).

A potential risk to this technique is the risk of lens touch, but this risk is no higher than that of a standard vitrectomy in a phakic eye. Another disadvantage is the cost of the valved trocar, unless a needle approach of this technique is used. Although there is a theoretical risk of iatrogenic retinal tears with the insertion of instruments through formed vitreous, this risk has not been borne out in large series of 25-gauge injection of intravitreal dexamethasone for diabetic retinopathy where the vitreous is also frequently nonsyncretic.¹⁰

In conclusion, internal drainage of SRF may be considered as an alternative to external drainage for chandelier-illuminated scleral buckling procedures to minimize complications associated with SRF drainage. The efficacy of this technique will be assessed in a larger future study.

Key words: internal drainage, chandelier-assisted, chandelier illumination, scleral buckling.

References

1. Falkner-Radler CI, Myung JS, Moussa S, et al. Trends in primary retinal detachment surgery: results of a biocenter study. *Retina* 2011;31:928–936.
2. Seider MI, Nomides RE, Hahn P, et al. Scleral buckling with chandelier illumination. *J Ophthalmic Vis Res* 2016;11:304.
3. Nam KY, Kim WJ, Jo YJ and Kim JY. Scleral buckling technique using a 25-gauge chandelier endoilluminator. *Retina* 2013;33:880–882.
4. Hilton GF. The drainage of subretinal fluid: a randomized controlled clinical trial, *Trans Am Ophthalmol Soc* 1981;79:517–540.
5. ShahGK, StoneTW, eds. 2017 Preferences and Trends (PAT) Survey. Chicago, IL: American Society of Retina Specialists.
6. Aylward GW, Orr G, Schwartz SD, and Leaver PK. Prospective randomized, controlled trial comparing suture needle drainage and argon laser drainage of subretinal fluid. *B J Ophthalmol* 1995;79:724–727.
7. Charles ST. Controlled drainage of subretinal and choroidal fluid. *Retina* 1985;5:233–234.
8. Aaberg TM, Pawlowski GJ. Exudative retinal detachments following scleral buckling with cryotherapy, *Am J Ophthalmol* 1972;74:245–251.
9. Cohen VML, Dinakaran S, Parsons MA, and Rennie IG. Transvitreal fine needle aspiration biopsy: the influence of intraocular lesion size on diagnostic biopsy result, *Eye* 2001;15:143.
10. Mello Filho P, Andrade G, Maia A, et al. Effectiveness and safety of intravitreal dexamethasone implant (Ozurdex) in patients with diabetic macular edema: a real-world experience, *Ophthalmologica* 2019;241:9–16.