



Delayed intestinal perforation secondary to blunt force abdominal trauma in a cat

A Taylor¹ , E Cooper² and K Ham³

Journal of Feline Medicine and Surgery Open Reports
1–5

© The Author(s) 2018

Reprints and permissions:

sagepub.co.uk/journalsPermissions.nav

DOI: 10.1177/2055116918763410

journals.sagepub.com/home/jfmsopenreports

This paper was handled and processed by the American Editorial Office (AAFP) for publication in *JFMS Open Reports*



Abstract

Case summary A 7-month-old intact male domestic shorthair cat was presented 4 h after being hit by a car. It had bilateral inguinal hernias and a mesenteric rent that were repaired surgically and a hematoma in the left retroperitoneal space. No other intra-abdominal abnormalities were identified on abdominal surgical exploration. Approximately 72 h after presentation, the cat started vomiting and developed severe abdominal discomfort. A sudden decrease in mentation and elevation of respiratory rate and effort ensued. Abdominal radiographs showed loss of detail in the abdominal cavity, and abdominocentesis confirmed septic peritonitis. The cat was euthanized, and post-mortem evaluation of the bowel revealed two 1 cm perforations of the jejunum.

Relevance and novel information To our knowledge, delayed intestinal perforation secondary to blunt force abdominal trauma has not previously been reported in cats. It has been reported in dogs, but the pathophysiology resulting in perforation is poorly understood. Delayed intestinal injury secondary to blunt force abdominal trauma has been reported in people, especially in children, as a result of motor vehicle accidents.

Accepted: 25 January 2018

Introduction

Blunt force trauma in small animals is commonly due to motor vehicle accidents.¹ To our knowledge, there are no reports describing motor vehicle injuries in cats alone. In a study describing motor vehicle injuries in both dogs and cats, the only abdominal injury reported was diaphragmatic hernia, noted in 4% of the cases.² The only other consistently reported cause of accidental blunt trauma in cats is high-rise syndrome, with the most commonly reported abdominal injuries in a recent study noted to be diaphragmatic rupture (0.02%), abdominal wall rupture (0.02%) and urinary bladder rupture (0.01%).³ Similar to reports in human medicine where intestinal injury is rarely reported as a result of blunt trauma,⁴ there were no reports of intestinal injury in either of these studies.^{2,3}

Intestinal and mesenteric injury secondary to blunt trauma in humans only comprises approximately 3–5% of all abdominal injuries.^{4,5} Delayed jejunal perforation is a known sequela to blunt trauma, with ischemia, stricture and increased intraluminal pressure described as possible mechanisms.⁶ Intestinal perforation following blunt trauma has been reported infrequently in dogs,^{7,8}

and has not previously been reported in cats. The purpose of this report is to describe the clinical features, treatment and outcome of a cat that developed two jejunal perforations and septic peritonitis approximately 72 h following blunt trauma.

Case description

A previously healthy 7-month-old intact male domestic shorthair cat was evaluated 4 h after being hit by a car. It weighed 3.64 kg, presented laterally recumbent with pale

¹Cummings School of Veterinary Medicine at Tufts University, North Grafton, MA, USA

²Department of Emergency and Critical Care, The Ohio State University, Columbus, OH, USA

³Department of Veterinary Clinical Sciences – Small Animal Surgery, The Ohio State University, Columbus, OH, USA

Corresponding author:

A Taylor DVM, Cummings School of Veterinary Medicine at Tufts University, 200 Westborough Road, North Grafton, MA 01536, USA

Email: drew.q.taylor@gmail.com



Creative Commons Non Commercial CC BY-NC: This article is distributed under the terms of the Creative Commons

Attribution-NonCommercial 4.0 License (<http://www.creativecommons.org/licenses/by-nc/4.0/>) which permits non-commercial use, reproduction and distribution of the work without further permission provided the original work is attributed as specified on the SAGE and Open Access pages (<https://us.sagepub.com/en-us/nam/open-access-at-sage>).

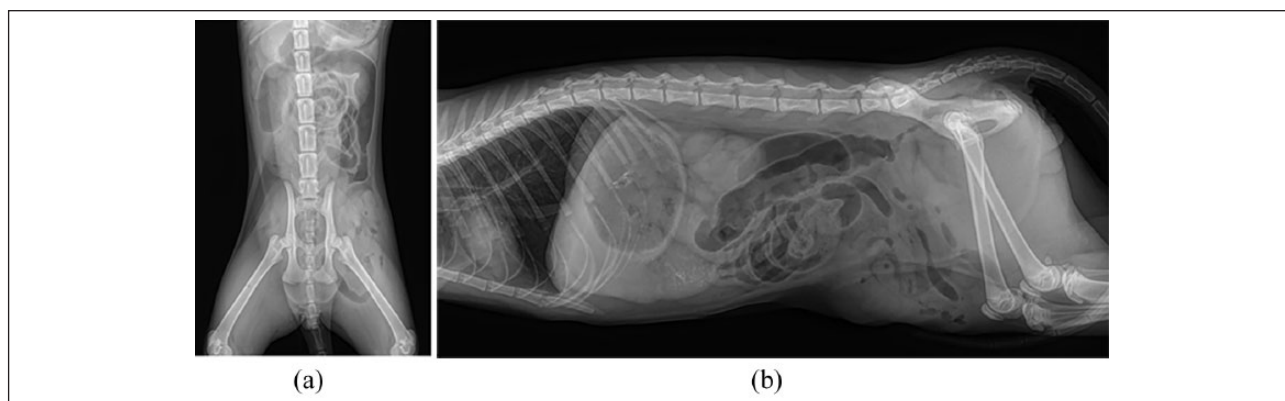


Figure 1 (a) Ventrodorsal radiograph obtained at the time of presentation showing inguinal herniation of the small intestines. (b) Right lateral radiograph obtained at the time of presentation showing inguinal herniation of the small intestines

mucous membranes, was hypothermic (35.0°C [95.0°F]) and mildly bradycardic (150 beats per min). Respiratory rate and effort were within normal limits. Several loops of bowel were palpated along the proximal medial aspect of the left pelvic limb. The skin was intact, but mild bruising was evident on the caudal abdomen. Several superficial abrasions were noted along the distal pelvic limbs.

The cat received a 13.7 ml/kg crystalloid fluid bolus (Lactated Ringer's Solution [LRS]; Abbott Laboratories) over 30 mins, buprenorphine (0.24 mg/kg SC [Simbadol; Zoetis]), and thermal support was provided via forced air warmer (Bair Hugger; 3M). Its temperature rose to 36.9°C (98.4°F) over the next 3 h and it became more responsive. Femoral pulses were moderate in quality and mucous membrane color was pale pink. A blood pressure was not obtained.

Following initial stabilization, a complete blood count (CBC), biochemical profile and chest and abdominal radiographs were performed. Abdominal radiographs showed appropriate serosal detail with several gas-filled loops of bowel outside the abdominal cavity and tracking along the left medial thigh (Figure 1a,b). The stomach was dilated with gas and contained a small amount of mineral opaque material. The thoracic cavity was unremarkable. No evidence of appendicular or axial fractures was detected. The radiographs were supportive of a diagnosis of inguinal herniation.

Following resuscitation, the hematocrit was 36.5% (reference interval [RI] 30.3–52.3%). Abnormalities included a mild neutrophilic leukocytosis with a left shift (white blood cell count $26.39 \times 10^9/l$ [$26,390/\mu l$]; RI 2.87–17.02 $\times 10^9/l$ [$2870-17,020/\mu l$]), neutrophilia ($14.41 \times 10^9/l$ [$14,410/\mu l$]; RI 1.48–10.29 $\times 10^9/l$ [$1480-10,290/\mu l$]) and lymphocytosis ($11.3 \times 10^9/l$ [$11,300/\mu l$]; RI 0.92–6.88 $\times 10^9/l$ [$920-6880/\mu l$]). Clinically relevant findings on serum biochemistry included an increased blood urea nitrogen (19.99 mmol/l [56 mg/dl]; RI 3.57–10.71 mmol/l [$10-30 \text{ mg/dl}$]), a normal creatinine (106.08 mmol/l [1.2 mg/dl]; RI 26.52–185.64 mmol/l

[0.3–2.1 mg/dl]), an increased alanine aminotransferase (ALT; 1440 U/l [$24.05 \mu\text{kat/l}$]; RI 20–100 U/l [$0.33-1.67 \mu\text{kat/l}$]) and a normal blood glucose (109 mg/dl [6.05 mmol/l]; RI 70–150 mg/dl [$3.9-8.32 \text{ mmol/l}$]).

The cat received LRS 3 ml/kg/h and ampicillin-sulbactam (30 mg/kg IV q8h [Unasyn; Pfizer]). The cat was able to maintain a sternal body position and was mentally appropriate. Its pulse quality and mucous membrane color remained moderate and pale pink. An abdominal exploratory celiotomy was performed the following morning.

The cat was induced with propofol (7 mg/kg IV [Propoflo; Abbott Laboratories]) and anesthesia was maintained with sevoflurane in oxygen (SevoFlo; Abbott Laboratories). The abdomen was aseptically prepared, and a 12 cm ventral midline incision was made extending from 2 cm cranial to the umbilicus caudally to the pubis. A full abdominal exploratory was performed. The urinary bladder was intact but deviated caudally and was entrapped in a left inguinal hernia. The left inguinal hernia measured approximately 3 cm and also contained approximately one-third of the mid-jejunum and a small portion of the colon. The bowel was examined closely, and no evidence of perforation or ischemic injury was evident at time of surgery. The intestines were normal in color, had strong mesenteric pulses and exhibited normal peristalsis. A mesenteric hematoma was evident adjacent to a 4 cm rent in the mesentery, and the crura of the superficial inguinal ring and aponeurosis of the external abdominal oblique muscle were entirely avulsed from the pubis. Hemorrhage was evident along the left retroperitoneal space. Otherwise, the abdominal contents were within normal limits.

The mesenteric rent and medial crus of the left inguinal hernia were closed in simple continuous pattern with 3-0 polydioxanone suture (PDS; Ethicon). The right inguinal musculature had entirely avulsed from its bony insertion, so the detached rectus abdominus muscle was sutured to fragments of remaining pubic periosteum using 3-0 PDS in a simple continuous pattern.⁹ The intestines were

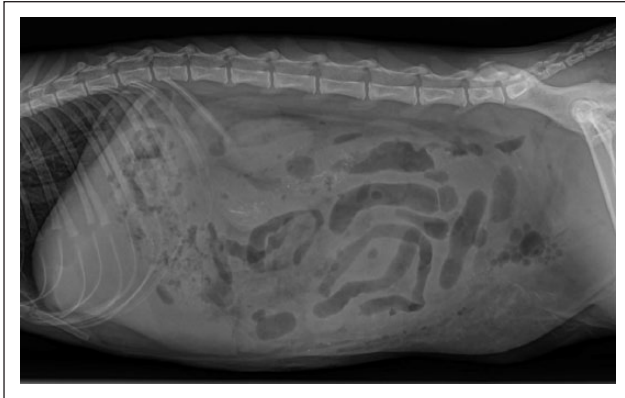


Figure 2 Abdominal radiograph showing a loss of abdominal detail and small round gas opacities suggestive of intestinal perforation and septic peritonitis

lavigated with sterile saline (0.9% NaCl Solution; Abbott Laboratories) and the abdominal cavity was dried using laparotomy sponges before routine closure using 3-0 polydioxanone suture in a simple continuous pattern to close the linea and 3-0 poliglecaprone suture in a buried intradermal pattern to close the skin (Monocryl; Ethicon).

Blood pressure trends were obtained with an oscillometric measurement device (SurgiVet; Smiths Medical) with an intraoperative reported mean arterial pressure range of 35–55 mmHg. Intraoperative intravenous fluid support included an initial LRS rate of 8.5 ml/kg/h with subsequent hydroxyethyl starch boluses totaling 5 ml/kg (Hetastarch 6% in 0.9% NaCl; Hospira) provided in response to decreasing blood pressure trends. Heart rate ranged from 125 - 150 beats per min (bpm), but temperature fell from 39.1°C (102.4°F) preoperatively to 34.1°C (93.4°F) immediately postoperatively, even though thermal support via a forced air warmer had been provided throughout. Recovery from anesthesia was uneventful and normothermia was achieved with additional external thermal support. The cat had a body temperature of 39.5°C (103.2°F), heart rate of 160 bpm and a respiratory rate of 24 breaths per min 8 h after surgery.

Postoperatively, the cat received LRS at 3 ml/kg/h, buprenorphine (0.24 mg/kg SC q12h) and ampicillin-sulbactam (30mg/kg IV q8h), and continued to recover well. Intravenous fluids were continued until the cat began eating and drinking approximately 8 h postoperatively. It began self-grooming 12 h after surgery. The following morning, it was ambulatory in the cage and was bright and alert, purring and interacting comfortably when held and manipulated. Its mucous membranes were pink and its femoral pulses were strong and synchronous. Body temperature was 39.3°C (102.7°F), the abdominal incision was clean and dry and abdominal palpation was non-painful.

Approximately 48 h postoperatively (72 h after initial injury), the cat's respiratory rate and effort increased suddenly. It became less responsive to normal stimuli and

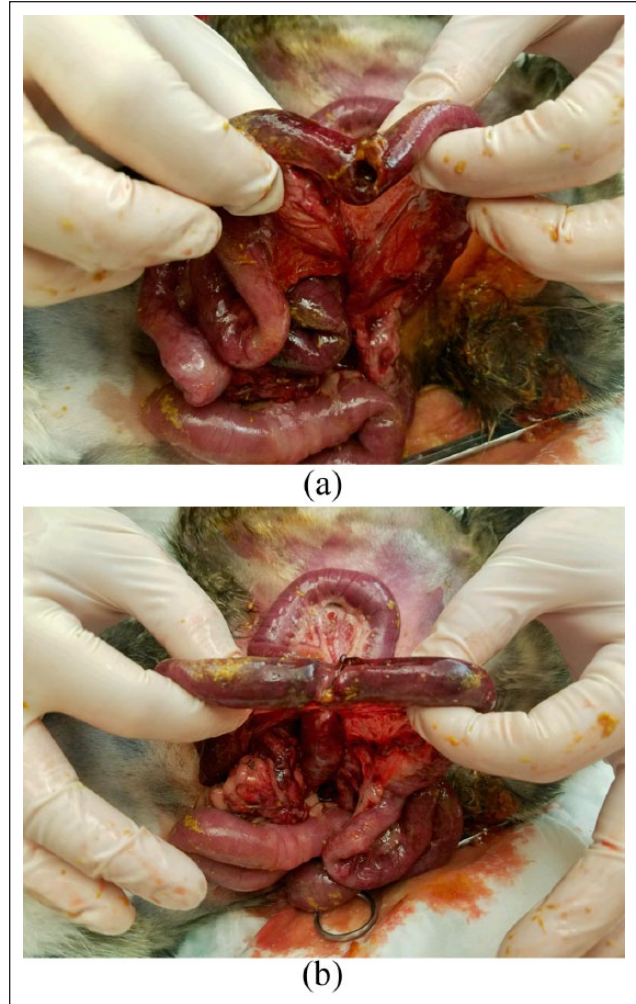


Figure 3 (a) Post-mortem image from autopsy showing perforation one of two in the jejunum. (b) Post-mortem image from autopsy showing perforation two of two in the jejunum

showed pain on abdominal palpation. A CBC and biochemical profile were unremarkable aside from an elevation in ALT (252 U/l; RI 20–100 U/l), though this had decreased significantly from presentation. A lateral abdominal radiograph showed loss of abdominal detail and evidence of free gas (Figure 2). Abdominal ultrasound showed a moderate amount of fluid in the abdomen. Blind abdominocentesis yielded a yellow–green-colored turbid fluid that contained grossly visible debris. Fluid cytology was supportive of acute bowel perforation with myriad polymorphic bacteria admixed with plant fragments and amorphous basophilic granular material.

Owing to the cat's rapid clinical deterioration, the decision was made to euthanize. Immediately following euthanasia with 3 ml euthanasia solution (Euthanasia Solution; VetOne) intravenously, an abdominally focused post-mortem examination was performed and revealed two 1 cm perforations in the anti-mesenteric wall of the mid-jejunum (Figure 3a,b). The intestine, approximately 3 cm oral and aboral of both perforations, was deep

purple in color, but the rest of the bowel was pink with the serosa being slightly hyperemic and fibrin coated in response to peritonitis. There was no obvious evidence of mesenteric thrombosis, and the mesenteric tissue was pink in color. The hernia repair sites were still intact. Full necropsy and histopathology were not performed.

Discussion

The cat in this report suffered inguinal herniation with no evidence of intestinal pathology at the time of initial abdominal exploration and was reported to be healthy prior to the trauma. The cat improved clinically after surgery with normal mentation, vitals and appetite but declined and was diagnosed with septic peritonitis 48 h postoperatively. On necropsy, two distinct intestinal perforations were identified. We postulate that the perforations were a direct result of the blunt trauma and that compressive and shearing forces were likely responsible for the injury.

Trauma sustained to internal organs during blunt force is the result of compression and deceleration forces and stress waves.^{5,10} The compressive forces are often the result of low-speed, high-momentum impacts that produce a displacement of the body wall.¹⁰ In the case of motor vehicle injury, compressive forces occur as the vehicle strikes the patient, the patient strikes the ground and as organs strike the internal body wall in a coup and countercoup fashion. Deceleration forces cause both shearing and stretching of the organs within the abdominal cavity,⁵ whereas stress waves cause small, rapid movement between tissue layers, and subsequent compression and re-expansion of gas within the intestinal lumen.¹⁰

Mesenteric vascular injuries are thought to be the result of compressive or deceleration forces and cause ischemia of corresponding bowel segments.^{11,12} Ischemia and subsequent necrosis of the intestinal wall leads to perforation and septic peritonitis. An increase in intraluminal pressure can result in punctate perforations on the anti-mesenteric border of the intestines.^{4,13} Intestinal hematomas from direct contact with the internal body wall or shearing forces of small vessels are the result of an accumulation of blood in the submucosal layer and can cause wall thickening and pressure necrosis leading to delayed perforations or strictures.^{10,11,13} These mechanisms were most likely responsible for the injuries sustained as the intestinal tract collided internally with the body wall and was stretched resulting in delayed ischemic injury.

Consequences of blunt abdominal trauma are well reported in human literature with a fairly low incidence of intestinal injury, and the frequency of intestinal perforation even lower (0.25%).^{4,5,11,13,14} Interestingly, blunt trauma accounts for 80–90% of all abdominal injuries in pediatric patients because of their immature abdominal wall structure and underdeveloped fat layers.¹⁵ Despite this prevalence, bowel injury remains rare (0.6%).¹⁶

Traumatic injury, even in pediatric patients, rarely affects the gastrointestinal tract owing to its central location and extreme mobility within the abdominal cavity.^{10,15} When intestinal injuries do occur, they are most commonly associated with the jejunum and ileum,^{4,14,15,17} and are typically seromuscular tears, mesenteric hematomas and ischemic events, intestinal wall perforations and late post-traumatic stricture.^{4,18}

The effect of blunt trauma on intestinal wall integrity is not well reported in cats and dogs. In a study from 1963 in which blunt trauma was intentionally inflicted on dogs in an experimental setting, shearing forces were reported to be the most significant cause of intestinal injury, and the ileum and jejunum were the most affected areas of bowel.¹⁹ More recently, this has been studied experimentally in rabbits where the intestinal tract was directly subjected to blunt force trauma and ischemic insult. Following 55 separate insults, only two incidents of perforation were reported.²⁰ In a study focused on severe blunt trauma in dogs, there were no reports of intestinal perforation, even though approximately 70% of cases presented with abdominal trauma. The most common injuries reported were hemoperitoneum (23%), abdominal hernia (5%) and urinary tract rupture (3%).²¹ Given the limited reports of blunt abdominal trauma in cats, it is unknown whether the incidence of intestinal injury is as rare as reported in other species.

Although the cat's delayed intestinal perforations were suspected to have been the direct result of blunt trauma, other etiologies such as thromboembolic complications or intestinal hypoperfusion due to hypovolemic or hypotensive shock cannot be fully excluded. While full necropsy with histopathology of the intestine was not performed to definitively exclude thrombosis as a cause of perforation, there was no evidence of mesenteric thrombus grossly at the time of surgery or during post-mortem examination. Although, theoretically, intestinal hypoperfusion with ischemic reperfusion injury could contribute to bowel compromise and subsequent perforation, intestinal perforation is rarely reported despite the frequency of hypovolemic and hypotensive shock associated with blunt trauma. On initial presentation clinical signs consistent with hypovolemic shock were present; however, after fluid resuscitation, the cat's cardiovascular status appeared stable until its decline 48 h postoperatively. While direct arterial blood pressure monitoring would have allowed for more accurate assessments perioperatively, this level of monitoring was not available. Given the limitations of oscillometric devices in cats, the true intraoperative mean arterial blood pressure values in this case are unknown; however, the relatively consistent blood pressure trends, combined with concurrent vital monitoring and rapid postoperative recovery, suggest that it is unlikely that significant anesthesia-associated hypotension occurred. Intravenous crystalloid and synthetic

colloid therapy was provided as needed in response to decreasing blood pressure trends, and, in the managing clinician's judgment, the perioperative assessment of the patient did not indicate that vasopressor therapy was necessary.

Conclusions

While delayed intestinal perforation is a rare occurrence, it should be considered a possible consequence of severe blunt trauma in patients that initially respond to treatment and then subsequently deteriorate.

Conflict of interest The authors declared no potential conflicts of interest with respect to the research, authorship, and/or publication of this article.

Funding The authors received no financial support for the research, authorship, and/or publication of this article.

ORCID ID A Taylor  <https://orcid.org/0000-0002-3117-1123>

References

- Culp WTN and Silverstein DC. **Thoracic and abdominal trauma**. In: Silverstein DC and Hopper K (eds). *Small animal critical care medicine*. 2nd ed. St Louis, MO: Elsevier Saunders, 2015, pp 728–733.
- Intarapanich NP, McCobb EC, Reisman RW, et al. **Characterization and comparison of injuries caused by accidental and non-accidental blunt force trauma in dogs and cats**. *J Forensic Sci* 2016; 61: 993–999.
- Vnuk D, Pirkic B, Matičić D, et al. **Feline high-rise syndrome: 119 cases (1998–2001)**. *J Feline Med Surg* 2004; 6: 305–312.
- Bège T, Brunet C and Berdah SV. **Hollow viscus injury due to blunt trauma: a review**. *J Visc Surg Suppl* 2016; 153: 61–68.
- Chou HG and Wilson WC. **Anesthetic considerations for abdominal trauma**. In: Smith CE (ed). *Trauma anesthesia*. 2nd ed. Cambridge: Cambridge University Press, 2015, pp 537–538.
- Subramanian V, Raju RS, Vyas FL, et al. **Delayed jejunal perforation following blunt abdominal trauma**. *Ann R Coll Surg Engl* 2010; 92: W23–W24.
- Rollings C, Rozanski EA, DeLaforcade A, et al. **Traumatic mesenteric avulsion and subsequent septic peritonitis in a dog**. *J Vet Emerg Crit Care* 2001; 11: 211–215.
- Suter PF and Olsson S-E. **The diagnosis of injuries to the intestines, gallbladder and bile ducts in the dog**. *J Small Anim Pract* 1970; 11: 575–584.
- Beittenmiller MR, Mann FA, Constantinescu GM, et al. **Clinical anatomy and surgical repair of prepubic hernia in dogs and cats**. *J Assoc Anim Hosp Assoc* 2009; 45: 284–290.
- Cripps NP and Cooper GJ. **Intestinal injury mechanisms after blunt abdominal impact**. *Ann R Coll Surg Engl* 1997; 79: 115–120.
- Wani I, Bhat, Rayees A, et al. **Isolated small bowel mesentery injury after steering wheel trauma**. *Trauma Monthly* 2012; 17: 279–281.
- Kar S, Mohapatra V and Rath PK. **Isolated mesenteric vascular injury following blunt abdominal trauma leading to massive segmental gangrene of small gut: a case report**. *J Clin Diagn Res* 2016; 10: pd16–pd17.
- Goyal S, Goyal S and Garg MK. **Single jejunal blowout perforation following blunt abdominal trauma: diagnostic dilemma**. *J Mahatma Gandhi Inst Med Sci* 2013; 18: 144–146.
- Sule AZ, Kidmas AT, Awani K, et al. **Gastrointestinal perforation following blunt abdominal trauma**. *East Afr Med J* 2007; 84: 429–433.
- Miele V, Piccolo CL, Trinci M, et al. **Diagnostic imaging of blunt abdominal trauma in pediatric patients**. *Radiol Med* 2016; 121: 409–430.
- Canty TG, Sr, Canty TG, Jr and Brown C. **Injuries of the gastrointestinal tract from blunt trauma in children: a 12-year experience at a designated pediatric trauma center**. *J Trauma* 1999; 46: 234–240.
- Chirdan LB, Uba AF and Chirdan OO. **Gastrointestinal injuries following blunt abdominal trauma in children**. *Niger J Clin Pract* 2008; 11: 250–253.
- Hamidian Jahromi A, Johnson L and Youssef AM. **Delayed small bowel perforation following blunt abdominal trauma: a case report and review of the literature**. *Asian J Surg* 2016; 39: 109–112.
- Williams RD and Sargent PT. **The mechanism of intestinal injury in trauma**. *J Trauma* 1963; 3: 288–294.
- Paterson-Brown S, Francis N, Whawell S, et al. **Prediction of the delayed complications of intestinal and mesenteric injuries following experimental blunt abdominal trauma**. *Br J Surg* 1990; 77: 648–651.
- Simpson SA, Syring R and Otto CM. **Severe blunt trauma in dogs: 235 cases (1997–2003)**. *J Vet Emerg Crit Care* 2009; 19: 588–602.