


Short-Term Results of Multiwavelength Photobiomodulation in Retinitis Pigmentosa

Rubens Camargo Siqueira ^{1,2}, Tainara Souza Pinho ², Cinara Cássia Brandão ²

¹Rubens Siqueira Research Center, São Jose do Rio Preto, Brazil; ²Faculty of Medicine of São Jose do Rio Preto—FAMERP, São Jose do Rio Preto, Brazil

Correspondence: Rubens Camargo Siqueira, Rubens Siqueira Research Center, Saldanha Marinho 2815 conj 42, Sao Jose do Rio Preto, SP, 15010-100, Brazil, Email siqueiraretina@gmail.com

Objective: To assess the short-term effects of Multiwavelength Photobiomodulation (LumiThera Valeda Light Delivery System) on retinal functional behavior in patients with retinitis pigmentosa (RP).

Materials and Methods: Twelve RP patients (24 eyes) underwent treatment involving nine photobiomodulation (PBM) sessions using the Valeda system, which emits three distinct wavelengths within the yellow (590 nm; 4 mW/cm²), red (660 nm; 65 mW/cm²), and near-infrared (NIR) (850 nm; 0.6 mW/cm²) spectrum. All evaluations were conducted four weeks post-therapy. The treated eye was compared with baseline (pre-therapy). Following nine PBM sessions, assessments included best-corrected visual acuity (BCVA), retinal sensitivity, and characteristics of the correction area via fundus automated perimetry using the Compass system. Additionally, a functional and structural assessment of the retina was performed using multifocal electroretinography (ERG), optical coherence tomography (OCT), fluorescence retinography (FR), and autofluorescence (AF). Statistical analysis employed the Student's *t*-test for paired samples at a 95% confidence level (*p*-value ≤ 0.05).

Results: LogMAR-based visual acuity assessment demonstrated an improvement in mean value from 0.62 to 0.53 logMAR, with a statistically significant *p*-value of 0.001. Visual field examination, based on mean deviation (MD), pattern standard deviation (PSD), and fundal perimeter deviation index (FPDI) parameters, showed improvement from −19.87 dB to −19.45 dB, 9.77 dB to 9.76 dB, and 37% to 39%, respectively, although with non-significant *p*-values of 0.366, 0.446, and 0.245, respectively. No adverse effects or abnormalities in optical coherence tomography (OCT) and electroretinogram (ERG) were observed during the follow-up period.

Conclusion: In this short-term study, PBM appeared to have the potential to enhance BCVA and fundus automated perimeter in RP patients without causing significant adverse events. However, further assessment with a larger patient cohort and longer follow-up is warranted to ascertain the efficacy of this technique in these patients.

Keywords: photobiomodulation, retinitis pigmentosa, LED, valeda, low-level laser therapy (LLLT)

Introduction

Retinitis pigmentosa (RP) represents a cluster of inherited disorders signified by a progressive decline in peripheral vision and challenges with night vision (nyctalopia) that may result in the loss of central vision. Recent progress in molecular research has unveiled RP as an amalgamation of retinal dystrophies and retinal pigment epithelium (RPE) maladies driven by molecular anomalies across over 40 distinct genes for isolated RP and above 50 different genes for syndromic RP. Clinical presentation diverges amidst patients bearing the same genetic mutation. Inheritance patterns include autosomal dominant (constituting about 20% of cases), autosomal recessive (about 20%), X-linked (approximately 10%), and sporadic occurrences without familial history (remaining 50%). Notably, RP can be associated with systemic conditions, most commonly hearing loss. Understanding RP's molecular underpinnings is critical for prognosis determination and the implementation of gene-targeted therapies. Mitochondrial dysfunction, oxidative stress, and apoptosis of photoreceptor cells comprise RP's pathogenesis. The prevalent RHO gene mutation (P23H) in North American RP patients correlates with the dominant disease form.^{1–13}

Various treatment strategies are being investigated for RP, including light exposure avoidance, vitamin A supplementation, gene therapy, and stem cell therapy. Despite scientific and technological advancements, there is currently no curative treatment for retinitis pigmentosa (RP), with only a small subset of individuals with confirmed

RPE65 mutations being eligible for the approved gene therapy (voretigene neparvovec). Therefore, there is a general need for superior treatment options for this patient population, aiming for functional improvement rather than merely slowing the progression of the degenerative process. Enhancing mitochondrial function and mitigating oxidative stress through therapy exhibits potential not only for RP but also for other retinal degenerations.^{14–19}

Photobiomodulation, a modern therapeutic approach in retinology, has exhibited promising outcomes in clinical investigations concerning age-related macular degeneration, Stargardt's disease, and diabetic retinopathy.^{19–21} Preclinical trials in animal models have illustrated that photobiomodulation (PBM) upheld the metabolic state, functionality, and structure of the treated animals' retinas compared to simulated control groups. It was suggested that PBM might benefit RP-afflicted eyes by alleviating oxidative stress, diminishing expression of proinflammatory proteins in the retina, repairing damaged mitochondria, stimulating cytoprotective factor production, and preventing cell death.^{22–29} Early clinical studies and case reports indicate that PBM therapy and low-level light therapy (LLLT) may yield beneficial effects for RP patients, enhancing visual acuity, night vision, and quality of life.^{30–33}

From a mechanical perspective, light wavelengths between 630 and 1000 nm are hypothesized to interact with the mitochondrial enzyme cytochrome c oxidase, initiating signaling mechanisms that optimize mitochondrial energy metabolism, promote antioxidant production, and enhance cellular survival.^{34,35} The absorption spectrum of cytochrome c oxidase corresponds to the cytoprotective effects associated with near-infrared light. Comparative analyses suggest that multinuclear enzymes containing copper (II) complexes are involved in the cellular mechanisms of photobiomodulation (PBM) within this wavelength range, with cytochrome c oxidase acting as the primary photoreceptor molecule. The enzyme's copper components, CuA and CuB, are believed to initiate secondary cellular signaling pathways that activate transcription factors, modify gene expression, and enhance the synthesis of protective proteins, thus creating a stable microenvironment for cell survival.^{36,37}

The therapeutic effects of far-red and near-infrared (FR/NIR) light are thought to occur through activation of intracellular signaling cascades via photon absorption by cytochrome c oxidase, facilitating improvements in bioenergetics and cellular homeostasis. Studies have demonstrated that red light-mediated PBM at 670 nm can protect the retina from mitochondrial toxicity induced by methanol and has been shown to have protective effects in models of diabetic retinopathy, age-related macular degeneration (AMD), and retinitis pigmentosa (RP). Notably, cytochrome c oxidase absorbs over 50% of light in the 600 to 850 nm range, enhancing the efficacy of PBM therapy.^{25–31}

For instance, PBM using 830 nm light has effectively preserved retinal structure in experimental RP models, evaluating protective effects through measurements of total retinal thickness and outer nuclear layer thickness, where photoreceptor nuclei reside. Furthermore, retinal function was assessed using electroretinography (ERG) measurements in rats during critical periods of photoreceptor loss, adhering to the ISCEV protocol. These findings highlight the promise of PBM as a therapeutic strategy for retinal disorders such as RP; however, further clinical investigations are required to confirm the efficacy and safety of this therapy in humans.^{30,31}

This study aimed to assess the short-term effects of Multiwavelength Photobiomodulation in retinitis pigmentosa-afflicted eyes, scrutinizing changes in visual acuity, visual field trends, and evaluating functional and structural shifts in the retina via electroretinography (ERG) and optical coherence tomography angiography (OCTA).

Patients and Methods

This research employed a prospective, non-randomized, open study design to assess alterations in best-corrected visual acuity (BCVA) and the effects on fluorescein angiography, infrared imaging, fundus autofluorescence (AF), OCT, optical coherence tomography angiography (OCTA), and fundus automated perimeter resulting from ocular photobiomodulation (PBM).

The study adhered to the principles of the Declaration of Helsinki and received approval from the Ethics Committee of the Hospital Beneficência Portuguesa de São José do Rio Preto and the National Research Ethics Committee in Brazil (registered under CAAE: 61700116.9.0000.5629). All participants provided their informed consent through signed consent forms.

The evaluation of patients took place at the Rubens Siqueira Research Center in São José do Rio Preto, SP, Brazil, spanning from August 2022 to June 2023.

Inclusion Criteria and Exclusion Criteria

Inclusion criteria required patients to be over 18 years old, diagnosed with RP, exhibiting a BCVA of 20/40 or worse (0.301 logMAR), or with acuity better than 20/40 (0.301 logMAR) but with a visual field of less than 20 degrees (tubular visual field), characterizing subnormal vision, and having duly signed the informed consent form.

Exclusion criteria encompassed individuals who had undergone intravitreal injection of corticosteroids or other antiangiogenic medications within 6 months of initial assessment, those with media opacities significantly affecting BCVA and fundus documentation, recent intraocular surgery or interventions, acute ocular infection, exposure to ionizing radiation in specific regions, allergy to fluorescein, alcoholism or drug use, medical or psychological conditions impeding study completion or consent signing, uncontrolled diseases, legal capacity limitations, or prior history of malignant tumors.

Ophthalmological Assessments

The patient initially underwent a series of assessments that included measurement of distance BCVA (best-corrected visual acuity) using the standard logMAR (Logarithm of the Minimum Angle of Resolution) chart. These were conducted by the same examiner at each follow-up visit prior to any other procedures. The LogMAR chart was chosen due to its superior accuracy compared to other visual acuity charts, and its results are more easily utilized in vision analysis, making it the preferred chart in clinical studies.

Additionally, multifocal ERG (Electroretinography), OCT (Optical Coherence Tomography RS-3000 Advance 2), color retinography and fluorescence (FR), AF (Auto Fluorescence imaging), and automated fundus perimetry using the Compass fundus perimeter were performed.

Automated perimetry with retinography was carried out using the Compass equipment, which is capable of analyzing visual field defects and corresponding areas in the retina through retinal imaging. The examination involved three key parameters: mean deviation (MD), pattern standard deviation (PSD), and fundal perimeter deviation index (FPDI).

The MD reflects the overall sensitivity of the retina, representing the weighted average deviation of the mean sensitivity of all tested points. It is a negative value; the closer it is to positive, the better the overall sensitivity of the retina.

The PSD indicates whether the values between the points on the total deviation plot differ significantly from each other, serving as an indicator of localized defects in the tested visual field. Its value will be small in normal visual fields.

The FPDI is a global index that assigns a value between 1% and 100% based on an aggregated percentage of the visual function, with 100% representing a perfect visual field adjusted for age. These parameters were utilized in our statistical analyses to evaluate retinal sensitivity before and after treatment.

PBM Treatment

A cohort of twelve patients diagnosed with Retinitis Pigmentosa (RP) underwent Valeda treatment, which administered three distinct wavelengths in the yellow (590 nm; 4 mW/cm²; 2×35 seconds), red (660 nm; 65 mW/cm²; 2×90 seconds), and near-infrared (NIR) (850 nm; 0.6 mW/cm²; 2×35 seconds) range.

Each treatment session lasted approximately 5 minutes per eye.

The patients received nine treatments over a 3-week period, with three sessions per week occurring on alternate days.

All evaluations were conducted 4 weeks post-intervention.

Data Analysis

The treated eye was compared to its pre-treatment state. The assessment included the following aspects: best-corrected visual acuity (BCAV), retinal sensitivity, and features of the correction area as evaluated by fundus automated perimeter using the compass system. Functional and structural assessments of the retina were also performed using multifocal ERG, OCT, FR, and AF modalities.

Statistical Methods

Paired samples Student's *t*-test was employed for statistical analysis using Jamovi software version 2.4 and R version 4.1. All analyses followed a 95% confidence level (p -value ≤ 0.05).

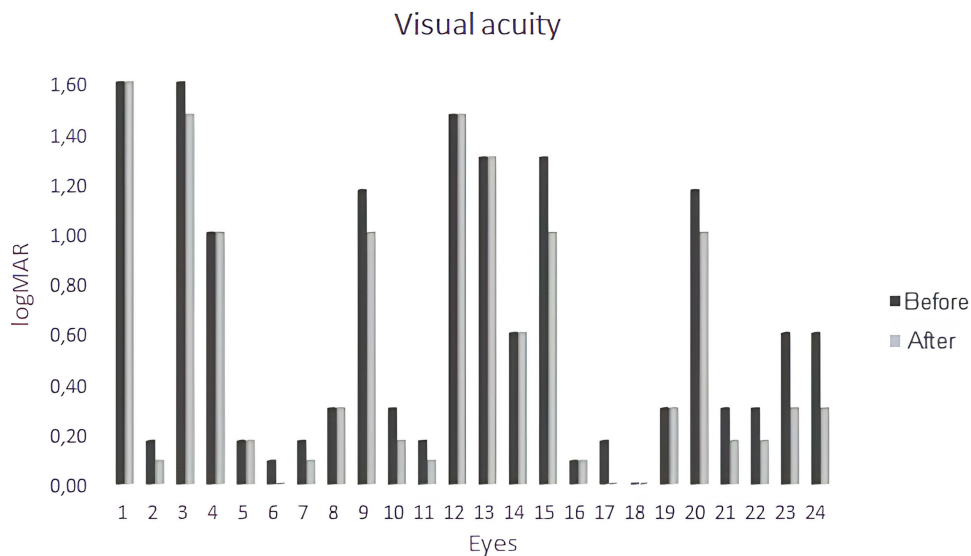


Figure 1 Graph showing visual acuity on the LogMAR scale before and after treatment with PBM (photobiomodulation).

Results

Following the assessment of best-corrected visual acuity (BCVA) using logMAR (Figure 1), a statistically significant improvement was observed in the mean value from 0.62 to 0.53 logMAR, with a p-value of 0.001. The paired samples *t*-test comparing the means yielded a p-value of <0.001, indicating a statistically significant difference between acuity values before and after treatment. Furthermore, analysis revealed that the median values before and after treatment remained unchanged, suggesting no central or typical alteration in data distribution (Figure 2). Visual field examination, assessing MD, PSD, and FPD parameters, exhibited improvements from -19.87 dB to -19.45 dB, 9.77 dB to 9.76 dB, and 37% to 39%, respectively, despite having p-values greater than 0.05 (p = 0.366, 0.446, and 0.245, respectively; Figure 3A and B).

Enhanced visual acuity (VA) and improved visual field were detectable within the first month of follow-up (Figure 4). Eight out of 12 patients reported increased sharpness and brightness in their vision. Although subjective, these self-reported improvements are considered relevant as patients spontaneously noted them without specific prompting.

No adverse effects or abnormalities in optical coherence tomography (OCT) and electroretinogram (ERG) were observed throughout the follow-up period among participants.

T-test for paired samples

			statistic	gl	p
BCVA before	BCVA after	Student's t	4.53	23.0	<.001

Note. $H_a: \mu \text{ Measure 1} - \text{Measure 2} \neq 0$

Descriptive statistics

	N	Mean	Median	St.dev	St.error
BCVA before	24	0.623	0.300	0.543	0.111
BCVA after	24	0.528	0.300	0.541	0.111

Figure 2 Statistics between mean and median before and after treatment, using t-test for paired samples.

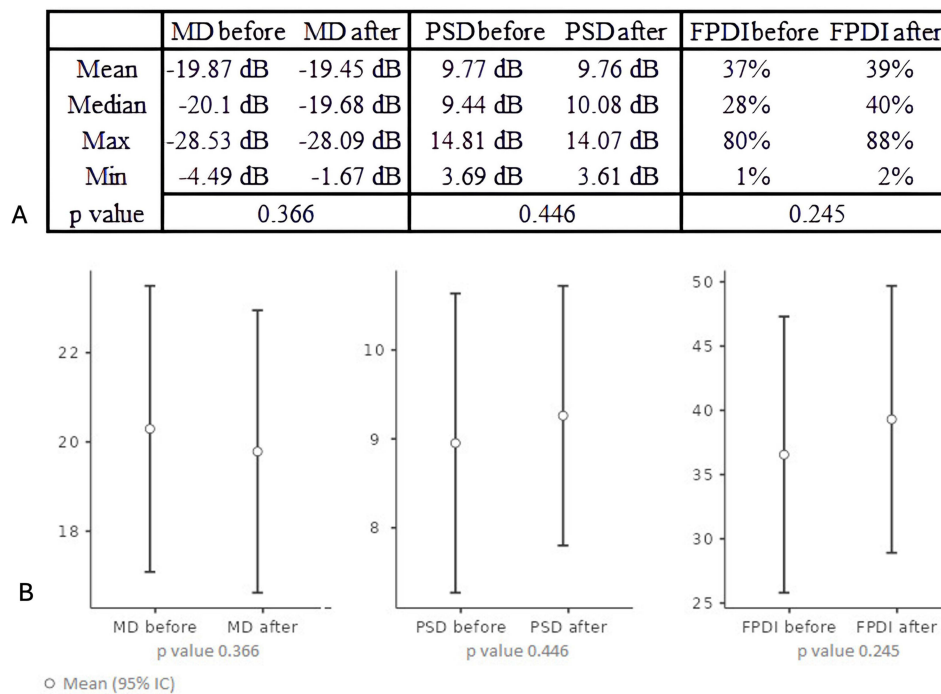


Figure 3 (A) Visual field examination, based on MD, PSD, and FPDI parameters, although having p-values greater than 0.05, showed an improvement from -19.87 dB to -19.45 dB, 9.77 dB to 9.76 dB, and 37% to 39% , respectively ($p = 0.366$, 0.446 , and 0.245 , respectively). The perimeter examination included three parameters: mean deviation (MD), pattern standard deviation (PSD), and fundus perimeter deviation index (FPDI). **(B)** graphical representation indicating that, although there was no statistically significant difference in perimetry, there was a trend toward improvement.

Discussion

Mitochondrial dysfunction, oxidative stress, and apoptosis are pivotal factors in the progression of retinal degenerations. Photoreceptors, being highly metabolically active, possess a dense population of mitochondria in their inner segments to satisfy the energy needs for outer segment renewal and dark current maintenance. Dysfunctional mitochondria and oxidative injury significantly contribute to the pathogenesis of photoreceptor degenerative disorders, such as retinitis pigmentosa and other retinal diseases. These conditions are linked to the decline of retinal antioxidant systems and cytoprotective factors, diminishing defense against oxidative harm and culminating in apoptotic cell death. Furthermore, mitochondrial dysfunction is evident in diverse neurodegenerative ailments including Parkinson's disease, Alzheimer's, Huntington's disease, and amyotrophic lateral sclerosis. Reactive oxygen species (ROS) are produced as byproducts during oxidative phosphorylation in the mitochondrial electron transport chain. Antioxidant mechanisms such as mitochondrial superoxide dismutase (MnSOD), glutathione (GSH), and thioredoxin aim to curtail free radical levels and impede their transformation into potent oxidants. An imbalance between free radical generation and antioxidant capacity results in oxidative stress, provoking impairment of cellular molecules, including lipids, proteins, and nucleic acids, leading to irreversible damage. Accumulation of mitochondrial ROS affects redox-sensitive signaling pathways that can trigger the initiation of the apoptotic process. Apoptosis, both caspase-dependent and -independent, is a prevailing feature in various hereditary photoreceptor degenerative conditions. In animal models of retinal degenerations, apoptosis occurs during the critical phase of photoreceptor development in the retina.^{20–31}

Sandeep Gopalakrishnan et al³¹ investigated the effects of photobiomodulation (PBM) on an animal model of retinitis pigmentosa, specifically in P23H transgenic rats. The study aimed to determine whether brief exposure to far-red and near-infrared light (830 nm) could support mitochondrial metabolism and reduce photoreceptor degeneration. Rat pups were exposed to 830 nm light (180 seconds; 25 mW/cm²; 4.5 J/cm²) from postnatal day 10 to 25, while a control group received a sham treatment without light exposure. At postnatal day 30, the metabolic state, retinal function, and

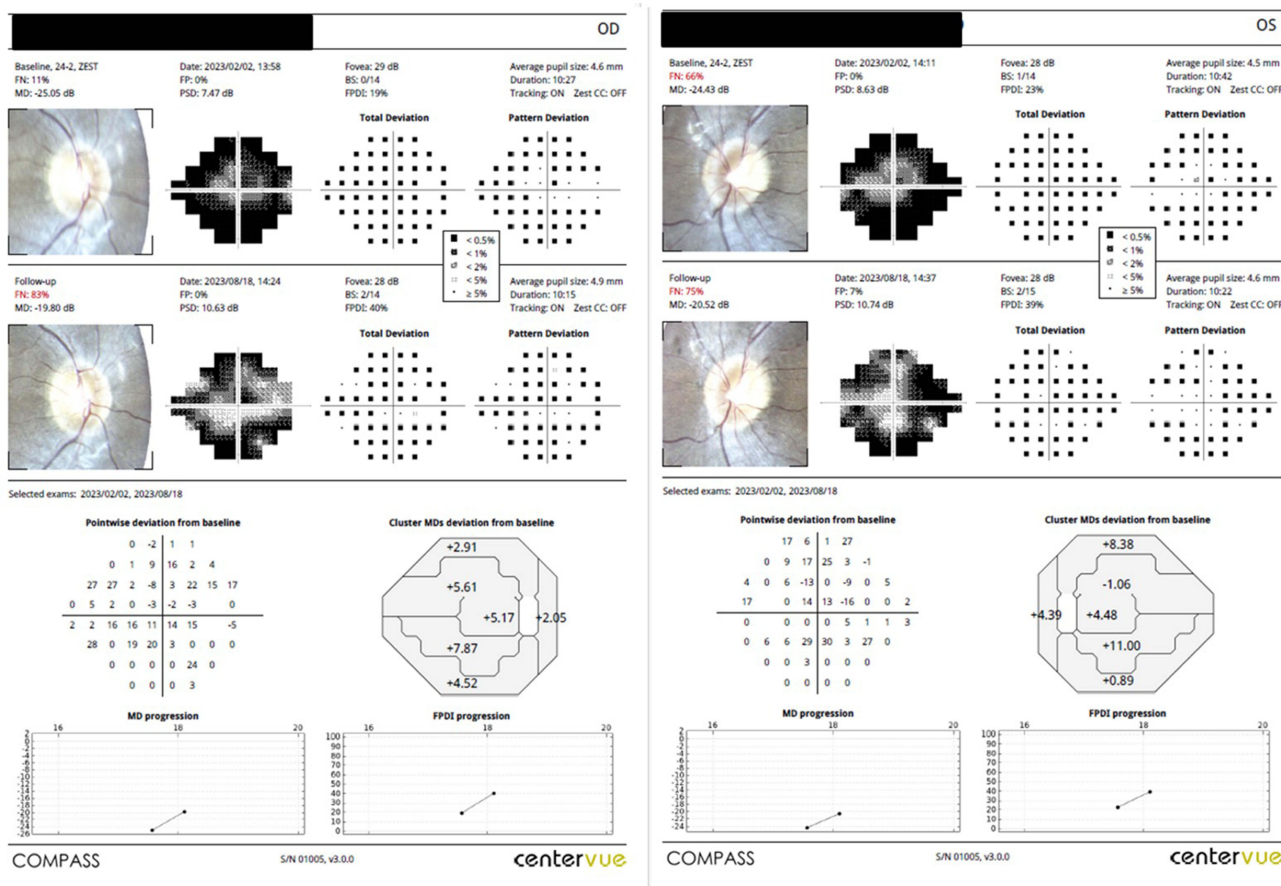


Figure 4 Fundus automated perimetry using the compass system, showing an improvement in retinal sensitivity 1 month after treatment.

morphology were assessed using 3D optical cryoimaging for mitochondrial redox state (NADH/FAD), electroretinography (ERG), spectral-domain optical coherence tomography (SD-OCT), and histomorphometry.

The results demonstrated that PBM preserved the metabolic, functional, and morphological condition of the retina in treated rats compared to sham controls. PBM protected against the disruption of mitochondrial respiratory chain oxidation state found in control animals. Additionally, scotopic ERG responses were significantly improved in PBM-treated rats. SD-OCT and histological analyses indicated that PBM maintained retinal structural integrity. This research provides initial evidence of PBM’s impact on the mitochondrial redox state in a reliable retinal disease model, highlighting that therapies targeting mitochondrial metabolism could offer substantial potential for treating degenerative retinal diseases.

Ivandic et al,³² reported a case study exploring the application of Low-Level Laser Therapy (LLLT) in a patient with retinitis pigmentosa. The treatment comprised using a continuous wave diode laser (780 nm, average output of 10 mW at 292 hz, 50% pulse modulation) on the retina through the conjunctiva for 40 seconds (0.4 J, 0.333 W/cm²), twice a week, over 2 weeks (totaling 1.6 J). The patient, a 55-year-old man with advanced retinitis pigmentosa, was monitored for 7 years.

At the initial assessment, the patient’s visual acuity was 20/50 in both eyes. Visual fields were limited to a central residue of 5 degrees, and Tritan color vision deficiency was identified. Electroretinography revealed an absence of retinal potential. Further examinations indicated optic nerve atrophy, narrowed retinal vessels, and a typical pattern of retinal pigmentation.

After four initial LLLT sessions, visual acuity improved to 20/20 in both eyes. Visual fields also showed improvement, except for an absolute concentric scotoma in a mid-peripheral area. Five years after cessation of LLLT treatment, symptoms recurred, leading to four additional LLLT sessions, which reinstated the initial success. Over the subsequent

two years, 17 additional “as-needed” treatments were administered to sustain the achieved outcome. These results indicate that LLLT may enhance and maintain vision in patients with retinitis pigmentosa, potentially contributing to delaying the progression of blindness.

Carson et al³⁸ conducted a Phase 1, single ascending dose trial (ACTRN12618000651280) to assess the safety of a photobiomodulation (PBM) laser treatment on the macula of individuals with advanced retinitis pigmentosa (RP). The study, adhering to the TREND guidelines, utilized a custom-designed PBM laser system integrated into a slit lamp, emitting a 670-nm near-infrared light with a 4.5 mm flat-top beam. The primary outcome was the safety profile, while secondary outcomes included changes in visual acuity and photopic flicker electroretinogram (ERG). Twelve patients were enrolled, divided into two groups: Group 1 received 25 mW/cm² irradiance, and Group 2 received 100 mW/cm², contingent on safety verification after a 6-month follow-up. The procedure was well tolerated by all participants, with no adverse reactions or missing data. The study reported a mean improvement of 5.4 letters in visual acuity at 8 weeks post-treatment, with greater variance in Group 2. Cone-derived photopic flicker responses were nearly abolished, showing high variability. No significant changes were observed in ERG amplitude, which was unrecordable due to disease severity. While the procedure did not significantly alter ophthalmic parameters, the visual acuity improvement appeared to taper by 6 months.

Luque-Mialdea and Molina-Seoane³³ presented a case study of a 38-year-old patient diagnosed with retinitis pigmentosa at 20 years old, displaying a progressive decline in visual acuity and visual field. Following the implementation of a photobiomodulation therapeutic protocol consisting of 9 interspersed sessions, the patient exhibited enhancements in visual acuity, night vision, and quality of life. Clinical assessment demonstrated a visual acuity of 10/10 in both eyes and a significant improvement in the visual field.

Alberta et al³⁹ conducted a systematic review, following PRISMA 2020 guidelines, which included seven studies examining the use of photobiomodulation therapy for retinitis pigmentosa. The inclusion criteria required studies to involve human or animal eyes, be published in English, and appear within the last decade. Most studies were expected to employ experimental designs, and their quality was assessed using the ROBINS-I tool. The reviewed studies showed clinical improvements in visual acuity and visual fields, as well as functional preservation of the outer nuclear layer. Electroretinogram waveforms declined slower than controls, with observed disruptions in the retinal pigment epithelium and photoreceptor nuclei preservation twice as thick as controls ($p < 0.05$). Photobiomodulation was found to enhance retinal mitochondrial function and maintain mitochondrial redox state, indicating significant recovery of photoreceptor cell function. These findings suggest that photobiomodulation can offer a promising therapeutic strategy for retinitis pigmentosa due to its significant impact on clinical improvement, mitochondrial repair, and retinal layer thickening. However, some studies had limited participant numbers, which restricts insights into long-term outcomes for retinitis pigmentosa.

In our research, employing each patient as their own control, we observed a substantial variance in mean visual acuity before and after treatment, with a p -value less than 0.001, indicating a statistically significant difference and notable enhancement in the patient’s visual acuity.

Considering the analysis of the BCVA (best corrected visual acuity) data presented in [Figure 1](#), the results suggest that there was no loss of visual acuity in any of the cases studied. This indicates that patients either maintained or improved their BCVA following treatment, suggesting its potential as a safety parameter for the use of PBM (photobiomodulation). No deleterious effects were observed in the acute protocol, which was characterized by a single treatment series.

Furthermore, the overall average gain was nearly one line of improvement in visual acuity, which is clinically significant. In contextualizing these results, we observe that in 50% of the eyes studied (24 eyes), the initial BCVA was 0.3 or better. This data highlights that, although most patients began with only a slight reduction in visual acuity, improvement was still observed. This suggests that the beneficial effect of the treatment is consistent even in cases with lesser initial impairment, thus minimizing concerns about a potential ceiling effect.

These findings are relevant for clinical application, confirming both the efficacy and safety of the acute PBM treatment protocol. Thus, the study reflects its potential as a safe alternative to improve visual acuity without causing harm to the patient.

Regarding the assessment of the visual field using the parameters MD, PSD, FPGDI, the Student's *t*-test yielded a *p*-value > 0.05, suggesting that statistically, the data before and after treatment did not differ. Nevertheless, Figure 4 indicated that over 30% of the patients exhibited improvements in visual acuity parameters, while over 40% maintained the same status without deterioration.

In our study, the analysis of both electroretinography (ERG) and optical coherence tomography (OCT) revealed no significant differences before and after treatment, indicating an absence of adverse effects from the therapy. Notably, the OCT results specifically demonstrated that there were no structural changes associated with the treatment. Regarding the multifocal electroretinogram (mfERG), while it provides a sectorial reflection of the retina's functional status and stands as a reliable parameter, we believe that the pattern electroretinogram (PERG) could offer more comprehensive quantitative data on macular function. However, PERG was not conducted in this pilot study. This omission highlights a potential area for further research to enhance our understanding of macular function in response to treatment.

This study had several limitations. Primarily, the absence of a control group due to the heterogeneity of the RP population and the small sample size may have led to the inclusion of eyes with no potential for improvement. Another limitation was the lack of a comparative protocol regarding the dose and interval of the therapy. We utilized photobiomodulation parameters derived from the study of age-related macular degeneration,⁴⁰ thereby forgoing comparison with a sequential days protocol or a greater number of total applications. Additionally, it remains uncertain whether there is any associated toxicity with the repeated and long-term use of this technique, as well as whether the response to therapy will be sustained in new cycles of PBM.

Despite the inherent limitations of a short-term pilot study, our findings indicate that photobiomodulation (PBM) shows promise in improving best-corrected visual acuity (BCVA) and outcomes from fundus automated perimetry in patients with retinitis pigmentosa (RP), without significant adverse effects. However, to thoroughly validate the efficacy and safety of PBM, additional studies with larger patient cohorts and extended follow-up durations are essential. This research will be crucial in confirming the potential therapeutic role of PBM in the treatment of RP and possibly expanding its application to other retinal disorders.

Funding

This study was funded by National Council for Scientific and Technological Development from Brazilian Ministry of Science, Technology and Innovation (CNPq #166489/2023-9). The opinions, assumptions, and conclusions or recommendations expressed in this material are the responsibility of the authors and do not necessarily reflect the views of funding agency.

Disclosure

The authors report no conflicts of interest in this work.

References

1. Nguyen XT, Moekotte L, Plomp AS, Bergen AA, van Genderen MM, Boon CJF. Retinitis pigmentosa: current clinical management and emerging therapies. *Int J Mol Sci.* 2023;24(8):7481. PMID: 37108642; PMCID: PMC10139437. doi:10.3390/ijms24087481
2. Liu W, Liu S, Li P, Yao K. Retinitis pigmentosa: progress in molecular pathology and biotherapeutic strategies. *Int J Mol Sci.* 2022;23(9):4883. PMID: 35563274; PMCID: PMC9101511. doi:10.3390/ijms23094883
3. Song DJ, Bao XL, Fan B, Li GY. Mechanism of cone degeneration in retinitis pigmentosa. *Cell Mol Neurobiol.* 2023;43(3):1037–1048. PMID: 35792991. doi:10.1007/s10571-022-01243-2
4. Berson EL. Retinitis pigmentosa. The Friedenwald Lecture. *Invest Ophthalmol Vis Sci.* 1993;34:1659–1676.
5. Hartong DT, Berson EL, Dryja TP. Retinitis pigmentosa. *Lancet.* 2006;368:1795–1809. doi:10.1016/S0140-6736(06)69740
6. Campochiaro PA, Mir TA. The mechanism of cone cell death in retinitis pigmentosa. *Prog Retin Eye Res.* 2018;62:24–37. doi:10.1016/j.preteyeres.2017.08.004
7. Berger W, Kloetkener-Gruissem B, Neidhardt J. The molecular basis of human retinal and vitreoretinal diseases. *Prog Retin Eye Res.* 2010;29:335–375. doi:10.1016/j.preteyeres.2010.03.004
8. Verbakel SK, van Huet RAC, Boon CJF, et al. Non-syndromic retinitis pigmentosa. *Prog Retin Eye Res.* 2018;66:157–186. doi:10.1016/j.preteyeres.2018.03.005
9. Mitchell J, Balem F, Tirupula K, et al. Comparison of the molecular properties of retinitis pigmentosa P23H and N15S amino acid replacements in rhodopsin. *PLoS One.* 2019;14:e0214639. doi:10.1371/journal.pone0214639

10. Dryja TP, McGee TL, Reichel E, et al. A point mutation of the rhodopsin gene in one form of retinitis pigmentosa. *Nature*. 1990;343:364–366. doi:10.1038/343364a0
11. Berson EL. Light deprivation and retinitis pigmentosa. *Vis Res*. 1980;20:1179–1184. doi:10.1016/0042-6989(80)90057-7
12. Berson EL, Rosner B, Sandberg MA, et al. Clinical trial of lutein in patients with retinitis pigmentosa receiving vitamin A. *Arch Ophthalmol*. 2010;128:403–411. doi:10.1001/archophthalmol.2010.32
13. Athanasiou D, Aguila M, Bellingham J, et al. The molecular and cellular basis of rhodopsin retinitis pigmentosa reveals potential strategies for therapy. *Prog Retin Eye Res*. 2018;62:1–23. doi:10.1016/j.preteyeres.2017.10.002
14. Daich Varela M, Georgiadis A, Michaelides M. Genetic treatment for autosomal dominant inherited retinal dystrophies: approaches, challenges and targeted genotypes. *Br J Ophthalmol*. 2023;107(9):1223–1230. PMID: 36038193. doi:10.1136/bjo-2022-321903
15. Humayun MS, Lee SY. Advanced retina implants. *Ophthalmol Retina*. 2022;6(10):899–905. PMID: 35436597. doi:10.1016/j.oret.2022.04.009
16. Murro V, Banfi S, Testa F, et al. A multidisciplinary approach to inherited retinal dystrophies from diagnosis to initial care: a narrative review with inputs from clinical practice. *Orphanet J Rare Dis*. 2023;18(1):223. PMID: 37525225; PMCID: PMC10388566. doi:10.1186/s13023-023-02798-z
17. Chen X, Xu N, Li J, Zhao M, Huang L. Stem cell therapy for inherited retinal diseases: a systematic review and meta-analysis. *Stem Cell Res Ther*. 2023;14(1):286. PMID: 37798796; PMCID: PMC10557171. doi:10.1186/s13287-023-03526-x
18. Tomita H, Sugano E. Optogenetics-mediated gene therapy for retinal diseases. *Adv Exp Med Biol*. 2021;1293:535–543. PMID: 33398840. doi:10.1007/978-981-15-8763-4_37
19. Siqueira RC, Belissimo LM, Pinho TS. Short-term results of photobiomodulation using light-emitting diode light of 670 nm in eyes with age-related macular degeneration. *Photobiomodul Photomed Laser Surg*. 2021;39(9):581–586. doi:10.1089/photob.2021.0005
20. Muste JC, Russell MW, Singh RP. Photobiomodulation therapy for age-related macular degeneration and diabetic retinopathy: a review. *Clin Ophthalmol*. 2021;15:3709–3720. PMID: 34511875; PMCID: PMC8421781. doi:10.2147/OPHT.S272327
21. Scalinci SZ, Valsecchi N, Pacella E, Trovato Battagliola E. Effects of photo-biomodulation in stargardt disease. *Clin Ophthalmol*. 2022;16:85–91. PMID: 35046633; PMCID: PMC8760100. doi:10.2147/OPHT.S344378
22. Karu T. Mitochondrial mechanisms of photobiomodulation in context of new data about multiple roles of ATP. *Photomed Laser Surg*. 2010;28(2):159–160. doi:10.1089/pho.2010.2789
23. Eells JT, Gopalakrishnan S, Valter K. Near-infrared photobiomodulation in retinal injury and disease. *Adv Exp Med Biol*. 2016;54:437–441. doi:10.1007/978-3-319-17121-0_58
24. Geneva I. Photobiomodulation for the treatment of retinal diseases: a review. *Int J Ophthalmol*. 2016;9:145–152. doi:10.18240/ijo.2016.01.24
25. de Freitas LF, Hamblin MR. Proposed mechanisms of photobiomodulation or low-level light therapy. *IEEE J Sel Top Quantum Electron*. 2016;22:348–364. doi:10.1109/JSTQE.2016.2561201
26. Hamblin MR. Mechanisms and mitochondrial redox signaling in photobiomodulation. *Photochem Photobiol*. 2018;94:199–212. doi:10.1111/php.12864
27. Natoli R, Zhu Y, Valter K, et al. Gene and noncoding RNA regulation underlying photoreceptor protection: microarray study of dietary antioxidant saffron and photobiomodulation in rat retina. *Mol Vis*. 2010;16:1801–1822. PMC2932490; PMID: 20844572.
28. Eells JT, Henry MM, Summerfelt P, et al. Therapeutic photobiomodulation for methanol-induced retinal toxicity. *Proc Natl Acad Sci*. 2003;100:3439–3444. doi:10.1073/pnas.0534746100
29. Nicholls P. Formate as an inhibitor of cytochrome c oxidase. *Biochem Biophys Res Commun*. 1975;67:610–616. doi:10.1016/0006-291x(75)90856-6
30. Kirk DK, Schmitt H, Abroeb B, et al. Photobiomodulation reduces photoreceptor death and regulates cytoprotection in early states of P23H retinal dystrophy. In: Proceedings of SPIE, Mechanisms for Low-Light Therapy VIII. 2013: 8569. doi: doi.org/10.1117/12.981791
31. Gopalakrishnan S, Mehrvar S, Maleki S, et al. Photobiomodulation preserves mitochondrial redox state and is retinoprotective in a rodent model of retinitis pigmentosa. *Sci Rep*. 2020;10. doi:10.1038/s41598-020-77290-w
32. Ivandic BT, Ivandic T. Low-level laser therapy improves vision in a patient with retinitis pigmentosa. *Photomed Laser Surg*. 2014;32(3):181–184. doi:10.1089/pho.2013.3535
33. Luque-Mialdea F, Molina-Seoane V. Retinitis pigmentosa: significant improvement with photobiomodulation. *Archivos de la Sociedad Española de Oftalmología*. doi:10.1016/j.oftale.2023.10.001
34. Albarracin R, Eells J, Valter K. Photobiomodulation protects the retina from light-induced photoreceptor degeneration. *Invest Ophthalmol Vis Sci*. 2011;52:3582–3592. doi:10.1167/iiov.10-6664
35. Wong-Riley MT, Liang HL, Eells JT, et al. Photobiomodulation directly benefits primary neurons functionally inactivated by toxins: role of cytochrome c oxidase. *J Biol Chem*. 2005;280:4761–4771. doi:10.1074/jbc.M409650200
36. Begum R, Pownner MB, Hudson N, Hogg C, Jeffery G. Treatment with 670 nm light up regulates cytochrome C oxidase expression and reduces inflammation in an age-related macular degeneration model. *PLoS One*. 2013;8:e57828. doi:10.1371/journal.pone.0057828
37. Eells J, Wong-Riley MT, VerHoeve J, et al. Introduction of mitochondrial signals in accelerated wound and retinal healing by near-infrared light therapy. *Mitochondrion*. 2004;4:559–567. doi:10.1016/j.mito.2004.07.033
38. Casson RJ, Wood JPM, Ao J, et al. Cone photoreceptor preservation with laser photobiomodulation in murine and human retinal dystrophy. *Clin Transl Med*. 2022;12(2):e673. PMID: 35184381; PMCID: PMC8858622. doi:10.1002/ctm2.673
39. Alberta IB, Amelia YS, Stefanie A. Photobiomodulation therapy as a new hope therapy for retinitis pigmentosa: a systematic review. *Rev Bras Oftalmol*. 2024;83:e0023. doi:10.37039/1982.8551.20240023
40. Burton B, Parodi MB, Jürgens I, et al. LIGHTSITE II randomized multicenter trial: evaluation of multiwavelength photobiomodulation in non-exudative age-related macular degeneration. *Ophthalmol Ther*. 2023;12(2):953–968. PMID: 36588113; PMCID: PMC9805913. doi:10.1007/s40123-022-00640-6

Clinical Ophthalmology

Dovepress

Publish your work in this journal

Clinical Ophthalmology is an international, peer-reviewed journal covering all subspecialties within ophthalmology. Key topics include: Optometry; Visual science; Pharmacology and drug therapy in eye diseases; Basic Sciences; Primary and Secondary eye care; Patient Safety and Quality of Care Improvements. This journal is indexed on PubMed Central and CAS, and is the official journal of The Society of Clinical Ophthalmology (SCO). The manuscript management system is completely online and includes a very quick and fair peer-review system, which is all easy to use. Visit <http://www.dovepress.com/testimonials.php> to read real quotes from published authors.

Submit your manuscript here: <https://www.dovepress.com/clinical-ophthalmology-journal>