

Received: 2021.05.21

Accepted: 2021.09.11

Available online: 2021.09.30

Published: 2021.10.29

# A Pain in the Foot: Delayed Diagnosis of Primary Septic Arthritis of Naviculocuneiform and Second/Third Tarsometatarsal Joints

EF **Pamela Isa Evangelista Basilio-Razon**  
E **Evelyn Wong**

Department of Emergency Medicine, Singapore General Hospital, Singapore, Singapore

#### Authors' Contribution:

Study Design A  
Data Collection B  
Statistical Analysis C  
Data Interpretation D  
Manuscript Preparation E  
Literature Search F  
Funds Collection G

**Corresponding Author:** Pamela Isa Evangelista Basilio-Razon, e-mail: [pamela.isa.evangelista.basilio@sg.com.sg](mailto:pamela.isa.evangelista.basilio@sg.com.sg)  
**Financial support:** None declared  
**Conflict of interest:** None declared

**Patient:** Male, 65-year-old  
**Final Diagnosis:** Septic arthritis of midfoot  
**Symptoms:** Foot pain  
**Medication:** —  
**Clinical Procedure:** Debridement • drainage  
**Specialty:** Family Medicine • General and Internal Medicine • Orthopedics • Emergency Medicine


**Objective:** Challenge in differential diagnosis  
**Background:** Septic arthritis needs to be recognized early because a delay in the treatment leads to significant morbidity and mortality. We present a case of primary septic arthritis of the tarsometatarsal joints in a middle-aged man who presented multiple times to outpatient clinics and the Emergency Department with worsening foot pain. His condition was misdiagnosed several times, and he only received definitive treatment 3 weeks after the onset of his symptoms.

**Case Report:** A middle-aged man developed sudden-onset atraumatic left ankle pain that later localized to his foot. Despite analgesics, his foot pain became severe and persistent, affecting his ambulation and sleep. He had multiple consults with his primary care physician, orthopedic specialists, and emergency physicians. Initial radiological and magnetic resonance imaging (MRI) showed degenerative changes, and osteoarthritis was diagnosed. Despite regular analgesics, he experienced worsening pain, prompting his revisit to the Emergency Department. Upon admission, his inflammatory markers were more elevated and a repeat MRI of the foot showed extensive joint effusion, periarticular marrow edema, and bony erosions. He underwent second to third tarsometatarsal joint debridement, washout, drainage, and biopsy. Intraoperative findings showed purulent fluid and clumps of debris within the joint. He received a 6-week course of intravenous antibiotics and was transferred to a rehabilitation center.

**Conclusions:** Septic arthritis of the midfoot is rare. Laboratory and radiological investigations have limitations and should be guided by appropriate clinical findings and judgment. It is important to maintain a high index of suspicion for these cases to prevent morbidity in affected patients.


**Keywords:** Arthritis, Infectious • Foot Diseases • Foot Joints • Tarsal Joints

Full-text PDF: <https://www.amjcaserep.com/abstract/index/idArt/933233>

 3164

 —

 6

 32



## Background

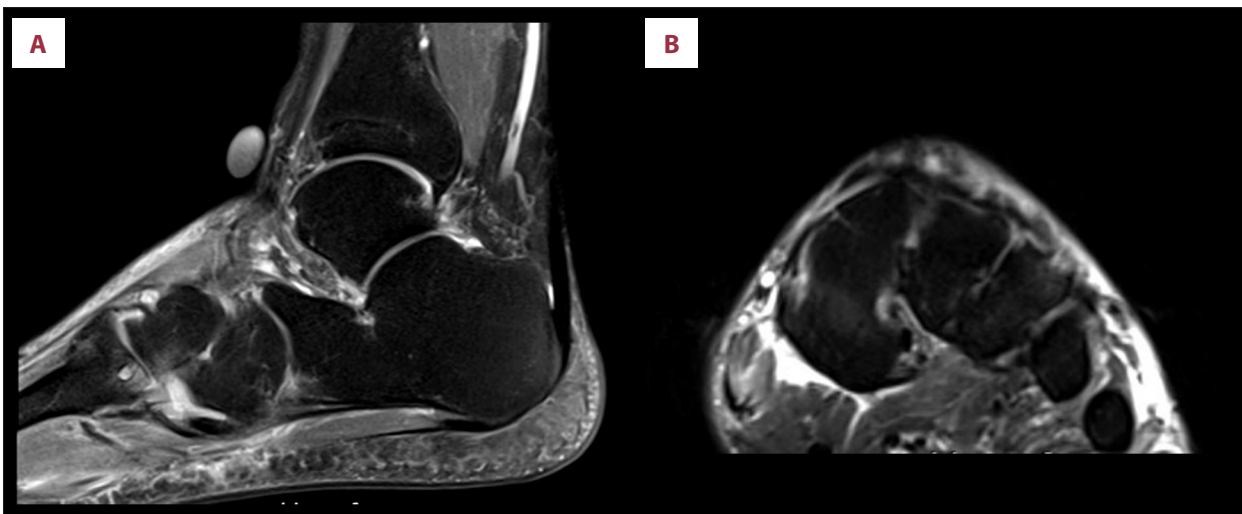
Acute painful joints are frequent presenting symptoms in the Emergency Department. The differential diagnoses for monoarticular arthritis are diverse, and it can be challenging for physicians to immediately identify the cause. Septic arthritis (SA) occurs when an infectious agent affects the synovium. The routes of infection include hematogenous spread, direct inoculation, and extension from an infected contiguous site [1-3]. The condition needs to be recognized early because delays in the treatment can lead to significant morbidity and mortality. Gout is clinically suspected in middle-aged men presenting with acute monoarthritis involving the foot or ankle [4], while osteoarthritis (OA) of the foot is a significant cause of foot pain among older adults [5,6]. We present a case of a middle-aged man who was treated for acute gout and OA. He presented multiple times to outpatient clinics and Emergency Departments (EDs) with worsening foot pain, and the lack of specific physical findings and laboratory and radiological results led to delays in diagnosis and appropriate management.

## Case Report

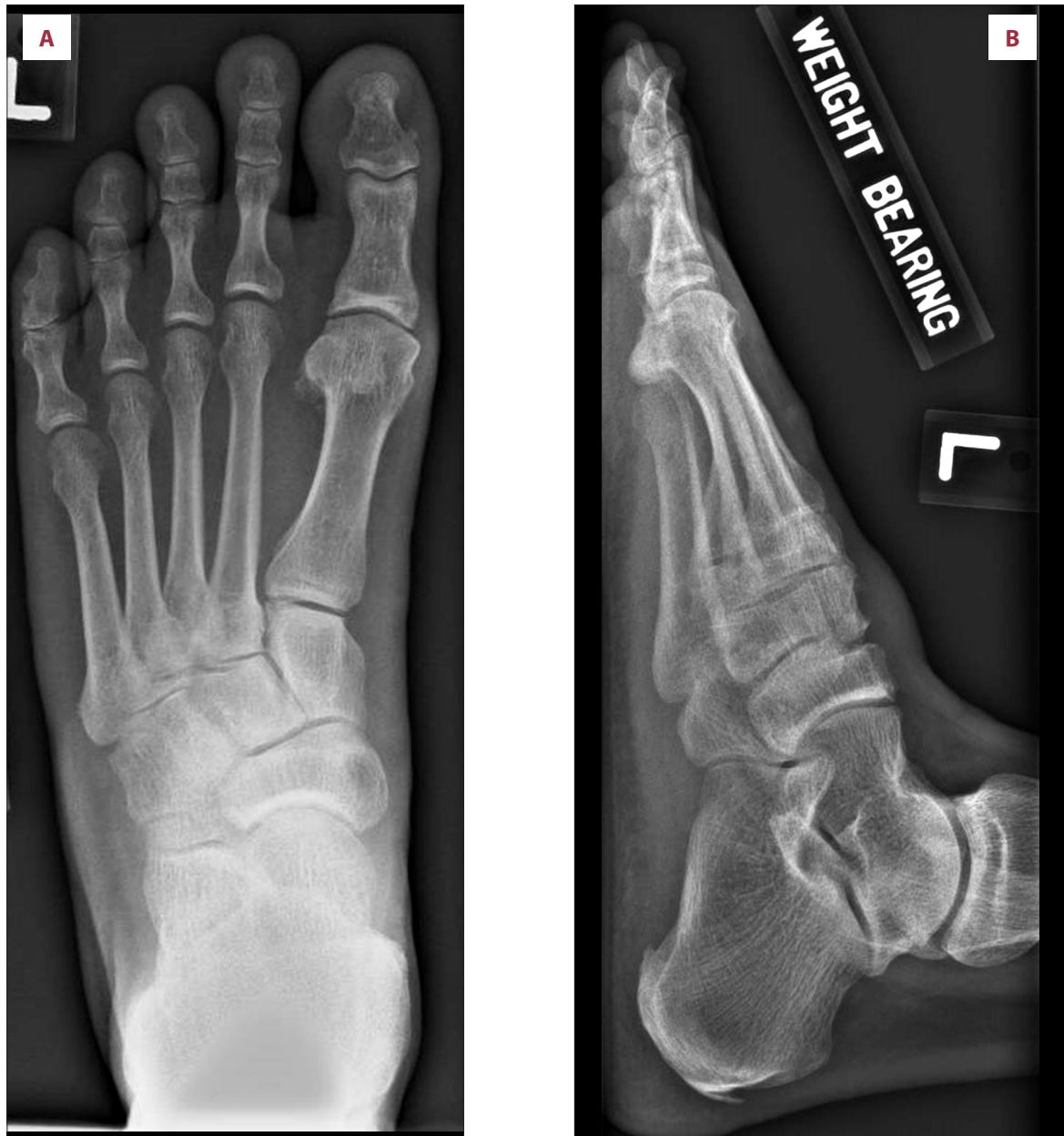A middle-aged man with a past medical history of hypertension and hyperlipidemia presented to our ED owing to severe left foot pain. He had developed sudden-onset, atraumatic mild pain in his left ankle that was worse with movement and ambulation. After 3 days, the pain localized to his left foot. The pain was associated with swelling and redness, which prompted the patient to consult his family physician. There was no fever or other associated symptoms. A provisional diagnosis of gout was made because of the patient's demographic profile and overall clinical presentation. He was prescribed

nonsteroidal anti-inflammatory drugs (NSAIDs) and colchicine, which did not improve his symptoms. After 4 more days, the patient consulted an orthopedic specialist. Magnetic resonance imaging (MRI) of the ankle was done, which showed medial talar and midfoot osteoarthritic changes (Figure 1). Analgesics and observation were again advised. Two weeks from the onset of his symptoms, the patient presented to the ED reporting severe, constant left foot pain that affected his sleep and prevented him from bearing weight on that foot. On examination, his vital signs were normal. The left foot was noted to have generalized swelling, with erythema and significant tenderness over the midfoot. Examination of the ankle was normal, and the plain radiograph of the foot was unremarkable. The clinical impression was OA, and the patient was discharged with NSAIDs. Two days after, he consulted the orthopedic specialist again, and investigations revealed C-reactive protein (CRP) of 60.4 mg/L and a white blood cell count (WBC) of  $7.97 \times 10^9/L$  without neutrophilia. The erythrocyte sedimentation rate (ESR), uric acid, and rheumatoid factor results were normal. A repeat radiograph of the left foot showed mild degenerative changes at the first metatarsophalangeal (MTP) joint (Figure 2). The clinical impression was OA, and the patient was again discharged with analgesics. After 5 more days, he re-presented to our ED owing to persistent severe pain despite medication compliance and was admitted to the Orthopedic Department.

Upon admission, further investigations were performed, which showed WBC  $12.92 \times 10^9/L$ , CRP 136 mg/L, and ESR 62 mm/h. Procalcitonin (PCT), antinuclear antibody, anti-double-stranded DNA antibody, and cyclic citrullinated peptide antibody findings were all normal. No predisposing factors were identified in the patient. His hemoglobin  $A_{1c}$  was 5.7%, and the HIV screen was nonreactive. His blood chemistry showed normal



**Figure 1.** T2-weighted magnetic resonance image of left foot. (A) Sagittal view showing small subchondral cystic changes in the tarsometatarsal joint, compatible with degenerative changes. (B) Coronal view showing mild degenerative changes.

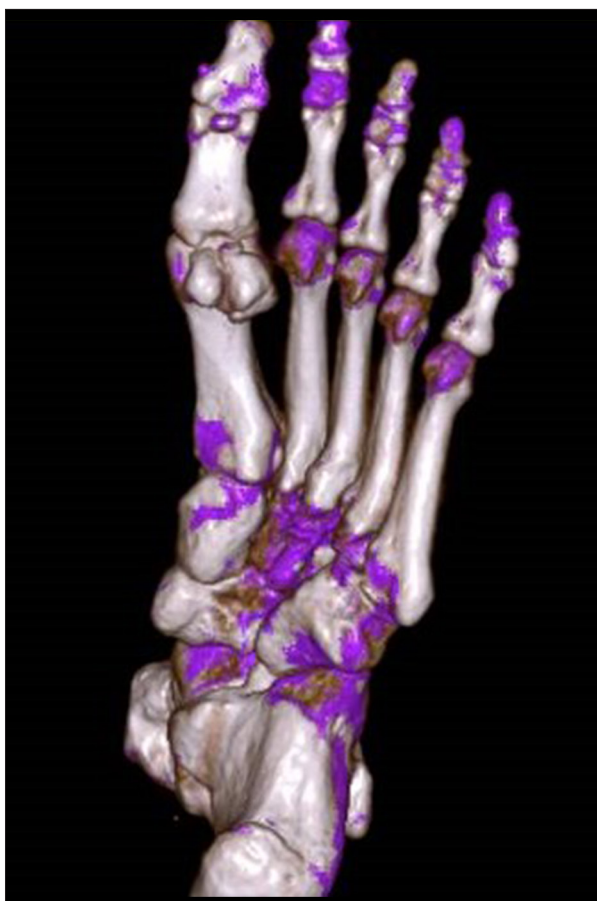

**Figure 2.** Plain radiograph of the left foot showing mild degenerative changes in 1<sup>st</sup> metatarsophalangeal joint. (A) dorsoplantar view, (B) lateral view.

renal and liver function. He did not have constitutional symptoms such as weight loss, night sweats, and anorexia. He was a healthy man with no history of recurrent infections and frequent admissions.

Rheumatology was consulted to rule out crystal arthropathy. Dual-energy computed tomography (CT) of the left foot showed multiple periarticular erosions in the tarsal bones and metatarsal bases with adjacent soft tissue swelling, suspicious for an inflammatory etiology (Figure 3). There was no evidence of monosodium urate (MSU) crystal deposition and

soft tissue calcification. MRI of the foot revealed extensive joint effusion and synovitis involving the second to fifth tarsometatarsal (TMT) joints and intercuneiform joints, with associated extensive periarticular marrow edema and erosions (Figure 4). The patient underwent drainage, washout, debridement, and biopsy of his left second/third TMT joints on day 3 of admission. Intraoperative findings revealed purulent fluid and clumps of debris within the joint. Tissue culture was positive for *Staphylococcus aureus* sensitive to cefazolin, and he was advised to complete a 6-week course of this antibiotic. On day 5 of admission, the patient underwent left foot wound



**Figure 3.** Noncontrast dual-energy computed tomography of the left foot showing the absence of monosodium urate crystal deposition. There are multiple periarticular erosions in the tarsal and metatarsal bases.

debridement and washout of the second/third TMT joint and the medial naviculocuneiform (NC) joint. Intraoperative findings revealed pus within the second TMT joint and medial NC joint and unhealthy synovium and connective tissue. A wound drain was inserted and removed after few days. The patient was eventually transferred to a community hospital, where he completed his intravenous antibiotics and continued his rehabilitation for a month. His inflammatory markers were all normal on discharge. He remained well but returned to the ED after 2 weeks for recurrence of persistent left foot pain. He was admitted again and repeat investigations were done, revealing CRP 54.3 mg/L (baseline 2), WBC  $11 \times 10^9/L$  (baseline 5), and ESR 12 mm/h (baseline 8). A repeat plain radiograph of the foot showed worsening cortical irregularity and lucencies in the anterosuperior aspect of the navicular bone and superior cuneiform (Figure 5). MRI was also repeated and showed interval progression of extensive periarticular marrow edema involving all tarsal bones and TMT joints, with increased bony erosions, especially along the dorsal aspect of the tarsal bones. Other findings included the presence

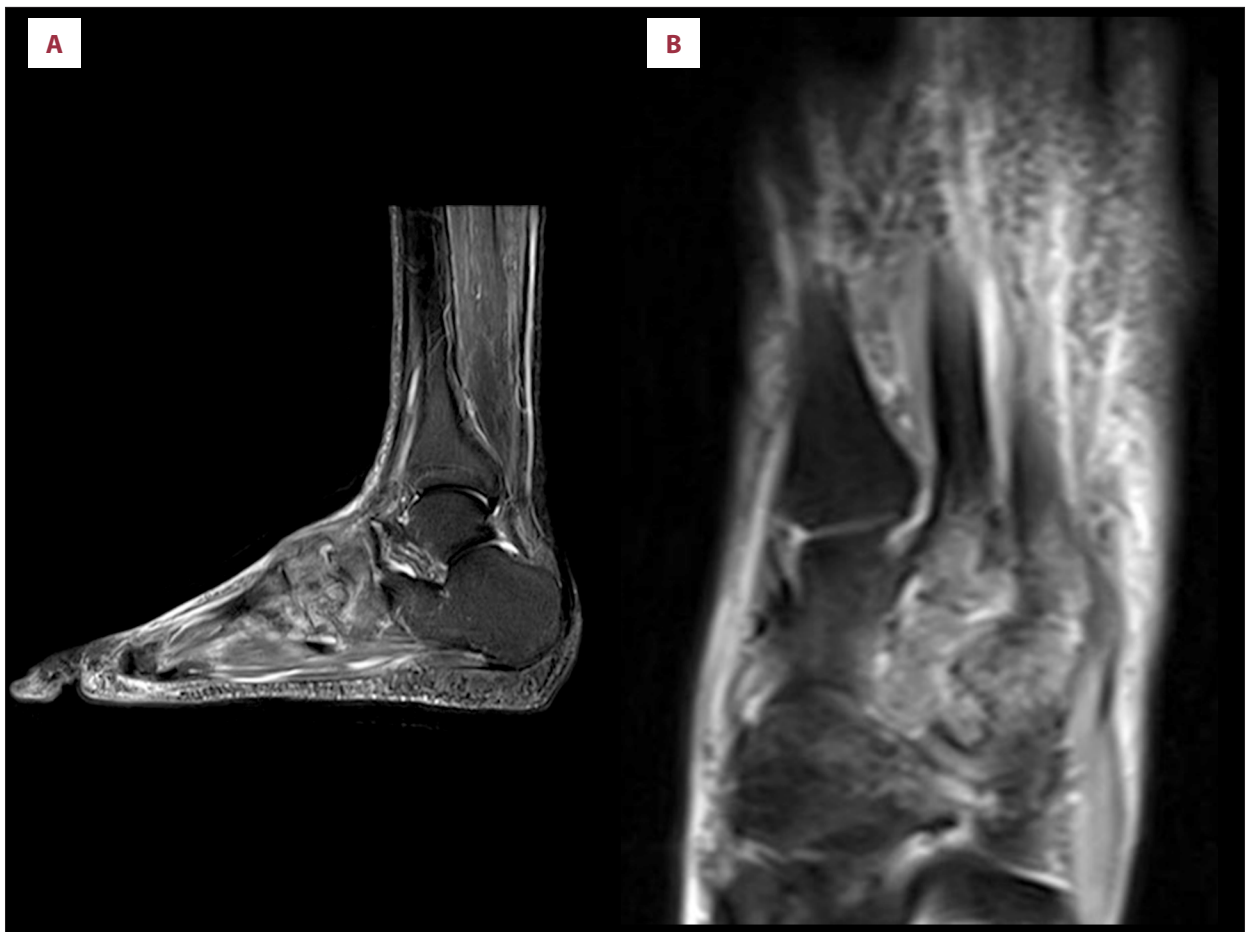of joint effusion and synovitis of the midfoot and the second to fifth TMT joints, with increased surrounding reactive subcutaneous soft tissue, plantar, and interosseous muscular enhancement (Figure 6). An infectious disease specialist was consulted and advised to continuation of intravenous cefazolin for another 6 weeks. Inflammatory markers were regularly monitored and were noted to be in a downward trend after 2 days. The patient was subsequently transferred to a community hospital to complete his intravenous antibiotics. He had an uneventful recovery and was discharged after few weeks. At present, he continues to have intermittent foot pain, and he is still on active follow-up with an orthopedic specialist and the Rehabilitation Department.

## Discussion

Early recognition of SA is important to prevent significant morbidity and mortality in affected patients. The reported incidence varies between studies and ranges between 2 and 60 cases per 100 000 person-years [1,7-9]. Delays in diagnosis and treatment lead to irreversible joint destruction in up to 25-50% of cases, and functional disability has been noted in 25-75% of the survivors [9,10]. Mortality rates of 3-40% have been described [1,7-8]. Patients most commonly present with acute joint pain, swelling, erythema, pain on movement, and decreased range of motion [3,8]. Reported affected areas are often the knee, hip, shoulder, and elbow [3,7,8]. Fever appears to be present in only half of the cases [8,9]. Based on the literature, the most important predisposing factor in native joints is a pre-existing joint disease, and almost half of the patients diagnosed with SA have previous joint conditions [1,3,8]. Immunocompromised states such as diabetes mellitus, cirrhosis, intravenous drug use, end-stage renal disease, and immunosuppressant use are also known risk factors [3,7]. Interestingly, another study showed that 22% of patients diagnosed with SA had no known risk factors [1,3].

SA of the foot is very uncommon, and it comprises only 3-7% of all SA cases reported [11]. Tibiotalar and first MTP joints are typically affected. A case report of primary SA involving the talonavicular joint in a healthy adult was previously published [11]. Our case is unusual because the main joints involved were the intercuneiform and NC joints. To the best of our knowledge, there is no published case report of primary SA involving these joints in an immunocompetent adult. Although the first MRI showed osteoarthritic changes in the midfoot, the patient denied having similar symptoms in the past and he was never diagnosed with OA.

The criterion standard for diagnosing SA is culture-positive synovial fluid or pus aspiration from the joint [1,2,12]. However, synovial gram stain sensitivity has been reported to be as low

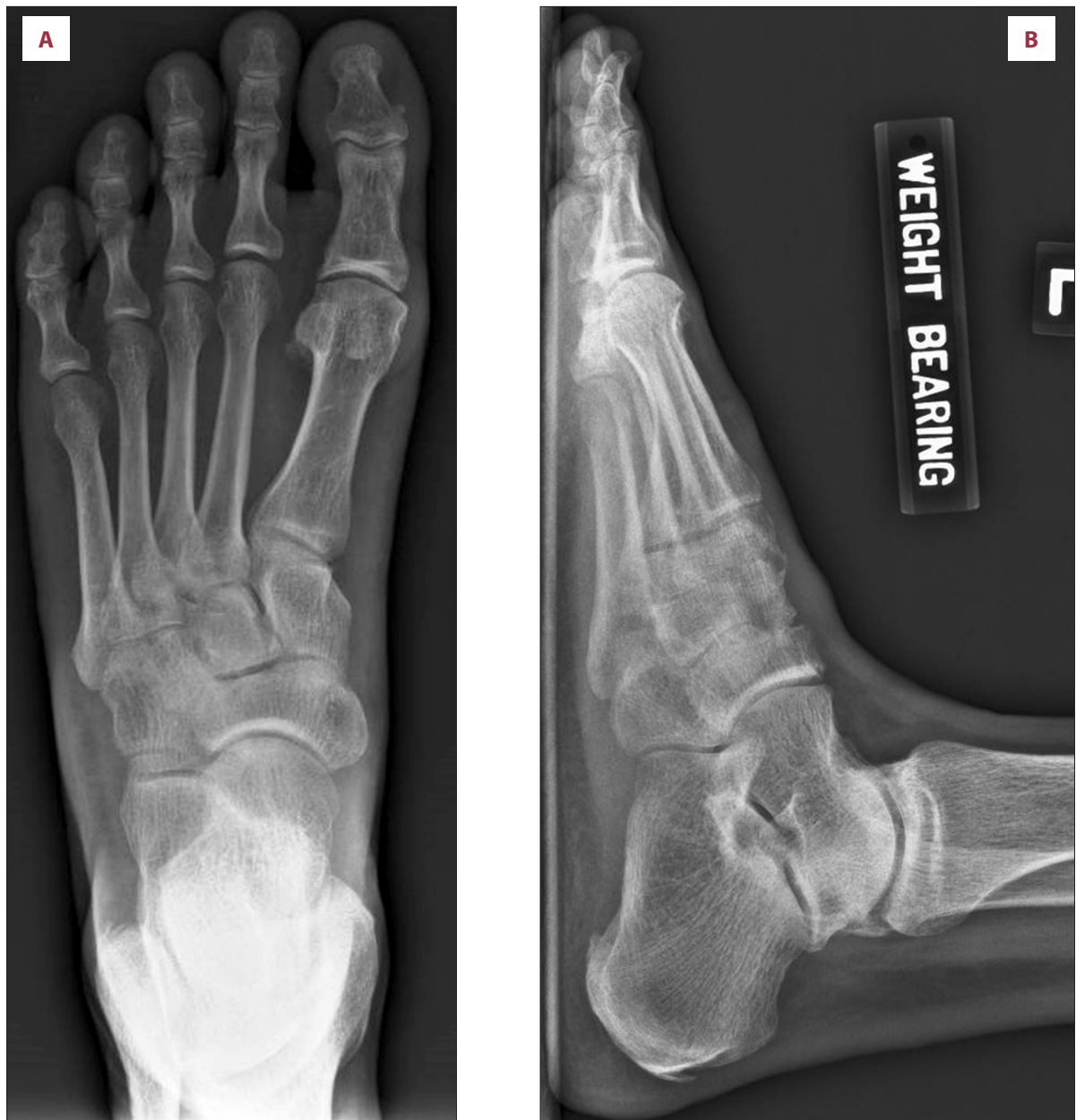

**Figure 4.** Magnetic resonance image T2-weighted of left foot (A) sagittal view of left foot showing mid foot periarticular marrow edema and erosions; (B) axial view showing 2<sup>nd</sup>-3<sup>rd</sup> tarsometatarsal joint effusion, with periarticular marrow edema and erosions.

as 29% [1]. Synovial culture sensitivities vary from 40% to 60% and results require a few days for return. Hence, these tests may not be very helpful in the ED [2]. Serum inflammatory markers such as total WBC, CRP, and ESR are routinely tested in most cases of arthritis, but unfortunately, studies show that these are not reliable in distinguishing infectious from non-infectious causes [3,7]. Recently, PCT has gained much attention as a biomarker for bacterial processes. A study by Maharajan et al [10] shows that PCT levels of more than 0.4 ng/mL represent a sensitive (85.2%) and specific (87.3%) marker for SA and osteomyelitis. A meta-analysis by Zhao et al [13] involving 10 studies demonstrated PCT has a sensitivity of 54% and a specificity of 95%, a positive likelihood ratio (LR) of 10.7, and a negative LR of 0.45. They concluded that PCT was a better diagnostic marker than CRP in differentiating SA from non-SA. Of note, our patient had a normal PCT level, which further complicated the diagnosis of SA and makes this case even more intriguing. It must be remembered that PCT remains low if the cause of SA is local, rather than systemic [7].

Plain radiographs are often performed and considered essential in most cases of arthritis, yet results are usually normal in the early stages [12,14,15]. In addition, they are unable to distinguish SA from other inflammatory conditions. Hence, radiography is not useful in diagnosing SA [2].

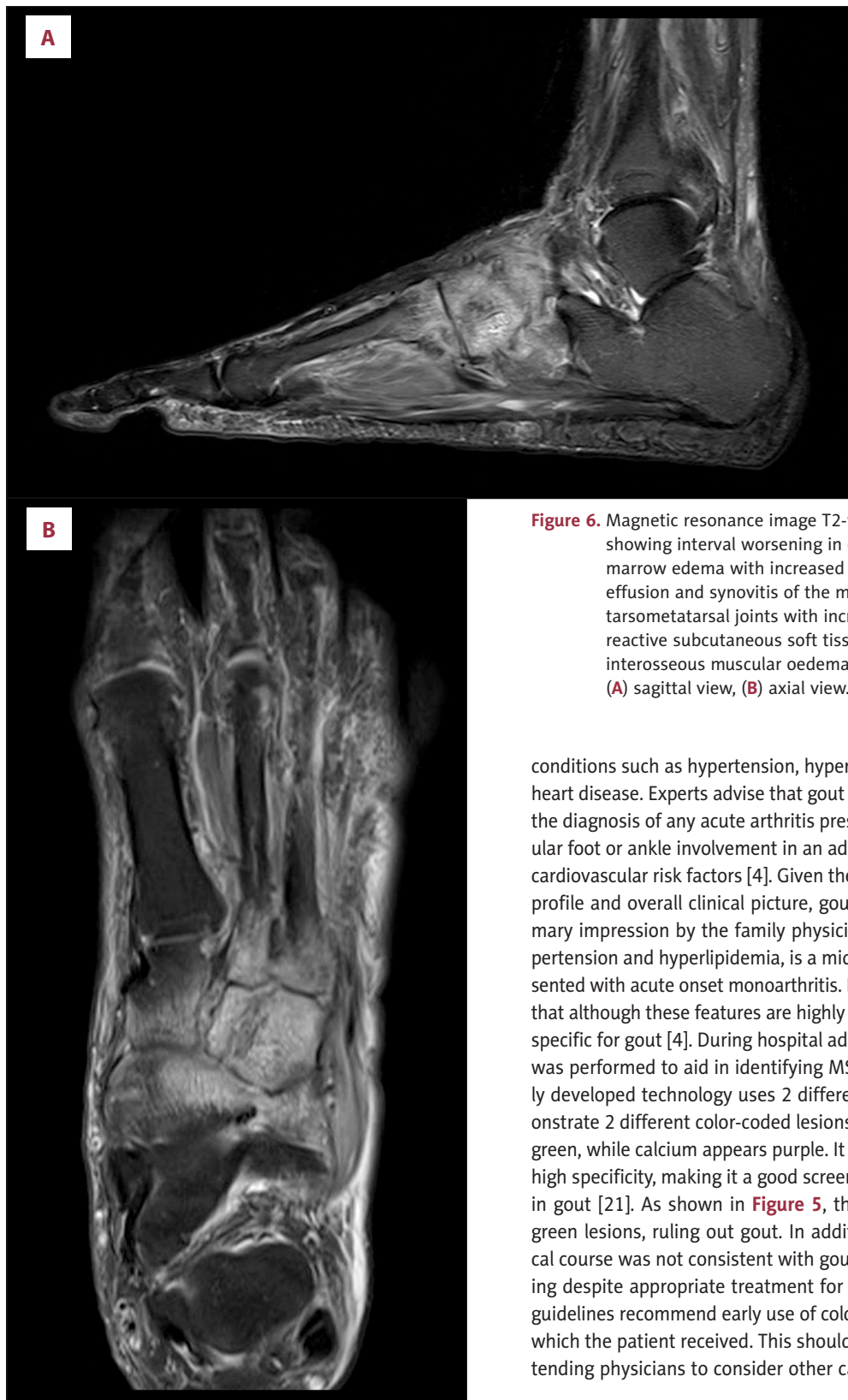CT and MRI generally provide a better joint assessment. While CT offers better visualization of bony details [14], MRI is more sensitive and is the preferred diagnostic imaging procedure for suspected bone and soft tissue infections [12,14-16]. The earliest signs of SA in MRI include synovial inflammation and effusion, while marrow signal abnormalities and bony erosions develop later [8,12,15]. A study by Karchevsky et al [17] showed that among 50 patients with SA, synovial enhancement and perisynovial edema were seen consistently, while joint effusion was observed in only 70% of the patients. In addition, effusion was not evident in half of the small joints; hence, the absence of effusion should not rule out the presence of infection. In our case, the small size of the TMT and NC joints might explain the negative findings in the first MRI.



**Figure 5.** Plain radiograph of the left foot. (A) Dorsoplantar view showing loss of bony densities of the intermediate, lateral cuneiforms and cuboid with narrowing of their tarsal metatarsal joint spaces. (B) Lateral view showing cortical irregularity and lucencies in the anterosuperior aspect of navicular and cuneiform bones.

Furthermore, these findings are also nonspecific and can be seen in noninfectious arthritis [3,12,14,17]. Although abnormalities can be seen as early as 2 days of symptom onset, MRI should be repeated if the clinical suspicion of infection remains high. A recent review by Lim et al [16] explained that MRI findings may lag behind symptoms by 2 weeks. In our case, the initial MRI findings performed about a week after the onset of symptoms were nondiagnostic, while the repeat scan revealed significant joint effusions, bone marrow edema, and periarticular erosions.

Clinical judgment appears to be the most reliable factor in differentiating SA from non-SA joints [3]. In this scenario, the main differential diagnoses are acute gout and OA. An acute gout episode commonly presents with rapid onset monoarticular arthritis, classically involving the first MTP joint. The symptoms are maximal within a day, last for about a week, and in most cases are self-limiting [4,18]. Its prevalence is higher in men and often associated with other comorbidities [4,19,20]. A retrospective study done locally by Koh et al [20] showed that in Singapore, gout mainly affects middle-aged men with chronic



**Figure 6.** Magnetic resonance image T2-weighted of left foot showing interval worsening in extensive peri-articular marrow edema with increased bony erosions. Joint effusion and synovitis of the midfoot and 2<sup>nd</sup> to 5<sup>th</sup> tarsometatarsal joints with increased surrounding reactive subcutaneous soft tissue, plantar and interosseous muscular oedema/enhancement. (A) sagittal view, (B) axial view.

conditions such as hypertension, hyperlipidemia, and ischemic heart disease. Experts advise that gout should be considered in the diagnosis of any acute arthritis presenting with monoarticular foot or ankle involvement in an adult who is male and has cardiovascular risk factors [4]. Given the patient's demographic profile and overall clinical picture, gout was a reasonable primary impression by the family physician. The patient has hypertension and hyperlipidemia, is a middle-aged man, and presented with acute onset monoarthritis. It should be emphasized that although these features are highly suggestive, they are not specific for gout [4]. During hospital admission, dual-energy CT was performed to aid in identifying MSU crystals. This recently developed technology uses 2 different energy rays to demonstrate 2 different color-coded lesions. Urate deposits appear green, while calcium appears purple. It has high sensitivity and high specificity, making it a good screening and diagnostic tool in gout [21]. As shown in **Figure 5**, there was an absence of green lesions, ruling out gout. In addition, the patient's clinical course was not consistent with gout. His pain was worsening despite appropriate treatment for weeks. Most treatment guidelines recommend early use of colchicine and NSAIDs [22], which the patient received. This should have prompted the attending physicians to consider other causes earlier.

Because of the first MRI and plain radiograph results, the subsequent physicians were likely led to believe that the diagnosis

was OA. It is the most common arthritis affecting adults [23-25], yet few studies discuss the involvement of the foot [5,6]. Based on a review by Roddy and Menz [5], the most commonly affected joint in foot OA is the first MTP, followed by the second cuneometatarsal. Symptomatic midfoot OA is known to be present in only about 12% of people aged more than 50 years old and is more common among elderly women [6]. Given the patient's demographic profile, it is doubtful that he had pre-existing mid-foot OA. Although the first MRI showed degenerative changes in the midfoot, the patient denied having similar symptoms in the past and he was never diagnosed with OA. MRI features suggestive of OA typically include the presence of joint space narrowing, osteophytes, effusion/synovitis, bony erosions, and bone marrow lesions [26]. While there is no finding specific for OA, Halstead et al [26] proposed a scoring system using these MRI features to evaluate foot OA. They reported excellent inter-reader reliability scores for joint space narrowing, osteophytes, and cysts, but lower scores for bony erosions, bone marrow lesions, and effusion. This highlights the difficulty in interpreting MRI of the foot because of its inherent anatomical complexity [14,26].

The question remains as to whether this case was primary osteomyelitis that was missed in the first MRI and subsequently complicated by secondary arthritis. We speculate that this is unlikely because MRI is highly sensitive and can identify bone marrow edema as early as 1-2 days after the onset of infection [16]. Negative findings can essentially rule out the presence of osteomyelitis [15]. However, we recognize that a delay in radiologic findings is still a small possibility. In this regard, nuclear medicine could have been considered as an adjunct diagnostic test. While other imaging demonstrates anatomical changes, nuclear imaging shows the physiologic state and bone metabolism. As early as 2-3 days from the onset of infection, a triple-phase bone scan can show the presence of increased focal uptake indicating osteomyelitis [15,27]. In this case, if the patient had primary osteomyelitis, nuclear imaging would have identified an early reactive or infectious activity. Nevertheless, findings are also not specific for infection and it is more useful in ruling out osteomyelitis when results are negative [15,27]. If results are unclear, a gallium scan can be utilized because it offers higher specificity [28]. Gallium 67 citrate is a traditional radiotracer that easily associates with transferrin. In areas of infection, blood flow and vascular permeability are increased, which leads to higher gallium deposition. Its application has been replaced by labeled leucocyte scintigraphy, which is presently considered to be the radionuclide criterion standard for diagnosis of osteomyelitis [27-29]. Patients' WBCs are labeled in vitro with indium-111 or 99mTc-exametazime (99mTc-HMPAO) and returned intravenously. Increased uptake is observed in the presence of infection. Physiologic uptake is also expected in bone marrow; hence, this is commonly complemented with Tc-sulfur colloid imaging [28,29]. Disadvantages include limited spatial resolution, labor-intensive procedures,

and prolonged results [27-29]. The enhanced images obtained from single photon emission computed tomography (SPECT)/CT hybrid augments the diagnostic accuracy and refines the anatomic definition and localization [27,30,31]. A study by Arican et al [31] showed that SPECT/CT changed the evaluation of osteomyelitis in 16.5% of their patients. Currently, nuclear medicine is recommended when MRI is contraindicated or infection is multifocal [15,16,27,28]. Moreover, nuclear imaging has limited value in diagnosing SA. Triple-phase bone scan, gallium, and indium scintigraphy are all unreliable in distinguishing infectious from inflammatory arthritis [15,27].

Although the CRP level was increased at the second orthopedic consult, this test is not specific for infection. Multiple studies now support the "inflammatory" theory as driving the OA process, and increased CRP is considered by some studies to be associated with OA [23-25]. Clinically, OA presents with gradual onset of pain with stiffness; it is associated with remitting and relapsing symptoms. Its pain is generally worse on activity, especially following a period of rest [32]. Given the patient's acute presentation with no previous episodes of foot pain, the diagnosis of OA should have been questioned.

Ideal management of SA primarily involves broad-spectrum antibiotics as soon as synovial fluid samples are collected, and early orthopedic consult for surgical management [1-3,8,12]. Open and arthroscopic techniques can be utilized to drain the infected joint and eliminate the purulent material [1,8]. Aside from decompression, drainage also helps in improving blood flow and removing toxins [2]. Intravenous antibiotics are generally continued for 3-4 weeks [1,8,12]. It must be emphasized that the first step is rapid recognition of SA in any patient presenting with acutely inflamed joint

Overall, a few factors contributed to the delay in diagnosing SA in this case. First, SA of the midfoot is extremely rare even for immunocompromised patients. In addition, the nondiagnostic initial plain radiograph and MRI findings, coupled with seemingly acceptable serum markers, may have given a false reassurance for ruling out an infectious cause.

This case serves as a reminder that a high index of suspicion is required in the early diagnosis of SA of small joints. Laboratory tests and imaging studies are now readily available to aid in diagnostic uncertainties, but proper clinical evaluation continues to play a vital role in clinching the correct diagnosis. Symptoms such as unremitting pain for 1 week despite analgesics, inability to bear weight, and pain affecting sleep are concerning for SA; these patients warrant a close follow-up regardless of unremarkable laboratory and imaging results. It is important to acknowledge that radiologic findings may lag behind the onset of symptoms and repeat diagnostic tests are needed in the presence of concerning symptoms.



## Conclusions

SA of the midfoot is rare but needs to be considered in any patient presenting with worsening symptoms after more than 1 week of anti-inflammatory medications. Laboratory and radiological investigations have limitations and should be guided by appropriate clinical findings and judgment. It is important to maintain a high index of suspicion for these cases to prevent morbidity and mortality in patients.

## References:

1. Long B, Koymfman A, Gottlieb M. Evaluation and management of septic arthritis and its mimics in the emergency department. *West J Emerg Med.* 2019;20(2):331-41
2. Wang DA, Tambyah PA. Septic arthritis in immunocompetent and immunosuppressed hosts. *Best Pract Res Clin Rheumatol.* 2015;29:275-89
3. Ross J. Septic arthritis of native joints. *Infect Dis Clin N Am.* 2017;31:203-18
4. Richette P, Doherty M, Pascual E, et al. 2018 Updated European League Against Rheumatism evidence-based recommendations for the diagnosis of gout. *Ann Rheum Dis.* 2020;79:31-38
5. Roddy E, Menz HB. Foot osteoarthritis: Latest evidence and developments. *Ther Adv Musculoskelet Dis.* 2018;10(4):91-103
6. Thomas MJ, Peat G, Rathod T, et al. The epidemiology of symptomatic mid-foot osteoarthritis in community-dwelling older adults: Cross-sectional findings from the Clinical Assessment Study of the Foot. *Arthritis Res Ther.* 2015;17(1):178
7. Carpenter C, Schuur J, Everett W, Pines J. Evidence-based diagnostics. Adult septic arthritis. *Acad Emerg Med.* 2011;18(8):781-96
8. Horowitz DL, Katzap E, Horowitz S, Barilla-LaBarca ML. Approach to septic arthritis. *Am Fam Physician.* 2011;84(6):653-60
9. Ferrand J, El Samad Y, Brunschweiler B, et al. Morbimortality in adult patients with septic arthritis: a three-year hospital based study. *BMC Infect Dis.* 2016;16:239
10. Maharajan K, Patro DK, Menon J, et al. Serum procalcitonin is a sensitive and specific marker in the diagnosis of septic arthritis and acute osteomyelitis. *J Orthop Surg Res.* 2013;8:19
11. Matar HE, Iyengar KP, Toh EM. Primary septic arthritis of talonavicular joint. *BMJ Case Rep.* 2014;2014:bcr2013203346
12. Garcia-Arias M, Balsa A, Mola EM. Septic arthritis. *Best Pract Res Clin Rheumatol.* 2011;25(3):407-21
13. Zhao J, Zhang S, Zhang L, et al. Serum procalcitonin levels as a diagnostic marker for septic arthritis: A meta-analysis. *Am J Emerg Med.* 2017;35:1166-71
14. Wilkinson V, Rowbotham E, Grainger A. Imaging in foot and ankle arthritis. *Semin Musculoskelet Radiol.* 2016;20(02):167-74
15. Beaman FD, von Herrmann PF, Kransdorf MJ, et al. ACR Appropriateness Criteria® suspected osteomyelitis, septic arthritis, or soft tissue infection (excluding spine and diabetic foot). *J Am Coll Radiol.* 2017;14(5):S326-37
16. Lim W, Barras CD, Zadow S. Radiologic mimics of osteomyelitis and septic arthritis: A pictorial essay. *Radiol Res Pract.* 2021;2021:9912257
17. Karchevsky M, Schweitzer ME, Morrison WB, Parellada JA. MRI findings of septic arthritis and associated osteomyelitis in adults. *Am J Roentgenol.* 2004;182(1):119-22
18. Rothenbacher D, Primates P, Ferreira A, et al. Frequency and risk factors of gout flares in a large population-based cohort of incident gout. *Rheumatology (Oxford).* 2011;50(5):973-81
19. Liang J, Jiang Y, Huang Y, et al. Comorbidities and factors influencing frequent gout attacks in patients with gout: A cross-sectional study. *Clin Rheumatol.* 2021;40(7):2873-80
20. Koh WH, Seah A, Chai P. Clinical presentation and disease associations of gout: A hospital-based study of 100 patients in Singapore. *Ann Acad Med Singap.* 1998;27(1):7-10
21. Jayakumar D, Sehra ST, Anand S, et al. Role of dual energy computed tomography imaging in the diagnosis of gout. *Cureus.* 2017;9(1):e985
22. Li Q, Li X, Wang J, et al. Diagnosis and treatment for hyperuricemia and gout: A systematic review of clinical practice guidelines and consensus statements. *BMJ Open.* 2019;9(8):e026677
23. Nguyen LT, Sharma AR, Chakraborty C, et al. Review of prospects of biological fluid biomarkers in osteoarthritis. *Int J Mol Sci.* 2017;18(3):601
24. Zhang J. Meta-analysis of serum C-reactive protein and cartilage oligomeric matrix protein levels as biomarkers for clinical knee osteoarthritis. *BMC Musculoskelet Disord.* 2018;19(1):22
25. Jin X, Beguerie JR, Zhang W, et al. Circulating C reactive protein in osteoarthritis: A systematic review and meta-analysis. *Ann Rheum Dis.* 2015;74(4):703-10
26. Halstead J, Martín-Hervás C, Hensor EMA, et al. Development and reliability of a preliminary foot osteoarthritis magnetic resonance imaging score. *J Rheumatol.* 2017;44(8):1257-64
27. Seltzer A, Xiao R, Fernandez M, Hafisja R. Role of nuclear medicine imaging in evaluation of orthopedic infections, current concepts. *J Clin Orthop Trauma.* 2019;10(4):721-32
28. Lee YJ, Sadigh S, Mankad K, Kapse N, Rajeswaran G. The imaging of osteomyelitis. *Quant Imaging Med Surg.* 2016;6(2):184-98
29. Palestro CJ, Glaudemans AWJM, Dierckx RAJO. Multiagent imaging of inflammation and infection with radionuclides. *Clin Transl Imaging.* 2013;1(6):385-96
30. Israel O, Pellet O, Biassoni L, et al. Two decades of SPECT/CT – the coming of age of a technology: An updated review of literature evidence. *Eur J Nucl Med Mol Imaging.* 2019;46(10):1990-2012
31. Arıcan P, Okudan B, Şefizade R, Naldöken S. Diagnostic value of bone SPECT/CT in patients with suspected osteomyelitis. *Mol Imaging Radionucl Ther.* 2019;28(3):89-95
32. Abhishek A, Doherty M. Diagnosis and clinical presentation of osteoarthritis. *Rheum Dis Clin N Am.* 2013;39(1):45-66

## Declaration of Figures' Authenticity

All figures submitted have been created by the authors who confirm that the images are original with no duplication and have not been previously published in whole or in part.