

Protective Effect of the Methanolic Extract of *Malva parviflora* L. leaves on Acetic Acid-induced Ulcerative Colitis in Rats

Aisha Dugani, Bushra Dakhil, Soad Treesh¹

Departments of Pharmacology and Clinical Pharmacy and ¹Histology and Medical Genetic, University of Tripoli, Tripoli, Libya

Address for correspondence:

Dr. Aisha Dugani,
Department of Pharmacology and Clinical Pharmacy, Faculty of Pharmacy, University of Tripoli, Tripoli, Libya.
E-mail: aishamohamed_33@hotmail.com

ABSTRACT

Background/Aims: Inflammatory bowel disease (IBD) is a general term describing chronic, idiopathic relapsing, inflammatory conditions of the gastrointestinal tract of unknown etiology. Previous studies have indicated that *Malva parviflora* leaf extract possesses anti-inflammatory, antioxidant, and antiulcerogenic activity. This work aimed to investigate the anti-inflammatory effect of the methanolic (MEMP) and aqueous (AEMP) extracts of *M. parviflora* leaves on acetic acid-induced colitis in rats. **Materials and Methods:** 42 male Wistar albino rats were divided into seven groups ($n = 6$). Group I: Normal saline control group with no colitis; Group II: Acetic acid colitis group; Group III: 100 mg/kg/5 d MEMP; Group IV: 200 mg/kg/5 d MEMP; Group V: 100 mg/kg/5 d AEMP; Group VI: 200 mg/kg/5 d AEMP; Group VII: Prednisolone group (2 mg/kg/5 d). Treatments were followed by induction of colitis using intrarectal instillation of 2 mL of 4% acetic acid. Colon damage was evaluated macroscopically (spleen weight/body weight, colon weight/length ratio) and the histological changes were also recorded. **Results:** The results of this study showed that acetic acid caused severe inflammation of the colon and a significant increase in spleen weight/body weight, and an increase in colon weight/length ratio compared with normal control group. Pretreatment with MEMP and AEMP for 5 days followed by induction of colitis resulted in a significant attenuation of spleen weight and colon weight/length ratio compared with acetic acid control group. Methanolic extract provided better anticolitic effect than aqueous extract; the effect was prominent at the dose of 200 mg/kg. Histopathological findings confirmed the protective effect of the MEMP. **Conclusion:** In conclusion, MEMP could ameliorate mucosal damage in experimentally induced colitis when given orally.

Key Words: Acetic acid-induced colitis, anti-inflammatory, *Malva parviflora*, ulcerative colitis

Received: 16.09.2015, Accepted: 24.12.2015

How to cite this article: Dugani A, Dakhil B, Treesh S. Protective effect of the methanolic extract of malva parviflora l. leaves on acetic acid-induced ulcerative colitis in rats. Saudi J Gastroenterol 2016;22:226-33.

Ulcerative colitis (UC) is a common form of inflammatory bowel disease (IBD) characterized by a diffuse mucosal inflammation of the colon and rectum. The exact cause of the disease is not completely understood; however, a combination of genetic and environmental factors are thought to play a crucial role in its pathogenesis.^[1] The pathological findings associated with UC include the following: An increase in inflammatory mediators such as prostaglandins (PG) and leukotrienes (LT), which are produced from arachidonic acid.

Clinical and experimental studies have confirmed that the levels of prostaglandin E₂, thromboxane A₂, prostacyclin, and especially LTB₄ during colonic inflammation were highly increased.^[2] Other contributing factors include: Oxidative stress, altered colonic milieu, abnormal mucosal content of glycosaminoglycan (GAG), decreased oxidation of short chain fatty acids (SCFAs), increased intestinal permeability, increased sulfide production, and decreased methylation.^[1]

Pharmacological management of IBD including UC is based on using drugs such as sulphasalazine (SSZ), 5-aminosalicylic acid (5-ASA), corticosteroids, immunomodulator drugs [azathioprine (AZA) and methotrexate (MTX)],

This is an open access article distributed under the terms of the Creative Commons Attribution-NonCommercial-ShareAlike 3.0 License, which allows others to remix, tweak, and build upon the work non-commercially, as long as the author is credited and the new creations are licensed under the identical terms.

For reprints contact: reprints@medknow.com

Access this article online	
Quick Response Code: 	Website: www.saudijgastro.com
	DOI: 10.4103/1319-3767.182459

6-mercaptopurine (6-MP), calcineurin inhibitors (cyclosporin and tacrolimus), and anti-TNF- α antibodies (infliximab, adalimumab, and certolizumab). The choice of treatment depends on the clinical goal (induction or maintenance of remission), extent and severity of disease, response to current or prior medication, and the presence of complications.^[3]

Traditionally, folk medicine is used in many countries to control the symptoms of IBD including UC. Several experimental and clinical studies have confirmed the ability of many natural products to relieve UC including: *Aloe vera*,^[4] *Boswellia serrata gum resin*,^[5,6] *Ginkgo biloba*,^[7,8] *Liquorice*,^[9] fenugreek,^[10] *Curcumin*,^[11] *Psyllium*,^[12] *Triticum aestivum*,^[13] *Zingiber officinale*,^[14] and Green tea (*Camellia sinensis*).^[15] Marine and botanical oils (fish oil and olive oil) have also demonstrated beneficial effects in prophylaxis and treatment of IBD.^[16-19]

M. parviflora is an annual or perennial herb, up to 10–30 cm tall, native to North Africa, Europe, Asia, and elsewhere. Raw leaves have a mild pleasant flavor; they make a very acceptable alternative to lettuce in salads.^[20] In Libya, because of its widespread availability, *M. parviflora* leaves and fruit have been used as a survival food during the years of famine and war where it was cooked as a soup or a stew and served with bread.

M. parviflora leaf extracts possess anti-inflammatory, analgesic, antioxidant, neuroprotective, antibacterial, and antifungal activities.^[21-24] The leaves are used in drawing swollen, inflamed purulent wounds. Hexane extract of *M. parviflora* leaves can efficiently inhibit insulin resistance, lipid abnormalities, and oxidant stress.^[25] Decoction from aerial parts of *M. parviflora* showed antiulcerogenic activity against ethanol-induced gastric ulcer model in rats.^[26] Successive solvent extraction method using petroleum ether, chloroform, and methanol have showed a counter-irritant effect on rabbit's ear with the petroleum ether fraction of *M. parviflora* exhibiting the prominent counter-irritant potential.^[27]

This study was aimed to evaluate the effects of pretreatment with the methanolic and aqueous extracts of *M. parviflora* L. on acetic acid-induced colitis in rats by assessing both the macroscopic and microscopic parameters.

MATERIALS AND METHODS

Plant collection and preparation of the extracts

The fresh plant of *M. parviflora* was collected from the city of Sebha, South of Libya, in March 2014. Leaves were separated from their stem, washed with water, and then shade dried at room temperature for at least two weeks. After that, they were crushed to get a homogenous fine powder using

a home blender and then kept in an air tight container in a dry place at room temperature until used to prepare the different extracts.

Animals

In all experiments, healthy male Wistar albino rats weighing 120–150 g were used. They were randomly allocated to groups of six rats each. The animals were housed in the animal care facility in the Department of Pharmacology and Clinical Pharmacy and maintained at 23°C with a 12:12 h light: Dark cycle. All rats were fasted for 24 h prior to the experimental procedure. The study was approved by the Faculty of Pharmacy and the experiments were done according to the ethics guidelines of the University of Tripoli.

Drugs and chemicals

Acetic acid, (WINLAB, Leicestershire, United Kingdom) and Gupisone tablet (Julphar, Gulf Pharmaceutical Industries, Ras Al Khaimah, UAE) containing 5 mg prednisolone was crushed into fine powder and suspended in 0.5% sodium CMC from this solution, and the corresponding doses were administered to animals in the reference standard group. Ketamine hydrochloride injection was obtained from Rotexmedica (Tittau, Germany). Lubricating gel was obtained from Joy Division International AG-Hannover, Germany, formaldehyde was obtained from BDH Chemicals Ltd, Poole, England, and polypropylene catheter from Greetmed, Ningbo, China.

Preparation of the methanolic extract of *M. parviflora* L

Ten grams of powdered leaves of *M. parviflora* were placed in a flask with 500 mL of methanol, and the mixture was then extracted by agitation for 5 h at 25°C. Then, a maceration of the extracts was done overnight for 24 h. After that, the methanolic layer containing the extract was taken. The extraction was repeated on the remaining amount of the precipitate using 150 mL of methanol, and all extracts were filtered by using a 0.45 millipore filter paper. The two fractions of extracts were mixed together and then concentrated using a rotary evaporator at 40°C under reduced pressure.^[28] The yield was found to be equal to 1.12 g (11.2%). Fresh solutions of MEMP were prepared using 0.5% carboxymethyl cellulose (CMC) as a vehicle.

Preparation of the aqueous extract of *M. parviflora* L

Ten grams of powdered leaves of *M. parviflora* were placed in a flask with 500 mL of distilled water, and the mixture was then extracted by agitation for 5 h at 25°C. Then, a maceration of the extracts was done overnight for 24 h. After that, the aqueous layer containing the extract was taken. The extraction was repeated on the remaining amount of the precipitate using 150 mL of distilled water and all extracts were filtered by using a 0.45 millipore filter paper.

The two fractions of extracts were mixed together, frozen, and lyophilized.^[28]

The yield was found to be equal to 1.9 g (19%). The lyophilized extract was stored in air tight containers at room temperature. Solutions of AEMP were prepared using 0.5% CMC as a vehicle.

Preliminary phytochemical screening

Both extracts were evaluated for the presence of alkaloids, flavonoids, saponins, coumarins, cardiac glycosides, anthraquinones, and phenolic glycosides using standard procedures.^[29]

Acute toxicity testing

Swiss albino mice of either gender, weighing between 20 and 25 g were used for toxicity study. Median lethal dose or LD50, is the lethal dose that kills 50% of population tested and is estimated as antilog of the geometric mean of lowest dose showing death and highest dose showing no death. For both extracts it was estimated using Locke's method.^[30] LD50 values were 1.995 and 2.818 mg/kg for the methanolic and aqueous extracts, respectively (usually 1/10 LD50 as maximum dose and lower doses may be tested).

Dosages of *M. parviflora* extract and standard drugs used

The freshly prepared aqueous and methanolic solutions of *M. parviflora* were administered to animals orally for 5 days in two different dosages (100 and 200 mg/kg/d).^[21] On 8th day, the colitis was induced by intrarectal administration of acetic acid. The drug treatment was continued even after administration of acetic acid. Prednisolone was used as the standard drug. Prednisolone was not given as pretreatment. Prednisolone was administered at a dose of 4 mg/kg/d IP, for 3 d). Prednisolone and acetic acid treatment was started on the same day.

Induction of colitis and treatment protocols

Colitis was induced in rats by intrarectal (IR) administration of acetic acid (AA). After anesthetization with ketamine in a dose of 75 mg/kg injected intraperitoneally, a soft 6F polypropylene catheter lubricated with jelly was inserted 6–8 cm via the anal canal into the colon. Two milliliter of AA (4% vol/vol in 0.9% saline) was slowly infused into the distal colon, and rats were maintained in a head-down position for 30 s to limit the expulsion of the solution.^[31]

The study comprised of seven groups of animals of six animals each according to the following protocol:

Group I: Normal control animals (received 1 mL/d of 0.5% CMC, p.o. for 5 days); **Group II:** Acetic acid control animals (received 1 mL/d of 0.5% CMC, p.o. for

5 days); **Group III:** MEMP (100 mg/kg) treated animals (received 5 days pretreatment with 100 mg/kg of MEMP, p.o.); **Group IV:** MEMP (200 mg/kg) treated animals (received 5 days pretreatment with 200 mg/kg of MEMP, p.o.); **Group V:** AEMP (100 mg/kg) treated animals (received 5 days pretreatment with 100 mg/kg of AEMP, p.o.); **Group VI:** AEMP (200 mg/kg) treated animals (received 5 days pretreatment with 200 mg/kg of AEMP, p.o.); and **Group VII:** Prednisolone-treated group, which received prednisolone (2 mg/kg, p.o. for 5 days).

On the 5th day, animals were fasted overnight and acetic acid-induced colitis was performed the next morning in groups II, III, IV, V, VI, and VII by administration of 2 mL of 4% acetic acid solution intrarectally (IR).

Group I received 2 mL of 0.9% normal saline IR instead. Solutions from extracts were freshly prepared as suspensions in 0.5% sodium CMC.

Assessment of the effect of treatment on colonic damage

Assessment of treatment on spleen weight

The spleen from each animal was removed and weighed. Weight was expressed as spleen weight (g)/body weight (g) × 100.

Assessment of treatment on colon weight/length ratio

The distal 5–7 cm segment of the colon was removed from each animal, weighed, and expressed as weight (g)/length (cm).

Histopathological evaluation

Pieces of colonic specimens were fixed in 10% formalin and embedded in paraffin, and 5 µm sections were prepared. Tissues were routinely stained with hematoxylin and eosin (H and E) and were evaluated for the appearance of mucosa and submucosa layers by light microscopy. The evaluation was done by a pathologist who was not informed about the treatment protocols.

Stained sections were examined under light microscope for any inflammatory changes including inflammatory cell infiltration, loss of mucosal architecture, absence or presence of goblet cells, epithelial erosion, edema, and necrotic foci.

Statistical analysis

Data are expressed as mean ± S.E.M. Statistical calculations were done with SPSS 16.0 software package. Comparison between two groups was performed using Student's *t*-test and comparison between more than two groups was carried using one-way analysis of variance (ANOVA). Differences were considered significant when the degree of confidence was 95% or better ($P < 0.05$).

RESULTS

Preliminary phytochemical screening

The results of phytochemical screening of the methanolic and aqueous extracts of *M. parviflora* are summarized in Table 1.

Acetic acid-induced colitis

Intrarectal installation of 2 mL (4%) acetic acid in rats induced a severe inflammatory reaction as evidenced by the gross macroscopic ulceration. Pretreatment with the methanolic extract and to a lesser extent with the aqueous extracts of *M. parviflora* resulted in amelioration of inflammation [Figure 1].

Effect of pretreatment with the MEMP and AEMP extracts on spleen weight

In this study, rats with acetic acid-induced colitis showed a spleen enlargement, the ratio of percentage of spleen to body weight (0.40 ± 0.01) as compared with control treated with the vehicle and given saline enema (0.23 ± 0.01), $P < 0.001$. Pretreatment with MEMP (100 and 200 mg/kg) for 5 days resulted in a significant, dose-dependent reduction in spleen weight/body weight ratio compared with acetic acid control group (0.33 ± 0.02 , 0.27 ± 0.01 , and 0.40 ± 0.01 respectively), ($P < 0.05$ and $P < 0.001$, respectively). The higher dose of 200 mg/kg MEMP extract produced a significant ($P < 0.05$) reduction in the ratio compared with the lower dose of 100 mg/kg (0.27 ± 0.01 and 0.33 ± 0.02 , respectively).

Pretreatment with AEMP (200 mg/kg) for 5 days also resulted in a significant reduction in spleen weight/body weight as compared with the control acetic acid group (0.30 ± 0.01) and (0.40 ± 0.01), 0.01 respectively, and $P < 0.01$). The dose of 100 mg/kg AEMP reduced, although insignificantly, the ratio of spleen/body weight compared with acetic acid-treated group. No significant difference was noted in the ratio among the group of rats pretreated with AEMP 100 and 200 mg/kg (0.34 ± 0.02 and 0.30 ± 0.01 , $P = 0.12$).

Table 1: Phytochemical analysis of the leaves of *Malva parviflora* extracts

Phytoconstituents	Methanolic extract	Aqueous extract
Alkaloids	-ve	-ve
Saponins	-ve	+ve
Antraquinones	+ve	+ve
Glycosides	+ve	+ve
Tannins	-ve	+ve
Flavonoids	+ve	+ve
Coumarins	+ve	+ve

+ve: Present, -ve: Absent

The standard drug prednisolone produced a highly significant reduction in spleen/body weight compared with acetic acid colitis group [(0.25 ± 0.02) and (0.40 ± 0.01)], ($P < 0.001$).

Spleen/body weight ratios in the MEMP (100 mg/kg) and AEMP (100 mg/kg) were significantly higher compared with the prednisolone group [(0.33 ± 0.02) , (0.34 ± 0.02) , and (0.25 ± 0.02)], ($P < 0.05$ and $P < 0.01$), respectively] compared with the prednisolone group [Figure 2] as previously described above.

Effect of pretreatment with the MEMP and AEMP extracts on colon weight/length ratio

The colon weight/length ratio was found to be significantly increased in the acetic acid colitis group compared with the normal saline group (0.50 ± 0.02) and (0.19 ± 0.01), ($P < 0.001$).

MEMP (100 and 200 mg/kg) and AEMP (100 and 200 mg/kg) produced a highly significant (0.00) reduction in the colon weight/length ratio as compared with acetic acid colitis group (0.14 ± 0.00 , 0.12 ± 0.00 , 0.15 ± 0.00 , 0.15 ± 0.00 , and 0.50 ± 0.02 , respectively). The reduction in colon weight/length ratio using MEMP in the dose of 200 mg/kg

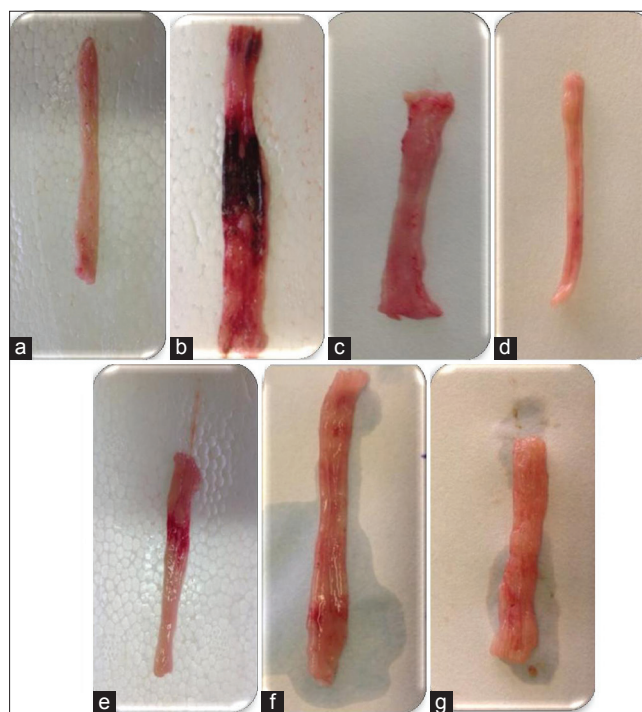


Figure 1: Representative photographs of rats' colon, showing severe colonic lesions with inflammation and bleeding in acetic acid colitis group. (a) Normal control, (b) colitis group, (c and d) MEMP (100 and 200 mg/kg/5 d) followed by AA-induced colitis, (e and f) AEMP (100 and 200 mg/kg/5 d) followed by AA-induced colitis, (g) standard control prednisolone (2 mg/kg/5 d) followed by AA-induced colitis

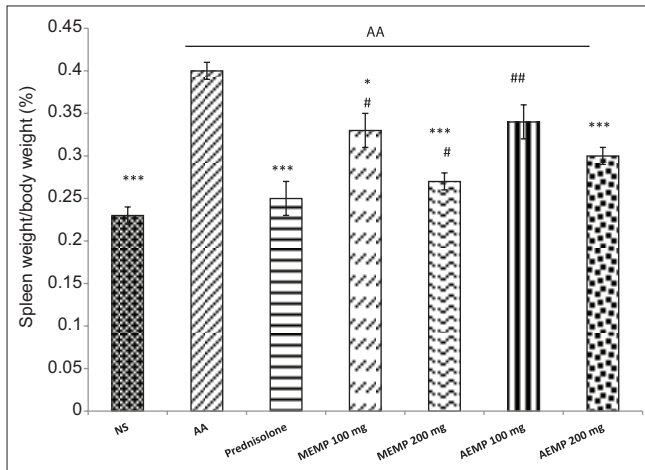


Figure 2: Effect of treatment with methanolic and aqueous extracts of *M. parviflora* (MEMP and AEMP; 100, 200 mg/kg per day for 5 days) on the percentage of spleen/body weight ratio in rats. Data are expressed as mean \pm SEM ($n = 6$). * $P < 0.05$. *** $P < 0.001$ significantly different from control colitis (acetic acid) group. # $P < 0.05$. ## $P < 0.01$ significantly different from standard prednisolone-treated group. NS = Normal saline, AA = Acetic acid, MEMP = Methanolic extract of *Malva parviflora*, AEMP = Aqueous extract of *M. parviflora*

was more prominent compared with the smaller dose of 100 mg/kg (0.12 ± 0.00 and 0.16 ± 0.00 respectively, $P < 0.05$). The results of pretreatment with similar doses of MEMP and AEMP on colon weight/length ratio indicated that no significant difference was obtained (0.16 ± 0.00 , 0.15 ± 0.00 , $P = 0.44$). However, with higher doses of 200 mg/kg of MEMP and AEMP, the methanolic extract produced a highly significant reduction ($P < 0.001$) than the aqueous extract (0.12 ± 0.00 and 0.15 ± 0.00).

The ratio was significantly lower ($P < 0.05$) in the group of rats treated with MEMP (200 mg/kg) as compared with the standard prednisolone group [Figure 3].

Histopathological results

Figure 4 shows examples of colonic tissues on microscopic examination. Normal control group, showing normal mucosal epithelium of tall columnar epithelial cells with goblet cells [Figure 4a]. In the AA group, the colon morphological studies showed that AA induced serious damage to the mucous glands with inflammatory cell infiltration. The photomicrograph revealed diffused active colitis, widely eroded mucosa with ulcerations, and necrosis associated with edema [Figure 4b].

In MEMP 100 plus AA group, slight healing of epithelial cells with scattered superficial ulcers lined by colonic glands and reparative epithelial changes with less goblet cells surrounded by transmucosal fewer lymphocytic infiltrate and stromal edema was seen [Figure 4c].

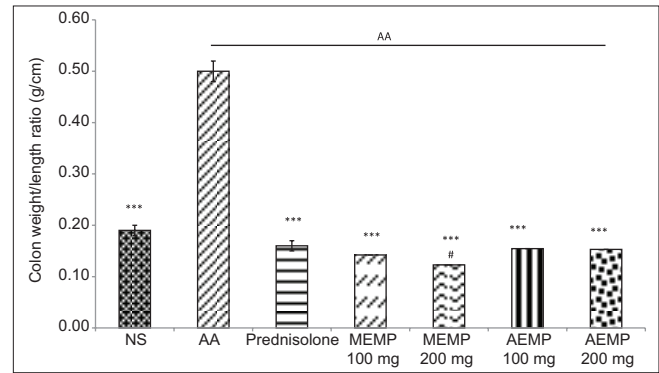


Figure 3: Effect of treatment with methanolic and aqueous extracts of *M. parviflora* (MEMP and AEMP; 100, 200 mg/kg per day for 5 days) on colon weight/length ratio in rats. Data are expressed as mean \pm SEM ($n = 6$). *** $P < 0.001$ significantly less than control colitis (acetic acid) group. # $P < 0.05$ significantly less than standard prednisolone-treated group. NS = Normal saline, AA = Acetic acid, MEMP = Methanolic extract of *Malva parviflora*, AEMP = Aqueous extract of *M. parviflora*

Photomicrograph from MEMP 200 plus AA group showed intestinal rat lined by healing epithelial cells, with superficial shredded cells, less eroded surface surrounded by few inflammatory edema and less necrosis. Colonic gland showed reparative epithelial changes [Figure 4d].

Photomicrograph from AEMP 100 plus AA group showed superficial tiny eroded mucosa with hemorrhage, edema and scattered acute and chronic inflammatory cells infiltrate surrounding colonic glands with reparative epithelial changes, and few goblet cells were seen [Figure 4e].

Photomicrograph from AEMP 200 plus AA group revealed intestinal section with better healed and improved intestinal mucosa compared with positive controlled sections with few mucosal lymphoplasmacytic infiltrate within stromal edema [Figure 4f].

Prednisolone treatment resulted in infiltration of lymphocytes surrounding colonic glands and submucosa layers with reparative epithelial changes and few goblet cells. Slight improvement of intestinal mucosa of prednisolone group in comparison with AA group is shown in Figure 4g.

DISCUSSION

UC is associated with migration of lymphocytes and macrophages to the intestinal mucosal tissue. Activated white blood cells produce free radicals in the intestinal mucosal tissue, which cause lipid peroxidation, increased permeability of blood vessels, the increasing entrance of neutrophils, and expanding of inflammation in the intestinal mucosal tissue.^[32]

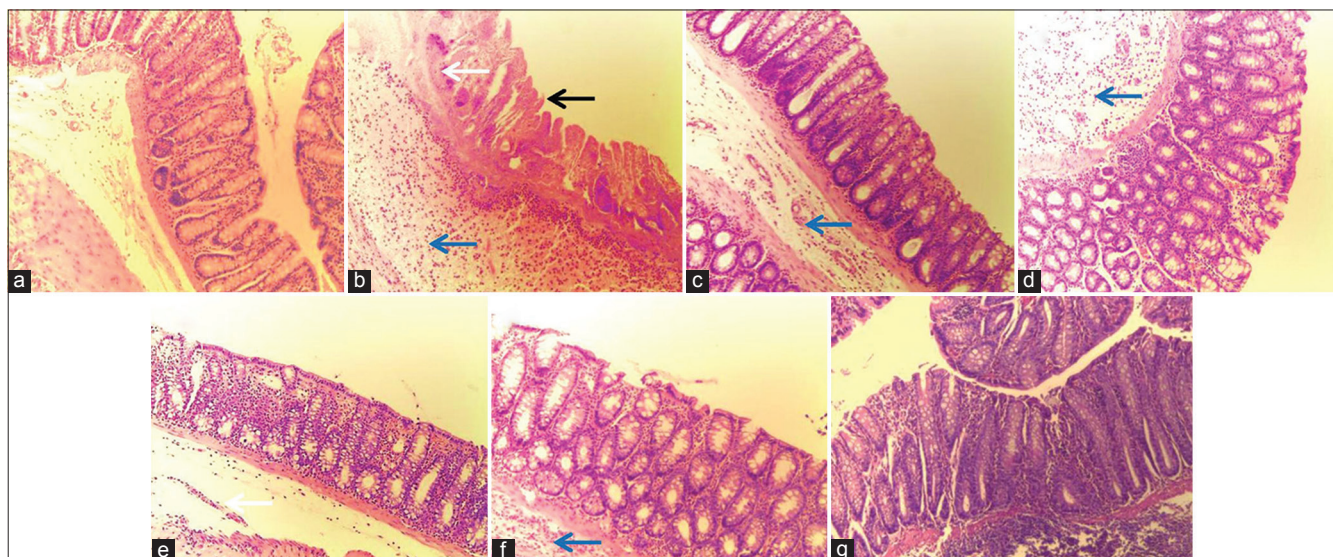


Figure 4: Representative histological slides of rat colonic mucosa. (a) Normal control group; (b) acetic acid (AA) colitis group; (c) MEMP (100 mg/kg); (d) MEMP (200 mg/kg); (e) AEMP (100 mg/kg); (f) AEMP (200 mg/kg); and (g) prednisolone (2 mg/kg). Black arrow indicates damage of mucosal epithelium, blue arrow indicates submucosal infiltration, and white arrow indicates hemorrhage

Currently, the clinical management of IBD is based on using anti-inflammatory agents such as corticosteroids, aminosalicylates, and immunosuppressants. These drugs are known for having serious adverse effects.^[33]

Therefore, For disease control and prevention, extensive studies on natural remedies particularly using those with antioxidant properties, have been conducted.^[1]

This study was aimed to evaluate the protective effect of the methanolic and aqueous extracts of *M. parviflora* on acetic acid-induced colitis in rats.

This model of colitis induction is rapid, reproducible, and resulted in a uniform diffuse colonic inflammation resembling many characteristics of human UC.^[34] Our results confirmed the suitability of this method, since an acute and invariably characteristic colitis was developed in experimental rats.

The macroscopic damage parameters of the colon after acetic acid treatment revealed increased colonic weight, mucosal hyperemia, edema, erosion, and ulceration in control groups and increased weight of colonic tissue due to inflammatory response, which is indicative of severity and extent of the disease.^[35] No changes were observed in normal saline group suggesting that handling and surgical procedure had no interference with experimental outputs.

Histopathological changes in the colitis group showed serious damage to the mucous glands. Necrosis is associated with edema, hemorrhage, inflammatory cellular infiltration, crypt damage, and ulceration.

Our results showed that both the methanolic and aqueous extracts of *M. parviflora* (MEMP and AEMP) in the doses of 100 and 200 mg/kg exhibited a significant, dose-dependent amelioration of intestinal inflammation as evidenced by reduction in spleen weight/body weight ratio and colon weight/length ratio compared with the control colitis group. These counts were also noticeably counteracted in the standard prednisolone group. The histopathological study confirmed our macroscopic results where higher doses of both extracts provided a noticeable healing of epithelial cells, less necrosis, and colonic gland showed reparative epithelial changes.

The preliminary phytochemical screening of *M. parviflora* extracts revealed the presence of flavonoids, saponins, tannins, steroids, coumarins, and glycosides. The protective effect may be attributed to the presence of one or more of these constituents.

Flavonoids are known to possess potent antioxidant properties. Antioxidants have the ability to neutralize free radicals and prevent cell damage due to free radicals.^[36] In a previous study, Rammal *et al.*^[28] reported that the percentage scavenger activity of *M. parviflora* leaves extract was 88% and was comparable to the antioxidant, ascorbic acid.

Acetic acid has been found to cause an increase in peritoneal fluid levels of prostaglandins (PGE2 and PGF2), hence causing inflammatory pain by inducing capillary permeability.^[37] The observed anti-inflammatory effects of *M. parviflora* in our study may be an indication of its inhibitory effect on prostaglandins synthesis.

Previously, crude saponin extracts of the whole plant of *Schwenkia Americana* Linn, the rhizome of *Asparagus africanus* Lam, the leaves of *Dichrostachys cinerea* Linn, the stem bark of *Ficus iteophylla* Miq, and the leaves of *lidigofera pulchra* Wild showed significant anti-inflammatory properties in the carrageenan-induced rat paw edema test.^[38] Therefore, we assume that saponins present in the aqueous extract of *M. parviflora* could be a contributor to its anticolitic effect.

Tannins were also detected in the aqueous extract of *M. parviflora* L. The tannins present in considerable amounts in *Cydonia oblonga* Miller (Quince) extracts were effective in reducing the inflammation and ulcer indices in murine model of acute colitis. Tannins could protect intestinal mucosal layers by precipitating their microproteins and protecting the layers against chemical injuries and proteolytic enzymes^[39]

Condensed tannins can also help return the gastrointestinal flora to a state of balance. Patients with UC have gastrointestinal flora that favor pathogenic bacteria.^[40,41]

Nirmal *et al.*^[43] have demonstrated that *T. purpurea* roots reduced myeloperoxidase (MPO) and malondialdehyde (MDA) levels in inflamed colon tissues significantly thus playing an anti-inflammatory role in the treatment of colitis, because MPO has been shown to be involved in the inflammatory reaction in colitis. This effect was attributed to the presence of glycosides.

M. parviflora extracts were rich in coumarins. Coumarins represent an important class of phenolic compounds with multiple biological activities, including inhibition of lipid peroxidation, neutrophil-dependent anion superoxide generation, and anti-inflammatory and immune suppressor actions. All of these properties suggest its beneficial use in the treatment of IBD.

Luchini *et al.*^[42] have demonstrated that coumarin and its derivative, the 4-hydroxycoumarin significantly attenuated the colonic damage induced by trinitrobenzenesulphonic acid in rats, as evidenced macroscopically, microscopically, and biochemically. This effect was related to an improvement in the colonic oxidative status, since coumarin and 4-hydroxycoumarin prevented the glutathione depletion that occurred as a consequence of the colonic inflammation.

Therefore, these preliminary results are encouraging to test the effects of dietary consumption of *M. parviflora* in patients with UC.

CONCLUSION

From these results, it may be concluded that the methanolic extract of *M. parviflora* leaves (MEMP) was more effective than the aqueous extract (AEMP) in attenuating macroscopic and microscopic findings of inflammation and tissue damage induced in rats by intracolonic administration of acetic acid. The protective effect was dose-dependent with the higher dose of 200 mg/kg body weight given orally, showing better protection. Such anticolitis activity may be due to the presence of various types of phytoconstituents such as coumarins, steroids, flavonoids, phenolic compounds, tannins, and glycosides.

Several studies have indicated that these phytoconstituents possess significant anticolitis activity. Further research is being conducted to identify and characterize the exact active phytoconstituents, which may be responsible for the observed significant anticolitis activity and, in particular, the coumarins.

Nonetheless, the study has some limitations. First, the duration of the study was short and longer pretreatment periods for up to two or three weeks would be useful in particular for the evaluation of the effectiveness of the aqueous extract. Second, the study lacked the evaluation of hematological parameters, such as white blood cell (WBC) count and C-reactive protein concentrations, which may reinforce our macroscopic and microscopic findings.

Financial support and sponsorship

Nil.

Conflicts of interest

There are no conflicts of interest.

REFERENCES

1. Molodecky NA, Kaplan GG. Environmental risk factors for inflammatory bowel disease. *Gastroenterol Hepatol (N Y)* 2010;6:339-46.
2. Niu X, Zhang H, Li W, Wang Y, Mu Q, Wang X, *et al.* Protective effect of cavidine on acetic acid-induced murine colitis via regulating antioxidant, cytokine profile and NF- κ B signal transduction pathways. *Chem Biol Interact* 2015;239:34-45.
3. Ardizzone S, Cassinotti A, Manes G, Porro GB. Immunomodulators for all patients with inflammatory bowel disease? *Therap Adv Gastroenterol* 2010;3:31-42.
4. Langmead L, Feakins RM, Goldthorpe S, Holt H, Tsironi E, De Silva A, *et al.* Randomized, double-blind, placebo-controlled trial of oral aloe vera gel for active ulcerative colitis. *Aliment Pharmacol Ther* 2004;19:739-47.
5. Triantafyllidi A, Xanthos T, Papalois A, Triantafyllidis JK. Herbal and plant therapy in patients with inflammatory bowel disease. *Ann Gastroenterol* 2015;28:210-20.

6. Ren J, Wang YG, Wang AG, Wu LQ, Zhang HJ, Wang WJ, *et al.* Cembranoids from the gum resin of *Boswellia carterii* as potential antiulcerative colitis agents. *J Nat Prod* 2015;78:2322-31.
7. Kotakadi VS, Jin Y, Hofseth AB, Ying L, Cui X, Volate S, *et al.* *Ginkgo biloba* extract EGb 761 has anti-inflammatory properties and ameliorates colitis in mice by driving effector T cell apoptosis. *Carcinogenesis* 2008;29:1799-806.
8. Zhou YH, Yu JP, Liu YF, Teng XJ, Ming M, Lv P, *et al.* Effects of *Ginkgo biloba* extract on inflammatory mediators (SOD, MDA, TNF-alpha, NF-kappaBp65, IL-6) in TNBS-induced colitis in rats. *Mediators Inflamm* 2006;2006:92642.
9. Kudo T, Okamura S, Zhang Y, Masuo T, Mori M. Topical application of glycyrrhizin preparation ameliorates experimentally induced colitis in rats. *World J Gastroenterol* 2011;17:2223-8.
10. Langmead L, Rampton DS. Review article: Complementary and alternative therapies for inflammatory bowel disease. *Aliment Pharmacol Ther* 2006;23:341-9.
11. Hanai H, Iida T, Takeuchi K, Watanabe F, Maruyama Y, Andoh A, *et al.* Curcumin maintenance therapy for ulcerative colitis: Randomized, multicenter, double-blind, placebo-controlled trial. *Clin Gastroenterol Hepatol* 2006;4:1502-6.
12. Fujimori S, Gudis K, Mitsui K, Seo T, Yonezawa M, Tanaka S, *et al.* A randomized controlled trial on the efficacy of synbiotic versus probiotic or prebiotic treatment to improve the quality of life in patients with ulcerative colitis. *Nutrition* 2009;25:520-5.
13. Ke F, Yadav PK, Ju LZ. Herbal medicine in the treatment of ulcerative colitis. *Saudi J Gastroenterol* 2012;18:3-10.
14. El-Abhar HS, Hammad LN, Gawad HS. Modulating effect of ginger extract on rats with ulcerative colitis. *J Ethnopharmacol* 2008;118:367-72.
15. Mazzon E, Muià C, Paola RD, Genovese T, Menegazzi M, De Sarro A, *et al.* Green tea polyphenol extract attenuates colon injury induced by experimental colitis. *Free Radic Res* 2005;39:1017-25.
16. Cabré E, Mañosa M, Gassull MA. Omega-3 fatty acids and inflammatory bowel diseases-a systematic review. *Br J Nutr* 2012;107(Suppl 2):S240-52.
17. Monk JM, Hou TY, Turk HF, Weeks B, Wu C, McMurray DN, *et al.* Dietary n-3 polyunsaturated fatty acids (PUFA) decrease obesity-associated Th17 cell-mediated inflammation during colitis. *PLoS One* 2012;7:E49739.
18. Kono H, Fujii H, Ogiku M, Tsuchiya M, Ishii K, Hara M. Enteral diets enriched with medium-chain triglycerides and N-3 fatty acids prevent chemically induced experimental colitis in rats. *Transl Res* 2010;156:282-91.
19. Sánchez-Fidalgo S, Villegas I, Aparicio-Soto M, Cárdeno A, Rosillo MÁ, González-Benjumea A, *et al.* Effects of dietary virgin olive oil polyphenols: Hydroxytyrosyl acetate and 3, 4-dihydroxyphenylglycol on DSS-induced acute colitis in mice. *J Nutr Biochem* 2015;26:513-20.
20. *Malva Parviflora*. Germplasm Resources Information Network (GRIN). Beltsville: United States Department of Agriculture, Agricultural Research Service. Available from: <http://www.ars-grin.gov/cgi-bin/npgs/html/taxon.pl?90031>. [Last accessed on 2014 Feb 20].
21. Afolayan AJ, Aboyade OM, Adedapo AA, Sofidiya MO. Antiinflammatory and analgesic activity of the methanol extract of *Malva parviflora* Linn (Malvaceae) in rats. *Afr J Biotech* 2010;9:1225-9.
22. Bouriche H, Meziti H, Senator A, Arnhold J. Anti-inflammatory, free radical-scavenging, and metal-chelating activities of *Malva parviflora*. *Pharm Biol* 2011;49:942-6.
23. Shale TL, Stirk WA, van Staden J. Variation in antibacterial and anti-inflammatory activity of different growth forms of *Malva parviflora* and evidence for synergism of the anti-inflammatory compounds. *J Ethnopharmacol* 2005;96:325-30.
24. Aslam M, Sial AA. Neuroprotective effect of ethanol extract of leaves of *Malva parviflora* against Amyloid- β - (A β -) Mediated Alzheimer's disease. *International Scholarly Research Notices* 2014. Available from: <http://dx.doi.org/10.1155/2014/156976>. [Last accessed on 2015 – June 20].
25. Perez Gutierrez RM. Evaluation of hypoglycemic activity of the leaves of *Malva parviflora* in streptozotocin-induced diabetic rats. *Food Funct* 2012;3:420-7.
26. Gürbüz I, Ozkan AM, Yesilada E, Kutsal O. Anti-ulcerogenic activity of some plants used in folk medicine of Pinarbasi (Kayseri, Turkey). *J Ethnopharmacol* 2005;101:313-8.
27. Ishtiaq S, Hassan SS, Niaz U, Saeed MA. Identification and evaluation of counter-irritant potential of crude extract of *Malva parviflora* L. by WHO recommended methods. *Pak J Pharm Sci* 2012;25:589-94.
28. Farhan H, Rammal H, Hijazi A, Hamad H, Daher A, Reda M, *et al.* *In vitro* antioxidant activity of ethanolic and aqueous extracts from crude *Malva parviflora* L. grown in Lebanon. *Asian J Pharm Clin Res* 2012;5(Suppl 3):234-8.
29. Dahiru D, Onubiyi JA, Umaru HA. Phytochemical screening and antiulcerogenic effect of *Moringa oleifera* aqueous leaf extract. *Afr J Tradit Complement Altern Med* 2006;3:70-5.
30. Chinedu E, Arome D, Ameh FS. A new method for determining acute toxicity in animal models. *Toxicol Int* 2013;20:224-6.
31. Kandhare AD, Raygude KS, Ghosh P, Ghule AE, Gosavi TP, Badole SL, *et al.* Effect of hydroalcoholic extract of *Hibiscus rosa sinensis* Linn. Leaves in experimental colitis in rats. *Asian Pac J Trop Biomed* 2012;2:337-44.
32. Maloy KJ, Powrie F. Intestinal homeostasis and its breakdown in inflammatory bowel disease. *Nature* 2011;474:298-306.
33. Wang J, Fu YX. Tumor necrosis factor family members and inflammatory bowel disease. *Immunol Rev* 2005;204:144-55.
34. Low D, Nguyen DD, Mizoguchi E. Animal models of ulcerative colitis and their application in drug research. *Drug Des Devel Ther* 2013;7:1341-57.
35. Somani SJ, Badgujar LB, Sutariya BK, Saraf MN. Protective effect of *Dillenia indica* L. on acetic acid induced colitis in mice. *Indian J Exp Biol* 2014;52:876-81.
36. Dixit N, Baboota S, Kohli K, Ahmad S, Ali J. Silymarin: A review of pharmacological aspects and bioavailability enhancement approaches. *Indian J Pharmacol* 2007;39:172-9.
37. Sklyarov AY, Panasyuk NB, Fomenko IS. Role of nitric oxide-synthase and cyclooxygenase/lipoxygenase systems in development of experimental ulcerative colitis. *J Physiol Pharmacol* 2011;62:65-73.
38. Hassan HS, Sule MI, Musa AM, Musa KY, Abubakar MS, Hassan AS. Anti-inflammatory activity of crude saponin extracts from five Nigerian medicinal plants. *Afr J Tradit Complement Altern Med* 2012;9:250-5.
39. Minaiyan M, Ghannadi A, Etemad M, Mahzouni P. A study of the effects of *Cydonia oblonga* Miller (Quince) on TNBS-induced ulcerative colitis in rats. *Res Pharm Sci* 2012;7:103-10.
40. Ewaschuk JB, Tejpar QZ, Soo I, Madsen K, Fedorak RN. The role of antibiotic and probiotic therapies in current and future management of inflammatory bowel disease. *Curr Gastroenterol Rep* 2006;8:486-98.
41. Sartor RB. Microbial-host interactions in inflammatory bowel diseases and experimental colitis. *Nestle Nutr Workshop Ser Pediatr Program* 2009;64:121-37, 251-7.
42. Nirmal SA, Sonawane LL, Asane GS, Pal SC, Mandal SC. Glycoside from *Tephrosia purpurea* roots in the treatment of ulcerative colitis. *Pharmacologia* 2014;5:310-5.
43. Luchini AC, Rodrigues-Orsi P, Cestari SH, Seito LN, Witacenis A, Pellizzon CH, *et al.* Intestinal anti-inflammatory activity of coumarin and 4-hydroxycoumarin in the trinitrobenzenesulphonic acid model of rat colitis. *Biol Pharm Bull* 2008;31:1343-50.