

Comprehensive Review

Advanced CT Imaging for the Assessment of Calcific Coronary Artery Disease and PCI Planning



Atomu Tajima, MD^{a,†}, Frederic Bouisset, MD, PhD^{a,†}, Hirofumi Ohashi, MD, PhD^b, Koshiro Sakai, MD, PhD^c, Takuya Mizukami, MD, PhD^a, Maurizio Lodi Rizzini, PhD^d, Diego Gallo, PhD^d, Claudio Chiastra, PhD^d, Umberto Morbiducci, PhD^d, Ziad A. Ali, MD, DPhil^e, James C. Spratt, MD, PhD^f, Hirohiko Ando, MD, PhD^b, Tetsuya Amano, MD, PhD^b, Pieter Kitslaar, MSc^g, Adriaan Wilgenhof, MD^{a,h}, Jeroen Sonck, MD, PhD^a, Bernard De Bruyne, MD, PhD^a, Carlos Collet, MD, PhD^{a,*}

^a Cardiovascular Center, OLV Hospital, Aalst, Belgium; ^b Department of Cardiology, Aichi Medical University, Nagakute, Aichi, Japan; ^c Division of Cardiology, Department of Medicine, Showa University School of Medicine, Tokyo, Japan; ^d Polito^{BIQ}Med Lab, Department of Mechanical and Aerospace Engineering, Politecnico di Torino, Turin, Italy; ^e St Francis Hospital & Heart Center, Roslyn, New York; ^f St. George's, University of London, London, United Kingdom; ^g Medis Medical Imaging Systems BV, Leiden, the Netherlands; ^h Department of Clinical and Molecular Medicine, Sapienza University, Rome, Italy

ABSTRACT

Vascular calcification is a hallmark of atherosclerosis and adds considerable challenges for percutaneous coronary intervention (PCI). This review underscores the critical role of coronary computed tomography (CT) angiography in assessing and quantifying vascular calcification for optimal PCI planning. Severe calcification significantly impacts procedural outcomes, necessitating accurate preprocedural evaluation. We describe the potential of coronary CT for calcium assessment and how CT may enhance precision in device selection and procedural strategy. These advancements, along with the ongoing Precise Procedural and PCI Plan study, represent a transformative shift toward personalized PCI interventions, ultimately improving patient outcomes in the challenging landscape of calcified coronary lesions.

Introduction

Vascular calcification is a hallmark of atherosclerosis. Coronary calcification increases with age and is present in 90% of men and 66% of women older than 70 years.¹ Coronary calcification is more common in individuals with risk factors for coronary artery disease, such as hypertension, smoking, hyperlipidemia, diabetes, and renal dysfunction.^{2–4} It is also promoted by treatments commonly associated with reducing cardiovascular events, such as statins.⁵

Calcification poses considerable challenges for percutaneous coronary intervention (PCI) by reducing vascular compliance, impacting device delivery, and hampering balloon and stent expansion.⁶ Studies have demonstrated that severe target lesion calcification is associated with worse short- and long-term outcomes than those in patients without calcification.⁷ Patients with severe calcification treated with PCI have higher rates of cardiac death, myocardial

infarction, and stent thrombosis than those with no or mild coronary calcification.⁷

Coronary computed tomography (CT) angiography has been increasingly adopted in the evaluation of patients with chest pain.^{8,9} CT is a highly sensitive method to assess calcium, enabling calcific plaques to be characterized morphologically in their longitudinal and circumferential extension.¹⁰ Uniquely, CT also has a role in assessing calcium density and resistance to fracture.¹¹ This review offers a state-of-the-art update on calcium evaluation by coronary CT and presents future perspectives on the use of CT for calcium assessment relevant to PCI planning.

Pathology of arterial calcification

Arterial calcification is characterized by the accumulation of calcium phosphate with the formation of hydroxyapatite crystals.¹² Continued

Abbreviations: CT, computed tomography; CTO, chronic total occlusion; IVI, intravascular imaging; OCT, optical coherence tomography; P4, Precise Procedural and PCI Plan; PCI, percutaneous coronary intervention.

Keywords: calcified lesions; coronary artery disease; coronary computed tomography angiography; computed tomography-guided percutaneous coronary intervention.

* Corresponding author: carloscollet@gmail.com (C. Collet).

† Contributed equally.

<https://doi.org/10.1016/j.jscai.2024.101299>

Received 22 December 2023; Received in revised form 8 January 2024; Accepted 9 January 2024

Available online 26 March 2024

2772-9303/© 2024 The Author(s). Published by Elsevier Inc. on behalf of the Society for Cardiovascular Angiography and Interventions Foundation. This is an open access article under the CC BY-NC-ND license (<http://creativecommons.org/licenses/by-nc-nd/4.0/>).

ossification and calcium deposition increase plaque density and size. The presence of calcium relates closely to vascular injury and inflammation.^{13,14} Vascular calcification can be restricted to the intima, associated with atherosclerosis, or confined to the media layer.¹³ Atherosclerotic intimal calcification is the most common type of calcific vasculopathy within the coronary vasculature.¹⁵ Inflammatory mediators in the lipidic milieu induce osteogenic differentiation of vascular smooth muscle cells.^{15,16} Both intima and medial calcification span a wide range of molecular pathways, including inflammation, apoptosis, disruption of calcium phosphate homeostasis, matrix vesicle extrusions, osteogenic transformations, extracellular matrix degeneration, and genetic aberrations.¹⁴ Calcification can also manifest in the adventitia.¹⁷ Increasing evidence suggests the active involvement of the adventitia in atherosclerosis, with inflammation occurring in atherosclerotic disease. Inflammatory processes in the adventitia can extend to the intima, fostering the progression of atherosclerosis in that tissue.¹⁸ The specific mechanisms underlying adventitia calcification remain unclear. Calcification in the adventitia may arise from fibroblasts that have undergone transformation into myofibroblasts or smooth muscle cells.¹⁷

Intimal calcification progresses from micro and punctate calcification (spanning from 0.5 μm to 1 mm in diameter) to fragment calcification, typically from 1 to 3 mm in diameter, to sheet calcifications, which are larger than 3 mm and can extend circumferentially 360°.¹⁹ Nodular calcification is another type of intimal calcification classified as eruptive or noneruptive. Eruptive nodules are irregular and are

associated with thrombosis and fibrin, while smooth nodules have a more regular surface and an intact fibrous cap.²⁰ Figure 1 shows the classification of arterial calcifications and their appearance in coronary CT angiography and optical coherence tomography (OCT).

Calcium and PCI

Since the early phase of PCI, calcified lesions have represented one of the most challenging subsets to treat.²¹ Although clinical outcomes have been improved with contemporary drug-eluting stents, a pooled analysis including more than 19,000 patients demonstrated that PCI in moderate to severe calcified coronary stenosis is still associated with a higher rate of major adverse events, including a higher rate of cardiac death and stent thrombosis, compared to PCI in noncalcified lesions.⁷

Calcific plaques reduce vessel compliance, impair device deliverability, hamper symmetric balloon expansion, and lead to stent underexpansion (Figure 2).¹⁶ In eccentric calcified plaques, balloon dilatation results in the stretch of the compliant (noncalcified) part of the vessel and uneven distribution of the forces applied by the balloon to the vessel wall. Moreover, high-pressure dilatation at the interface between calcium and soft tissue disrupts the vessel, commonly resulting in coronary dissections.¹⁶ Extensive calcification also hampers device crossability and may affect the integrity of stent struts

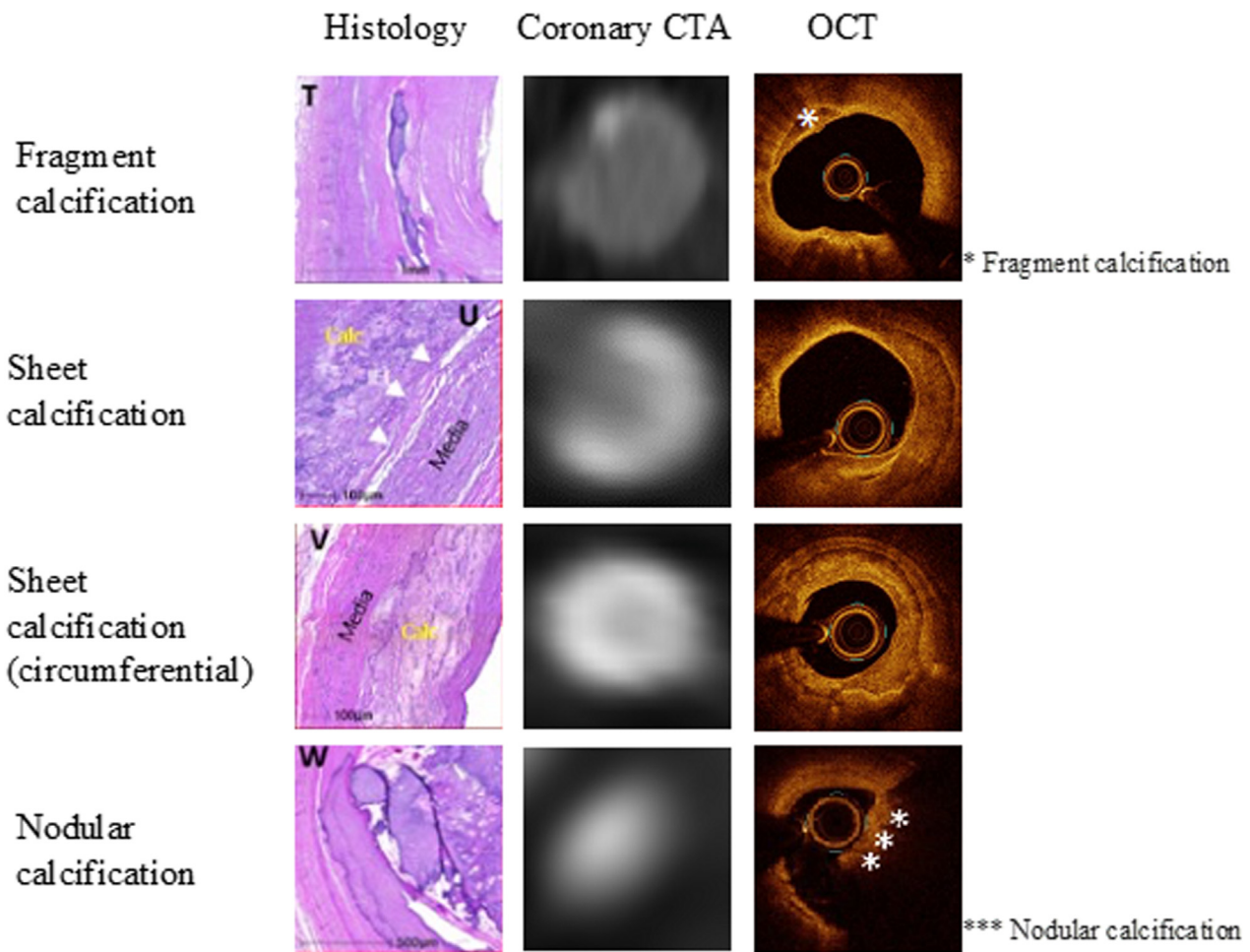


Figure 1.

Types of calcifications. Histological, coronary computed tomography angiography (CTA), and optical coherence tomography (OCT) findings are shown for different levels of calcification. The histological sections (T to W) of the intimal calcifications were stained with hematoxylin and eosin. White arrowheads indicate internal elastic lamina. Modified and reproduced with permission from <https://doi.org/10.1016/j.jacc.2021.06.049>.

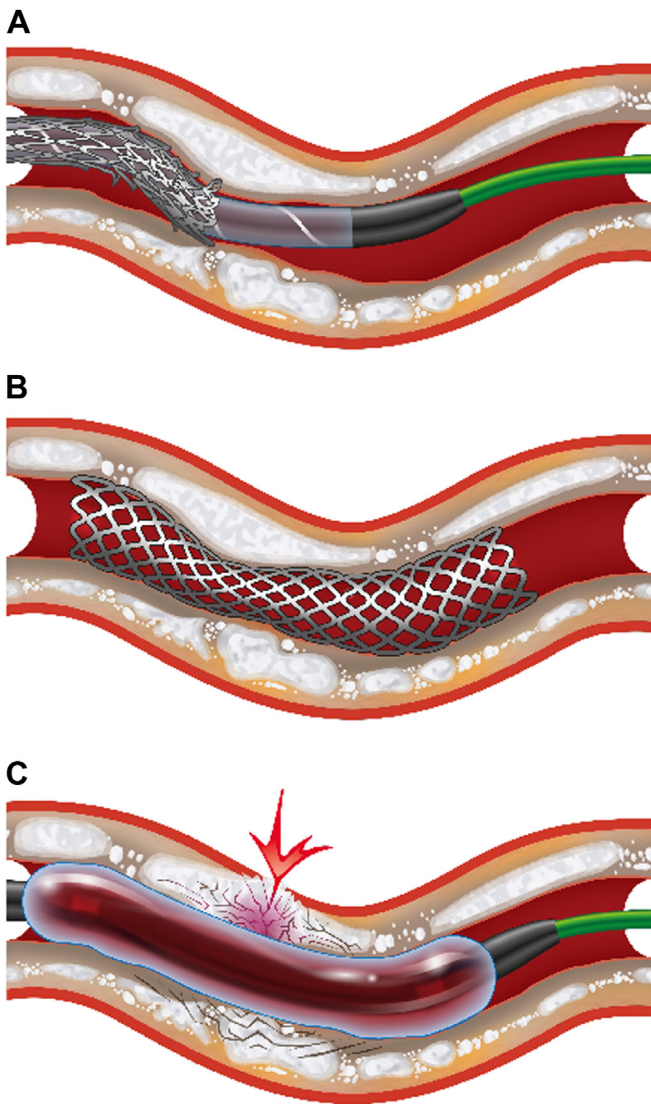


Figure 2. Percutaneous coronary intervention complications related to arterial calcification. (A) Attempted crossing of a calcified lesion with a stent, leading to an unsuccessful traversal associated with a partial decrimping and longitudinal compression of the stent. (B) Stent under deployment observed in an inadequately prepared calcified lesion. (C) Coronary rupture occurring during predilatation of a calcified lesion insufficiently prepared beforehand.

when pushed forcefully downstream. Furthermore, treatment of coronary calcium with ablative technologies has been associated with particle embolization, resulting in an increased rate of periprocedural myocardial infarction.

Calcium is the single most critical predictor of stent expansion.^{22,23} In addition, asymmetric stent expansion and malapposition are frequently observed after PCI in calcific lesions.²⁴ Stent under-expansion, assessed by measuring the minimal stent area, is an independent predictor of clinical outcomes after drug-eluting stent implantation.^{25,26} Therefore, adequate vessel preparation with advanced plaque modification is paramount to obtaining appropriate vessel dilatation with larger luminal areas and optimizing stent expansion in calcified lesions.

The calcification severity evaluated by imaging determines the necessity of advanced plaque modification before stenting.^{22,23} The available tools for calcium preparation can be divided into ablative technologies aimed primarily at reducing calcium volume (eg, rotational and orbital atherectomy) and those targeting modification of plaque compliance (eg, lithotripsy and scoring/cutting balloons).⁶ Table 1 summarizes the available methods for coronary calcified lesion preparation.

Characterization of calcium

The quantification of calcium severity before PCI allows for predicting case complexity, device crossability, and the probability of stent underexpansion. Coronary CT, conventional or enhanced angiography, and intravascular imaging (IVI) can assess the calcification burden qualitatively and quantitatively. Table 2 summarizes the characteristics of the different imaging techniques.

The absorption and attenuation coefficient of radiation within a tissue plays a crucial role in CT reconstruction, generating a grayscale image.²⁷ Hounsfield units (HU) express CT attenuation values. On the Hounsfield scale, water is assigned 0 HU, while air is given -1000 HU. Upper limits extend to 1000 for bones, 2000 for dense bones like the cochlea, and surpass 3000 for metals such as steel or silver. A higher HU number corresponds to a brighter pixel intensity. Calcium, with its higher atomic number and density compared to most tissues, results in increased X-ray attenuation, reducing the passing X-ray intensity. Due to its density, calcium appears bright white on a CT scan.²⁷ Tissue density is proportionate to the X-ray attenuation, aiding in the differentiation of calcified structures. The HU is named after Godfrey Hounsfield, a Nobel Prize recipient in 1979.

The calcium score, developed in 1990, is the first quantitative calcium measurement accounting for the area and the density of the calcified plaques.²⁸ The density is measured in HU and reflects the strength of the plaque. The Agatston score has been extensively utilized for risk stratification in patients with cardiovascular risk factors.²⁹ In the PCI field, Sekimoto et al³⁰ reported that a per-lesion calcium score ≥ 453 predicted the need for rotational atherectomy.

A more refined evaluation of calcium can be performed by administering contrast for a coronary CT angiography. The 3-dimensional (3D) maximum intensity projection is an automatic reconstruction that portrays the distribution of calcium in the aorta and coronary tree (Figure 3).

Table 1. Imaging modalities to assess coronary calcifications.

	Calcium score	Coronary CT angiography	Angiography	IVUS	OCT
Modality	Noninvasive	Noninvasive	Invasive	Intravascular	Intravascular
Resolution	-	0.5 mm	0.1 mm	100-200 μ m	10-20 μ m
Contrast	-	+	+	-	++
Quantification	+	-	-	+	+
Arc	-	++	-	+++	+++
Thickness	-	++	-	+/-	+++
Length	-	++	-	+++	+++
Density	-	+++	-	-	-
3-Dimensional	-	+	-	-	+/-

CT, computed tomography; IVUS, intravascular ultrasound; OCT, optical coherence tomography.

Table 2. Devices for advanced calcium modification.

Device	Characteristics	Mechanism of action	Indication
Scoring/cutting balloon	Semicompliant or noncompliant surrounded by an external helical scoring edge.	The device creates 3 or 4 endovascular radial incisions through the fibrocalcific tissue by scoring/cutting force. It allows further expansion compared with conventional balloons.	<ol style="list-style-type: none"> 1. Proximal and distal lesions 2. Aorto-ostial lesions 3. Tortuous coronary segments 4. After RA, OA, or IVL
Intravascular lithotripsy	IVL catheter consists of a 0.014" guidewire compatible, balloon angioplasty catheter with 2 spark gap-based lithotripsy emitters incorporated into the shaft of the 12 mm long balloon.	The IVL system incorporates a portable regenerator to provide energy, and the transmitters produce intermittent sonic pressure waves, resulting in the delivery of mechanical energy to the target lesion. The acoustic energy results in the creation of micro-cracks within the calcified plaque with each transmission and consecutive impulses causing an increase in vessel compliance with preservation of underlying wall composition with reduced atmospheric pressures compared to balloon inflation.	<ol style="list-style-type: none"> 1. Deep calcification and calcified nodules 2. Large vessels 3. Stent under expansion (off-label) 4. Bifurcation lesions 5. Calcified aorto-ostial lesions
Rotational atherectomy	A rapidly rotating olive-shaped metallic burr coated with small diamond crystals on its distal end. The burr diameter ranges between 1.25 and 2.5 mm.	Ablates plaque using a diamond elliptical burr, rotating at 135,000 to 180,000 rpm by a helical driveshaft that advances gradually across a lesion over a dedicated guidewire. The basic physical principle is differential cutting, which allows the advancing burr to selectively cut inelastic material while elastic tissue deflects away from the burr. As 95% of the particles generated by rotablation are less than 5 microns in diameter, they are removed from the body by the reticuloendothelial system.	<ol style="list-style-type: none"> 1. Undilatable and/or balloon uncrossable lesions 2. Superficial or nodular calcification 3. Very tight calcified stenoses 4. Long calcified lesions 5. Selected calcified bifurcation lesions, if side-branch wire protection is not mandatory
Orbital atherectomy	A drive shaft eccentrically mounted diamond-coated crown modifies the plaque and increases the luminal size and compliance.	An eccentrically mounted diamond-coated crown orbits at high speeds and removes a thin layer of calcific plaque. By centrifugal forces, the crown orbits allow for the continuous flow of blood during ablation. An average particle size of debris of 2.04 μm —smaller than a red blood cell—may contribute to low rates of no-reflow and transient heart block with orbital atherectomy. It also works bidirectionally, ablating plaques while being advanced and retracted.	<ol style="list-style-type: none"> 1. Undilatable lesions 2. Superficial or nodular calcification 3. Selected calcified bifurcation lesions, if side-branch wire protection is not mandatory
Laser atherectomy	Catheter delivered photoablation for molecular breakdown of tissue. Efficient in fibrous but less so with severe calcium.	Laser atherectomy uses a xenon-chloride monochromatic excimer laser to produce bursts of ultraviolet light at 308 nm. The light is readily absorbed by plaque and thrombus in a similar fashion. Light energy absorption almost instantaneously releases a laser-induced pressure wave. The pressure wave initiates rapid fluid displacement, which leads to vapor bubble formation and collapse, leading to vaporizing and debulking of plaque.	<ol style="list-style-type: none"> 1. Uncrossable lesions 2. Stent under expansion 3. Fibrotic intimal hyperplasia causing in-stent restenosis

IVL, intravascular lithotripsy; OA, orbital atherectomy; RA, rotational atherectomy.

The 3D maximum intensity projection allows for an intuitive evaluation of the global burden of calcium and its location, providing an initial automated appraisal of PCI complexity.³¹ It is important to consider that CT-derived calcium volume exhibits a 60% overestimation relative to OCT.¹⁰ Extending the reconstruction to coronary vessels, multiplanar reconstructions, and cross-sectional views are useful to assess calcification severity, which can be quantified in terms of arc, thickness, and length. These 3 parameters derived from IVI (specifically OCT) have been shown to be associated with stent underexpansion.^{22,23} The likelihood of stent underexpansion is high when the arc is $>180^\circ$, thickness >5 mm, and length >5 mm.^{22,23} Monizzi et al¹⁰ showed that calcium arc, thickness, and length can be accurately derived from coronary CT angiography using OCT as a reference. Using a similar methodology based on coronary CT angiography, Sekimoto et al³⁰ showed the clinical relevance of this approach by identifying that an arc of calcium $>270^\circ$ predicted the need for rotational atherectomy.

Beyond the classical morphological assessment of calcium, CT offers the possibility to stratify calcium based on density. This approach partly mimics that utilized in the classical Agatston score extended to coronary CT angiography. In CT analysis, calcific plaques can be defined as those structures with HU >380 or 400 HU. These are easy plaque elements to visualize due to the bright aspect of the image. The intensity of calcium within the plaques can differ, ie, there are calcific plaques with low and high HU. In patients with coronary artery disease, calcific plaques with HU <1.000 have been linked to plaque vulnerability, whereas calcium calcific plaques with HU >1.000 are associated with better prognosis.³²

Similarly, with noncontrast calcium scoring, higher calcium density appears to confer a lower risk of mortality.³³

The density of calcium measured in terms of HU is also a marker of biological resilience, reflecting its hardness. In patients with calcific stones in the urinary tract, HU have been used to predict the efficacy of shock wave lithotripsy. The higher the stone density in HU, suggesting higher calcium strength, the stronger the acoustic energy needed to achieve fragmentation.³⁴ Therefore, the HU in calcific plaques allows for assessing the "resistance" of the plaque to fracture. Ultimately, the objective of calcific lesion modification before PCI is to fracture calcium, which would improve vessel compliance, and allow separation of calcium fragments to permit adequate stent expansion.³⁵

In coronary arteries, CT-derived calcium density has demonstrated clinical utility in predicting the necessity for advanced plaque modification. Kurogi et al¹¹ reported that high calcium density (>637 HU) at the cross-sectional CT predicted the need for rotational atherectomy. The stratification of calcium based on density represents a novel approach for guiding plaque modification and, following proper validation, should assist in device selection. The hypothesis is that calcific plaque with greater density (ie, higher HU) may require advanced preparation (lithotripsy, atherectomy, etc.).

It is essential to recognize the current limitations of this approach, given that the absolute HU measured at the level of the calcified plaque depends on the CT acquisition parameters (eg, kilovolts) and contrast iodine concentration.³⁶ Therefore, it becomes challenging to use absolute HU since it will depend on the scan. In addition, some algorithms

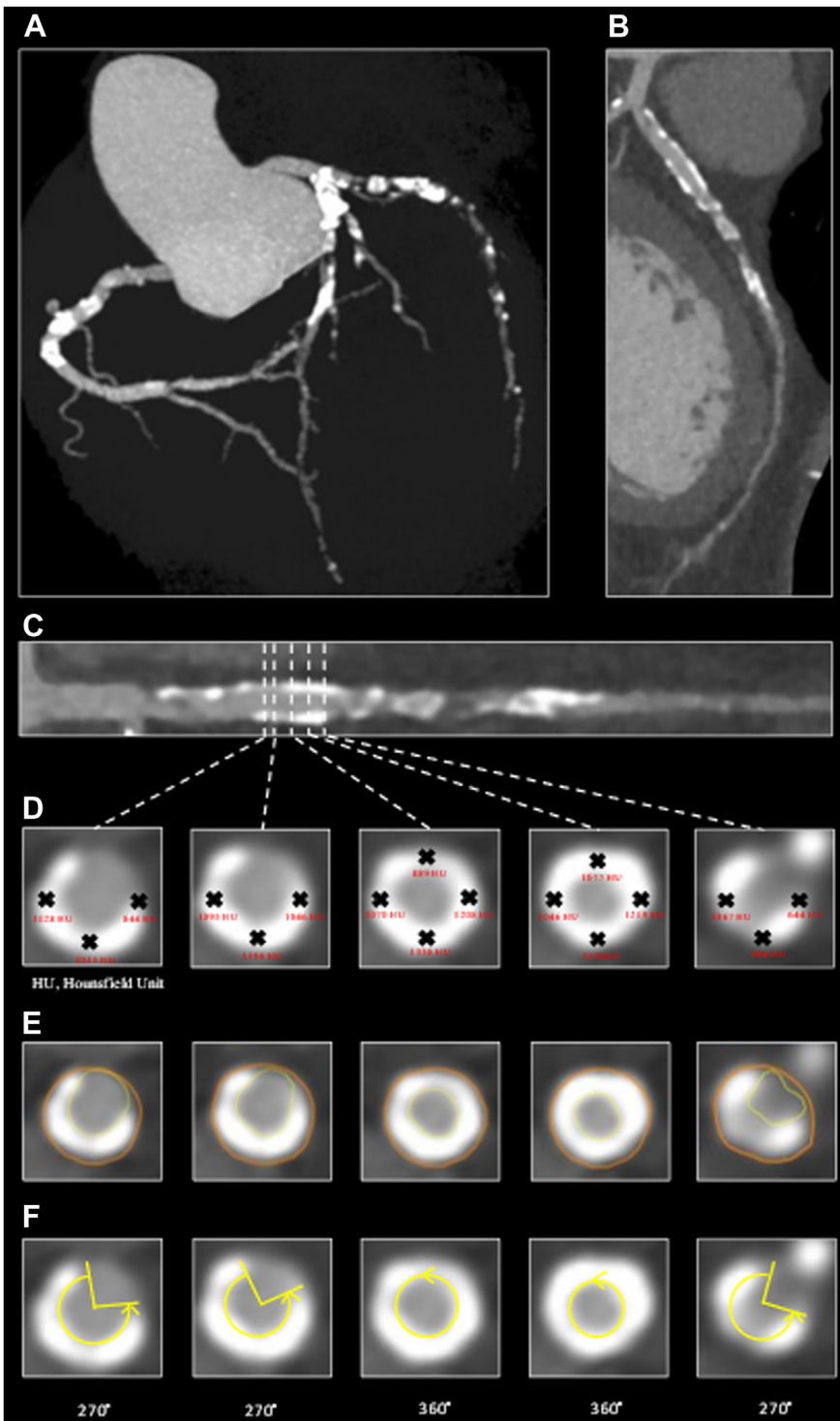


Figure 3. Evaluation of arterial calcification with coronary computed tomography angiography. (A) Three-dimensional angiography derived from computed tomography, providing an overview of the calcification level throughout the entire coronary tree. (B) Curved multiplanar reconstruction and (C) straight multiplanar reconstruction of the left anterior descending artery. These projections enable precise assessment of calcium location and length at the vessel level. (D) Vessel cross-sections illustrating the areas where calcium density was evaluated along the circumference. (E) Cross-section of the same vessel highlighting the contouring of the lumen and vessel. (F) Cross-section of the same vessel demonstrating the assessment of the calcium arc angle. HU, Hounsfield unit.

for motion correction and image enhancements may alter the intensity of the image, further hampering the comparability of HU at the level of coronary plaques between scans.

Circumferential calcifications

Segments with circumferential calcium are of great concern during PCI because they may lead to severe stent underexpansion if not

adequately treated. The exact mechanism of calcific ring formation remains poorly understood. Calcium deposition may initiate as a sheet of calcium that expands circumferentially until a complete connection is made. Further calcium growth would increase its density and thickness. Okutsu et al³⁷ have shown that calcium thickness and density are strongly correlated.

In cases of circumferential calcification, we have observed heterogeneity in the density across the calcium arc. To quantify this phenomenon, we measured calcium density at every 0.5 mm and

90° interval in circumferential calcifications. Using this approach, we were able to quantify the variability in intensity across circumferential calcifications (Figure 4). We hypothesized that calcified structures with nonuniform composition or variation in their density are more susceptible to breakage or fracture. In contrast, vessels with circumferential calcium with high and homogenous intensity along the circumference might be more difficult to fracture.

3D calcium evaluation

Using coronary CT, calcified plaques can be reconstructed, and the disease can be displayed as a color-coded 3D structure. 3D calcium evaluation represents a novel and intuitive way to evaluate calcium. Notably, 3D representation of the plaque and lumen permits the assessment of the plaque's location relative to the vessels'

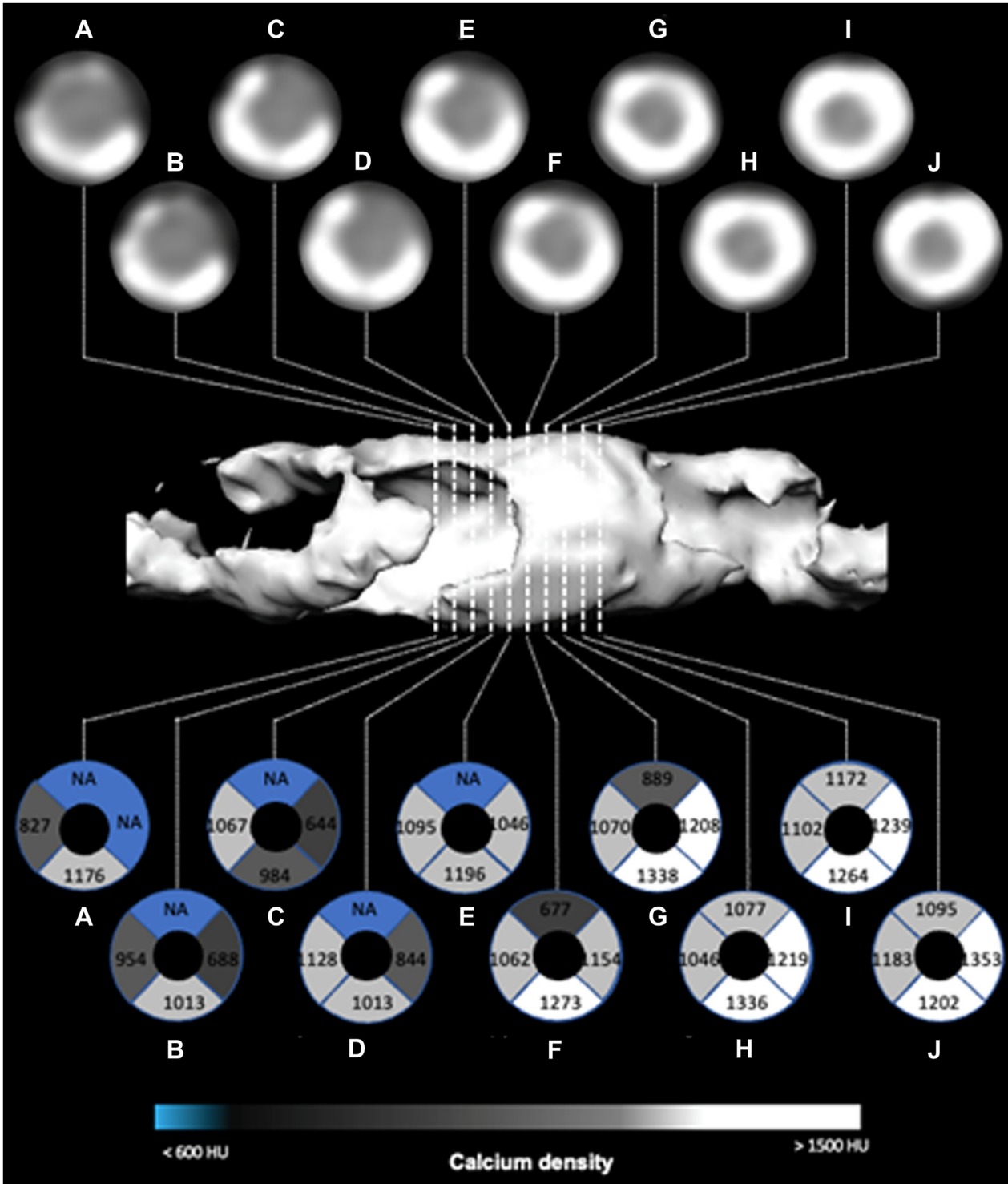


Figure 4. Distribution of density in circumferential calcifications. The central image illustrates an isolated coronary calcification. This structure undergoes detailed analysis through 10 cross-sectional images (labeled A-J). In each cross-section, the original form is displayed at the top, while a representative view is presented at the bottom. The representative view is defined through 4 dials, each indicating the maximum density recorded in Hounsfield units (HU). Additionally, a color-coded scale is applied to represent varying density levels. NA, not available.

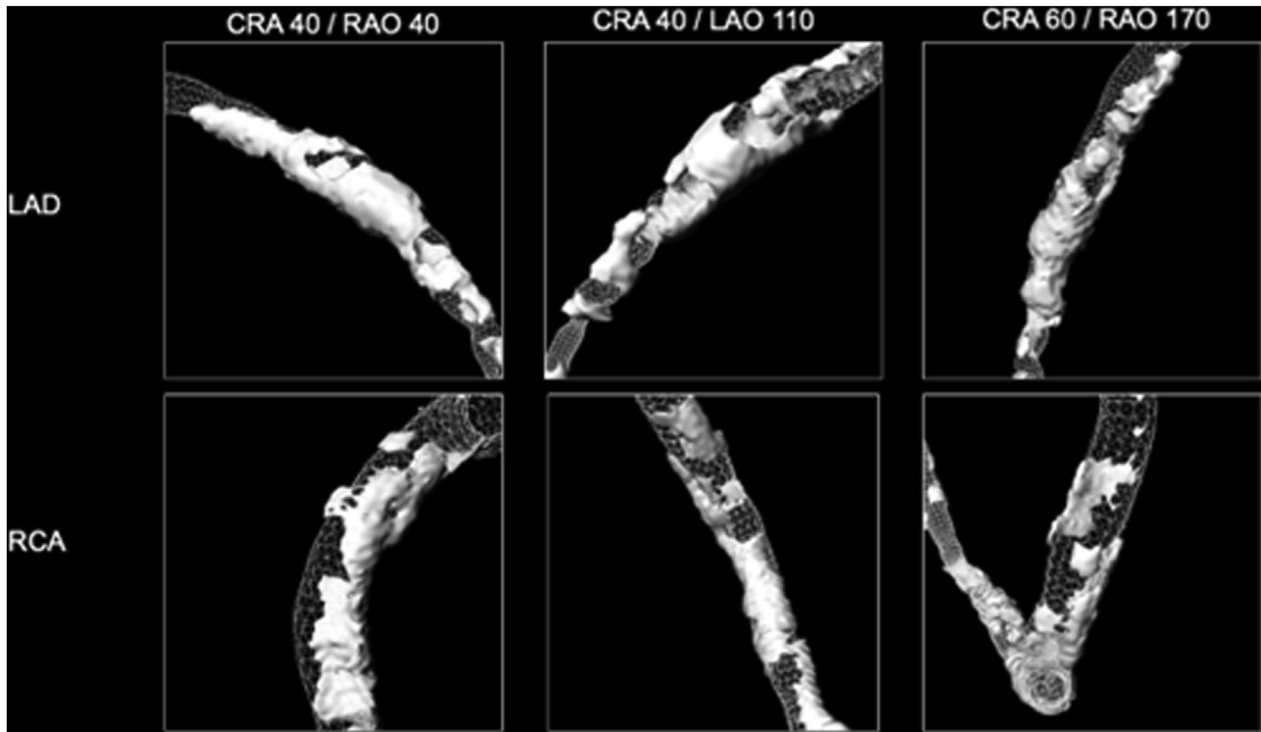


Figure 5.

Location of the calcium according to the vessel circumference. The upper row showcases 3 distinct projection angles of the same left anterior descending (LAD) vessel, highlighting the distribution of calcium around the vessel. In the lower row, 3 distinct projection angles of the same right coronary artery (RCA) vessel are displayed, serving the same purpose. This figure illustrates that calcium can be situated at the epicardial or myocardial quadrant of the vessels. CRA, cranial; LAO, left anterior oblique; RAO, right anterior oblique.

circumference. Using this approach, calcium can be described based on the vessel wall location as in the superior (epicardial) or inferior (myocardial) segment or, more specifically, at the upper left, upper right, lower left, and lower right quadrants (Figure 5).

The location of the calcium relative to the vessel circumference is clinically relevant because it permits assessing device friction based on the expected wire bias. Understanding wire bias may allow for tailoring plaque preparation strategies. The passage of equipment during coronary intervention occurs via a coronary guidewire (0.014 inches in diameter), over which devices can be used. The position of the guidewire in the coronary vessel is determined by the anatomy and compliance of the coronary tree, namely curvature, tortuosity, and radius. For the proximal part of the vessel, the position of the guiding catheter also influences the position of the wire inside the coronary artery. By combining this information, the position of the wire relative to the calcium can be estimated. In other words, the probability of contact between calcifications and devices (eg, stents, rotablation burr) can be predicted. The mechanism of action of devices like rotational atherectomy depends on the direct ablation of the calcified plaque. Therefore, predicting the path of the coronary wire and its relationship to calcium may aid in selecting plaque modification tools based on their mechanism of action.

The position of the wire inside the vessel can be predicted based on factors such as the vessel's anatomy and wire properties.^{38,39} Several methods, such as the finite-element method, mass-spring model, and rigid multibody links, have been proposed to simulate the wire's path in arteries.³⁹ These methods are based on mathematical assumptions or formal material simulations. Other approaches that follow the assumption that wire adopts the straightest configuration within a tortuous vessel have also been proposed.⁴⁰ In this regard, it has been demonstrated that combining CT imaging and graph theory allows the prediction of patient-specific wire pathways within the coronary vessel through the minimization of the wire's total bending energy.⁴⁰ This

approach based on wire's bending energy minimization assures a satisfactory trade-off between accuracy and computational costs and has been validated against OCT images. By leveraging 3D model coronary CT angiography, 3D models can be used to predict the path of the wire and, hence, the point of contact between the wire and the vessel can be estimated. The possibility to predict the wire bias inside the 3D model of the vessel, integrated by information on calcium location, density, and thickness, can support the clinical design of the treatment strategy at a superior level.

The circumferential location of the calcium relative to the vessel cross-section can be extracted along the length of the vessel from coronary CT angiography (Figure 6). Subsequently, information on the predicted wire's path location can be overlaid on the calcium density/thickness maps around each vessel's cross-section luminal surface. This framework can be adopted to predict the wire's location with respect to the calcifications on the vessel's wall.

Coronary CT angiography holds the potential to answer 2 relevant questions: when should advanced calcium plaque modification be employed, and, equally important, which is the device of choice? The availability of noninvasive calcium metrics that complement the information obtained with intravascular techniques may be a major step forward in the field of coronary CT and PCI, especially in complex cases with severe calcifications.

CT-guided PCI in calcified disease

Computed tomography-guided PCI uniquely provides the opportunity for comprehensive procedural planning incorporating calcific plaque characterization (Central Illustration). The ability to predict the need for advanced calcium preparation based on coronary CT angiography has important implications and might facilitate the efficient allocation of resources (eg, time, equipment, dedicated operators)

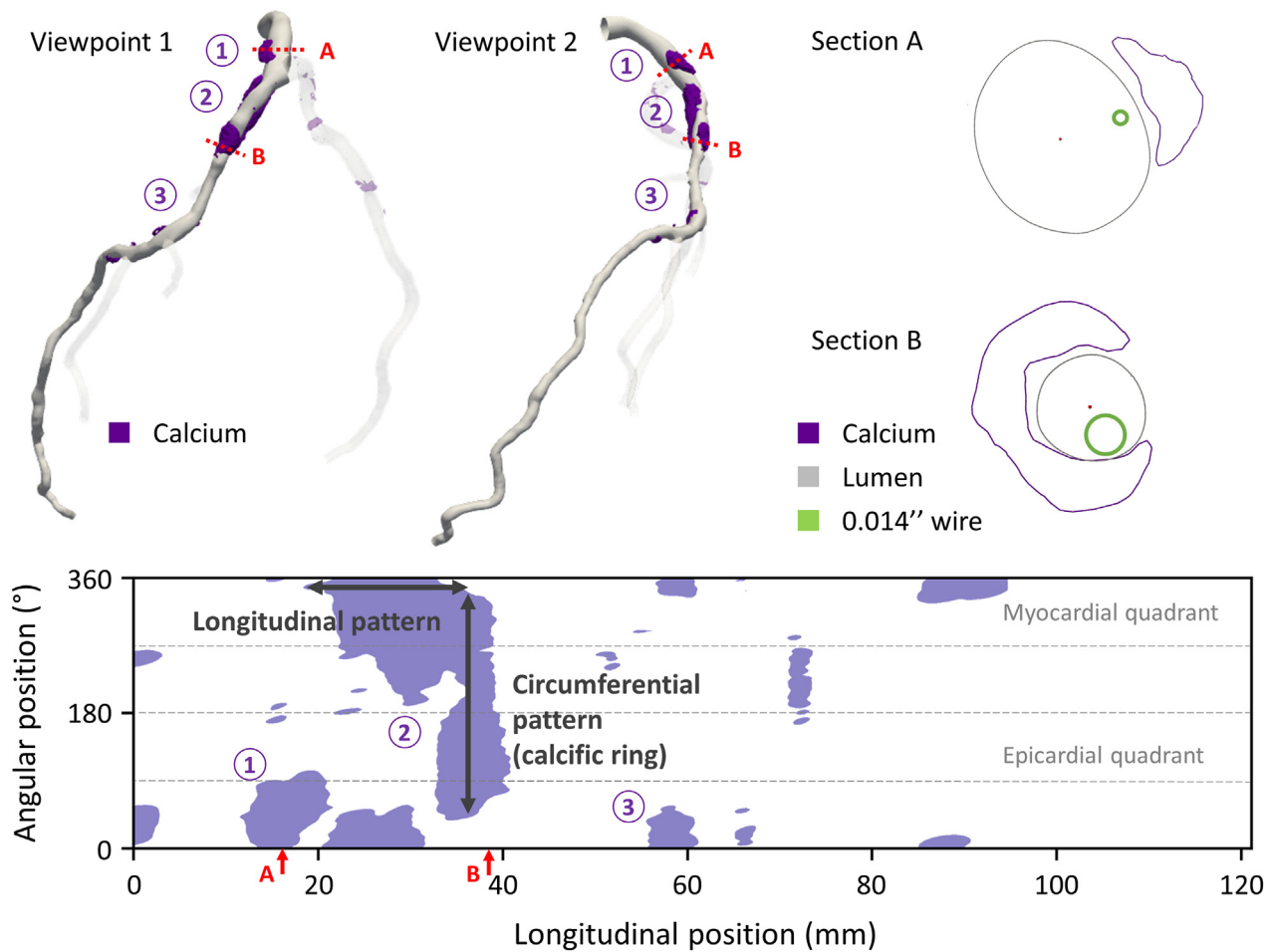


Figure 6.

Calcium distribution patterns over length and circumference. Upper panel: 2 different views of the 3-dimensional computed tomography reconstruction of a left anterior descending artery with calcification (highlighted in purple). The circumferential distribution of the calcium around 2 different vessel cross-sections (labeled sections A and B, respectively) is visualized, combined with the predictable wire location over each cross-section. Lower panel: longitudinal vs. circumferential distribution of calcifications along the coronary vessel.

tailored to the case complexity. In addition, understanding the necessity of plaque preparation in the preprocedural phase should prompt more IVI during the procedure to assess the need for additional devices for plaque preparation.

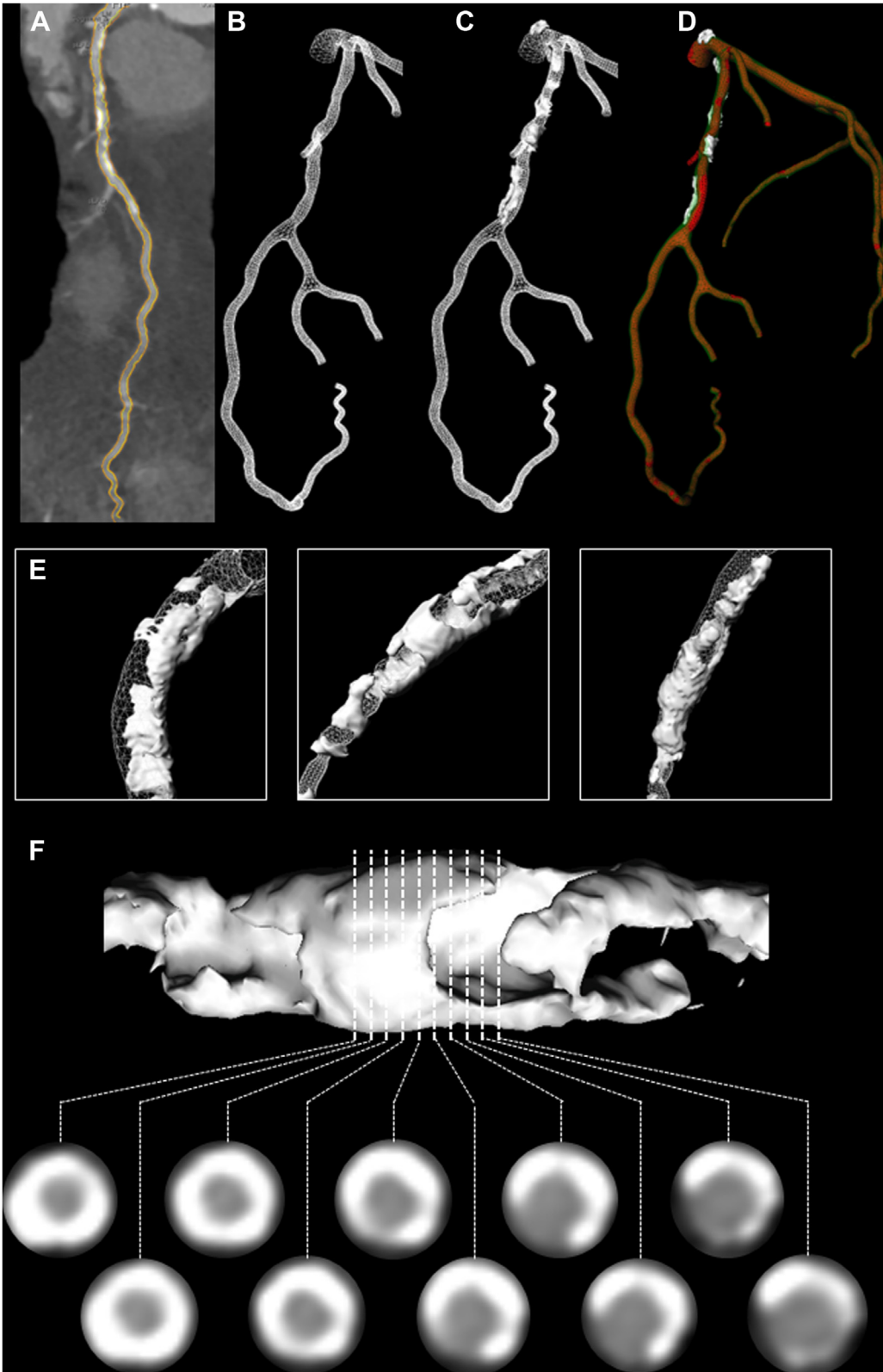
Planning complex procedures with calcified disease also provides an opportunity for patients to have a clearer understanding of the upcoming intervention and thus a more nuanced consent procedure, as the risk associated with these procedures is higher than PCI in non-calcified disease. From the physician's perspective, knowing the type and complexity of the disease also permits one to better prepare in terms of the material, personnel required, initial strategy, potential complications, and corrective actions.⁴¹

Percutaneous coronary intervention of a coronary chronic total occlusion (CTO) remains one of the most challenging procedures in interventional cardiology. In recent decades, there has been an improvement in both success rates and safety.⁴² These improvements were driven by the hybrid algorithm, which gave operators a standardized framework and technological advancement.¹ In CTO PCI, calcium is an independent predictor of procedural failure across a range of predictive scoring systems, eg, Multicenter CTO Registry in Japan; Computed Tomography Registry of Chronic Total Occlusion Revascularization; CT Angiography derived Multicenter CTO Registry of Japan score, and Korean Multicenter CTO CT Registry scores. The scores derived from coronary CT angiography mostly exceed the diagnostic

performance of the angiographic-only Multicenter CTO Registry in Japan score.^{43–47}

Periprocedural guidance with an online 3D model synchronized to the C-arm rotation has the potential to increase the anatomical understanding and safety of the CTO procedure.³¹ Furthermore, coronary CT angiography allows clarification of an ambiguous cap, a better understanding of lesion length, and unmasking of multiple occlusions where present. Despite these advantages, coronary CT angiography remains underused in CTO procedures.⁴⁸ Nevertheless, it will take a prominent place in the planning of complex PCI as it has the potential to guide strategy choices. For example, a very hard calcified proximal cap will direct us toward dissection and re-entry techniques or a retrograde approach if there are suitable collaterals. Very tortuous segments will limit the use of highly penetrative wires but orientate instead to polymer-jacketed wires that are less likely to exit the vessel. Coronary CT angiography also allows selection of an optimal "re-entry zone" with minimal plaque burden.

In the present work, we have introduced novel methods for calcium stratification that hold the potential to enhance clinical decision-making about plaque modification and help select the right tool for the right patient. The novel concept of CT-guided PCI, including dedicated calcium evaluation, is currently under investigation in a prospective randomized controlled trial, The Precise Procedural and PCI Plan (P4; NCT05253677). P4 will include 1000 patients with



Central Illustration.

Advanced calcium reconstruction using coronary computed tomography angiography. Top panel shows the reconstruction from coronary computed tomography angiography. (A) Curve multiplanar reconstruction of a left anterior descending artery. (B) Luminal mesh extracted from the curve multiplanar reconstruction contours. (C) Three-dimensional reconstruction with the calcium on top of the luminal mesh. (D) Left coronary tree color-coded with red color showing the luminal surface and white showing calcific plaques. (E) Examples of distribution of calcium within 3 different coronary vessels. (F) Three-dimensional reconstruction of the calcific plaque depicting the circumferential distribution of the calcium in each cross-section.

hemodynamically significant lesions as determined by fractional flow reserve derived from CT and randomize them in a 1:1 fashion to either CT-guided PCI or intravascular ultrasound-guided PCI. Approximately 30% of patients will show severe calcification based on CT. The study hypothesis is that a comprehensive assessment by coronary CT

angiography to plan and guide PCI will yield comparable clinical outcomes to intravascular ultrasound-guided PCI at the 1-year follow-up. This study will help validate the calcium analysis derived from CT with intravascular and clinical outcomes. Anticipated results from the study are expected to be available by 2026.

Conclusion

Vascular calcification, a hallmark of atherosclerosis, poses considerable challenges during PCI, impacting procedural success and patient outcomes. The increasing adoption of coronary CT angiography in evaluating patients with chest pain has opened avenues for detailed, sensitive, and lesion-specific assessment of coronary calcium. Coronary CT angiography has emerged as a valuable tool for assessing the extent, position, morphology, and density of calcific plaques, which may prove essential information for device selection and procedural strategy.

We introduce innovative approaches to quantify and stratify calcium hardness, potentially informing operators about the necessity of advanced plaque modification tools. Integration of coronary CT in PCI planning not only enhances procedural precision but also holds promise for optimizing resource allocation. Prospective trials, such as the ongoing P4 study, are expected to validate these novel approaches and underscore their clinical utility.

In the era of personalized medicine, detailed characterization of coronary calcium through advanced imaging techniques represents a crucial step toward tailored and optimized PCI interventions. The insights provided in this review underscore the evolving landscape of PCI planning, emphasizing the pivotal role of coronary CT in navigating the challenges posed by calcified lesions and ultimately improving patient outcomes.

Declaration of competing interest

Frederic Bouisset received consultancy fees from Boston Scientific, B-Braun, and Amgen. Ziad A. Ali received institutional grants from Abbott Vascular and Cardiovascular System Inc. to Columbia University and Cardiovascular Research Foundation; honoraria from Amgen, AstraZeneca, and Boston Scientific; and equity from Shockwave Medical. Pieter Kitslaar is an employee of Medis Medical Imaging Systems BV. Bernard De Bruyne reports receiving consultancy fees from Boston Scientific and Abbott and receiving research grants from Coroventis Research, Pie Medical Imaging, CathWorks, Boston Scientific, Siemens, HeartFlow Inc., and Abbott Vascular. Carlos Collet reports receiving research grants from Biosensor, Coroventis Research, Medis Medical Imaging Systems BV, Pie Medical Imaging, CathWorks, Boston Scientific, Siemens, HeartFlow, and Abbott Vascular and consultancy fees from HeartFlow, OpSens, Abbott Vascular, and Philips Volcano. The remaining authors have no conflicts of interest to declare.

Funding sources

This work was not supported by funding agencies in the public, commercial, or not-for-profit sectors.

Ethics statement and patient consent

The authors retrieved and synthesized data from previously published studies; therefore, no ethical approval was required or obtained.

References

- Mohan J, Bhatti K, Tawney A, Zeltser R. *Coronary Artery Calcification*. StatPearls Publishing; 2023.
- Golub IS, Termeie OG, Kristo S, et al. Major global coronary artery calcium guidelines. *JACC Cardiovasc Imaging*. 2023;16(1):98–117. <https://doi.org/10.1016/j.jcmg.2022.06.018>
- Greenland P, Blaha MJ, Budoff MJ, Erbel R, Watson KE. Coronary calcium score and cardiovascular risk. *J Am Coll Cardiol*. 2018;72(4):434–447. <https://doi.org/10.1016/j.jacc.2018.05.027>
- Kalra SS, Shanahan CM. Vascular calcification and hypertension: cause and effect. *Ann Med*. 2012;44(suppl 1):S85–S92. <https://doi.org/10.3109/07853890.2012.660498>
- Nakazato R, Gransar H, Berman DS, et al. Statins use and coronary artery plaque composition: results from the International Multicenter CONFIRM Registry. *Atherosclerosis*. 2012;225(1):148–153. <https://doi.org/10.1016/j.atherosclerosis.2012.08.002>
- De Maria GL, Scarsini R, Banning AP. Management of calcific coronary artery lesions: is it time to change our interventional therapeutic approach? *J Am Coll Cardiol Interv*. 2019;12(15):1465–1478. <https://doi.org/10.1016/j.jcin.2019.03.038>
- Guedeney P, Claessen BE, Mehran R, et al. Coronary calcification and long-term outcomes according to drug-eluting stent generation. *J Am Coll Cardiol Interv*. 2020;13(12):1417–1428. <https://doi.org/10.1016/j.jcin.2020.03.053>
- Knuuti J, Wijns W, Saraste A, et al, ESC Scientific Document Group. 2019 ESC Guidelines for the diagnosis and management of chronic coronary syndromes. *Eur Heart J*. 2020;41(3):407–477. <https://doi.org/10.1093/eurheartj/ehz425>
- Writing Committee Members, Gulati M, Levy PD, et al. 2021 AHA/ACC/AASE/CHEST/SAEM/SCCT/SCMR guideline for the evaluation and diagnosis of chest pain: executive summary: a report of the American College of Cardiology/American Heart Association joint committee on clinical practice guidelines. *J Am Coll Cardiol*. 2021;78(22):2218–2261. <https://doi.org/10.1016/j.jacc.2021.07.052>
- Monizzi G, Sonck J, Nagumo S, et al. Quantification of calcium burden by coronary CT angiography compared to optical coherence tomography. *Int J Cardiovasc Imaging*. 2020;36(12):2393–2402. <https://doi.org/10.1007/s10554-020-01839-z>
- Kurogi K, Ishii M, Nagatomo T, et al. Mean density of computed tomography for predicting rotational atherectomy during percutaneous coronary intervention. *J Cardiovasc Comput Tomogr*. 2023;17(2):120–129. <https://doi.org/10.1016/j.jcct.2023.02.002>
- Zaheer A, Murshed M, De Grand AM, Morgan TG, Karsenty G, Frangioni JV. Optical imaging of hydroxyapatite in the calcified vasculature of transgenic animals. *Arterioscler Thromb Vasc Biol*. 2006;26(5):1132–1136. <https://doi.org/10.1161/01.ATV.0000210016.89991.2a>
- Demer LL, Tintut Y. Vascular calcification: pathobiology of a multifaceted disease. *Circulation*. 2008;117(22):2938–2948. <https://doi.org/10.1161/CIRCULATIONAHA.107.743161>
- Demer LL, Tintut Y. Inflammatory, metabolic, and genetic mechanisms of vascular calcification. *Arterioscler Thromb Vasc Biol*. 2014;34(4):715–723. <https://doi.org/10.1161/ATVBAHA.113.302070>
- Abedin M, Tintut Y, Demer LL. Vascular calcification: mechanisms and clinical ramifications. *Arterioscler Thromb Vasc Biol*. 2004;24(7):1161–1170. <https://doi.org/10.1161/01.ATV.0000133194.94939.42>
- Madhavan MV, Tarigopula M, Mintz GS, Maehara A, Stone GW, Généreux P. Coronary artery calcification: pathogenesis and prognostic implications. *J Am Coll Cardiol*. 2014;63(17):1703–1714. <https://doi.org/10.1016/j.jacc.2014.01.017>
- Li N, Cheng W, Huang T, Yuan J, Wang X, Song M. Vascular adventitia calcification and its underlying mechanism. *PLOS ONE*. 2015;10(7):e0132506.
- Wilcox JN, Scott NA. Potential role of the adventitia in arteritis and atherosclerosis. *Int J Cardiol*. 1996;54(suppl):S21–S35. [https://doi.org/10.1016/s0167-5273\(96\)02811-2](https://doi.org/10.1016/s0167-5273(96)02811-2)
- Lanzer P, Hannan FM, Lanzer JD, et al. Medial arterial calcification: JACC state-of-the-art review. *J Am Coll Cardiol*. 2021;78(11):1145–1165. <https://doi.org/10.1016/j.jacc.2021.06.049>
- Torii S, Sato Y, Otsuka F, et al. Eruptive calcified nodules as a potential mechanism of acute coronary thrombosis and sudden death. *J Am Coll Cardiol*. 2021;77(13):1599–1611. <https://doi.org/10.1016/j.jacc.2021.02.016>
- Bredlau CE, Roubin GS, Leimgruber PP, Douglas JS, King SB, Gruentzig AR. In-hospital morbidity and mortality in patients undergoing elective coronary angioplasty. *Circulation*. 1985;72(5):1044–1052. <https://doi.org/10.1161/01.CIR.72.5.1044>
- Zhang M, Matsumura M, Usui E, et al. Intravascular ultrasound-derived calcium score to predict stent expansion in severely calcified lesions. *Circ Cardiovasc Interv*. 2021;14(10):e010296. <https://doi.org/10.1161/CIRCINTERVENTIONS.120.010296>
- Fujino A, Mintz GS, Matsumura M, et al. A new optical coherence tomography-based calcium scoring system to predict stent underexpansion. *EuroIntervention*. 2018;13(18):e2182–e2189. <https://doi.org/10.4244/EIJ-D-17-00962>
- Dong P, Bezerra HG, Wilson DL, Gu L. Impact of calcium quantifications on stent expansions. *J Biomech Eng*. 2019;141(2):210101–210108. <https://doi.org/10.1115/1.4042013>
- Fujii K, Carlier SG, Mintz GS, et al. Stent underexpansion and residual reference segment stenosis are related to stent thrombosis after sirolimus-eluting stent implantation: an intravascular ultrasound study. *J Am Coll Cardiol*. 2005;45(7):995–998. <https://doi.org/10.1016/j.jacc.2004.12.066>
- Song HG, Kang SJ, Ahn JM, et al. Intravascular ultrasound assessment of optimal stent area to prevent in-stent restenosis after zotarolimus-, everolimus-, and sirolimus-eluting stent implantation. *Catheter Cardiovasc Interv*. 2014;83(6):873–878. <https://doi.org/10.1002/ccd.24560>
- DenOtter TD, Schubert J. *Hounsfield Unit*. StatPearls Publishing; 2023.
- Agatston AS, Janowitz WR, Hildner FJ, Zusmer NR, Viamonte M, Detrano R. Quantification of coronary artery calcium using ultrafast computed tomography. *J Am Coll Cardiol*. 1990;15(4):827–832. [https://doi.org/10.1016/0735-1097\(90\)90282-t](https://doi.org/10.1016/0735-1097(90)90282-t)
- Hulten E, Bittencourt MS, Ghoshhajra B, et al. Incremental prognostic value of coronary artery calcium score versus CT angiography among symptomatic patients without known coronary artery disease. *Atherosclerosis*. 2014;233(1):190–195. <https://doi.org/10.1016/j.atherosclerosis.2013.12.029>
- Sekimoto T, Akutsu Y, Hamazaki Y, et al. Regional calcified plaque score evaluated by multidetector computed tomography for predicting the addition of rotational atherectomy during percutaneous coronary intervention. *J Cardiovasc Comput Tomogr*. 2016;10(3):221–228. <https://doi.org/10.1016/j.jcct.2016.01.004>

31. Collet C, Sonck J, Leipsic J, et al. Implementing coronary computed tomography angiography in the catheterization laboratory. *JACC Cardiovasc Imaging*. 2021; 14(9):1846–1855. <https://doi.org/10.1016/j.jcmg.2020.07.048>
32. van Rosendaal AR, Narula J, Lin FY, et al. Association of high-density calcified 1K plaque with risk of acute coronary syndrome. *JAMA Cardiol*. 2020;5(3):282–290. <https://doi.org/10.1001/jamacardio.2019.5315>
33. Razavi AC, van Assen M, De Cecco CN, et al. Discordance between coronary artery calcium area and density predicts long-term atherosclerotic cardiovascular disease risk. *JACC Cardiovasc Imaging*. 2022;15(11):1929–1940. <https://doi.org/10.1016/j.jcmg.2022.06.007>
34. Gupta NP, Ansari MS, Kesarvani P, Kapoor A, Mukhopadhyay S. Role of computed tomography with no contrast medium enhancement in predicting the outcome of extracorporeal shock wave lithotripsy for urinary calculi. *BJU Int*. 2005;95(9): 1285–1288. <https://doi.org/10.1111/j.1464-410X.2005.05520.x>
35. Kubo T, Shimamura K, Ino Y, et al. Superficial calcium fracture after PCI as assessed by OCT. *JACC Cardiovasc Imaging*. 2015;8(10):1228–1229. <https://doi.org/10.1016/j.jcmg.2014.11.012>
36. Takagi H, Leipsic JA, Indraratna P, et al. Association of tube voltage with plaque composition on coronary CT angiography: results from PARADIGM registry. *JACC Cardiovasc Imaging*. 2021;14(12):2429–2440. <https://doi.org/10.1016/j.jcmg.2021.07.011>
37. Okutsu M, Mitomo S, Onishi H, et al. The estimation of coronary artery calcium thickness by computed tomography angiography based on optical coherence tomography measurements. *Heart Vessels*. 2023;38(11):1305–1317. <https://doi.org/10.1007/s00380-023-02286-1>
38. Sharei H, Alderliesten T, van den Dobbelsteen JJ, Dankelman J. Navigation of guidewires and catheters in the body during intervention procedures: a review of computer-based models. *J Med Imaging (Bellingham)*. 2018;5(1):010902. <https://doi.org/10.1117/1.JMI.5.1.010902>
39. Cardoso FM, Furuie SS. Guidewire path determination for intravascular applications. *Comput Methods Biomech Biomed Engin*. 2016;19(6):628–638. <https://doi.org/10.1080/10255842.2015.1055732>
40. Schafer S, Singh V, Noël PB, Walczak AM, Xu J, Hoffmann KR. Real-time endovascular guidewire position simulation using shortest path algorithms. *Int J Comput Assist Radiol Surg*. 2009;4(6):597–608. <https://doi.org/10.1007/s11548-009-0385-z>
41. Bouisset F, Ohashi H, Andreini D, Collet C. Role of coronary computed tomography angiography to optimise percutaneous coronary intervention outcomes. *Heart*. 2023. Published online September 19, 2023 <https://doi.org/10.1136/heartjnl-2023-322889>
42. Brilakis ES, Grantham JA, Rinfret S, et al. A percutaneous treatment algorithm for crossing coronary chronic total occlusions. *J Am Coll Cardiol Interv*. 2012;5(4): 367–379. <https://doi.org/10.1016/j.jcin.2012.02.006>
43. Fujino A, Otsuji S, Hasegawa K, et al. Accuracy of J-CTO score derived from computed tomography versus angiography to predict successful percutaneous coronary intervention. *JACC Cardiovasc Imaging*. 2018;11(2 Pt 1):209–217. <https://doi.org/10.1016/j.jcmg.2017.01.028>
44. Mollet NR, Hoye A, Lemos PA, et al. Value of preprocedure multislice computed tomographic coronary angiography to predict the outcome of percutaneous recanalization of chronic total occlusions. *Am J Cardiol*. 2005; 95(2):240–243.
45. Morino Y, Abe M, Morimoto T, et al. Predicting successful guidewire crossing through chronic total occlusion of native coronary lesions within 30 minutes: the J-CTO (Multicenter CTO Registry in Japan) score as a difficulty grading and time assessment tool. *J Am Coll Cardiol Interv*. 2011;4(2):213–221. <https://doi.org/10.1016/j.jcin.2010.09.024>
46. Opolski MP, Achenbach S, Schuhbäck A, et al. Coronary computed tomographic prediction rule for time-efficient guidewire crossing through chronic total occlusion: insights from the CT-RECTOR multicenter registry (Computed Tomography Registry of Chronic Total Occlusion Revascularization). *J Am Coll Cardiol Interv*. 2015;8(2):257–267. <https://doi.org/10.1016/j.jcin.2014.07.031>
47. Yu CW, Lee HJ, Suh J, et al. Coronary computed tomography angiography predicts guidewire crossing and success of percutaneous intervention for chronic total occlusion: Korean multicenter CTO CT registry score as a tool for assessing difficulty in chronic total occlusion percutaneous coronary intervention. *Circ Cardiovasc Imaging*. 2017;10(4):e005800. <https://doi.org/10.1161/CIRCIMAGING.116.005800>
48. Simsek B, Jaffer FA, Kostantinis S, et al. Preprocedural coronary computed tomography angiography in chronic total occlusion percutaneous coronary intervention: insights from the PROGRESS-CTO registry. *Int J Cardiol*. 2022;367: 20–25. <https://doi.org/10.1016/j.ijcard.2022.08.027>