



## OPEN ACCESS

<sup>1</sup>Thoracic Surgery Unit, Department of Thoracic Diseases, G.B. Morgagni-L. Pierantoni Hospital, University of Bologna, Forlì, Italy

<sup>2</sup>Pulmonary Operative Unit, Department of Thoracic Diseases, Morgagni-Pierantoni Hospital, AUSL of Romagna, Forlì, Italy

<sup>3</sup>Department of Respiratory Diseases and Allergy, Aarhus University Hospital, Aarhus, Denmark

<sup>4</sup>Thoracic Surgery Unit, Department of Thoracic Diseases, G.B. Morgagni-L. Pierantoni Hospital, AUSL della Romagna Rimini, Forlì, Italy

## Correspondence to

Dr Alessio Campisi, Thoracic Surgery Unit, Department of Thoracic Diseases, G.B. Morgagni-L. Pierantoni Hospital, University of Bologna, Forlì, Emilia-Romagna, Italy; alessio.campisi@studio.unibo.it

Received 14 April 2020

Revised 17 July 2020

Accepted 19 July 2020

## IMAGES IN THORAX

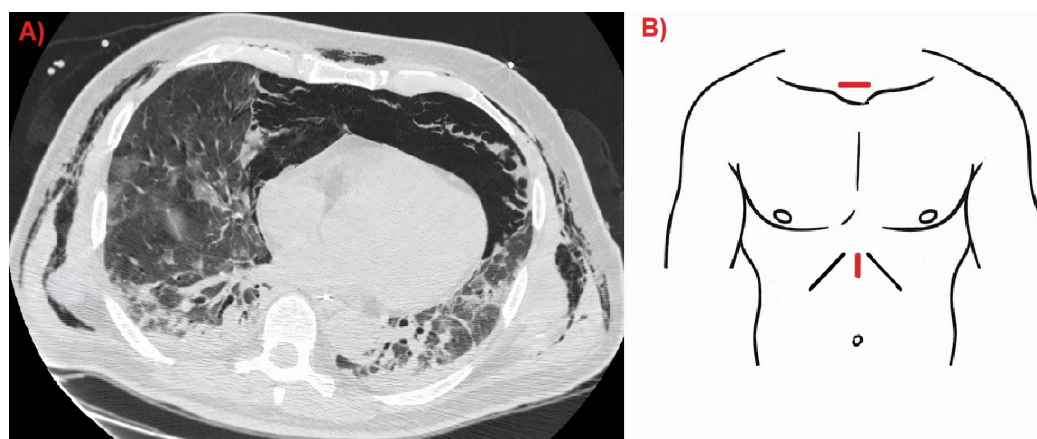
## Tension pneumomediastinum in patients with COVID-19

Alessio Campisi,<sup>1</sup> Venerino Poletti,<sup>2,3</sup> Angelo Paolo Ciarrocchi,<sup>1</sup> Maurizio Salvi,<sup>4</sup> Franco Stella<sup>1</sup>

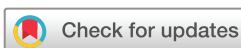A 65-year-old obese male, with no other comorbidities, was admitted to our intensive care unit for acute respiratory failure due to severe acute respiratory syndrome coronavirus 2 (SARS-CoV-2) infection. The patient was mechanically ventilated (intermittent positive pressure ventilation auto-flow mode with tidal volume of 6 mL/kg, positive end expiratory pressure (PEEP) 12 cmH<sub>2</sub>O, respiratory rate 20 breaths/min and fractional inspired oxygen (FiO<sub>2</sub>) to the lowest level to maintain arterial pO<sub>2</sub> in a range of 55–60 mm Hg) for 7 days before his condition abruptly worsened. He became haemodynamically unstable with changes in the cardiac electrical activity and hypotension unresponsive to catecholamines. An initial plain chest X-ray revealed widespread subcutaneous emphysema. Chest-CT demonstrated a massive tension pneumomediastinum. Mediastinal decompression was performed via two incisions, one at the sternal notch and one below the xiphoid process (figure 1). The posterior wall of the sternum was liberated of pericardial fat using blunt dissection with fingers and peanut sponge forceps. A chest tube was placed from the inferior incision and connected to a suction system to avoid any recurrence (figure 2). A laminar drain was inserted from the superior incision into the pretracheal space and connected to a closed system to reduce aerosolisation (Biotrol System 2 bag, B. Braun Medical). After the procedure the ventilation mode was modified, reducing the PEEP to 8 cmH<sub>2</sub>O and respiratory rate to 16 increasing the FiO<sub>2</sub> to 80%. The patient was haemodynamically stable and remained on mechanical ventilation for

6 more days followed by cycles of non-invasive ventilation for a further 5 days at which point the two tubes were removed and the incisions closed with simple interrupted sutures. He was transferred to a respiratory ward where he went on to make a full recovery and was discharged 2 weeks later. Tension pneumomediastinum is a life-threatening condition especially in critically ill patients. One of the most common situations in which it occurs is prolonged invasive and non-invasive ventilation with high end-expiratory pressure.<sup>1</sup> Due to the high number of patients with SARS-CoV-2 related respiratory infections being treated with this type of ventilation, we are seeing an increasing number of tension pneumomediastinum cases.

Air leakage from the alveolus occurs due to a pressure gradient between the alveolus and the perivascular sheaths. If the pressure gradient is maintained, the air tracks along the vascular sheaths to the mediastinum.<sup>1,2</sup> Due to increasing mediastinal pressure a compression of the great vessels occurs, leading to decreased venous return, hypotension and finally to cardiac collapse.<sup>3</sup> The initial diagnosis may be difficult due to associated subcutaneous emphysema that covers the underlying disease on chest X-ray. Treatment may be conservative, reducing the airway pressures, allowing permissive hypercapnia and increasing the oxygen percentage of the airflow to denitrogenate the mediastinal space.<sup>1,2</sup> Considering the fragility of patients with COVID-19, this approach is often insufficient, thus surgery may be necessary. In our experience, the approach we

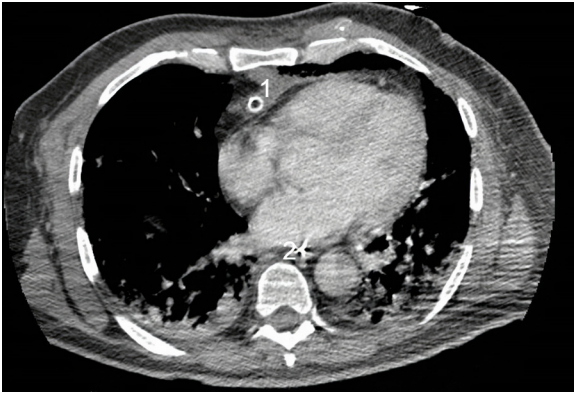


**Figure 1** (A) Chest-CT scan of a patient with COVID-19 with a tension pneumomediastinum. (B) Scheme of the surgical incision to decompress the mediastinum.



© Author(s) (or their employer(s)) 2020. No commercial re-use. See rights and permissions. Published by BMJ.

**To cite:** Campisi A, Poletti V, Ciarrocchi AP, et al. *Thorax* Epub ahead of print: [please include Day Month Year]. doi:10.1136/thoraxjnl-2020-215012



**Figure 2** CT scan showing significant radiological improvement with correct placement of the chest drain. (1) Chest tube. (2) Nasogastric tube.

described immediately improves the clinical condition of the patient with very low risks of complications, even for an inexperienced thoracic surgeon. (figure 2)

**Contributors** Conception and design: AC, VP, APC; administrative support: FS, VP; provision of study materials or patients: AC, MS; collection and assembly of data: AC, APC; data analysis and interpretation: APC, MS, FS; manuscript writing: AC, VP, APC; final approval of manuscript: all authors. All authors discussed the results and contributed to the final manuscript.

**Funding** The authors have not declared a specific grant for this research from any funding agency in the public, commercial or not-for-profit sectors.

**Competing interests** None declared.

**Patient consent for publication** Next of kin consent obtained.

**Provenance and peer review** Not commissioned; externally peer reviewed.

This article is made freely available for use in accordance with BMJ's website terms and conditions for the duration of the covid-19 pandemic or until otherwise determined by BMJ. You may use, download and print the article for any lawful, non-commercial purpose (including text and data mining) provided that all copyright notices and trade marks are retained.

## REFERENCES

- 1 Kouritas VK, Papagiannopoulos K, Lazaridis G, *et al.* Pneumomediastinum. *J Thorac Dis* 2015;7:S44–9.
- 2 Zhou C, Gao C, Xie Y, *et al.* COVID-19 with spontaneous pneumomediastinum. *Lancet Infect Dis* 2020;20:510.
- 3 Weaver JB, Kumar AB. Tension pneumomediastinum: a rare cause of acute intraoperative circulatory collapse in the setting of unremarkable TEE findings. *J Clin Anesth* 2017;37:136–8.