

CASE REPORT

Carotid access for percutaneous coronary intervention

Matthias De Boule¹  | Erik Debing¹ | Dries Belsack² | Bert Vandeloos¹

¹Centrum voor Hart- en Vaatziekten, Vrije Universiteit Brussel (VUB), Universitair Ziekenhuis Brussel (UZ Brussel), Brussels, Belgium

²Department of Radiology, Vrije Universiteit Brussel (VUB), Universitair Ziekenhuis Brussel (UZ Brussel), Brussels, Belgium

Correspondence

Matthias De Boule, Universitair Ziekenhuis Brussel, Laarbeeklaan 101, 1090 Jette, Belgium.
Email: matthias.deboulle@gmail.com

Funding information

None

Abstract

Transcarotid percutaneous coronary intervention is feasible and safe and can be considered as an ultimate alternative in cases where conventional peripheral vascular access is unavailable.

KEYWORDS

atherosclerosis, drug-eluting stent, Leriche syndrome

1 | INTRODUCTION

Vascular access for percutaneous coronary intervention (PCI) is usually obtained through the radial or femoral, and to lesser extent the brachial or ulnar artery. We describe the transcarotid approach for PCI in a patient with severe peripheral artery disease. No adverse neurological or cardiac events were observed.

Vascular access for percutaneous coronary intervention (PCI) is gained via a peripheral artery, mainly the radial or femoral artery. Other less frequently used access sites include the brachial and ulnar artery.¹ In this article, we present a patient in which conventional arterial access sites were inaccessible due to severe peripheral artery disease, and where access was obtained at the left carotid artery for PCI of the left anterior descending coronary artery (LAD).

2 | CASE REPORT

A 64-year-old woman, without prior cardiac history, was admitted to the hospital with worsening dyspnea on

exertion, orthopnea, and swelling of the lower limbs. She had hypercholesterolemia and prediabetes and was an active smoker. Clinical examination showed signs of congestion. A transthoracic echocardiogram revealed a dilated left ventricle with severe left ventricular dysfunction, with a left ventricular ejection fraction of 25%. The diagnosis of congestive heart failure was made. Medical heart failure therapy was initiated.

To rule out underlying coronary artery disease, an invasive coronary angiography was planned. However, vascular access could not be obtained despite several attempts via different arterial access points, both radial and femoral. A computed tomography angiography (CTA) and a coronary computed tomography angiography (CCTA) were performed. The CTA showed extensive peripheral artery disease, with a total occlusion of the infrarenal aorta and both common iliac arteries (Leriche Syndrome), a total occlusion of both subclavian arteries, and a critical stenosis of the brachiocephalic artery (Figure 1), explaining the inability to obtain access through conventional access sites. Furthermore, there was a severe stenosis of the left internal carotid artery, and a mild stenosis of the left common

This is an open access article under the terms of the Creative Commons Attribution-NonCommercial License, which permits use, distribution and reproduction in any medium, provided the original work is properly cited and is not used for commercial purposes.

© 2021 The Authors. *Clinical Case Reports* published by John Wiley & Sons Ltd.

carotid artery. However, arterial access could be obtained proximally at the left carotid artery. The CCTA showed

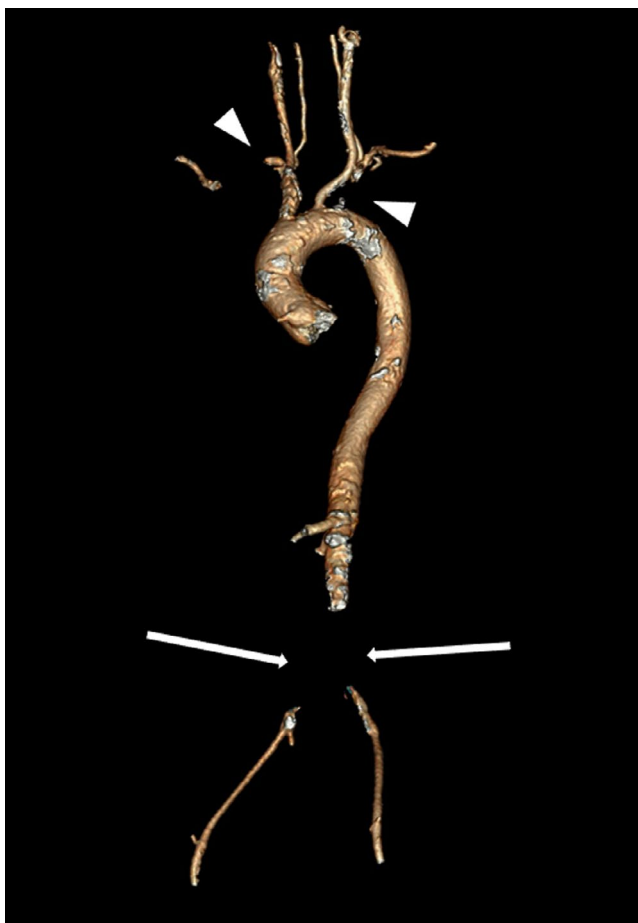

FIGURE 1 Computed tomography angiography showing a total occlusion of the infrarenal aorta and both common iliac arteries (arrows), and a total occlusion of both subclavian arteries (arrowheads)

extensive coronary calcifications, with a severe stenosis in the LAD, a moderate stenosis in the right coronary artery (RCA) and a moderate stenosis in the left circumflex artery (LCx), and thus justified the need for coronary artery revascularization.

After multidisciplinary Heart Team discussion, involving the vascular surgeon, the decision was made to perform PCI of the LAD via the left carotid artery.

The configuration of the catheterization laboratory was adjusted to enable carotid access site preparation and PCI (Figure 2). The procedure was performed under general anesthesia. First, the vascular surgeon made the skin incision along the anterior border of the sternocleidomastoid muscle. The subcutaneous tissue and platysma were incised. The sheath over the common carotid artery was opened and the artery encircled with a vessel loop. After that, a retrograde puncture of the artery was performed and a guidewire with a 6 French sheath was positioned in the aortic arch under fluoroscopy. To ensure that the sheath stayed fixated, it was sutured to the sternocleidomastoid muscle (Figure 3). A diagnostic coronary angiogram was then made by the interventional cardiologist. The presence of a severe stenosis in the mid segment of the LAD and moderate stenoses in the RCA and LCx were confirmed. PCI was performed, with deployment of a XIENCE Sierra™ 2.75 × 38 mm drug-eluting stent (Abbott) in the mid LAD. Adequate stent expansion and complete stent apposition were achieved, confirmed by angiography and intravascular ultrasound (IVUS) (Figure 4). Finally, the vascular surgeon removed the sheath, closed the puncture hole with a prolene suture, and sutured the overlying tissues and skin.

The length of the combined procedure was 111 minutes, with a total fluoroscopy time of 14 minutes. The total dose area product (DAP) was 25.311 Gy.cm², with a total

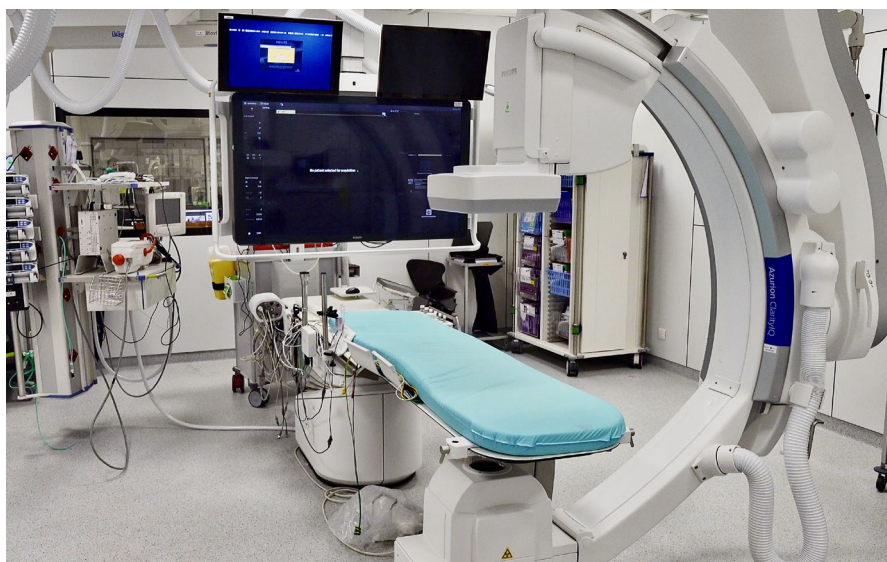

FIGURE 2 Configuration of the catheterization laboratory, which allowed for carotid access site preparation and percutaneous coronary intervention

air kerma (K) of 318 mGy. A total of 150 ml of iodinated contrast was used. During the procedure, 5000 units of unfractionated heparin were given. The patient received dual antiplatelet therapy, consisting of acetylsalicylic acid 80 mg and clopidogrel 75mg once daily.

During the postoperative observation period, the patient showed good vital signs, no chest pain, and no neurological symptoms. She was discharged from the hospital the next day.

3 | DISCUSSION

The transcarotid approach has been described as a viable alternative for vascular access in several other procedures,

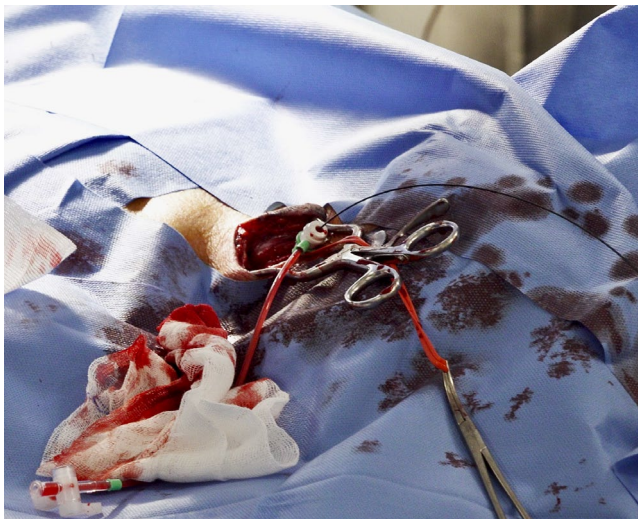

FIGURE 3 Perioperative view, showing the left common carotid artery with a 6 French sheath fixated to the sternocleidomastoid muscle

such as aortic repair interventions,² cerebral angiography,³ endovascular intervention for acute ischemic stroke,^{4,5} complex pediatric cardiac interventions,^{6,7} and transcatheter aortic valve implantation (TAVI).⁸⁻¹⁰ One case of a diagnostic coronary catheterization via transcarotid approach has also been described.¹¹ This is, to our knowledge, the first reported adult case of a PCI via transcarotid approach.

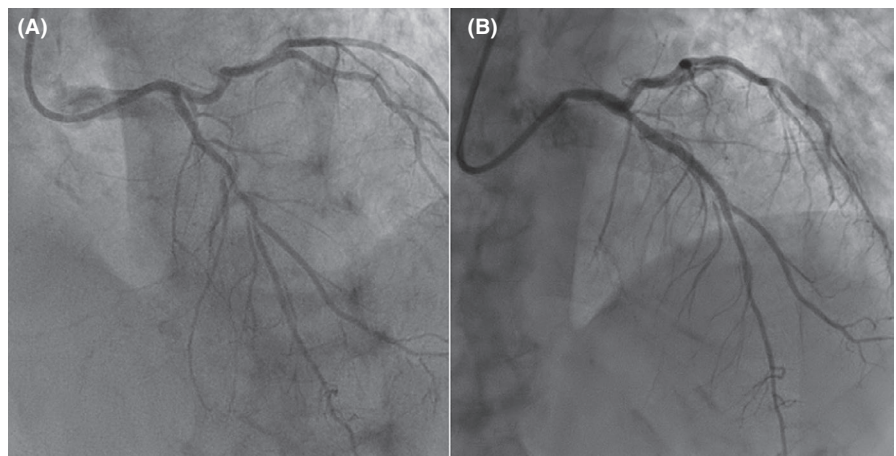
In a recent meta-analysis, comparing transcarotid versus transfemoral TAVI, transcarotid TAVI seems to be non-inferior to transfemoral TAVI in terms of overall mortality and short-term neurological complications such as transient ischemic attack and stroke.⁸ As such, safety for performing transcarotid percutaneous interventions has been demonstrated. Since our current experience is limited to this case alone, we cannot make general conclusions regarding the safety of PCI via transcarotid approach. Nonetheless, our patient experienced no adverse neurological or cardiac events during or after the procedure.

For this procedure, the configuration of the catheterization laboratory was different than the usual configuration used for PCI via the radial or femoral approach. Apart from this adjusted catheterization laboratory configuration, the materials used for the PCI were the same as what is normally used, including a standard sheath and standard coronary catheters.

4 | CONCLUSION

Our case demonstrates that transcarotid PCI is feasible. The transcarotid approach can be considered as an ultimate alternative in cases where conventional peripheral vascular access for PCI is unavailable.

FIGURE 4 Angiographic view of the severe mid left anterior descending artery stenosis, before (A) and after (B) percutaneous coronary intervention with implantation of a drug-eluting stent



ACKNOWLEDGMENTS

We thank Margot Allonsius for taking and processing the periprocedural images. Published with written consent of the patient.

CONFLICT OF INTEREST

All authors have no conflict of interest to disclose.

AUTHOR CONTRIBUTIONS

Matthias De Boule: Literature research and manuscript writing. Eric Debing: Manuscript correction and writing. Dries Belsack: Data processing and manuscript correction. Bert Vandeloo: Literature research and manuscript correction.

ETHICAL APPROVAL

The patient gave informed consent and agreed to the use of clinical data for scientific purposes and publication.

DATA AVAILABILITY STATEMENT

The data that support the findings of this study are available on request from the corresponding author. The data are not publicly available due to privacy or ethical restrictions.

ORCID

Matthias De Boule  <https://orcid.org/0000-0003-2015-3074>

REFERENCES

1. Kolkailah AA, Alreshq RS, Muhammed AM, Zahran ME, Anas El-Wegoud M, Nabhan AF. Transradial versus transfemoral approach for diagnostic coronary angiography and percutaneous coronary intervention in people with coronary artery disease. *Cochrane Database Syst Rev*. 2018;4:CD012318.
2. Wee I, Syn N, Choong A. Carotid access for aortic interventions: genius or madness? *Vasc Endovasc Rev*. 2018;23(1):38-42.
3. Bauer J, Salazar JL, Sugar O, Pawl RP. Direct percutaneous cerebral angiography in neurosurgical practice. *J Neurosurg*. 1980;52(4):525-528.
4. Cilingiroglu M, Hakeem A, Wholey M, Goktekin O. Direct carotid access for endovascular management of acute ischaemic stroke. *EuroIntervention*. 2017;13(9):e1120-e1121.
5. Colombo E, Rinaldo L, Lanzino G. Direct carotid puncture in acute ischaemic stroke intervention. *Stroke Vasc Neurol*. 2020;5(1):71-79.
6. Davenport JJ, Lam L, Whalen-Glass R, et al. The successful use of alternative routes of vascular access for performing pediatric interventional cardiac catheterization. *Catheter Cardiovasc Interv*. 2008;72(3):392-398.
7. Polat TB. Use of percutaneous carotid artery access for performing pediatric cardiac interventions: Single-center study. *Ann Pediatr Cardiol*. 2020;13(1):16-24.
8. Wee IJY, Stonier T, Harrison M, Choong AMTL. Transcarotid transcatheter aortic valve implantation: A systematic review. *J Cardiol*. 2018;71(6):525-533.
9. Folliguet T, Laurent N, Bertram M, et al. Transcarotid transcatheter aortic valve implantation: multicentre experience in France. *Eur J Cardio-Thorac Surg*. 2018;53(1):157-161.
10. Modine T, Lemesle G, Azzaoui R, Sudre A. Aortic valve implantation with the CoreValve ReValving System via left carotid artery access: first case report. *J Thorac Cardiovasc Surg*. 2010;140(4):928-929.
11. Lichtenwalter C, Guleserian KJ, Holper EM. Carotid access for cardiac catheterization: revisiting the past for a complex intra-arterial approach. *Cardiovasc Revasc Med*. 2011;12(2):134.e1-134.e5.

How to cite this article: De Boule M, Debing E, Belsack D, Vandeloo B. Carotid access for percutaneous coronary intervention. *Clin Case Rep*. 2021;00:e04739. <https://doi.org/10.1002/ccr3.4739>