

Tracing: A Simple Interpretation Method for the DIEP Flap CT Angiography to Help Operative Decision-making

Lars Johan Sandberg, MD, FACS,
FEBOPRAS*†

Summary: CT angiography (CTA) is an established technique that allows preoperative planning in DIEP flap reconstruction. However, innovative technological developments with extensive amounts of information require processing of data. It also requires user knowledge to interpret findings. Descriptions by radiologists are many times disappointingly limited to caliber and exit points of the perforator from the rectus fascia. Many DIEP flap surgeons similarly fail to utilize the CTA to its full extent. This is likely due to information overload. By tracing the DIEA on the CTA on a computer screen, using an ordinary ballpoint pen and a white sheet of paper, the surgeon can create a stylistic map of the dissectional-path of the DIEA. The map illustrates unusual branching patterns, perforator caliber and location, interconnections between individual perforators (or lack thereof), length of intramuscular dissection, and also rectus abdominis muscle intersections. The mapping can help in the choice of perforator(s) and may also speed up decision-making during surgical dissection. A penciled map also eases a round-table discussion, if multiple surgeons are involved in the operation. The map can also easily be brought to the operating room for guidance. Tracing is a user-friendly, time-efficient, intuitive, low-cost, and low-tech method that generates data that are easy to interpret, easy to share, and easy to discuss with other surgeons. The method is also not dependent on a radiologist for interpretation. (*Plast Reconstr Surg Glob Open* 2020;8:e3218; doi: 10.1097/GOX.0000000000003218; Published online 25 November 2020.)

INTRODUCTION

The modern surgeon is exposed to large amounts of data, both clinical and administrative.¹ Excessive amounts of unprocessed data may get ignored. The fine and helpful details hidden in a CTA scan need to be extracted and highlighted to get the full value of the examination.²⁻⁴

In an effort to process relevant data available in a CTA for DIEP flap reconstruction, the tracing system was developed over time by the author to map the perforator and DIEA dissectional-path. Tracing answers the questions about perforator caliber and location, interconnections (or lack thereof) between individual perforators, unusual branching patterns, length of intramuscular dissection, and rectus inscriptions in relation to perforators. All these factors can affect dissection choices.

From the *Department of Plastic Surgery, Karolinska University Hospital, Stockholm, Sweden; and †Department of Plastic Surgery, Rikshospitalet, Oslo, Norway.

Received for publication April 8, 2020; accepted September 3, 2020.

Copyright © 2020 The Author. Published by Wolters Kluwer Health, Inc. on behalf of The American Society of Plastic Surgeons. This is an open-access article distributed under the terms of the [Creative Commons Attribution-Non Commercial-No Derivatives License 4.0 \(CCBY-NC-ND\)](#), where it is permissible to download and share the work provided it is properly cited. The work cannot be changed in any way or used commercially without permission from the journal.

DOI: 10.1097/GOX.0000000000003218

The mapping can help in the choice of a perforator and also speed up decision-making during the dissection. A penciled map also allows easier round-table discussions if multiple surgeons are involved in the operation.

The following description provides an easy, low-cost method that generates data that are easy to interpret, easy to share, and easy to discuss with other surgeons. The method is also not dependent on a radiologist for interpretation as just basic radiological skills are needed. (**See Video 1 [online]**, which displays the CTA tracing technique step by step.)

METHOD

A CTA of the abdomen with coronal and cross-sectional views is used. Software with stacking of images or “slab function” is not necessary but can be used.

1. The first step is to analyze cross-sectional views to find large and appropriate perforators. Their relative location to the umbilicus is assessed. Measures from the midline

Disclosure: The author has no financial interest to declare in relation to the content of this article.

Related Digital Media are available in the full-text version of the article on www.PRSGlobalOpen.com.

to the perforators are performed. A note is made about the adequacy and rough location of these perforators.

2. The actual tracing is performed in a coronal view. A regular white paper sheet is applied to the computer screen (Fig. 1). The computer screen works as a light table for transillumination.
3. An ordinary ballpoint pen is then used to mark the umbilicus, as it exits from the fascia. The umbilicus serves as a landmark for all other structures.
4. Next, the origin of the DIEA is found and marked, as it takes off from the external iliac artery.
5. Scrolling step-by-step is then done. We trace each step with a ball point pen, following the arterial flow from its origin all the way to the perforator level. (Figs. 2, 3). The usually convex configuration of the abdomen allows a serial “step-up-scroll” in the coronal view to follow the artery from its origin to the perforator as it exists the fascia.
6. All branches are marked. Once the subcutaneous level is reached, the take-off of the perforator can be seen, to verify the previous findings on axial views.
7. Next, the rectus muscle is reviewed in coronal views for assessment of rectus muscle inscriptions, which are additionally marked on the map. This helps determine how complicated the dissection for a specific perforator may be.
8. The cross-sectional view is then used again, to locate the point where the intramuscular course of the




Fig. 2. Tracing the DIEA from its origin at the external iliac artery in a coronal view—full-screen view is used. The umbilical exit from the fascia level has already been marked as a landmark. Scrolling of the CTA scan step-by-step and tracing in an antegrade fashion all the way up to the fascial exit point of the perforator(s) is then performed.

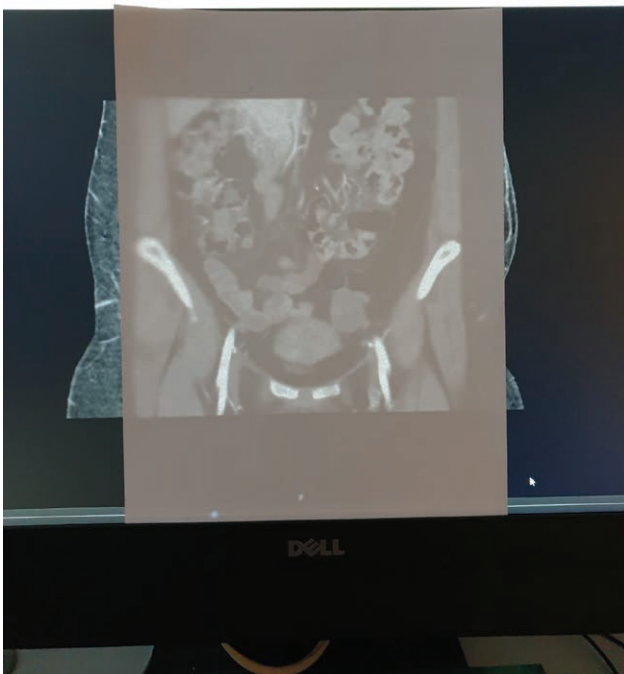



Fig. 1. A white paper sheet is attached to the computer screen, which acts as a transilluminating light board.

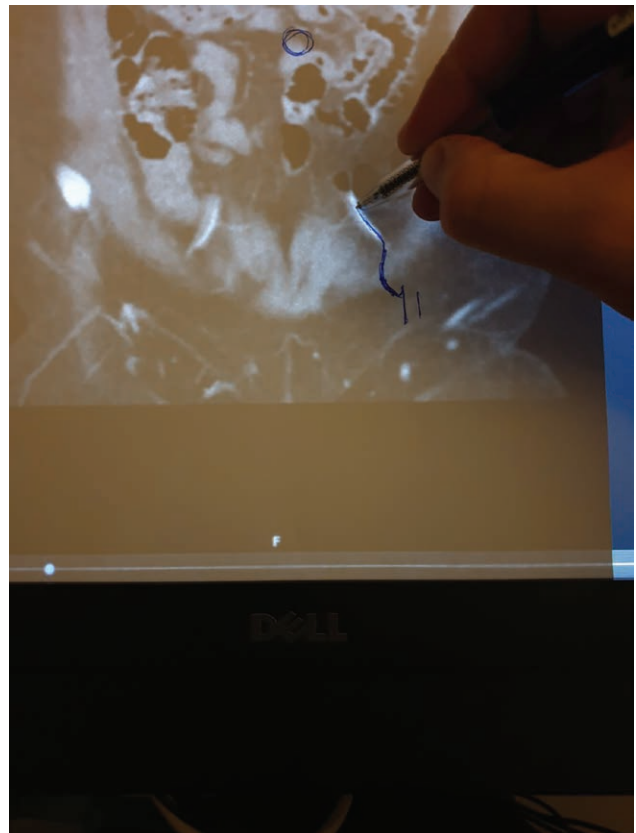


Fig. 3. A continuous map of the vessel is created by scrolling step-by-step to trace the DIEA.

perforator ends. This usually coincides with a branching point of the pedicle.

9. Finally, measures are performed in the coronal view from the perforators fascial exit point to the branching point from the pedicle to determine intramuscular-path-length.

DISCUSSION

Radiologists reading the CTA are asked to translate a series of pictures into a short and comprehensible report. This report may serve as the basis for the planning of a procedure that most radiologists likely have never seen and have little insight about. Many plastic surgeons however are not used to reviewing CT scans and for that reason fail to use the CTA to its full potential, leading to great informational waste.

Tracing the CTA instead tries to visualize the important facts for the DIEP flap dissection in the format of a pictorial report. The surgeon who performs the DIEP flap procedure has ownership of the patient and full insight about the demands of a DIEP flap. The dissection of the DIEA in itself is a surgical “tracing” of the vessels, but now in a retrograde fashion. The tracing process allows the surgeon to preoperatively visualize the path of dissection. Potentially difficult steps of the vessel dissection, such as sharp unexpected 90-degree-turns and unusual branching patterns, can be noted ahead of dissection. The map can also be used to make a preoperative preliminary choice of perforator/s for the flap. A clear operative plan can be devised. With additional CTA information, surgical acumen can be improved.

If a team with multiple surgeons are operating, the map can also be used for round-table discussions. In the experience of the author a 3-dimensional reconstruction of perforators is usually not valuable due to the small caliber of the vessels and poor quality of the pictorial reconstruction.

The map can later easily be brought into the operating room. Intraoperatively the measures can be transferred onto the fascia relative to the umbilical landmark with a regular marking pen.

Not all surgeons use CTA for DIEP flap surgery. Many proficient surgeons are trained to use only intraoperative findings as a guide to dissection. CTAs are however now very common and mainstream.⁵ If a CTA is ordered, it should be used to its full extent.

In the case presented in Figure 4, the 2 perforators on the right side of the patient may be mistaken to be located on the same branch if a full tracing is not performed, thus underestimating the amount of dissection needed. In this particular case, the left-side single perforator (with a straight, uncomplicated course) was successfully used as a single perforator flap for unilateral delayed breast reconstruction.

CONCLUSIONS

Using tracing-technique of the DIEA with a ballpoint-pen and a regular paper sheet helps extract relevant DIEP flap data. The method is intuitive, low-tech, low cost, easy to share, and not dependent on a radiologist for interpretation. It also helps visualize the different steps in the path

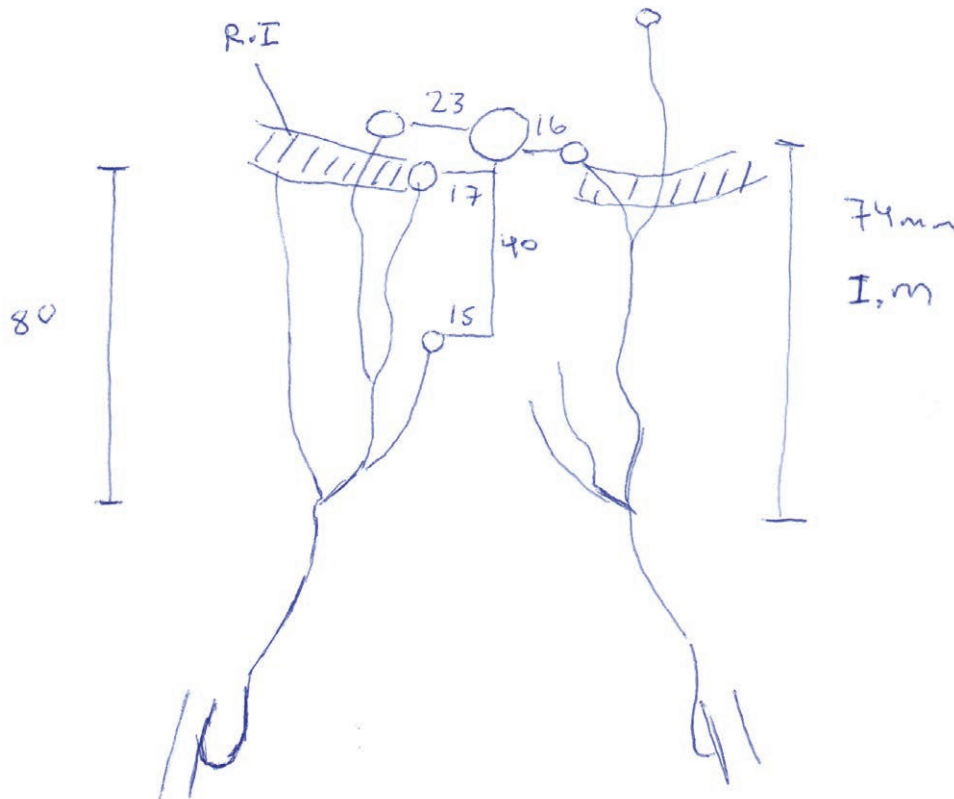


Fig. 4. The full map, including rectus muscle inscriptions (RI) marked, measures of distance from the perforator to the umbilicus, and measures of intramuscular dissection distance (IM).

of dissection. The map may help in perforator choice and may expedite intraoperative decision-making. CTA tracing may also help communicate complex findings to a group of surgeons in a simple format. Further studies are needed.

Lars Johan Sandberg, MD, FACS, FEBOPRAS

Department of Plastic Surgery

Karolinska University Hospital

171 56 Stockholm, Sweden

E-mail: johansandberg@hotmail.com

REFERENCES

1. Wolfe SA. Information overload in the digital age. *Plast Reconstr Surg.* 2003;112:1473–1474.
2. Rozen WM, Bhullar HK, Hunter-Smith D. How to assess a CTA of the abdomen to plan an autologous breast reconstruction. *Gland Surg.* 2019;8(suppl 4):S291–S296.
3. Leung R, Chae MP, Tobin V, et al. In-vivo quantitative mapping of the perforasomes of deep inferior epigastric artery perforators. *Plast Reconstr Surg Glob Open.* 2018;6:e1960.
4. Shen Y, Huang J, Dong MJ, et al. Application of computed tomography angiography mapping and located template for accurate location of perforator in head and neck reconstruction with anterolateral thigh perforator flap. *Plast Reconstr Surg.* 2016;137:1875–1885.
5. Rodkin B, Hunter-Smith DJ, Rozen WM. A review of visualized preoperative imaging with a focus on surgical procedures of the breast. *Gland Surg.* 2019;8(suppl 4):S301–S309.