



Exclusive endoscopic transcanal approach to lateral skull base lesions: Institutional experience of 3 cases

Sidharth Pradhan, Preetam Chappity*, Anindya Nayak, Pradeep Pradhan, Pradipta K. Parida

All India Institute of Medical Sciences, Bhubaneswar Department of Otorhinolaryngology and Head & Neck Surgery, 1st floor, AIIMS, Bhubaneswar, Sijua, Bhubaneswar, Odisha, 751019, India

ARTICLE INFO

Article history:

Received 11 July 2020
Received in revised form
20 August 2020
Accepted 27 August 2020

Keywords:

Transcanal endoscopic approach
Petrous cholesteatoma
Glomus tympanicum
Lateral skull base

ABSTRACT

Introduction: Majority of petrous bone and lateral skull base pathologies are benign in nature. The complex anatomy usually warrants an extensive approach with associated morbidity.

Case summary: Two cases of petrous bone cholesteatoma (1 congenital cholesteatoma with facial palsy and 1 acquired cholesteatoma) and a case of glomus tympanicum were treated with exclusive endoscopic transcanal approach. The cases of petrous cholesteatoma were addressed with trans-promontorial and infra-cochlear approaches. The mean operative time was approximately 140 min. No CSF otorrhoea was noticed in the post-operative period. The average period of hospital stay was 3.7 days.

Conclusion: In the subset of cases with limited benign disease an endoscopic trans-canal approach is a better alternative to an external approach. It decreases operative time, blood loss, chance of meningitis, morbidity and hospital stay. The lack of depth perception is a major hurdle which can be come over by experience in endoscopic middle ear surgery. This approach can create direct access to cochlea/petrous apex/internal auditory canal (IAC)/Supra-geniculate ganglion region.

© 2020 PLA General Hospital Department of Otolaryngology Head and Neck Surgery. Production and hosting by Elsevier (Singapore) Pte Ltd. This is an open access article under the CC BY-NC-ND license (<http://creativecommons.org/licenses/by-nc-nd/4.0/>).

1. Introduction

Lateral skull base lesions have always been a major dilemma for neurosurgeons and otolaryngologists alike being an anatomic region where the two domains coincide. Presence of important structures such internal carotid artery (ICA), facial nerve and otic capsule frequently presents a challenge to the surgeon. Moreover, extensive surgical approaches are often required despite the benign and limited nature of the lesions in this anatomical region (Marchioni et al., 2015). Majority of approaches used at present are open and microscope dependant and include the transpetrous (translabyrinthine/transotic/transcochlear), retrosigmoid or middle cranial fossa routes (Marchioni et al., 2015). All of these approaches cause significant morbidity due to brain retraction, CSF (Cerebrospinal fluid) otorrhoea and neurovascular manipulation (Marchioni et al., 2015).

Endoscopic techniques have gradually found their way in ear

surgeries since 1990s (Marchioni et al., 2015; Thomassin et al., 1993; Presutti et al., 2008). Initially used to assist microscopic ear surgeries, endoscopic techniques have now replaced the microscope in many middle ear surgeries (Marchioni et al., 2010a, 2011a, 2011b; Tarabichi, 2004). With the evolution of endoscopic techniques, they are being gradually used for management of specific lateral skull base lesions (Presutti et al., 2013; Marchioni et al., 2017a, 2017b, 2020). The endoscopic transcanal route additionally avoids any external incision using the natural corridor of external auditory canal (EAC) and significantly reduces morbidity associated with open approaches (Marchioni et al., 2015).

We present our experience with the endoscopic transcanal approach applied in a case of glomus tympanicum and 2 cases of lateral skull base approach (transpromontorial and infracochlear) for petrous bone cholesteatoma.

2. Case summary

We had 3 cases in which we adopted an exclusive endoscopic transcanal approach.

* Corresponding author.

E-mail address: drcpreetam@aiimsbhubaneswar.edu.in (P. Chappity).

Peer review under responsibility of PLA General Hospital Department of Otolaryngology Head and Neck Surgery.

2.1. Operative technique

The surgery is undertaken using 3 mm 0° endoscope (Richard Wolf, Knittlingen, Germany). A circumlunar incision is given at the bony cartilaginous junction to create a tympanomeatal flap, which may be 270° (superiorly based in inferiorly placed lesions and inferiorly based in superior lesions) or circumferential (360°) in larger lesions. Canaloplasty along with drilling of tympanic annulus is then undertaken to allow adequate exposure of the part of petrous apex being addressed and allow instrumentation in the narrow corridor. The epitympanum is then drilled to expose the malleo-incudal joint and both these ossicles are removed after cutting the tensor tympani tendon. This step can be skipped in the infracochlear approach (Fig. 1).

In the *infracochlear approach*, the hypotympanic cells are drilled within the internal carotid artery (ICA) anteriorly, jugular bulb inferiorly and the promontory superiorly. Following removal of the cholesteatoma by blunt dissection using a ball probe, the petrous apex is examined endoscopically for any residual disease (Figs. 1 and 4).

In the *transpromontorial approach*, a portion of the remnant cochlea is drilled to allow exposure to the internal auditory canal (IAC). The anterior limit of drilling again remains the ICA with the oval window forming the posterior limit. The IAC is checked endoscopically for any CSF leak following the removal of disease by blunt dissection (Figs. 1 and 3).

The cavity is then filled with fat and fascia to plug any CSF leak if present with reposition of the tympanomeatal flap and filling the EAC with medicated gelfoam (Fig. 1).

2.2. Case 1

A 50 year old female presented with complaints of tinnitus and aural fullness in her right ear for duration of 5 months. Otoscopy revealed a reddish mass behind the tympanic membrane (Fig. 2). Audiometry and tympanometry revealed moderate conductive hearing loss (45dBHL/15dBHL) and Type B tympanogram respectively. Facial nerve status was normal. High resolution CT (HRCT) revealed a soft tissue density in the mesotympanum overlying promontory medial to tympanic membrane with preserved ossicles

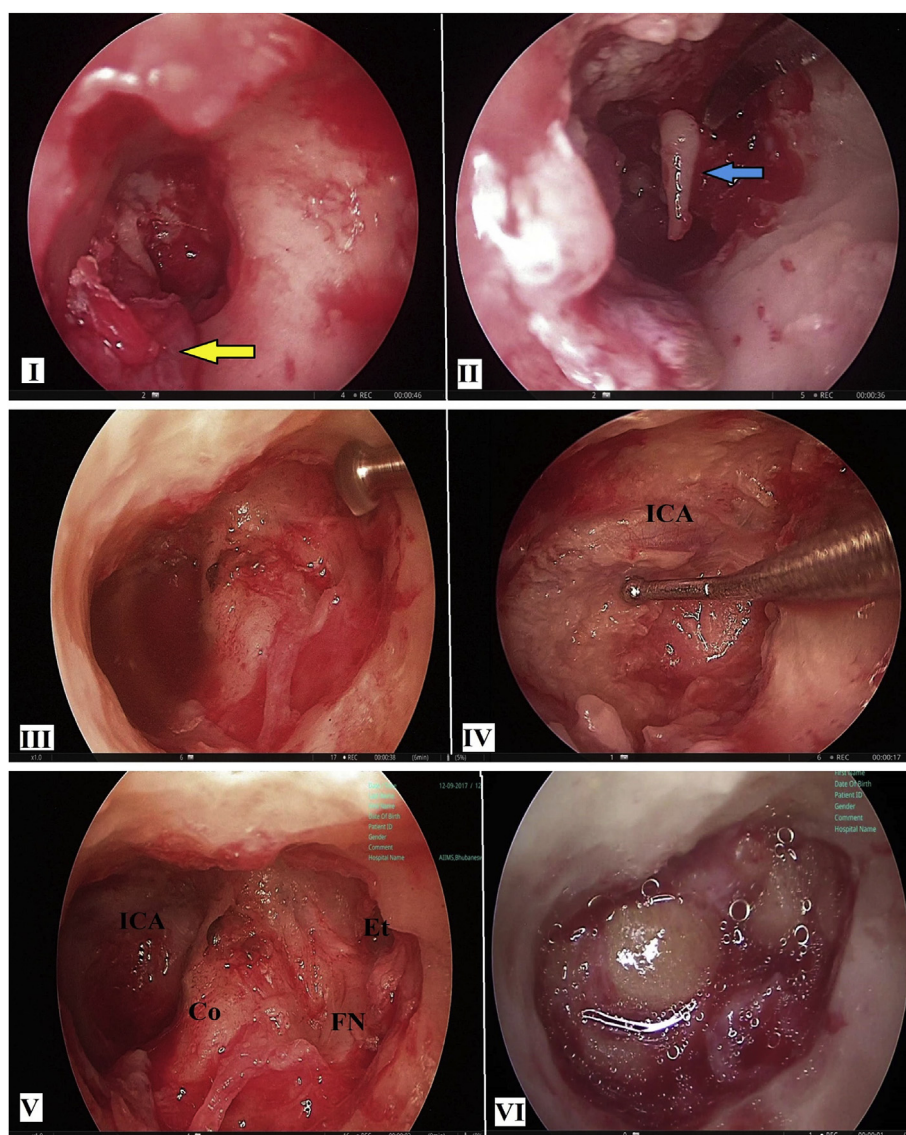


Fig. 1. Operative technique – (I) Elevation of tympanomeatal flap (Superiorly based/Inferiorly based/Circumferential); (II) Removal of malleus and incus (blue arrow); (III) Drilling of tympanic annulus and canaloplasty; (IV) Blunt dissection of epithelium using ball probe; (V) Endoscopic assessment following dissection; (VI) Packing the defect with fat and fascia.

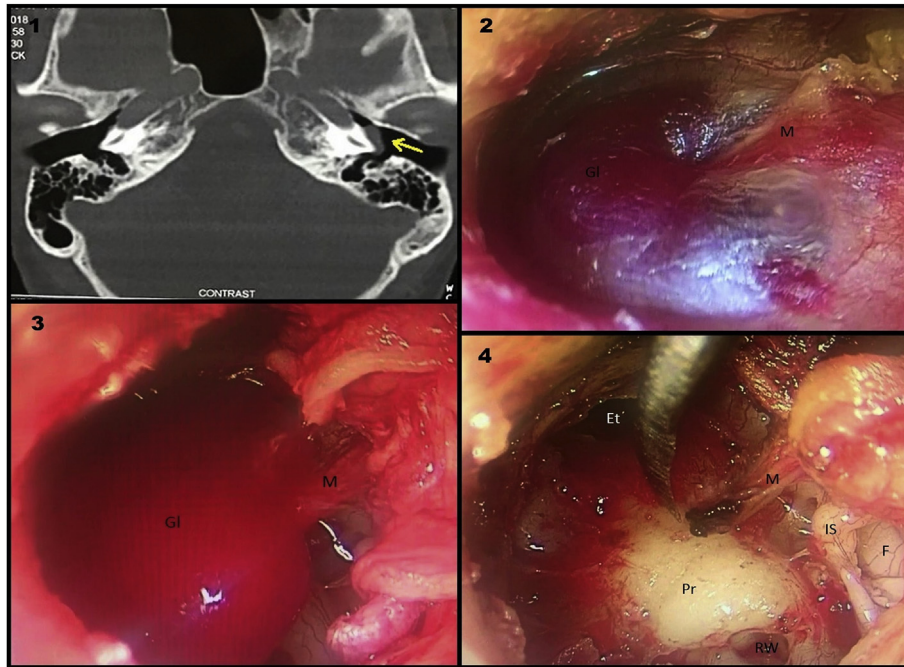


Fig. 2. (1) Showing the Soft tissue density overlying promontory in HRCT temporal bone; (2) Oto-endoscopic picture of the glomus tympanicum; (3) Intra-operative endoscopic picture of the tumor after raising of the tympanomeatal flap; (4) Endoscopic picture post removal tumor.
 M = Malleus, Gl = Glomus tympanicum, Pr= Promontory, F= Facial nerve (Horizontal segment), IS= Incudo-stapedial joint, RW = Round window niche, Et = Eustachian tube.

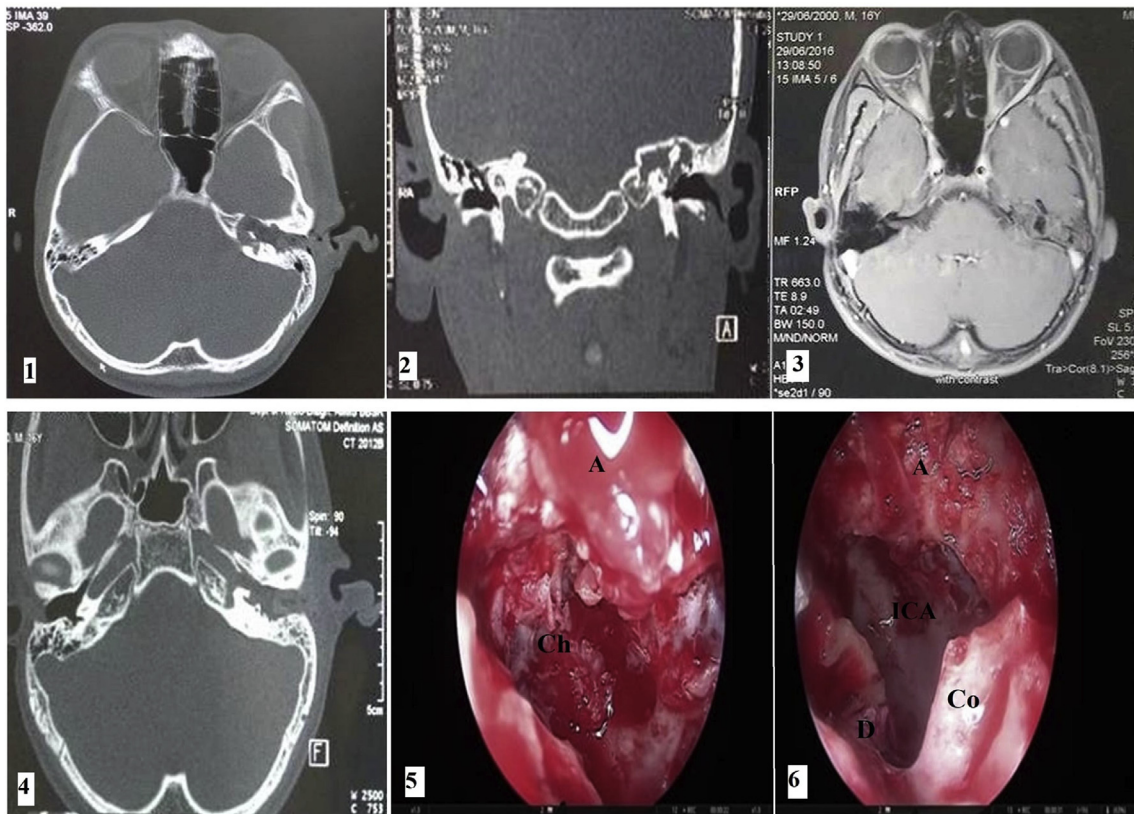


Fig. 3. (1) (2) HRCT showing soft tissue density extending to petrous apex with extensive destruction of vestibule and upper part of cochlea; (3) MRI finding of the lesion; (4) Post-operative HRCT showing remnant portion of cochlea; (5) Intraoperative endoscopic picture of the cholesteatoma; (6) Endoscopic picture of petrous apex post removal of cholesteatoma.
 A = Anterior, Ch = Cholesteatoma, ICA= Internal carotid artery, Co= Remnant cochlea, D = Dura of Internal auditory canal and site of CSF leak.

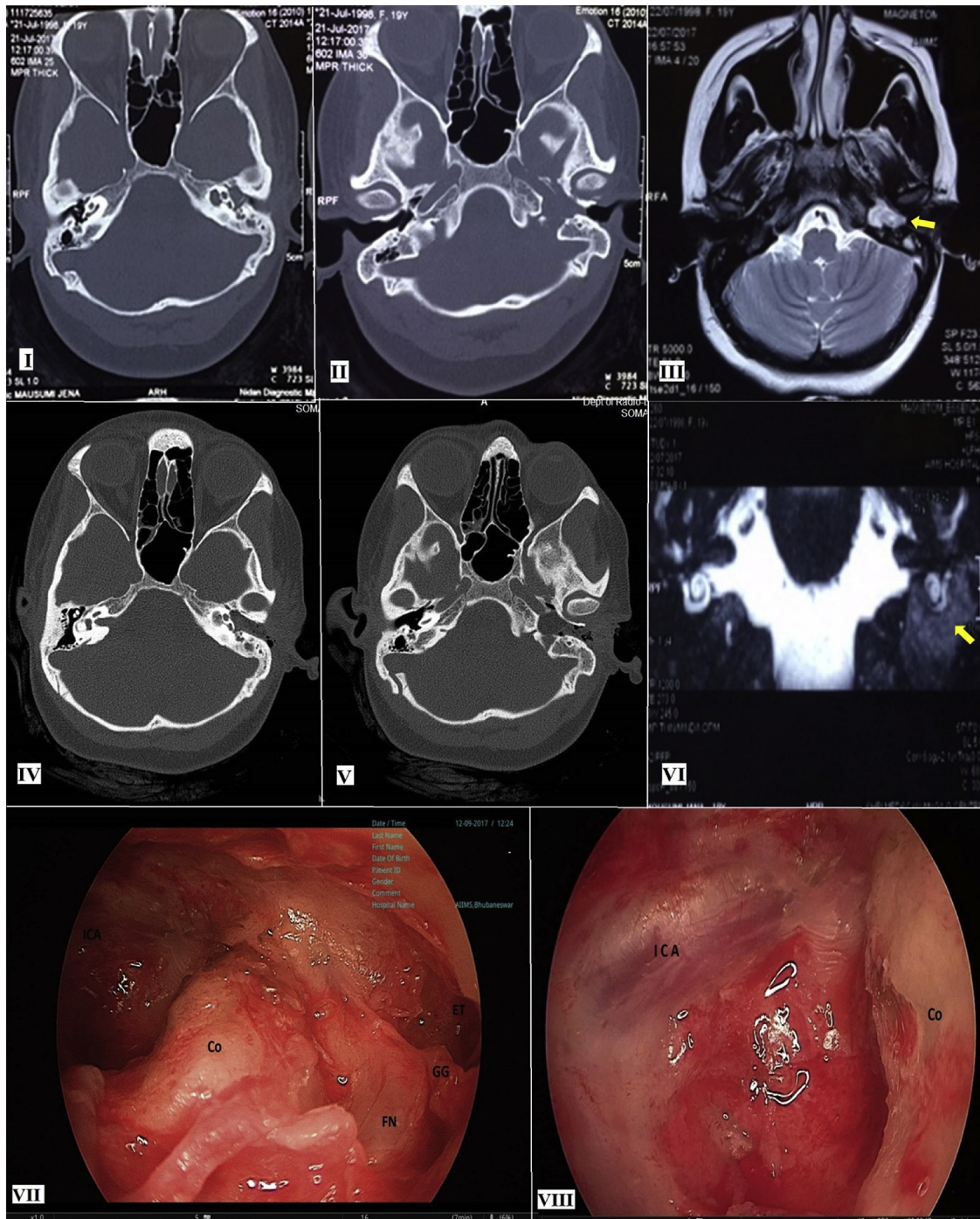


Fig. 4. (I) (II) Axial HRCT showing the lesion involving petrous apex; (IV) (V) Corresponding Axial HRCT post-operatively showing fat and fascia packed cavity; (III) (VI) Axial and coronal MRI showing the lesion involving the infra-cochlear corridor; (VII) Intra-operative endoscopic picture post removal of cholesteatoma; (VIII) Endoscopic picture showing the petrous apex and exposed ICA.

ICA= Internal carotid artery, Co= Cochlea, FN= Facial nerve (horizontal segment), GG = Geniculate ganglion, ET = Eustachian tube.

(Fig. 2). CEMRI showed the soft tissue to be isointense on T1 with mild post-contrast enhancement and hyperintense on T2. With informed consent, an endoscopic transcanal approach was adopted approaching the middle ear by raising a superiorly based 270° tympanomeatal flap. The tumour was cauterized partly, excised carefully in toto and sent for histopathological (HPE) analysis (Fig. 2). Ossicles were found to be intact. The flap was then repositioned back and EAC packed with medicated gelfoam. The final HPE

was consistent with paraganglioma. The operative duration was 110 min and immediate post-operative period was uneventful. The patient was discharged on the 3rd post-operative day. Follow up revealed a tympanic membrane (TM) perforation which persisted and coincidentally gave us a natural corridor to detect any recurrence. A tympanoplasty was performed a year after primary surgery as no recurrence was detected till then.

2.3. Case 2

A 16-year-old male presented with complaints of left sided hearing impairment and facial palsy for 3 years. With intact tympanic membrane on otoscopy, and grade V (House Brackmann – HB) facial palsy on examination, audiometry and tympanometry revealed unilateral very severe mixed hearing loss (75/40 dBHL) and a Type B tympanogram respectively. HRCT showed a hypodense lesion involving petrous apex causing extensive bony erosion including superior aspect of cochlea and vestibule (Fig. 3). CEMRI revealed an isointense mass on T1 occupying the petrous apex area with erosion of a portion of cochlea (Fig. 3). An endoscopic transcanal transpromontorial approach was adopted. Following 360° elevation of the tympanomeatal flap and canaloplasty, malleus with a remnant of incus was removed (stapes absent). Following atticotomy, cholesteatoma was found in the mesotympanum and epitympanum with complete erosion of the fallopian canal and extension to the petrous apex by erosion of upper 2/3rd of cochlea and vestibule (Fig. 3). The cholesteatoma was slowly dissected out from the petrous apex area following which the petrous carotid and the dura of IAC were found exposed with CSF leak (Fig. 3). The leak and defect was packed with thigh fat and fascia lata with reposition of the tympanomeatal flap and packing with medicated gelfoam. The operative duration was 165 min. There was no CSF leak in the post-operative period and the patient was discharged on the 5th day of surgery. Facial palsy (HB grade V) persisted for which facial reanimation was done with unilateral temporalis muscle sling 3 months after initial surgery. There is no recurrence on CEMRI at 18 months.

2.4. Case 3

A 19-year-old female with complaints of left ear discharge and hearing impairment for 5 and 3 years respectively. Otoscopy revealed dull retracted TM with possible cholesteatoma in the mesotympanum. Audiometry indicated a moderate conductive hearing loss (42/12 dBHL). HRCT displayed a soft tissue density in the mesotympanum extending to petrous apex inferior to cochlea and causing bony erosion till petrous carotid (Fig. 4). CEMRI showed an isointense (T1) and mildly hyperintense (T2) lesion involving the petrous apex area (Fig. 4). Facial nerve function was normal. An endoscopic transcanal infra-cochlear approach was adopted with 360° elevation of tympanomeatal flap and canaloplasty. Malleus and incus were removed with preservation of stapes. The cholesteatoma sac was removed carefully with portion of the petrous carotid found exposed (Fig. 4). The defect was filled with thigh fat and fascia lata with reposition of tympanomeatal flap reinforced by fascia lata and EAC packed with medicated gelfoam. The operative duration was 145 min with an uneventful post-operative period and the patient was discharged on the 3rd day post-surgery. The hearing loss persisted with audiometry at 3 and 6 months showing moderate conductive hearing loss. Follow up CEMRI showed no recurrence at 1 year.

3. Discussion

Traditionally extensive open surgical approaches are often required to approach lateral skull base despite the predominantly benign nature of lesions of the region. This mainly is due to the complex anatomy of the petrous bone and presence of important structures such as IAC, facial nerve, otic capsule, ICA and jugular bulb. These include transpetrous (translabyrinthine/transotic/transcochlear), retrosigmoid or middle cranial fossa routes, all of which are microscope dependent and require significant brain retraction and neurovascular manipulation (Marchioni et al., 2015).

Similarly conventional microscope-based canal wall down or canal wall up approaches are still being widely preferred to transcanal endoscopic approaches to middle ear diseases, such as tympanic cavity cholesteatoma (Marchioni et al., 2015).

With the gradual evolution of endoscopy usage in ear surgeries (Marchioni et al., 2010a, 2010b, 2011a, 2011b, 2020; Tarabichi, 2004), exclusive endoscopic transcanal approaches have been increasingly used to address select lateral skull base lesions namely supra-geniculate fossa, cochlea, vestibule, fundus of the IAC and petrous apex. Involvement of mastoid however will require additional microscopic clearance. Endoscopic transcanal approach additionally also avoids an external incision using the natural EAC orifice as a corridor. However endoscopic ear surgery has a definite learning curve (Alicandri-Ciuffelli et al., 2018). The chance of developing meningitis is also significantly less as the amount of drilling done is less and hence CSF otorrhoea is rare. In traditional open approaches the wide drilling creates pathways for the CSF to seep out and cause CSF otorrhoea which prolongs the stay and increases the possibility of meningitis.

Our paper presents 3 cases in which we employed an exclusive endoscopic transcanal approach. 1 case was of a glomus tympanicum limited to mesotympanum and the other 2 were of petrous apex cholesteatomas which required a lateral skull base approach (1 each of transpromontorial and infracochlear). The mean operative duration was 140 min (110, 165, 145 min respectively) and the patients were discharged on the 3rd, 5th, and 3rd post-operative day respectively. There was residual tympanic membrane perforation in the case of glomus while intraoperative IAC CSF leak was present in the case of transpromontorial approach. There were no other notable complications in our experience. The CSF leak was plugged intra operatively with fat plug and fascia. The important point is to make sure that the leak has been sealed completely, so as to avoid post-operative CSF otorrhoea. The patient with residual perforation is planned for tympanoplasty. This complication can be prevented by reinforcing the replaced tympanomeatal flap with a graft.

We have a limited case number but this presents our initial experiences with the endoscopic transcanal approach. This approach can only be used in select lesions of mesotympanum and lateral skull base. Involvement of mastoid, lesions extending anterior or medial to IAC or involving the jugular bulb area and lesions of petrous apex larger than the transcanal corridor are contraindications to this approach. Hence a detailed preoperative radiological assessment is paramount to undertake such an approach. An additional limitation of this approach as compared to microscopic approaches is the lack of bimanual instrumentation and the lack of depth perception, which can be gradually overcome with experience in endoscopic middle ear surgery and cadaveric dissections.

4. Conclusion

The endoscopic transcanal approach is a better alternative approach to select lesions of mesotympanum and lateral skull base than the open approaches. It significantly decreases operative time, blood loss, morbidity and the duration of hospital stay. The structures of concern in this approach remain the internal carotid artery (ICA), facial nerve, otic capsule and dura of IAC. The major challenges of this approach are the gradual learning curve and the possibility of residual disease.

Financial support

None.

Declaration of competing interest

None.

- Endoscopic transcanal approach is a better alternative approach to select lesions of mesotympanum and lateral skull base than the open approaches.
- Advantages of this approach include decreased operative time, blood loss, morbidity and the duration of hospital stay.
- The structures of concern in this approach remain the internal carotid artery (ICA), facial nerve, otic capsule and dura of IAC.
- The major challenges of this approach are the gradual learning curve and the possibility of residual disease.

Acknowledgements

None.

References

- Alicandri-Ciuffelli, M., Marchioni, D., Pavesi, G., Canzano, F., Feletti, A., Presutti, L., 2018. Acquisition of surgical skills for endoscopic ear and lateral skull base surgery: a staged training programme. *Acta Otorhinolaryngol. Ital.* 2, 151–159.
- Marchioni, D., Alicandri-Ciuffelli, M., Molteni, G., Genovese, E., Presutti, L., 2010a. Endoscopic tympanoplasty in patients with attic retraction pockets. *Laryngoscope* 120, 1847–1855.
- Marchioni, D., Alicandri-Ciuffelli, M., Piccinini, A., Genovese, E., Presutti, L., 2010b. Inferior retrotympanum revisited: an endoscopic anatomic study. *Laryngoscope* 120, 1880–1886. <https://doi.org/10.1002/lary.20995>.
- Marchioni, D., Alicandri-Ciuffelli, M., Piccinini, A., et al., 2011a. Surgical anatomy of transcanal endoscopic approach to the tympanic facial nerve. *Laryngoscope* 121, 1565–1573.
- Marchioni, D., Villari, D., Alicandri-Ciuffelli, M., Piccinini, A., Presutti, L., 2011b. Endoscopic open technique in patients with middle ear cholesteatoma. *Eur Arch Otorhinolaryngo* 268, 1557–1563.
- Marchioni, D., Alicandri-Ciuffelli, M., Rubini, A., et al., 2015. Endoscopic transcanal corridors to the lateral skull base: initial experiences. *Laryngoscope* 125 (Suppl. 5), S1–S13.
- Marchioni, D., Alicandri-Ciuffelli, M., Rubini, A., et al., 2017a. Exclusive endoscopic transcanal transpromontorial approach: a new perspective for internal auditory canal vestibular schwannoma treatment. *J. Neurosurg.* 126, 98–105.
- Marchioni, D., Bonali, M., Presutti, L., 2017b. Transcanal endoscopic lateral skull base surgery. *Oper Tech Otolaryngol Head Neck Surg* 28 (1), 57–64.
- Marchioni, D., Gazzini, L., Bonali, M., et al., 2020. Role of endoscopy in lateral skull base approaches to the petrous apex. *Eur. Arch. Oto-Rhino-Laryngol.* 277, 727–733.
- Presutti, L., Marchioni, D., Mattioli, F., Villari, D., Alicandri-Ciuffelli, M., 2008. Endoscopic management of acquired cholesteatoma: our experience. *J Otolaryngol Head Neck Surg* 37, 481–487.
- Presutti, L., Nogueira, J.F., Alicandri-Ciuffelli, M., Marchioni, D., 2013. Beyond the middle ear: endoscopic surgical anatomy and approaches to inner ear and lateral skull base. *OtolaryngolClin North Am* 46, 189–200.
- Tarabichi, M., 2004. Endoscopic management of limited attic cholesteatoma. *Laryngoscope* 114, 1157–1162.
- Thomassin, J.M., Korchia, D., Doris, J.M., 1993. Endoscopic guided otosurgery in the prevention of residual cholesteatomas. *Laryngoscope* 103, 939–943.