



Research Article

Usefulness of grayscale values measuring hypoechoic lesions for predicting prostate cancer: An experimental pilot study



Jeong Woo Yoo, Kwang Suk Lee*

Department of Urology, Gangnam Severance Hospital, Yonsei University College of Medicine, Seoul, Korea

ARTICLE INFO

Article history:

Received 20 July 2021

Received in revised form

12 October 2021

Accepted 29 November 2021

Available online 3 December 2021

Keywords:

Biopsy

Hypoechoic lesion

Prostate

Transrectal ultrasonography

ABSTRACT

Background: To ensure reproducibility and representativeness of hypoechoic lesions in transrectal ultrasonography (TRUS), we used grayscale values and evaluated their usefulness in predicting prostate cancer (PCA).

Methods: A total of 172 patients scheduled for prostate biopsy for suspected PCA between October 2016 and May 2018 were prospectively enrolled. Patients underwent 12 core target biopsies for hypoechoic lesions in 12 areas of the prostate and two additional target biopsy cores for two hypoechoic lesions. We estimated the grayscale value of the image using a red/green/blue scoring method through a function embedded in the picture archiving and communication system. Imaging data were analyzed using estimated grayscale values.

Results: Of the 127 patients (median age = 68.5 years, median prostate-specific antigen level = 6.19 ng/mL), 67 (52.8%) had PCA. Of 1778 biopsy lesions, 327 (18.4%) were PCA lesions. No differences in the grayscale values were found between PCA and benign lesions; however, the grayscale value between 28.0 and 57.0 for hypoechoic lesions was identified as a significant factor for predicting PCA in multivariable analysis ($p=0.008$). Multivariable analysis indicated a grayscale value between 34.0 and 48.0 as a predicting factor for clinically significant PCA (cs-PCA: Gleason grade group ≥ 2) ($p=0.001$). The area under the curve (AUC) for predicting cs-PCA was higher for combined clinical and grayscale value parameters than for TRUS grayscale values (0.780 vs. 0.561, $p<0.001$).

Conclusions: Hypoechoic lesions that meet the quantitative criteria seem useful for predicting cs-PCA. The presence of hypoechoic lesions is not a predicting factor for PCA.

© 2022 Asian Pacific Prostate Society. Publishing services by Elsevier B.V. This is an open access article under the CC BY-NC-ND license (<http://creativecommons.org/licenses/by-nc-nd/4.0/>).

1. Introduction

Unlike other solid organ cancers where imaging plays a pivotal role in identifying patients requiring biopsy, prostate cancer (PCA) is diagnosed by 10–12 random core prostate biopsies (PBxs) from 10–12 areas in the prostate.^{1–3} Recently, prebiopsy magnetic resonance imaging (MRI) has been recommended in the National Comprehensive Cancer Network (NCCN) guidelines based on results of improving prediction of clinically significant PCA (cs-PCA).^{4–6} Furthermore, introducing MRI/transrectal ultrasonography (TRUS) fusion biopsy reduces sampling error and improves risk stratification.^{7–10}

In the NCCN guidelines, the indication for a PBx is an elevated serum prostate-specific antigen (PSA) level or the presence of suspicious lesions palpated on digital rectal examination.⁶ Although the presence of a hypoechoic lesion on TRUS was not included as an indication for PBx, several studies have reported the usefulness of hypoechoic lesions in predicting high-grade cancer.^{11,12} Additionally, hypoechoic lesions detected on TRUS were used as an indicator for imaging matching in MRI/TRUS fusion biopsy.

Our group has sought to improve cancer detection in patients who cannot afford to undergo expensive MRI and MRI/TRUS fusion biopsy.¹³ Our previous study proposed a method for quantifying hypoechoic lesions using grayscale values to detect PCA that can be easily implemented without additional equipment in practical TRUS-guided biopsy.¹³ In the present study, we aimed to validate this imaging analysis method by quantifying hypoechoic lesions, demonstrating the diagnostic accuracy of grayscale values, and specifying the quantitation range of hypoechoic lesions.

* Corresponding author. Department of Urology, Gangnam Severance Hospital, Yonsei University College of Medicine, 211 Eonju-ro, Gangnam-gu, Seoul, 06273, Korea.

E-mail addresses: yoo8318@yuhs.ac (J.W. Yoo), calmenow@yuhs.ac (K.S. Lee).

2. Materials and methods

2.1. Patient cohort

This prospective study enrolled patients scheduled for PBxs for suspected PCA at our institution between October 2016 and May 2018. The indication for a PBx was a PSA level ≥ 3.0 ng/mL or the presence of a palpable nodule on a digital rectal examination. Of the initial 172 patients, 45 were excluded because of a prior PCA diagnosis ($n = 2$) and a planned MRI/TRUS fusion biopsy or other protocols ($n = 43$). The remaining 127 patients were included in the final study group. All procedures performed in studies involving human participants were in accordance with the ethical standards of the institutional and/or national research committee and with the 1964 Helsinki Declaration and its later amendments or comparable ethical standards. Study details were explained to the patients, and informed consent was obtained. The study was approved by the institutional ethics committee (2016-0288-003).

2.2. Data collection

Patient characteristics, including clinicopathological data, such as age, history of a PBx, the prostate volume (PV), PSA, PSA density (PSAD: PSA value divided by PV), and a number of biopsy cores, were obtained.

2.3. Prostate biopsy procedures

The PBx protocol used was slightly different from that used in our previous study.¹³ Previously, we obtained a 12-core random systematic biopsy in addition to a targeted biopsy (TBx) for up to two lesions in each patient. In the present study, we performed a prostate biopsy targeting the most hypoechoic lesion in each of the 12 peripheral zones of a 12-core random biopsy, which is generally performed. The 12 core random biopsy was performed in the following order: the right lateral base, right lateral mid, right lateral apex, right medial base, right medial mid, right medial apex, left lateral base, left lateral mid, left lateral apex, left medial base, left medial mid, and left medial apex. Additional two-core TBxs for two hypoechoic lesions in the prostate (one each from the right and left sides of the prostate), which were selected by the operator as being most suspicious for PCA, were performed before the 12-core target biopsies of hypoechoic lesions were obtained according to the procedure described in our previous study. In total, 14 core biopsies were performed.

All target biopsies of the hypoechoic lesions were obtained by one urologist, who, to date, has performed <600 MRI/TRUS fusion target biopsies. A hypoechoic lesion was defined as a region with a lower grayscale value than the surrounding tissue. Ultrasonography settings, including the gain, repetition, frequency, power output, and filter settings, were fixed to neutral according to our previous study because time gain compensation modulation was not required because of the short distance between the prostate and transducer.¹³ We used a BK Medical Ultra-View 800 ultrasound system (Analogic Corporation, Peabody, MA, USA) and a 7.5–12-MHz multiplanar probe.

2.4. Imaging analysis

All target lesion images were collected and stored using a picture archiving and communication system (PACS) (GE Healthcare, Barrington, IL, USA) at our hospital. We estimated the grayscale value of the image using a red/green/blue (RGB) scoring method through a function embedded in the PACS as the PACS we used did not provide the grayscale value directly. An average RGB value was obtained

from scores at three other randomized points in the most identical slice to reduce any selection bias in selecting the points. After confirming that there was no difference between one point and the average of the three points by a paired-samples test, we used the average of each parameter as the representative value. Grayscale values were replaced with average RGB values on a pixel-by-pixel basis ($Y = 0.2126 \times \text{Red} + 0.7152 \times \text{Green} + 0.0722 \times \text{Blue}$).¹⁴

2.5. Statistical analysis

Data are reported as median (interquartile range) for continuous variables and as a number of occurrences (frequency) for categorical variables. The Pearson χ^2 test was used to statistically compare continuous and categorical variables. Simple and multiple logistic regression analyses were used to predict PCA and cs-PCA. Receiver operating characteristic curves and the area under the curves (AUCs) were used to calculate the performance of imaging to detect PCA and cs-PCA (Gleason grade group ≥ 2) using grayscale values.^{15,16} These optimal cut-off values were based on predefined values and analysis using the Youden index (sensitivity + specificity – 1). Comparisons of the AUC were performed using the DeLong method for statistical significance of AUC differences. SPSS software version 25.0 (IBM Corp., Armonk, NY, USA) and MedCalc version 11.6 (MedCalc Software, Acaciaaan, Oostende, Belgium) were used to perform the statistical analyses; all statistical tests were two-tailed. $P < 0.05$ was considered statistically significant.

3. Results

3.1. Baseline characteristics of the patients and hypoechoic lesions

Baseline characteristics of the study population that underwent a PBx are shown in Table 1. Among the 127 patients (median age = 68.5 years, median PSA level = 6.19 ng/mL), 67 (52.8%) were diagnosed with PCA (PSA level <10 ng/mL: 46.2% [43/93], PSA level ≥ 10 ng/mL: 70.6% [24/34]). Patients diagnosed with PCA were significantly older and had a higher PSA and PSAD than those not diagnosed with PCA. Of 1778 biopsy lesions from the 127 patients, 327 (18.4%) were diagnosed as PCA. In total, 179 (54.7%) lesions were detected in the peripheral zone. The cut-off grayscale values for predicting PCA ranged from 28.0 to 57.0, and the cut-off grayscale values for predicting cs-PCA among PCA ranged from 34.0 to 48.0 by the Youden index. A higher proportion of lesions with grayscale values ranging from 28.0 to 57.0 was PCA lesions rather than benign lesions (57.5% vs. 50.4%, $p = 0.021$). In our study, there were no significant differences in the grayscale values between the peripheral and transitional zones ($p = 0.520$).

Age (odds ratio [OR] = 1.06; $p = 0.034$), PSA (OR = 1.16; $p = 0.006$), and PV (OR = 0.97, $p = 0.009$) were identified as significant predictive factors of PCA in multiple logistic regression analysis (Table 2).

3.2. Association of TRUS images with grayscale values and pathology reports of the prostate biopsies

Fig. 1 describes the association of TRUS images with the grayscale values and pathology reports of the PBxs. In Figure (A), the grayscale value was 91.23, and the lesion was pathologically noncancerous. Figure (B) shows the grayscale value of 25.36, which was categorized as noncancerous. Figures (C) and (D) present the grayscale values of 53.72 and 31.43, and the corresponding pathology report indicates PCA with a Gleason score of 6. Figures (E) and (F) show grayscale values of 45.65 and 39.51, and the corresponding pathology report indicates PCA with Gleason scores of 7 and 8, respectively.

Table 1
Baseline characteristics of the study population who underwent a prostate biopsy

	Study population (n = 127)	Prostate cancer		P-value
		No (n = 60)	Yes (n = 67)	
Age (y)	68.5 (61.8–72.8)	65.2 (59.0–72.2)	69.7 (64.2–75.1)	0.020
PSA level (ng/mL)	6.19 (4.60–10.22)	5.19 (4.15–8.07)	8.01 (5.11–13.59)	0.028
Prostate volume (cm ³)	35.9 (27.8–51.7)	39.7 (31.7–57.8)	32.0 (25.4–46.8)	0.107
PSAD (ng/mL/cm ³)	0.17 (0.12–0.28)	0.13 (0.10–0.18)	0.23 (0.15–0.41)	0.018
History of prostate biopsy (yes)	26 (20.5)	11 (18.3)	15 (22.4)	0.321
Detection of prostate cancer	67 (52.8)			
Gleason grade <1	22 (32.8)			
≥2	45 (67.2)			
No. of lesions	1778	1451 (81.6)	327 (18.4)	
Gleason grade <1			135 (41.3)	
≥2			192 (58.7)	
Vascularity (yes)	1265 (72.1)	1028 (70.8)	237 (72.5)	0.918
Peripheral zone (yes)	1070 (60.2)	891 (61.4)	179 (54.7)	0.648
Grayscale value	53.0 (42.0–66.0)	53.0 (42.0–66.0)	51.0 (40.8–65.0)	0.063
Grayscale value (34.0–48.0)	471 (26.5)	372 (25.7)	98 (30.0)	0.115
Grayscale value (28.0–57.0)	920 (51.7)	732 (50.4)	188 (57.5)	0.021

Data are presented as n (%) or median (interquartile range).
PSA, prostate-specific antigen; PSAD, prostate-specific antigen density.

3.3. Use of grayscale values of hypoechoic lesions for predicting prostate cancer and clinically significant prostate cancer

In multivariable analyses, age, PSA, PV, and grayscale value (28.0–57.0) were identified as significant predictive factors for PCA, whereas age, PSA, PV, and grayscale value (34.0–48.0) were identified as significant predictive factors for cs-PCA (Table 3).

The sensitivity and specificity for detecting PCA lesions using TRUS grayscale values ranging from 28.0 to 57.0 were 57.5% and 49.6%, respectively, and the AUC was 0.535. When using clinical variables that were significantly associated with PCA detection (age, PSA, and PV), the AUC was 0.754, which was significantly higher than that when using only the TRUS grayscale values ($p < 0.001$). When combining the grayscale values and clinical variables, the AUC was 0.755, which was higher than that when using only the TRUS grayscale values ($p < 0.001$) (Fig. 2).

The sensitivity and specificity of detecting cs-PCA lesions using TRUS grayscale values ranging from 34.0 to 48.0 were 37.4% and 74.8%, respectively, and the AUC was 0.561. When using clinical variables that were significantly associated with cs-PCA detection (age, PSA, and PV), the AUC was 0.771 (95% confidential interval: 0.733–0.810), which was significantly higher than that when using only the TRUS grayscale values ($p < 0.001$). When combining the grayscale values and clinical variables, the AUC was 0.780 (0.742–0.818), which was higher than that when using only the TRUS grayscale values ($p < 0.001$) (Fig. 3).

4. Discussion

This study is the first to provide a validation report of consistent prediction of cancer detection and malignancy aggressiveness using grayscale values of hypoechoic lesions obtained by a TRUS

biopsy. As proposed from our previous study with 229 hypoechoic lesions, the present study was an extension of our first attempt to assign numerical values to hypoechoic lesions using RGB as grayscale components.¹³ In this study, we evaluated our method using 1778 biopsy lesions and provided the specific range of grayscale values that could improve the accuracy of detecting PCA and cs-PCA. Herein, we proposed a specific target range of the grayscale value for discriminating PCA and cs-PCA in hypoechoic lesions.

The normal human eye has limitations in identifying hypoechoic lesions in terms of reproducibility and representativeness. Therefore, we tried to minimize the ambiguity of hypoechoic lesions because what may be seen as hypoechoic lesions on TRUS may differ in numerical values. We intended to present specific guidelines for defining significant hypoechoic lesions that are associated with PCA and cs-PCA, which could be objectively used and should not be dependent on operators, using numerical values that we termed as grayscale values. We provided the specific ranges that showed good performance in detecting PCA and cs-PCA. The range of grayscale values was largely different in hypoechoic lesions. Therefore, we tried to determine the specific range of these grayscale values. The grayscale values ranging from 28.0 to 57.0 and from 34.0 to 48.0 showed good performance in detecting PCA and cs-PCA, respectively. Although the performance of including grayscale values did not increase the performance of including only clinical variables in detecting PCA or cs-PCA, the focus of this study was to identify and demonstrate the usefulness of grayscale values in detecting PCA and cs-PCA lesions. Because this study was an extension of our previous study that demonstrated the possible role of grayscale values in identifying PCA or cs-PCA, we did not consider or focus on increasing the performance of automatically detecting PCA or cs-PCA.

Table 2
Results of univariable and multivariable logistic regression analyses for predicting the presence of prostate cancer

	Univariable analysis		Multivariable analysis	
	OR (95% CI)	P-value	OR (95% CI)	P-value
Age	1.06 (1.01–1.11)	0.008	1.06 (1.00–1.11)	0.034
PSA level	1.13 (1.04–1.22)	0.006	1.16 (1.042–1.29)	0.006
Prostate volume	0.97 (0.95–0.99)	0.025	0.97 (0.94–0.99)	0.009
History of prostate biopsy (yes)	1.29 (0.59–3.07)	0.572		

CI, confidence interval; OR, odds ratio; PSA, prostate-specific antigen.

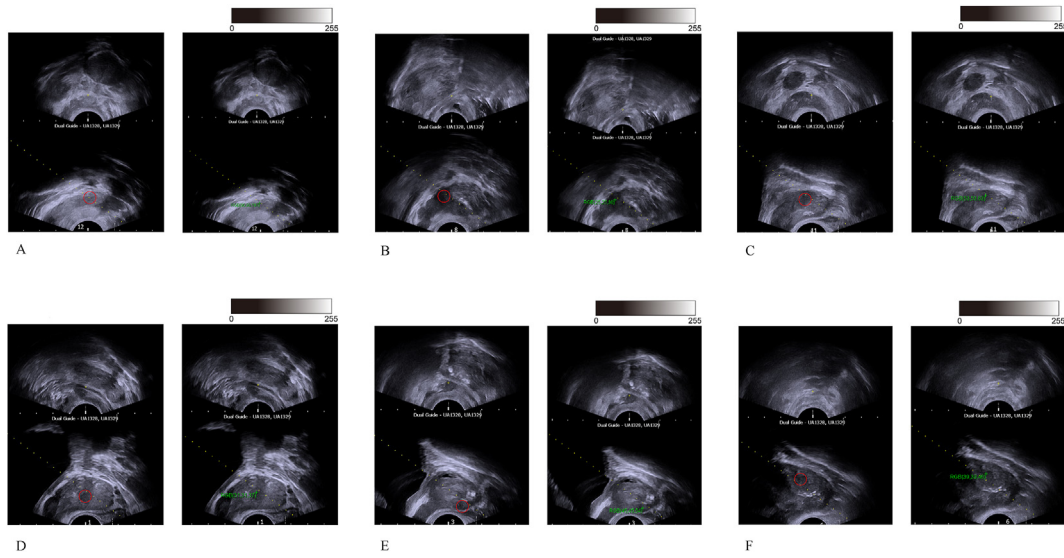


Fig. 1. Association of transrectal ultrasound images with grayscale values and pathology reports of the prostate biopsies. A: The grayscale value of 91.23 is pathologically categorized as noncancerous. B: The grayscale value of 25.36 is pathologically categorized as noncancerous. C: The grayscale value of 53.72 is pathologically categorized as prostate cancer with a Gleason score of 6. D: The grayscale value of 31.43 is pathologically categorized as prostate cancer with a Gleason score of 6. E: The grayscale value of 45.65 is pathologically categorized as prostate cancer with a Gleason score of 7. F: The grayscale value of 39.51 is pathologically categorized as prostate cancer with a Gleason score of 8.

Similar to our study, previous studies reported that a hypoechoic lesion represented significantly high-grade disease.^{11,12} In 500 patients with hypoechoic lesions on TRUS, PCA presented as a hypoechoic area in 496 men (99.2%).¹¹ Patients who underwent prostatectomy with hypoechoic lesions, as detected by MRI-TBx, had significantly worse outcomes than those without hypoechoic lesions, despite significant differences in the Gleason grade, PSA level, and percentage of positive core biopsies.¹² However, normal prostate tissue and prostatic adenomas can appear as hypoechoic lesions, and 30% of all PCAs are isoechoic.^{17–19} Owing to the low positive biopsy rate of hypoechoic versus isoechoic lesions, a systematic biopsy should be chosen regardless of echogenicity.^{20,21} Our result showing no increase in AUCs for predicting PCA by adding the grayscale value to conventional parameters was useful for supporting the guidelines that recommend random PBxs regardless of echogenicity. However, for predicting cs-PSA, the AUCs of combined clinical and grayscale value parameters were marginally higher than those of clinical

parameters, indicating that hypoechoic lesions are useful for discriminating cancer aggressiveness.

Until now, several diagnostic image modalities, including TRUS and MRI, have been suggested.^{22,23} The sensitivity and specificity of standard sextant biopsy in predicting cs-PCA were 53.0% and 66.0%, respectively, and the AUC was 0.59. For prebiopsy MRI with MRI/TRUS fusion biopsy, the sensitivity and specificity were 85.0% and 49.0%, respectively, and the AUC was 0.67.¹⁰ The MRI and TRUS biopsy in PCA study reported ranges of 87.0%–93.0% for sensitivity and 48.0%–60.0% for specificity according to several definitions for cs-PCA.²⁴ Our diagnostic accuracy of grayscale values showed a sensitivity, specificity, and AUC of 66.0%, 79.6%, and 0.535, respectively, which is similar to those reported in a previous study. Therefore, TRUS showed a low diagnostic ability for PCA regardless of using grayscale values. However, the sensitivity, specificity, and AUC for cs-PCA were 37.4%, 74.8%, and 0.561, respectively. Based on these results, evaluating hypoechoic lesions with grayscale values

Table 3

Results of univariable and multivariable logistic regression analyses for predicting the presence of prostate cancer or clinically significant prostate cancer in biopsied lesions

	Prediction of prostate cancer			
	Univariable analysis		Multivariable analysis	
	OR (95% CI)	P-value	OR (95% CI)	P-value
Age	1.05 (1.035–1.067)	<0.001	1.03 (1.016–1.049)	<0.001
PSA level	1.04 (1.027–1.042)	<0.001	1.03 (1.027–1.041)	<0.001
Prostate volume	0.99 (0.978–0.994)	<0.001	0.97 (0.964–0.983)	<0.001
History of prostate biopsy (yes)	1.10 (0.818–1.469)	0.539		
Transitional zone (yes)	0.76 (0.597–0.968)	0.026	0.86 (0.52–1.120)	0.258
Grayscale value	1.00 (0.989–1.002)	0.186		
Grayscale value (28.0–57.0)	1.33 (1.043–1.693)	0.022	1.44 (1.098–1.890)	0.008
Prediction of clinically significant prostate cancer				
Age	1.10 (1.070–1.114)	<0.001	1.07 (1.049–1.094)	<0.001
PSA level	1.02 (1.019–1.028)	<0.001	1.24 (1.019–1.028)	<0.001
Prostate volume	0.99 (0.977–0.997)	0.009	0.98 (0.962–0.987)	<0.001
History of prostate biopsy	1.28 (0.895–1.818)	0.177		
Transitional zone (yes)	1.25 (0.926–1.698)	0.144		
Grayscale value	0.99 (0.983–1.000)	0.062		
Grayscale value (34.0–48.0)	1.78 (1.293–2.428)	<0.001	1.82 (1.285–2.570)	0.001

CI, confidence interval; OR, odds ratio; PSA, prostate-specific antigen.

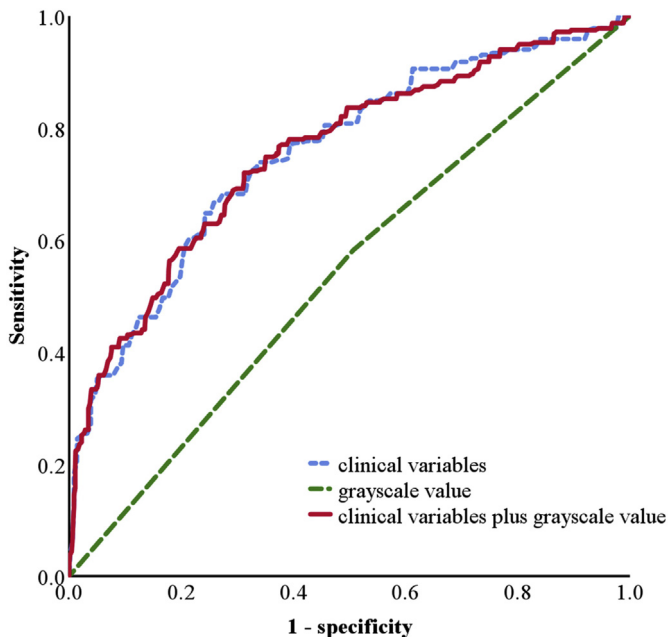


Fig. 2. ROC curves of detecting PCA lesion using clinical variables and grayscale values (ranging from 28.0 to 57.0) of hypoechoic lesions. AUC of clinical variables: 0.754, AUC of grayscale value of hypoechoic lesion: 0.535, AUC of the grayscale of clinical variables plus grayscale of hypoechoic lesion: 0.755. AUC, area under the curve of receiver operator characteristic; PCA, prostate cancer; ROC, receiver operator characteristic.

may be useful as an aided diagnostic tool to make more accurate stratification of lesions suspected of being cs-PCA with a Prostate Imaging Reporting and Data System (PI-RADS) score ≥ 3 on MRI.²⁵ Thus, implementation of the grayscale value in MRI/TRUS fusion biopsy can help detect cs-PCA.

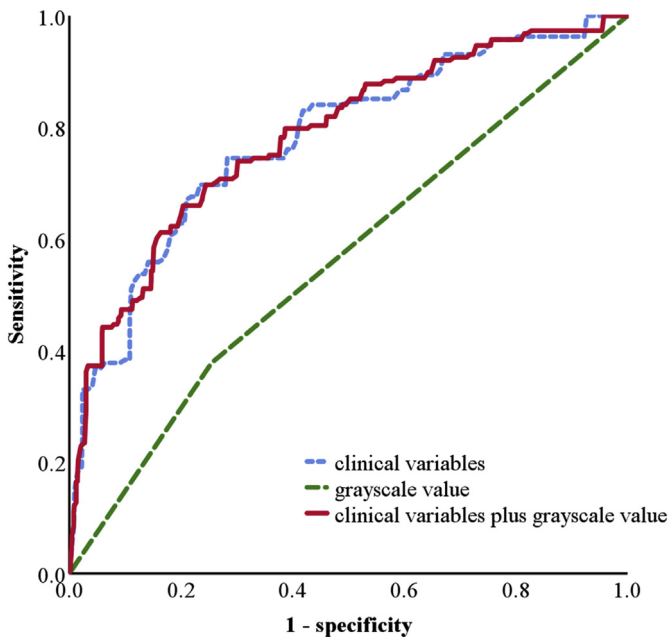


Fig. 3. ROC curves of detecting cs-PCA lesion using clinical variables and grayscale values (ranging from 34.0 to 48.0) of hypoechoic lesions. AUC of clinical variables: 0.771, AUC of the grayscale value of hypoechoic lesion: 0.561, AUC of the grayscale of clinical variables plus grayscale of hypoechoic lesion: 0.780, AUC, area under the curve of receiver operator characteristic; cs-PCA, clinically significant prostate cancer; PCA, prostate cancer; ROC, receiver operator characteristic.

The method presented in this study has two clinically significant aspects: it is cheaper than MRI, and errors due to overlooking cancerous lesions during TRUS biopsies are avoided. In terms of clinical implication, our team is developing a program that can display suspicious lesions on ultrasonograms in real time using artificial intelligence based on this study's results. Moreover, our findings will be useful as explainable variables for lesions selected by computer-aided diagnosis. Our future study will focus on the association of PI-RADS lesions and TRUS grayscale lesions.

The present study has several limitations. First, it was a single-institution, non-randomized study. Further randomized multi-center studies are warranted to verify our results. Second, ultrasound settings, such as the gain, repetition frequency, power output, and filter settings, were fixed, but they can vary between instruments and operators. Future studies for developing models to predict PCA and cs-PCA should consider this variability according to the settings and ultrasound devices. Third, we targeted most hypoechoic lesions in approximately 12 systematic areas in the prostate. Because TBx of hypoechoic lesions was done at 12 sites in the present study, the performance of using grayscale values cannot be compared with our previous study, which only performed TBx at a maximum of two hypoechoic lesions in a single patient. Moreover, because this is the first study of its kind and an extension of our first attempt at using grayscale values for detecting PCA and cs-PCA, direct comparison of the performance of our method for detecting PCA or cs-PCA with other study methods is not possible. Finally, in some of the 12 areas, hypoechoic lesions may be poorly identified. In this case, the target for measuring the grayscale value may be different depending on the subjectivity of the physician. However, such bias in grayscale values of relatively isoechoic lesions is not expected to significantly affect our endpoints to determine the grayscale values of relatively hypoechoic lesions.

5. Conclusions

Using a specific range of grayscale values would promote an objective assessment of lesions and increase the sensitivity and specificity of a TRUS biopsy. This imaging analysis method can be easily implemented without additional equipment in practical PBxs. Moreover, we improved the ability to discriminate hypoechoic lesions using grayscale values. Using this range, we plan to develop automated computer-assisted models that predict PCA and cs-PCA without using expensive diagnostic tools.

Conflicts of interest

All of the authors declare that they have no conflicts of interest to declare.

Acknowledgments

This study was supported by the Korean Society for Urologic Ultrasonography Grant (Grant Number 2016-00).

Reference

1. Abraham NE, Mendhiratta N, Taneja SS. Patterns of repeat prostate biopsy in contemporary clinical practice. *J Urol* 2015;193(4):1178–84.
2. Ahn HK, Lee KS, Koo KC, Chung BH. Clinical experience with active surveillance protocol using regular magnetic resonance imaging instead of regular repeat biopsy for monitoring: A study at a high-volume center in Korea. *Prostate Int* 2021;9(2):90–5.
3. Lee BC, Kim HO, Chung HS, Heo SH, Jeong YY, Kim MS, et al. Does music from noise-canceling headphones have a beneficial effect on men undergoing transrectal ultrasound-guided prostate biopsy? *Prostate Int* 2021;9(3):145–50.

4. Turkbey B, Brown AM, Sankineni S, Wood BJ, Pinto PA, Choyke PL. Multiparametric prostate magnetic resonance imaging in the evaluation of prostate cancer. *CA A Cancer J Clin* 2016;66(4):326–36.
5. Mowatt G, Scotland G, Boachie C, Cruickshank M, Ford J, Fraser C, et al. The diagnostic accuracy and cost-effectiveness of magnetic resonance spectroscopy and enhanced magnetic resonance imaging techniques in aiding the localisation of prostate abnormalities for biopsy: a systematic review and economic evaluation. *Health Technol Assess* 2013.
6. Schaeffer E, Srinivas S, Antonarakis ES, Armstrong AJ, Bekelman JE, Cheng H, et al. NCCN Guidelines Insights: Prostate Cancer, Version 1.2021: Featured Updates to the NCCN Guidelines. *J Natl Compr Cancer Netw* 2021;19(2):134–43.
7. Bjurlin MA, Meng X, Le Nobin J, Wysock JS, Lepor H, Rosenkrantz AB, et al. Optimization of prostate biopsy: the role of magnetic resonance imaging targeted biopsy in detection, localization and risk assessment. *J Urol* 2014;192(3):648–58.
8. Tran GN, Leapman MS, Nguyen HG, Cowan JE, Shinohara K, Westphalen AC, et al. Magnetic resonance imaging–ultrasound fusion biopsy during prostate cancer active surveillance. *Eur Urol* 2017;72(2):275–81.
9. Gordetsky J, Rais-Bahrami S, Epstein JI. Pathological Findings in Multiparametric Magnetic Resonance Imaging/Ultrasound Fusion-guided Biopsy: Relation to Prostate Cancer Focal Therapy. *Urology* 2017;105:18–23.
10. Siddiqui MM, Rais-Bahrami S, Turkbey B, George AK, Rothwax J, Shakir N, et al. Comparison of MR/ultrasound fusion-guided biopsy with ultrasound-guided biopsy for the diagnosis of prostate cancer. *J Am Med Assoc* 2015;313(4):390–7.
11. Augustin H, Graefen M, Palisaar J, Blonski J, Erbersdobler A, Daghofe F, et al. Prognostic significance of visible lesions on transrectal ultrasound in impalpable prostate cancers: implications for staging. *J Clin Oncol* 2003;21(15):2860–8.
12. Junqueira VCN, Zogbi O, Cologna A, Dos Reis RB, Tucci Jr S, Reis LO, et al. Is a visible (hypoechoic) lesion at biopsy an independent predictor of prostate cancer outcome? *Ultrasound Med Biol* 2012;38(10):1689–94.
13. Lee KS, Koo KC, Chung BH. Quantitation of hypoechoic lesions for the prediction and Gleason grading of prostate cancer: a prospective study. *World J Urol* 2018;36(7):1059–65.
14. Anderson M, Motta R, Chandrasekar S, Stokes M, eds. Proposal for a standard default color space for the internet—srgb. Color and imaging conference. Society for Imaging Science and Technology; 1996.
15. Portalez D, Mozer P, Cornud F, Renard-Penna R, Misrai V, Thoulouzan M, et al. Validation of the European Society of Urogenital Radiology scoring system for prostate cancer diagnosis on multiparametric magnetic resonance imaging in a cohort of repeat biopsy patients. *Eur Urol* 2012;62(6):986–96.
16. Sonn GA, Natarajan S, Margolis DJ, MacAiran M, Lieu P, Huang J, et al. Targeted biopsy in the detection of prostate cancer using an office based magnetic resonance ultrasound fusion device. *J Urol* 2013;189(1):86–92.
17. Dahner WF, Hamper UM, Eggleston JC, Walsh PC, Sanders RC. Prostatic evaluation by transrectal sonography with histopathologic correlation: the echogenic appearance of early carcinoma. *Radiology* 1986;158(1):97–102.
18. Salo JO, Rannikko S, Mäkinen J, Lehtonen T. Echogenic structure of prostatic cancer imaged on radical prostatectomy specimens. *Prostate* 1987;10(1):1–9.
19. Strohmeier D, Rössing C, Strauss F, Bauerfeind A, Kaufmann O, Loening S. Tumor angiogenesis is associated with progression after radical prostatectomy in pT2/pT3 prostate cancer. *Prostate* 2000;42(1):26–33.
20. Vallancien G, Prapotnich D, Veillon B, Brisset J, Andre-Bougaran J. Systematic prostatic biopsies in 100 men with no suspicion of cancer on digital rectal examination. *J Urol* 1991;146(5):1308–12.
21. Hammerer P, Huland H. Systematic sextant biopsies in 651 patients referred for prostate evaluation. *J Urol* 1994;151(1):99–102.
22. Shin TJ, Jung W, Ha JY, Kim BH, Kim YH. The significance of the visible tumor on preoperative magnetic resonance imaging in localized prostate cancer. *Prostate Int* 2021;9(1):6–11.
23. Harland N, Stenzl A. Micro-ultrasound: a way to bring imaging for prostate cancer back to urology. *Prostate Int* 2021;9(2):61–5.
24. Ahmed HU, El-Shater Bosaily A, Brown LC, Gabe R, Kaplan R, Parmar MK, et al. Diagnostic accuracy of multi-parametric MRI and TRUS biopsy in prostate cancer (PROMIS): a paired validating confirmatory study. *Lancet* 2017;389(10071):815–22.
25. Purysko AS, Rosenkrantz AB, Barentsz JO, Weinreb JC, Macura KJ. PI-RADS version 2: a pictorial update. *Radiographics* 2016;36(5):1354–72.