



Ureteral embolisation for the management of persistent uretero-ileal anastomotic leak

Matthew Chau^{*}, Haider Bangash, Robert Goodwin

Department of Urology, Sir Charles Gairdner Hospital, Perth, WA, Australia

ARTICLE INFO

Keywords:

Ureteral embolisation
Anastomotic leak
Urinary leak
Coils

ABSTRACT

Ureteral embolisation has been described in the use of complete occlusion of the ureter to manage urinary leaks, haematuria, and fistulas. This is usually a management option of last resort in patients who have many comorbidities, poor surgical candidates, or previous pelvic surgery. We report the use of vascular coils and glue to manage a uretero-ileal anastomotic leak following radical cystoprostatectomy.

1. Introduction

Ongoing Uretero-ileal anastomotic leak is a rare but significant complication that is associated with significant morbidity and mortality. Standard practice involves urinary diversion with percutaneous nephrostomies to allow time for the leaks to improve.¹ Persistent urinary leaks may require minimally invasive techniques such as ureteral embolisation, particularly in those who are not good surgical candidates. We described the use of vascular coils and glue to achieve complete ureteric occlusion to manage a complex problem.

2. Case presentation

A 66-year-old man with T1 high grade transitional cell carcinoma of a bladder diverticulum was electively admitted for a radical cystoprostatectomy (RCP) with an ileal conduit formation for urinary diversion, following MDT review. His past surgical history included a lobectomy from primary lung adenocarcinoma and previous sigmoid colectomy for stage II colon adenocarcinoma. His other history included typed 2 diabetes, hypertension, and previous cardiac stenting.

No intra-operative or early post-operative complications were encountered. Day 5 post-operatively, he developed high grade small bowel obstruction that failed conservative management, requiring exploratory laparotomy. Interstitial herniation of small bowel between recti, inferiorly, was found to be the source. The uretero-ileal anastomosis and conduit appeared healthy and were well perfused at this time. During anaesthesia induction, there was significant aspiration of gastric contents causing difficulties with ventilation, oxygenation, and sepsis.

Venous-venous extracorporeal membrane oxygenation (VV-ECMO) was commenced to provide adequate oxygenation in the intensive care unit. He was eventually weaned off VV-ECMO and extubated. He continued in septic shock with vasopressor and inotropic requirements increasing. A computed tomography (CT) scan of the abdomen revealed new widespread free fluid and bowel oedema. Due to the high vasopressor requirements and VV-ECMO, new ischaemic bowel and a small anastomotic leak developed. A Hartmann's resection was performed and anastomotic leak managed conservatively with his previous Bander ureteral diversion stents. Conservative management was opted at this stage given the early stage of his recovery and the first line management option.

Persistent uretero-ileal anastomotic leaks were reflected by his ongoing sepsis, vasopressor requirements and new pelvic collection, despite appropriately situated ureteral stents. He also developed dehiscence of his laparotomy wound that leaked intra-abdominal free fluid. A urethral indwelling catheter and Flexi-Seal[®] (Convatec Group, Berkshire, UK) rectal tube was inserted to allow free drainage of the pelvic collection. Creatinine level from this fluid had a creatinine of 1490 $\mu\text{mol/L}$. Given his hostile abdomen from 3 previous laparotomies and current clinical status, urinary diversion with bilateral nephrostomy tubes was preferred, which temporarily improved his clinical situation for over a month. Despite nephrostomy tubes, he had persistent leak from his uretero-ileal anastomosis. This was confirmed by injecting methylene blue into his nephrostomy tubes, that was subsequently seen within his intrabdominal drain bottles and his wound.

Nephrostograms were performed, which demonstrated free drainage into the pelvic collection from the distal ureters bilaterally (Fig. 1). No

^{*} Corresponding author. 3a Leschenaultia St, Greenwood, Western Australia, 6024, Australia.

E-mail address: matthew.chau@health.wa.gov.au (M. Chau).

<https://doi.org/10.1016/j.eucr.2022.102260>

Received 28 August 2022; Received in revised form 27 September 2022; Accepted 7 October 2022

Available online 7 October 2022

2214-4420/Crown Copyright © 2022 Published by Elsevier Inc.

(<http://creativecommons.org/licenses/by-nc-nd/4.0/>).

This is an open access article under the CC BY-NC-ND license

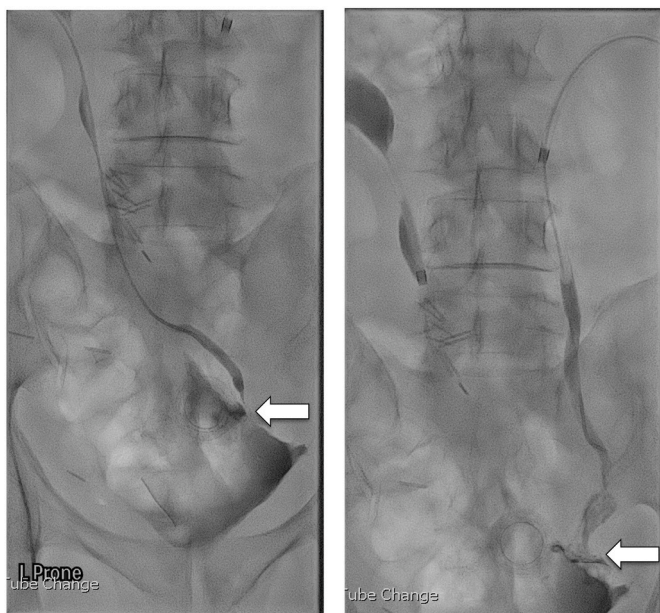


Fig. 1. Bilateral nephrostogram with patient prone, demonstrating distal ureteric leak into the pelvic collection.

evidence of conduit filling from either ureter was seen. After consultation in a multi-disciplinary team meeting, ureteric embolisation was performed at the level of the pelvic inlet using a combination of Interlock-18 coils with a Histoacryl/Lipiodol glue in 1:1 dilution. Satisfactory occlusion by radiological criteria was achieved with minimal leak past the coils. A covering 10.2Fr nephrostomy tube was inserted on straight drainage.

Repeat nephrostogram 3 weeks post initial embolisation demonstrated ongoing leak beyond the right embolisation coil and glue pack (Fig. 2). Ongoing sepsis prompted another attempt at embolisation. A larger 9Fr sheath was used and a MVP-9Q plug was deployed in the more proximal ureter. The space between the plug and the coils was filled with Histoacryl/Lipiodol in 1:3 dilution. Final nephrostogram showed adequate occlusion of the ureters (Fig. 3).

After a long stay he was able to be transferred to a rehabilitation facility with only bilateral nephrostomy tubes, all other drains and tubes removed. He has since been discharged home with ongoing follow-up with the Urology service. He has been followed for 12 months post embolisation by means of clinical and radiological assessment without concerns of ongoing leak. He has regular 6-weekly nephrostomy tube exchanges with nephrostogram to assess embolisation site. He continues to have surveillance scans for his bladder cancer.

3. Discussion

Persistent urinary leak from ileal anastomosis stands to cause significant issues with sepsis. We have described, to our knowledge, the first case of ureteric embolisation, using coils and glue, in a patient with persistent anastomotic leak despite standard management techniques.

This minimally invasive technique is a permanent option in patients with ureteral-ileal anastomotic leaks, unsuitable for major surgical intervention and who have failed standard draining methods. It is a technique that has been described previously to treat cases of intractable haematuria, malignant ureteral fistulas and vesicoureteral reflux, with variable success (55%, 70% to 80% and nearly 100%).²⁻⁴ Other described ureteral embolisation techniques include the use of angiography balloons, detachable balloons, nylon plugs and gelatin sponges. The pathogenesis of ureteral occlusion is ureteral stricture from urothelial irritation and induction of hyperplastic tissue. Complications arising from ureteric embolisation include migration of coils, softening

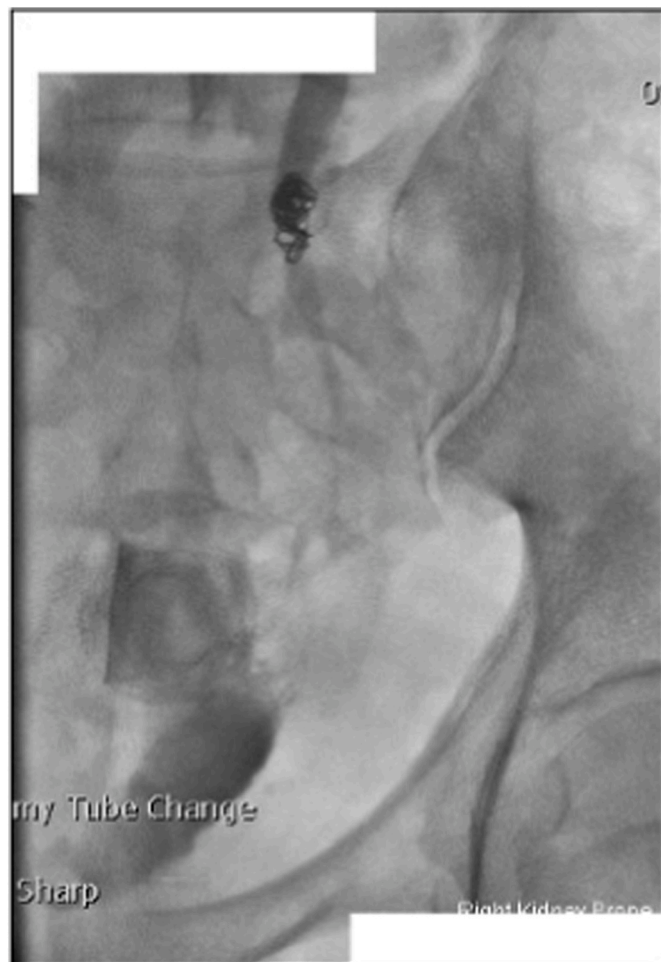

Fig. 2. Repeat nephrostogram demonstrating contrast bypassing coil/glue pack and into pelvic collection.

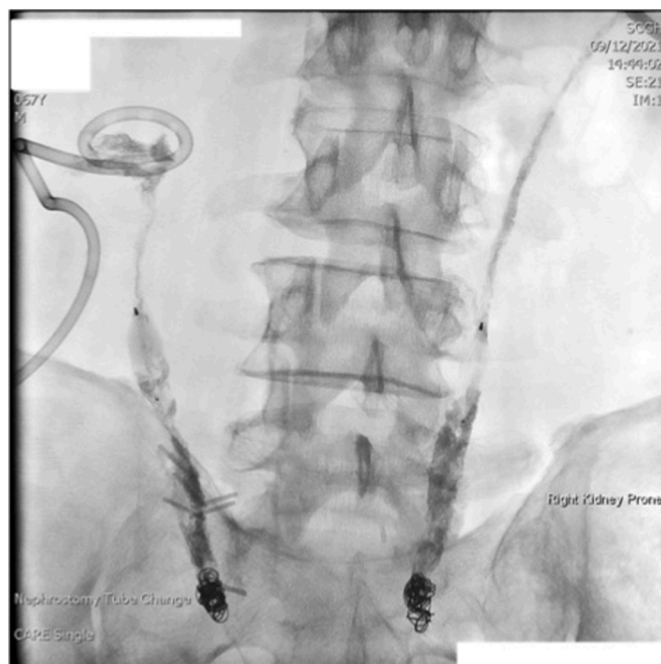

Fig. 3. Final nephrostogram demonstrating no contrast leakage beyond embolisation location.

of glue, insufficient occlusion, secondary fistulas and pseudoaneurysms.⁵ Following ureteral embolisation, patients will be committed to lifelong nephrostomy drainage and regular (6–8 weekly) changes. No long term literature is currently available to describe the effects of radiation or complications such as stone formation or infection of the exposed material. More invasive management techniques such as cutaneous ureterostomies and tying or clipping of the ureter can be considered for patients who are suitable for major surgical interventions.

Asvadi et al. reviewed a total of 39 ureteral embolisation using coils and found successful embolisation in 94.6% based on post-procedure antegrade nephrostogram.¹ All patients included in their study reported relief of symptoms related to the original indication (leak, fistula, or haematuria). This suggests ureteral embolisation is an effective technique with a high success rate. Theoretically, reopening and leaking after embolisation can occur, however no documented events have been recorded in literature.

4. Conclusion

We present a successful management option for persistent ureteral-ileal leak, insufficiently managed standard urinary diversion techniques, using coils and glue to completely occlude the ureters. Ureteral embolisation should be considered in patients with persistent anastomotic leaks and unsuitable for surgical management.

Consent

Written informed consent was obtained from the patient for

publication of this case report and accompanying images.

Declaration of competing interest

The authors declare that they have no conflicts of interest.

Acknowledgements

Thank you to the interventional radiology department at Sir Charles Gairdner Hospital for assisting with the procedure and providing images: Dr John Tibbals, Dr Shaun Samuelson and Dr William Ormiston.

References

1. Asvadi NH, Arellano RS. Transrenal antegrade ureteral occlusion: clinical assessment of indications, technique and outcomes. *J Urol.* 2015;194(5):1428–1433.
2. Schild HH, Günther R, Thelen M. Transrenal ureteral occlusion: results and problems. *J Vasc Intervent Radiol.* 1994;5(2):321–325.
3. Forde JC, O'Connor KM, Fanning DM, Guiney MJ, Lynch TH. Management of a persistent ileo-ureteric anastomotic leak with bilateral ureteric occlusion using angioplasty balloon catheters. *Can J Urol.* 2010;17(5):5397–5400.
4. Yarlagadda V, Pettibon K, Ertel N, Nix J. Ureteral embolization to prevent thrombotic obstruction of nephrostomy catheters in the context of refractory hemorrhagic radiation cystitis with severe vesicoureteral reflux, 2016 *Case Reports in Urology.* 2016.
5. Huber T, Wilkins LR, Sabri S, et al. Midterm follow-up of ureteral embolization using vascular plugs and N-butyl cyanoacrylate glue. *J Vasc Intervent Radiol.* 2017;28(8): 1123–1128.