

Arterial palmar arch occlusion in a woman with Raynaud's disease taking oral combined menopausal hormone therapy: A case report

Cristina Llaneza-Suarez ^a, Montserrat Eiriz-Eirin ^a, Placido Llaneza ^{b,*}

^a Xove Centro de Salud, Hospital Da Costa Burela, Camino Real, 0, 27870 Xove, Lugo, Spain

^b Universidad de Oviedo, La Merced, 22, 2C, 33201 Oviedo, Gijón, Spain

ARTICLE INFO

Article history:

Received 7 April 2020

Received in revised form 16 April 2020

Accepted 20 April 2020

Keywords:

Arterial palmar arch occlusion

Finger vascular lesion

Menopausal hormone therapy

Raynaud's disease

Cardiovascular risk

ABSTRACT

Patients with surgical menopause often present to their primary care provider with menopausal symptoms. Here we present an unusual case of palmar arch artery occlusion in a 55-year-old woman with primary Raynaud's disease taking oral combined menopausal hormone therapy after surgical menopause for endometriosis. She was successfully treated with intravenous infusion of prostaglandin E1 and nitroglycerin patches over two weeks. Menopausal hormone therapy was stopped and her vasomotor symptoms did not recur.

© 2020 Published by Elsevier B.V. This is an open access article under the CC BY-NC-ND license (<http://creativecommons.org/licenses/by-nc-nd/4.0/>).

1. Introduction

Oophorectomy at the time of hysterectomy causes a sudden reduction in the production of ovarian sex steroid and often results in the immediate postoperative appearance of vasomotor and other menopausal symptoms, which are usually more severe than in women with natural menopause [1,2]. Thus, women with surgical menopause often present to their primary care provider with menopausal symptoms requesting treatment. Here we present an unusual case of right arterial palmar arch occlusion and a vascular lesion in the distal phalanx of the first right finger in a woman with primary Raynaud's disease taking oral combined menopausal hormone therapy (MHT) after surgical menopause for endometriosis.

2. Case Presentation

A 55-year-old woman with a history of surgical menopause, vasomotor symptoms and primary Raynaud's disease presented to the emergency department with pain, swelling and redness in the distal phalanx of the first right finger for 3 weeks. Symptoms had not responded to several courses of oral antibiotic therapy. The redness had spread and the finger had recently enlarged over 4 days. A smoker for 23 years, she drank alcohol in moderation. Her family history was unremarkable. Primary Raynaud's disease had been diagnosed many

years before and no other connective tissue diseases were present. She had undergone total abdominal hysterectomy and bilateral salpingo-oophorectomy for leiomyomas and endometriosis 12 months previously. For the past 8 months she had been successfully treated with combined oral MHT consisting of estradiol hemihydrate 1 mg and norethisterone acetate 1 mg orally once a day for severe vasomotor symptoms. She was taking combined MHT because of her history of endometriosis.

On physical examination, the patient's weight was 98 kg (BMI: 34) and her temperature was 37.1 °C. Her blood pressure was 140/84 mmHg and heart rate 95 beats per minute with a regular rhythm. The results of an examination of the head, eyes, ears, nose, and throat were normal. Examination of the chest and heart revealed no abnormalities.

The patient was admitted to hospital for intravenous antibiotic treatment with piperacillin (4 g) with tazobactam (500 mg) 8 hourly for 10 days but she did not improve. Hematocrit and hemoglobin levels were normal. Erythrocyte sedimentation rate was 25 mm/h (1–20 mm/h), C-reactive protein 0.32 mg/dL (0–0.5 mg/dL) and procalcitonin 0.03 ng/mL (0–0.49 ng/mL).

MHT was stopped, an ultrasound examination of the finger was performed and she was referred to a vascular surgeon. Finger sonography showed increased thickness and flow on power Doppler. Arteriography revealed narrowing and tapering of radial, ulnar, interosseous arteries and digital vessels and occlusion of the palmar arch (Fig. 1). She was treated with intravenous infusion of prostaglandin E1 (Alprostadiol®) 20 µg per day for 13 days. A nitroglycerin patch (glyceryl trinitrate, 10 mg changed every 24 h), applied the first phalanx of the finger for 15 days, was also prescribed. Clinical resolution of the finger lesion

* Corresponding author.

E-mail addresses: meireir@sergas.es (M. Eiriz-Eirin), llaneza@uniovi.es (P. Llaneza).

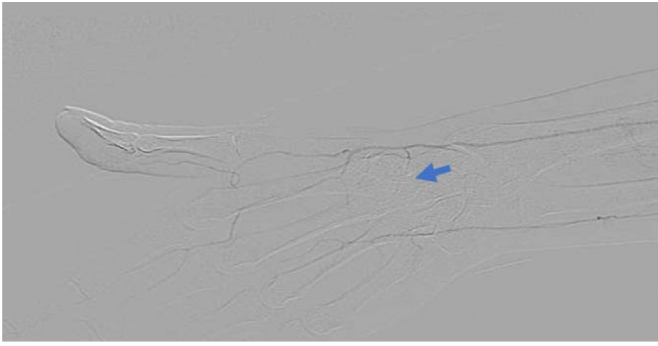


Fig. 1. Right-hand arteriography showing narrowing and tapering of radial, ulnar, interosseous arteries and digital vessels and occlusion of the palmar arch (arrow).

occurred after 15 days. After hospital discharge, the patient was referred to a behavior change program for smoking cessation, healthy diet and physical exercise. Her vasomotor symptoms improved and she was no longer taking MHT.

3. Discussion

The most effective treatment for menopausal symptoms is MHT with systemic estrogen. MHT includes a wide range of hormonal products, doses and routes of administration. Estrogen as a single systemic agent is appropriate in women after hysterectomy, but estrogen plus concomitant progestogen is required in the presence of a uterus for endometrial protection [3]. Combined MHT may be used after hysterectomy to prevent reactivation of pre-existing endometriosis. However, randomized clinical trials have shown that combined oral MHT containing estrogen plus progestin is associated with risk of breast cancer, arterial or venous disease and thromboembolic events [4,5].

Primary Raynaud's disease is characterized by constriction of the small arteries of the extremities in response to cold, pain, or emotional stimuli. Increased vasoconstriction is mediated by activation of the alpha-2 adrenoreceptors. In these patients the intracellular signalling pathway is modified and causes increased sensitivity of contractile proteins to calcium in the smooth muscle of cutaneous vessels. Intravascular abnormalities including platelet activation with increased thromboxane, defective fibrinolysis and reduced deformability of red blood cells can also be present [6]. Few studies have been published on the use of MHT in women with Raynaud's disease but some factors as cigarette smoking or estrogen could be implicated in disease evolution [7]. Animal studies have shown that estrogen upregulates alpha-adrenergic receptor, stimulates the release of norepinephrine and increases the sensitivity of small arteries to epinephrine and norepinephrine with a potential negative effect [8]. In contrast, other studies have reported that progesterone either has little effect or has an effect opposite to that of estrogen [9].

Studies regarding MHT and Raynaud's disease are limited. A cross-sectional study of women from the Framingham Offspring Cohort examined 49 women diagnosed with Raynaud's phenomenon. In that small sample, unopposed estrogen therapy was associated with Raynaud phenomenon, but this association was not present in women receiving combined hormone therapy [10]. In our patient, combined MHT was prescribed for protection against reactivation of the endometriosis. The combination of oral estradiol with norethisterone has been associated with a lower risk of thrombosis compared to conjugated equine estrogen with medroxyprogesterone, but higher thrombosis risk than estradiol with dydrogesterone or micronized progesterone or unopposed estradiol by transdermal route [11,12]. In this regard, it is important to remember that MHT formulation, dose and route of administration may have different effects on target organs and potentially allow options to minimize risk.

Lastly, menopause management should be holistic and include lifestyle recommendations regarding diet, exercise, smoking cessation and safe levels of alcohol consumption [13,14].

Contributors

Cristina Llana-Suarez performed the literature search, collected the data, oversaw clinical care and edited the manuscript.

Montserrat Eiriz Eirin assisted in data collection, and oversaw clinical care and manuscript editing.

Placido Llana provided comments and critically revised the manuscript.

All authors saw and approved the final version of the manuscript.

Conflict of Interest

The authors declare that they have no conflict of interest regarding the publication of this case report.

Funding

No funding from an external source supported the publication of this case report.

Patient Consent

Obtained.

Provenance and Peer Review

This case report was peer reviewed.

References

- [1] M. Rodriguez, D. Shoupe, Surgical menopause, *Endocrinology and Metabolism Clinics of North America*, W.B. Saunders 2015, pp. 531–542, September 1.
- [2] A. Finch, S.A. Narod, Quality of life and health status after prophylactic salpingo-oophorectomy in women who carry a BRCA mutation: a review, *Maturitas* (2011) 261–265 November.
- [3] M. Neves-E-Castro, M. Birkhauser, G. Samsioe, I. Lambrinoudaki, S. Palacios, R.S. Borrego, P. Llana, I. Ceausu, H. Depypere, C.T. Erel, et al., EMAS position statement: the ten point guide to the integral management of menopausal health, *Maturitas* 81 (1) (2015).
- [4] J.E. Rossouw, G.L. Anderson, R.L. Prentice, A.Z. LaCroix, C. Kooperberg, M.L. Stefanick, R.D. Jackson, S.A.A. Beresford, B.V. Howard, K.C. Johnson, et al., Risks and benefits of Estrogen plus progestin in healthy postmenopausal women: principal results from the Women's Health Initiative randomized controlled trial, *JAMA* 288 (3) (2002) 321–333.
- [5] S. Hulley, D. Grady, T. Bush, C. Furberg, D. Herrington, B. Riggs, E. Vittinghoff, Randomized trial of Estrogen plus progestin for secondary prevention of coronary heart disease in postmenopausal women. Heart and Estrogen/Progestin Replacement Study (HERS) Research Group, *JAMA* 280 (7) (1998) 605–613.
- [6] K.K. Temprano, A review of Raynaud's disease, *Mo. Med.* (2016) 123–126 March 1.
- [7] S. Generini, J.R. Seibold, M. Maticci-Cerinic, Estrogens and neuropeptides in Raynaud's Phenomenon, *Rheum. Dis. Clin. N. Am.* (2005) 177–186 February.
- [8] B.M. Altura, Sex and estrogens and responsiveness of terminal arterioles to neurohypophysial hormones and catecholamines, *J. Pharmacol. Exp. Ther.* 193 (2) (1975) 403–412.
- [9] L.T. Williams, R.J. Lefkowitz, Regulation of rabbit myometrial alpha adrenergic receptors by estrogen and progesterone, *J. Clin. Invest.* 60 (4) (1977) 815–818.
- [10] L. Fraenkel, Y. Zhang, C.E. Chaisson, S.R. Evans, P.W.F. Wilson, D.T. Felson, The association of estrogen replacement therapy and the Raynaud phenomenon in postmenopausal women, *Ann. Intern. Med.* 129 (3) (1998) 208–211.
- [11] Y. Vinogradova, C. Coupland, J. Hippisley-Cox, Use of hormone replacement therapy and risk of venous thromboembolism: nested case-control studies using the QResearch and CPRD databases, *BMJ* 364 (2019) k4810.
- [12] The NAMS 2017 Hormone Therapy Position Statement Advisory Panel, The 2017 Hormone therapy position statement of the North American Menopause Society, *Menopause* 25 (11) (2018) 1362–1387.
- [13] T.J. de Villiers, A. Pines, N. Panay, M. Gambacciani, D.F. Archer, R.J. Baber, S.R. Davis, A.A. Gompel, V.W. Henderson, R. Langer, et al., Updated 2013 international menopause society recommendations on menopausal hormone therapy and preventive strategies for midlife health, *Climacteric* 16 (3) (2013) 316–337.
- [14] M. Rees, D. Goules, P. Lopes (Eds.), EMAS Care Online: The Essential Guide to Women's Health in Midlife and beyond, European Menopause and Andropause Society, Geneva, 2020. <https://www.emas-online.org/>.