

Available online at www.sciencedirect.com

ScienceDirect

journal homepage: <http://Elsevier.com/locate/radcr>

Interventional Radiology

Endovascular retrieval of foreign body in persistent left-sided superior vena cava

Michael Segal DO^{a,*}, Andres Krauthamer MD^b, Brian Hall MD^a, Kenneth Hassler DO^c, Stephen Carryl MD^a

^aDepartment of Surgery, Wyckoff Heights Medical Center, Brooklyn, USA

^bDepartment of Radiology, Wyckoff Heights Medical Center, Brooklyn, USA

^cDepartment of Surgery, Maricopa Integrated Health System, Phoenix, USA

ARTICLE INFO

Article history:

Received 9 May 2017

Accepted 7 July 2017

Available online

Keywords:

Superior vena cava

Persistent

Endovascular

Chemoport

Interventional radiology

Aberrant anatomy

ABSTRACT

Endovascular retrieval of a foreign body is becoming an increasingly common procedure in the management of complications resulting from more frequent endovascular procedures. Many procedures are performed on a regular basis in assessment of vascular anatomy, endovascular-guided therapy, and catheter placement. This case report depicts a complication of a chemoport placement resulting in a foreign body. Evaluation of the foreign body raised attention to aberrant anatomy, a persistent left-sided superior vena cava. We further discuss briefly the embryology behind a persistent left-sided superior vena cava, technical errors leading to the foreign body, and assessing the nature of the foreign body through different imaging modalities. This is followed by the subsequent endovascular retrieval by Interventional Radiology and a literature review and individual case assessment of endovascular foreign body retrieval. We discuss considerations for practice based upon our literature review.

© 2017 the Authors. Published by Elsevier Inc. under copyright license from the University of Washington. This is an open access article under the CC BY-NC-ND license (<http://creativecommons.org/licenses/by-nc-nd/4.0/>).

Case report

We present the case of a 52-year-old female with clinical stage IIB ductal carcinoma ER-, PR-, Her2, of the right breast confirmed by core needle biopsy. A positron emission tomography (PET) scan confirmed axillary node involvement without any

other nodal involvement or metastasis; however, the mass was abutting the pectoralis muscle. Following a multidiscipline tumor board discussion, the plan was to begin with neoadjuvant chemotherapy.

The patient presented through ambulatory surgery for operative Chemoport placement. The planned site of access was the left subclavian vein due to right breast cancer and concern

Disclosures: None.

Authors' contributions: Michael Segal: Primary author, involved in IR/General case, primary correspondent. Andres Krauthamer: Interventional radiologist involved with case and editing report. Brian Hall: General surgeon involved with case and editing report. Kenneth Hassler: Secondary author writing/editing paper. Stephen Carryl: Editing paper.

* Corresponding author.

E-mail address: msegal3110@gmail.com (M. Segal).

<https://doi.org/10.1016/j.radcr.2017.07.011>

1930-0433/© 2017 the Authors. Published by Elsevier Inc. under copyright license from the University of Washington. This is an open access article under the CC BY-NC-ND license (<http://creativecommons.org/licenses/by-nc-nd/4.0/>).

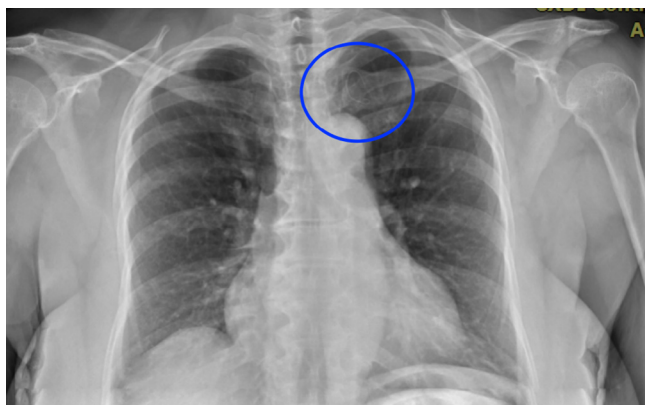


Fig. 1 – Anteroposterior Chest X-ray displaying a retained portion of guidewire in the left chest.

for future right-sided intervention. The introducer needle was inserted successfully into the left subclavian vein and confirmed by venous aspiration. Upon passage of the guidewire under fluoroscopic guidance, the guidewire was noted to be in an aberrant position. As the guidewire was manipulated and withdrawn through the introducer needle, it was noted that a portion of the guidewire had sheared off and was retained as a foreign body. This is seen on the postprocedural chest X-ray (Fig. 1). At this point the procedure was aborted and the presumed Chemoport subcutaneous pocket was closed.

A postoperative computed tomography (CT) chest with contrast was obtained to further evaluate the positioning of the foreign body (Supplementary Image Stack S1, S2). The CT images demonstrated a persistent left superior vena cava (SVC) with a partially intravascular retained guidewire at the junction of the left brachiocephalic and SVC junction (Fig. 2).

At this point, Interventional Radiology was consulted and the patient was taken for endovascular retrieval of the foreign body. A 5Fr sheath was introduced into the left basilic vein. A venogram was performed to define and further delineate the anatomy (Fig. 3). With the assistance of a 5Fr guiding catheter, an endovascular gooseneck snare was used to capture the foreign body (Fig. 4). The guidewire was then retrieved without significant resistance through an endovascular approach (Fig. 5).

Upon completion of the retrieval, a Hickman catheter was inserted in the persistent left SVC without any complications (Fig. 6). Patient has since successfully received multiple courses of neoadjuvant chemotherapy via the placed Hickman catheter.

Discussion

Endovascular retrieval of a foreign body is becoming an increasingly more common procedure in the management of complications resulting from more frequent endovascular procedures. Many procedures are performed on a regular basis in assessment of vascular anatomy, endovascular-guided therapy, and catheter placement. Retrieval of these intravascular foreign bodies can now be accomplished at a low risk and serve to potentially prevent serious complications caused by migration of a guidewire fragment intravascularly [1]. Current literature,

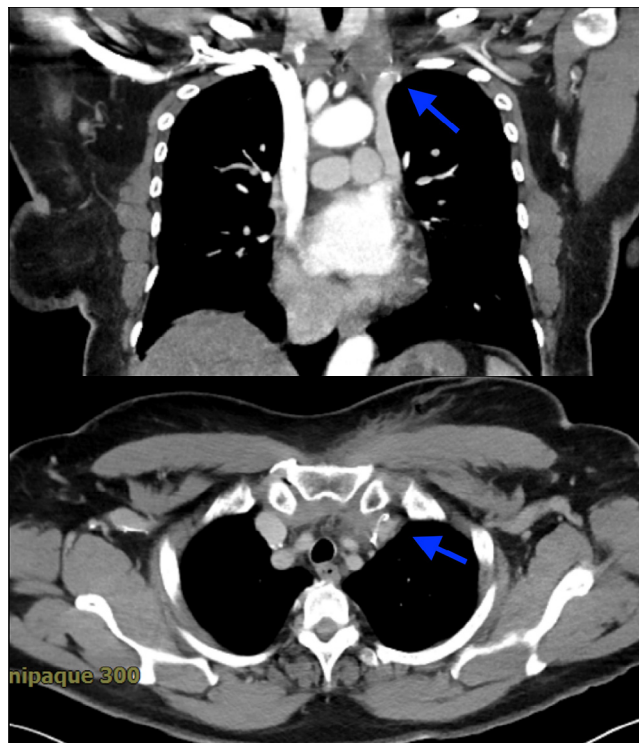


Fig. 2 – Computed tomography (CT) chest with intravenous contrast with 3-mm helical axial imaging and coronal reformation displaying rudimentary left superior vena cava (SVC) with retained guidewire at the left brachiocephalic junction.

however, is trending toward leaving venous foreign bodies in situ due to clinically lower observed complication rates than older literature had originally inferred [2]. With this in mind, endovascular retrieval should be approached with caution.

The embryonic development of the heart begins early in fetal life. At 3 weeks, the endocardial tubes fuse together into a primary heart. Following this development, sulci divide the heart tube into sections including the sinus venosus, into which the common cardinal veins, the umbilical veins, and the vitelline veins drain. The common cardinal veins then differentiate into an anterior and medial cardinal vein [3]. Typically, the left anterior cardinal veins obliterate, leaving only the oblique vein of Marshall as a remnant. It is the failure of the left cardinal vein to obliterate that leads to the development of a “persistent” left-sided SVC.

The presence of a “persistent” left-sided SVC may be identified in the preoperative period. However, investigation is typically foregone due to the low prevalence. A persistent left-sided SVC is present in 0.3%-0.5% of the general population, and is more frequently noted in 10% of those with congenital heart disease [3]. In our case, there was no identification of a persistent left-sided SVC on preoperative imaging reports or 2D echo. Typically, dilation of the coronary sinus is the first hint of this anomaly due to the direct drainage from the left-sided SVC [4]. Again, this was not noted in the preoperative Echo report. Echo may be limited by acoustic windows and will have a lower sensitivity to diagnose such an anomaly. Additionally, review of the PET scan for vasculature anatomy was not performed and no radiologic notation of the anomaly on

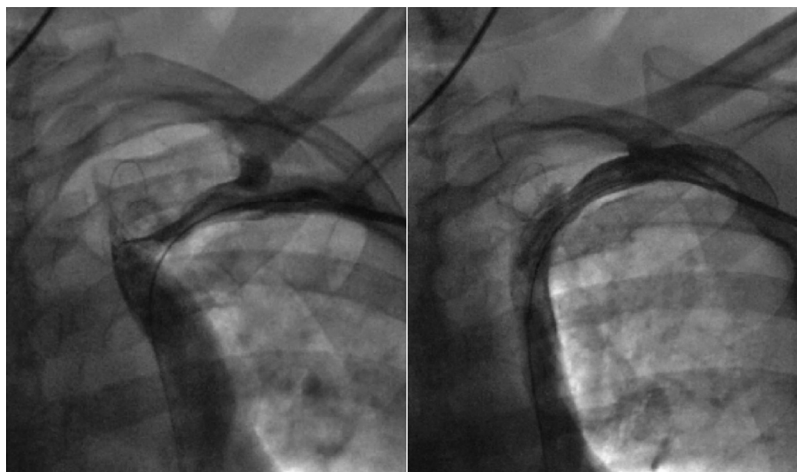


Fig. 3 – Initial venogram displayed in both images shot through 7 Fr 23-cm Pinnacle introducer sheath (Terumo Medical Corp, Somerset, NJ) using Visipaque 320.

PET-CT was noted. This was likely an oversight as a PET-CT for staging of the breast cancer should have been sufficient to identify the anatomy.

Most frequently, this anomalous anatomy is incidentally found during central venous catheter placement. Confirmatory imaging, following placement of these catheters, displays the catheter tip in an aberrant position [5]. The presence of this anomaly may complicate accurate placement of the guidewire

in unknowing hands. During our procedure, there was a thought that the guidewire had begun to pass through the left brachiocephalic vein. In retrospect, after reviewing perioperative imaging, there was no crossing anatomic vein to the SVC. It should be noted that there is an anatomic variation of this anomaly where there is an innominate bridging vein that is present in up to 30% [6]. The mindful surgeon should be aware of this potential variation.

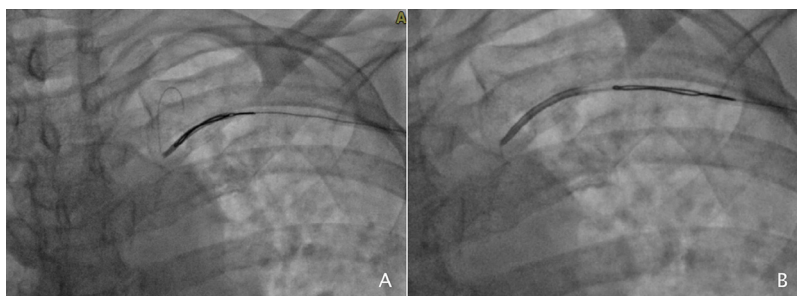


Fig. 4 – Fluoroscopic imaging of endovascular retrieval of foreign body located in persistent left superior vena cava (SVC) using 15-mm Amplatz Gooseneck snare and 6Fr MPA catheter (Covidien Medtronic HQ, Minneapolis, MN). Imaging displays initial snare of foreign body (A) and foreign body being removed with no foreign body retained (B).

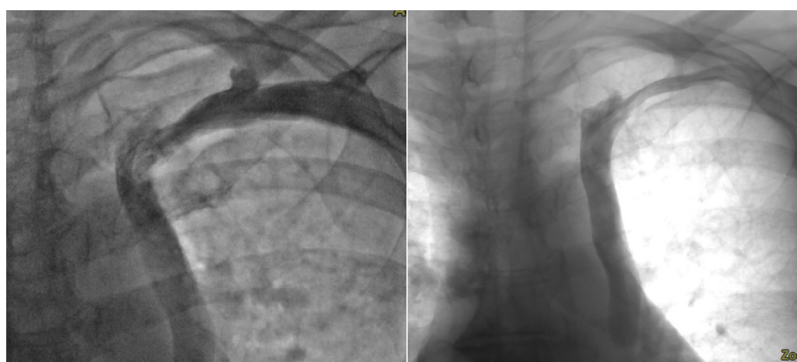

Fig. 5 – Fluoroscopic completion venogram through a 6Fr MPA catheter using Visipaque 320 displaying left subclavian vein and persistent left superior vena cava (SVC) following endovascular retrieval of foreign body.

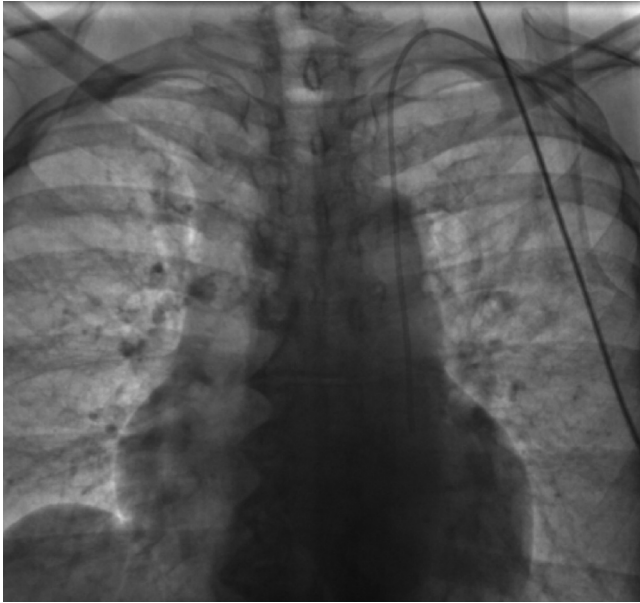

Fig. 6 – Fluoroscopic confirmatory image of placement of a tunneled 6Fr double lumen Power Hickman central venous catheter (BARD, Temple, AZ) with catheter tip floating freely in persistent left superior vena cava (SVC).

There must be a wholesome consideration as to the rationale for retrieval of the foreign body. It has historically been the standard to retrieve all endovascular foreign bodies as a literature review in 1978 by Fisher and Ferreyro of intravascular foreign bodies described a 71% rate of serious complications with a death rate of 38% [7]. These data are now outdated and not widely accepted as the normal rates of complications as more recent data reflect that leaving foreign bodies in situ may be a more appropriate option in an asymptomatic patient [2]. In our case, the decision to retrieve the foreign body deemed necessary as the Chemoport placement on the left side was essential to the patients' treatment. With this approach, there was concern for dislodgement of the foreign body with catheter placement. The foreign body was ultimately retrieved endovascularly using the gooseneck snare without any difficulty. If there was any difficulty in retrieving the foreign body due to resistance or increased procedural time, the procedure would have been aborted.

Takeaways from the case include early identification of any anatomic variance and technical considerations to prevent future complications. One well-documented option would be to perform a venogram to identify anatomy when variation is in question. This would have identified a persistent left-sided SVC and prevented the subsequent manipulation of the guidewire with the introducer needle in place. It was this technical error that resulted in a portion of the guidewire being sheared and retained as a foreign body.

In review, we would not recommend any preoperative imaging to identify this rare anomaly as this is a low-yield practice. We would, however, recommend that any interventionists

performing these procedures should be well versed in the possible anatomic variations as to prevent unneeded manipulation leading to potential harm.

Upon identification of aberrant anatomy, the decision on how to proceed should be made early. The decision on how to proceed when faced with a clearly peculiar positioning of the catheter or guidewire determines whether an intraoperative venogram should be used to help assess the anatomy or the procedure should be aborted and postoperative imaging obtained. Subsequent retrieval of a foreign body should be taken on a case-by-case basis as interventions or leaving the foreign body in place typically pose little risk.

Teaching point

In review, we would not recommend any preoperative imaging to identify this rare anomaly of persistent left-sided SVC, as this is a low-yield practice. We would, however, recommend that any interventionists performing these procedures should be well versed in the possible anatomic variations as to prevent unneeded manipulation leading to potential harm, as well as potential methods to assess the anatomy intraoperatively.

Supplementary data

Supplementary data associated with this article can be found online version, at <http://dx.doi.org/10.1016/j.radcr.2017.07.011>.

REFERENCES

- [1] Carroll MI, Ahanchi SS, Kim JH, Panneton JM. Endovascular foreign body retrieval. *J Vasc Surg* 2013;57(2):459–63. PMID: 23069073.
- [2] Thomson KR. Nonsurgical retrieval of devices and foreign bodies. *Endovasc Today* 2010;29–32.
- [3] Irwin RB, Greaves M, Schmitt M. Left superior vena cava: revisited. *Eur Heart J Cardiovasc Imaging* 2012;13(4):284–91. PMID: 22301985.
- [4] Shah SS, Teague SD, Lu JC, Dorfman AL, Kazerooni EA, Agarwal PP. Imaging of the coronary sinus: normal anatomy and congenital abnormalities. *Radiographics* 2012;32(4):991–1008. PMID: 22786990.
- [5] Povoski SP, Khabiri H. Persistent left superior vena cava: review of the literature, clinical implications, and relevance of alterations in thoracic central venous anatomy as pertaining to the general principles of central venous access device placement and venography in cancer patients. *World J Surg Oncol* 2011;9:173. PMID: PMC3266648.
- [6] Pretorius PM, Gleeson FV. Case 74: right-sided superior vena cava draining into left atrium in a patient with persistent left-sided superior vena cava. *Radiology* 2004;232(3):730–4. PMID: 15333794.
- [7] Fisher RG, Ferreyro R. Evaluation of current techniques for nonsurgical removal of intravascular iatrogenic foreign bodies. *AJR Am J Roentgenol* 1978;130:541–8. PMID:415566.