

Induced sputum versus bronchial washings in the diagnosis of sputum negative pulmonary tuberculosis

Gopathi Nageswar Rao¹, Mandava Venu¹, Namballa Usha Rani¹,
Makala Sravani¹

¹Department of Pulmonology, Government Hospital for Chest and Communicable Diseases, Katuri Medical College, Guntur, Andhra Pradesh, India

ABSTRACT

Introduction: Tuberculosis (TB) is one of the most important public health problems worldwide. Detecting patients with active pulmonary TB (PT) is an important component of TB control programs. However, at times in patients even with a compatible clinical picture, sputum smears do not reveal acid-fast bacilli (AFB) and smear-negative PT remains a common problem. This study compares the results of induced sputum (IS) and bronchial washings (BWs) in detecting sputum negative PT. **Materials and Methods:** A prospective study conducted from June 2014 to June 2015, comprising 120 patients fulfilling study criteria. Patients with respiratory symptoms and chest roentgenogram suspicious of PT with no previous history of antiTB treatment (ATT) and two spontaneous sputum smear samples negative for AFB were included in the study. Patients with active hemoptysis and sputum positive were excluded from the study. Sputum induction was done using 5–10 ml of 3% hypertonic saline through ultrasonic nebulizer taking safety precautions. All the patients underwent fiberoptic bronchoscopy after 6 h fasting on the same day. About 20 ml of normal saline instilled into the suspected pathology area and washings were taken with gentle suction. The sample processing and fluorescent staining for AFB were done in a designated microscopy laboratory. **Results:** Of 120 smear-negative PT patients, IS smear examination detected AFB in 76 patients (63.3%) and AFB detected from BWs in 94 patients (78.5%). Smear positivity higher in cavitory and infiltrative lesions compared to consolidation and infrahilar pattern disease. **Conclusions:** Even though both IS and BWs procedures were valuable for the diagnosis of smear-negative TB, sputum induction with hypertonic saline should be the initial procedure of choice, which can be repeated twice/thrice in a day or 2 consecutive days. If the patient remains IS smear-negative and if the clinical probability of TB is high, starting ATT and closely monitoring patient and reserving bronchoscopy to those patients who do not improve and to exclude alternative diagnosis seems to be a practically useful approach.

Keywords: Acid-fast bacilli, antituberculosis treatment, fiberoptic bronchoscopy, smear-negative pulmonary tuberculosis

Introduction

Tuberculosis (TB) is one of the most important public health problems worldwide and is declared as “global emergency” by the World Health Organization.^[1] An estimated 9 million people fell ill with TB in 2014, and 1.5 million died worldwide.^[2]

Detecting patients with active pulmonary TB (PT) disease is an important component of TB control programs as early appropriate treatment renders these patients noninfectious and interrupts the chain of transmission of TB. Under the program conditions, diagnosis of PT is based on sputum examination. Acid-fast bacilli (AFB) staining by fluorescent microscopy remains a fundamental tool of diagnosis, but may be negative up to 50% of active PT.^[3] Alternative methods of obtaining sputum specimens are frequently needed in those patients with

Address for correspondence: Dr. Gopathi Nageswar Rao, Assistant Professor, Department of Pulmonology, Katuri Medical College, Guntur - 522 017, Andhra Pradesh, India. E-mail: nityanageswar@gmail.com

Access this article online

Quick Response Code:



Website:
www.jfmpc.com

DOI:
10.4103/2249-4863.192336

This is an open access article distributed under the terms of the Creative Commons Attribution-NonCommercial-ShareAlike 3.0 License, which allows others to remix, tweak, and build upon the work non-commercially, as long as the author is credited and the new creations are licensed under the identical terms.

For reprints contact: reprints@medknow.com

How to cite this article: Rao GN, Venu M, Rani NU, Sravani M. Induced sputum versus bronchial washings in the diagnosis of sputum negative pulmonary tuberculosis. J Family Med Prim Care 2016;5:435-9.

radiological suspicion of PT, who are unable to expectorate or are smear-negative. These methods include – induced sputum (IS), bronchial washings (BWs), bronchoalveolar lavage, and gastric washings samples. Each method has its advantages and disadvantages and diagnostic yield vary.

Bronchoscopy is an invasive procedure, only available in the large hospitals, needs experts for performance, costly, and may not be feasible if the large numbers of patients are to be tested. IS technique is a cheap and noninvasive alternative with a diagnostic yield “same if not better” than bronchoscope.^[4] This study aims to compare the results of sputum induction and BWs in the diagnosis of smear-negative PT.

Materials and Methods

One hundred and thirty patients of suspected PT with negative sputum smear during 1 year at our Pulmonology Department were enrolled in the study. The inclusion criteria were – (i) patients with respiratory symptoms suspicious of PT such as cough for 2 weeks or more, evening rise of temperature, dyspnea, loss of weight, and appetite, (ii) Sputum either not produced or sputum negative for AFB on two samples, (iii) chest radiograph showing changes consistent with active PT, and (iv) age more than 18 years. Patients with uncontrolled asthma or chronic obstructive pulmonary disease, active hemoptysis, unstable angina, and patients already on antituberculous therapy were excluded from the study. Informed consent was taken from all the patients, and the study was approved by the Institutional Ethics Committee.

For all the 130 selected patients, a detailed clinical history, thorough clinical examination was made, and necessary investigations such as chest radiography, sputum induction, and flexible bronchoscopy were done. Computed tomogram (CT) of chest and Mantoux skin test were done wherever needed. Each patient’s chest radiographs and CT chest were evaluated independently by two senior chest physicians. Abnormalities compatible with a possible active disease such as cavitary lesions, consolidation, fluffy shadows, infiltrates, and miliary pattern were noted.

Sputum induction was done using 10 ml of 3% hypertonic saline through an ultrasonic nebulizer (Beurer Ultrasonic Nebulizer IH50) according to Iredale *et al.* protocol.^[5] Inhalation continued till the patient had either produced good amount of sputum or 15 min time elapsed. Sample collected in a sterile container, concentrated by modified Petroff’s method, and examined for AFB by fluorescent staining technique in a designated microscopy center. The procedure was done in a well-ventilated room with adequate safety precautions for the staff members who supervised the procedure. The patient was closely monitored during the procedure and 1 h postprocedure. The nebulizer equipment was decontaminated with 2% glutaraldehyde.

All the above patients underwent flexible bronchoscopy (Karl Storz) after 6 h fasting on the same day transnasally under local anesthesia with 2% lignocaine. BW was performed by instilling 20 ml normal saline at room temperature through the working channel of the fiberoptic bronchoscope and aspirated into a suction trap. The sample processing done as said above. After the procedure is over, the patient was observed for the development of any pneumothorax, hemorrhage, infection, and cardiac arrhythmias for 24–48 h. Bronchoscope was thoroughly cleaned with water and sterilized by immersing in 2% glutaraldehyde for 1 h.

All the patients were initiated on anti-TB treatment (ATT) under revised national TB control program and were followed up at monthly intervals in the initial intensive phase and at bimonthly intervals in the continuation phase. The clinical and radiological response were evaluated. Of the total 130 patients, during the follow-up period, six patients failed to turn up, and an alternative non-TB diagnosis was made in four patients. These 10 members were excluded from the final study group, and results were statistically analyzed.

Results

Out of 120 patients in the study group, 78 were males, and 42 were females. Most patients were in the age group of 31–50 years (62.5%) with a mean age of 38 years [Table 1]. The main symptomatology of patients was cough (95%), expectoration (88%), fever (80%), and loss of appetite (75%). Radiologically, an exclusive upper zone involvement was seen in 70% of patients ($n = 84$) while 25% of other patients ($n = 30$) had multilobar involvement including upper zones and six patients had exclusive lower zone involvement. Most common findings on chest X-ray are cavitations in 53% cases ($n = 64$) followed by

Table 1: Clinico-epidemiological profile of smear-negative pulmonary tuberculosis patients

Character	Subset	Total number (n)	Percentage
Gender	Male	78	65
	Female	42	35
Age (years)	11-20	9	7.5
	21-30	24	20
	31-40	42	35
	41-50	33	27.5
	51-60	12	10
Symptoms	Cough	114	95
	Expectoration	106	88
	Fever	96	80
	Loss of appetite	90	75
	Dyspnea	75	63
	Chest pain	38	32
	Hemoptysis	18	15
Zonal involvement	Upper zone	84	70
	Multilobar	30	25
	Lower zone	6	5

fluffy or nodular infiltrations in 22% patients ($n = 26$), miliary pattern in 12% ($n = 14$), consolidation (8.3%, $n = 10$), and infrahilar distribution (5%, $n = 6$) [Figure 1].

Of the total 120 patients, IS smear examination for AFB was positive in 76 cases (63.3%) and BWs detected AFB in 94 cases (78.3%). Neither of the methods do not detected AFB in 18 patients (15%). Sputum induction procedure additionally detected AFB in eight cases where BWs results were negative (6.6%). Bronchoscopy yielded an extra positivity of 26 cases in IS negative scenario (21.6%) [Figure 2]. There appears a fair agreement between the two procedures (kappa coefficient is 0.337)

In pulmonary cavitary lesions, sputum induction detected bacilli in 62% (40 out of 64 cases) and bronchoscopy-guided washings detected in 81% cases (52 out of 64 cases). The sensitivity rate in fluffy, infiltrative lesions was 69% and 77% for SI and BW successfully. Miliary pattern nodules have a positivity rate of 71% in SI and 86% in BW [Figure 3].

Discussion

As a destroyer of humankind, TB has no equivalent. It continues to intimidate the human race since time immemorial. Diagnosis of active PT is an important component of TB control programs in all countries as early institution of ATT makes the patients less infectious and interrupts the chain of transmission of TB. Although sputum microscopy is the most appropriate, low cost, highly specific investigation to diagnose PT, in 22–61% of the cases, sputum smear-negative (SSN), and culture positive status is observed.^[6] Causes of smear negativity include low bacterial load ($<10,000$ bacilli/ml), poor quality of sputum sample (submitting saliva as sputum), improper preparation and examination of smears, people with late-stage HIV disease, immune suppressed patients, and children.^[7]

SSN-PT remains a common problem faced by the clinicians. Over 50% of smear-negative patients would be needing chemotherapy by 12 months if left untreated.^[8] The mortality rate for smear-negative, culture-positive cases was 14.1% compared with the 34.7% observed in smear-positive patients.^[9] Thus, early diagnosis of active SSN-PT disease is also important.

Various methods have been used for the diagnosis of disease activity in smear-negative cases. They are sputum induction, gastric lavage, BWs, bronchoalveolar lavage, and bronchial biopsy.^[10]

Sputum induction procedure was first used by Hensler *et al.*, for the diagnosis of active PT.^[11] The ultrasonic nebulizer produces a mist of hypertonic saline droplets. The smaller droplets are deposited peripherally in the lung. They draw interstitial fluid into lower airways by osmosis. Also causes bronchial irritation and stimulates bronchial secretions. After 10–20 min of nebulization,

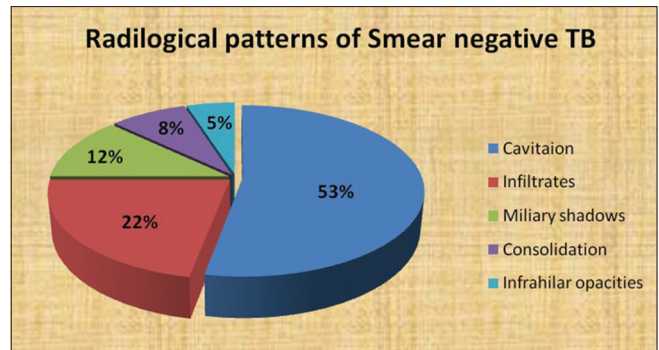


Figure 1: Chest radiography findings in suspected smear-negative pulmonary tuberculosis patients

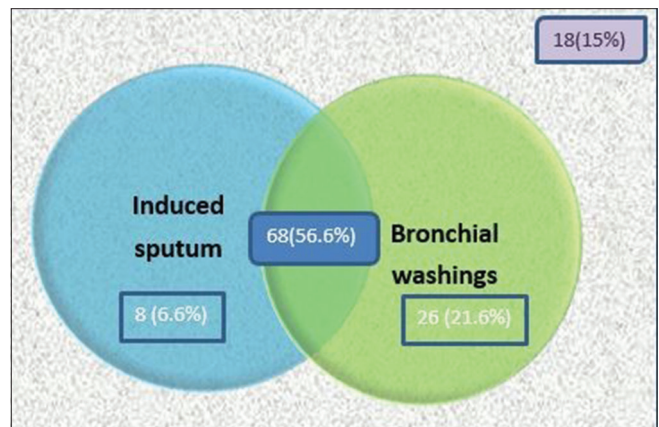


Figure 2: Venn representation of induced sputum and bronchial washings accuracy

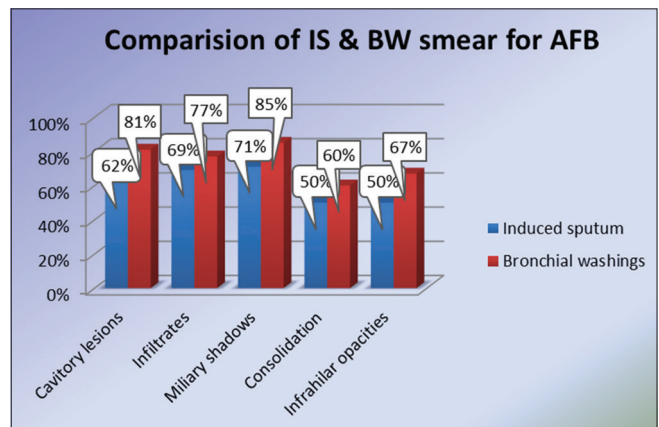


Figure 3: Acid-fast bacilli positivity among induced sputum and bronchial washings according to the pathology

the fluid produced mobilize the material in lower airways. Repeated coughing by the patient helps in the movement of this material into trachea to facilitate expectoration.^[12] Commonly used agents are hypertonic saline of varying concentrations, namely, 3%, 4.5%, 5%, glucose, and salbutamol.^[13] IS also helpful in diagnosis of pneumocystis pneumonia,^[14] eosinophilic asthma,^[15] pleural TB,^[16] interstitial lung disease,^[17] and lung cancer.^[18]

In this study, IS smear positivity of 63.3% is higher, compared to the previous studies by Saglam *et al.*^[19] with 47% positivity and Hartung *et al.*^[20] study with 42% positivity. In another large study of 129 subjects by McWilliams *et al.*,^[21] IS AFB sensitivity was found to be very high, i.e., 96%. The higher positive results may be related to the difference in the methodology as each patient went through three IS procedures and also because both fluorochrome and Ziehl–Neelsen staining methods were used for AFB detection. McWilliams *et al.* concluded that since chances of missing diagnosis with single IS procedure are high, three IS tests should replace bronchoscopy in investigating a case of TB suspect.^[21]

The fiberoptic bronchoscope was first invented by Dr. Shigeto Ikeda. The advantage of flexible bronchoscopy over the rigid bronchoscopy is that the procedure is done under local anesthesia and a wide range of visibility up to subsegmental bronchi. Bronchoscopy nowadays has wider availability and provides excellent sample for the diagnosis of suspected cases of TB.^[22]

In this study, BWs smear results were positive in 78.5% of cases. In the previous studies by Charoenratanakul *et al.*,^[23] Fujii *et al.*^[24] and Chawla *et al.*,^[25] positive BW/BL results ranged from 25% to 72%. Some of the studies also included post bronchoscopy sputum and cultures, which made the result increase up to 90%.^[26,27] The wide range of difference in the results may be related to differences in procedure, cooperation of patients, experience of bronchoscopist, and quantity of fluid for irrigation and dose of xylocaine used.

The chest radiographic appearances of the study subjects were evaluated and it is observed that IS smear positivity (70%, $n = 18/26$), and BWs smear positivity (77%, $n = 20/26$) were higher in patients presenting with fluffy nodular infiltrates followed by cavitory lesions (62% and 81% for IS and BW). In this study, 10 patients presented with consolidation pattern, five cases were AFB positive by IS (50%) and six were by BWs (60%). In six cases of infrahilar TB, IS was positive in 50% (3/6), and BWs was positive in 66% (4/6). In two studies by Chan *et al.*,^[27] Jain *et al.*^[28] where lower lung field TB cases were evaluated, bronchial smear positivity was observed in 75% and 67% of the cases, respectively.

All the study subjects were initiated on ATT and they were followed up regularly at monthly intervals in intensive phase and bimonthly intervals in the continuation phase. The 18 cases which were negative for AFB by both IS and BWs showed good clinical and radiological response on starting ATT. Rest of the cases positive for AFB either by IS or BWs or both responded well to ATT. The study is limited by lack of culture facilities for *Mycobacterium tuberculosis*.

Although this study shows that BWs smear positivity is higher compared to IS for detecting active TB, sputum induction is a good alternative for flexible bronchoscopy. Although in developed countries with good-resource settings, bronchoscopy

is the initial procedure of choice for smear-negative TB; lately, there is a renewed interest in sputum induction procedures due to the advent of acquired immunodeficiency syndrome. Sputum induction procedure has several advantages, as it is cost effective, safe, and well tolerated, has low risk of nosocomial TB transmission more available and does not need expertise. Conde *et al.*^[29] observed that there is no significant difference in the yield of AFB smear or cultures obtained by sputum induction or bronchial lavage as IS has a diagnostic yield in agreement with the results of FOB for diagnosis of TB in both HIV seronegative and seropositive patients. On the other hand, bronchoscopy is a semi-invasive procedure, time-consuming, expensive requires trained personnel and special equipment and not widely available in developing countries and resource-poor settings. Hence, it is suggested that the best course of action in a patient with suspected SSN-PT would be, sputum induction with hypertonic saline as the initial procedure of choice, which can be repeated twice/thrice in a day or 2 consecutive days. If the patient remains IS negative and if the clinical probability of TB is high, starting ATT and closely monitoring the patient and reserving bronchoscopy to those patients who do not improve and to exclude alternative diagnosis such as pulmonary neoplasm seems to be a practically useful approach. If the clinical probability of TB is low; then, early bronchoscopy may be carried out in such patients.^[30]

Conclusions

Even though both IS and BWs were valuable for the diagnosis of TB in patients with SSN for AFB, bronchoscopy is a semi-invasive procedure, expensive, and not readily available everywhere, whereas sputum induction procedure is simple, relatively safe, cost effective, and is widely available. Therefore, in a patient with suspected SSN-PT sputum induction should be the initial procedure of choice, reserving bronchoscopy for those nonresponders seems to be a practically useful approach.

Financial support and sponsorship

Nil.

Conflicts of interest

There are no conflicts of interest.

References

1. Malin AS, McAdam KP. Escalating threat from tuberculosis: The third epidemic. *Thorax* 1995;50 Suppl 1:S37-42.
2. National TB Statistics: TB Facts; 2014. Available from: <http://www.tbfacts.org/tb-statistics.html>. [Last accessed on 2015 May 01].
3. American Thoracic Society and Centers for Disease Control and Prevention. Diagnostic standards and classification of tuberculosis in adults and children. *Am J Respir Crit Care Med* 2002;161:1376-95.
4. Anderson C, Inhaber N, Menzies D. Comparison of sputum induction with fiber-optic bronchoscopy in the diagnosis of tuberculosis. *Am J Respir Crit Care Med* 1995;152(5 Pt 1):1570-4.

5. Iredale MJ, Wanklyn SA, Phillips IP, Krausz T, Ind PW. Non-invasive assessment of bronchial inflammation in asthma: No correlation between eosinophilia of induced sputum and bronchial responsiveness to inhaled hypertonic saline. *Clin Exp Allergy* 1994;24:940-5.
6. Hong Kong Chest Service/Tuberculosis Research Centre, Madras/British Medical Research Council. A study of the characteristics and course of sputum smear-negative pulmonary tuberculosis. *Tubercle* 1981;62:155-67.
7. Toman K. What are the main causes of false-positive and false-negative sputum smears? In: Frieden T, editor. *Toman's Tuberculosis Case Detection, Treatment and Monitoring: Questions and Answers*. 2nd ed. Geneva: World Health Organization; 2004. p. 23-7.
8. Kalawat U, Sharma KK, Reddy PN, Kumar AG. Study of bronchoalveolar lavage in clinically and radiologically suspected cases of pulmonary tuberculosis. *Lung India* 2010;27:122-4.
9. Narain R, Nair SS, Naganna K, Chandrasekhar P, Rao GR, Lal P. Problems in defining a "case" of pulmonary tuberculosis in prevalence surveys. *Bull World Health Organ* 1968;39:701-29.
10. Mello FC, Bastos LG, Soares SL, Rezende VM, Conde MB, Chaisson RE, *et al.* Predicting smear negative pulmonary tuberculosis with classification trees and logistic regression: A cross-sectional study. *BMC Public Health* 2006;6:43.
11. Hensler NM, Spivey CG Jr., Dees TM. The use of hypertonic aerosol in production of sputum for diagnosis of tuberculosis. Comparison with gastric specimens. *Dis Chest* 1961;40:639-42.
12. Al Zahrani K, Al Jahdali H, Poirier L, René P, Menzies D. Yield of smear, culture and amplification tests from repeated sputum induction for the diagnosis of pulmonary tuberculosis. *Int J Tuberc Lung Dis* 2001;5:855-60.
13. Pavord ID, Pizzichini MM, Pizzichini E, Hargreave FE. The use of induced sputum to investigate airway inflammation. *Thorax* 1997;52:498-501.
14. LaRocque RC, Katz JT, Perruzzi P, Baden LR. The utility of sputum induction for diagnosis of *Pneumocystis pneumonia* in immunocompromised patients without human immunodeficiency virus. *Clin Infect Dis* 2003;37:1380-3.
15. Louis R, Lau LC, Bron AO, Roldaan AC, Radermecker M, Djukanovic R. The relationship between airways inflammation and asthma severity. *Am J Respir Crit Care Med* 2000;161:9-16.
16. Conde MB, Loivos AC, Rezende VM, Soares SL, Mello FC, Reingold AL, *et al.* Yield of sputum induction in the diagnosis of pleural tuberculosis. *Am J Respir Crit Care Med* 2003;167:723-5.
17. Olivieri D, D'Ippolito R, Chetta A. Induced sputum: Diagnostic value in interstitial lung disease. *Curr Opin Pulm Med* 2000;6:411-4.
18. Alonso Fernández A, García Río F, Mayoralas Alises S, Sánchez Fraga S, Mediano San Andrés O, Villamor León J. Usefulness of induced sputum cytology in the study of central masses in elderly patients. *Rev Clin Esp* 2001;201:444-7.
19. Saglam L, Akgun M, Aktas E. Usefulness of induced sputum and fibreoptic bronchoscopy specimens in the diagnosis of pulmonary tuberculosis. *J Int Med Res* 2005;33:260-5.
20. Hartung TK, Maulu A, Nash J, Fredlund VG. Suspected pulmonary tuberculosis in rural South Africa - Sputum induction as a simple diagnostic tool? *S Afr Med J* 2002;92:455-8.
21. McWilliams T, Wells AU, Harrison AC, Lindstrom S, Cameron RJ, Foskin E. Induced sputum and bronchoscopy in the diagnosis of pulmonary tuberculosis. *Thorax* 2002;57:1010-4.
22. Altaf Bachh A, Gupta R, Haq I, Varudkar HG. Diagnosing sputum/smear-negative pulmonary tuberculosis: Does fibre-optic bronchoscopy play a significant role? *Lung India* 2010;27:58-62.
23. Charoenratanakul S, Dejsomritrutai W, Chaiprasert A. Diagnostic role of fiberoptic bronchoscopy in suspected smear negative pulmonary tuberculosis. *Respir Med* 1995;89:621-3.
24. Fujii H, Ishihara J, Fukaura A, Kashima N, Tazawa H, Nakajima H, *et al.* Early diagnosis of tuberculosis by fibreoptic bronchoscopy. *Tuber Lung Dis* 1992;73:167-9.
25. Chawla R, Pant K, Jaggi OP, Chandrashekhar S, Thukral SS. Fibreoptic bronchoscopy in smear-negative pulmonary tuberculosis. *Eur Respir J* 1988;1:804-6.
26. de Gracia J, Curull V, Vidal R, Riba A, Orriols R, Martin N, *et al.* Diagnostic value of bronchoalveolar lavage in suspected pulmonary tuberculosis. *Chest* 1988;93:329-32.
27. Chan HS, Sun AJ, Hoheisel GB. Bronchoscopic aspiration and bronchoalveolar lavage in the diagnosis of sputum smear-negative pulmonary tuberculosis. *Lung* 1990;168:215-20.
28. Jain NK, Sharma TN, Madan A, Agrawal K, Koolwal S, Sarkar SK, *et al.* Lower lung field tuberculosis: An evaluation of bronchofiberscopy in bacteriological diagnosis. *Indian J Chest Dis Allied Sci* 1984;26:20-5.
29. Conde MB, Soares SL, Mello FC, Rezende VM, Almeida LL, Reingold AL, *et al.* Comparison of sputum induction with fiberoptic bronchoscopy in the diagnosis of tuberculosis: Experience at an acquired immune deficiency syndrome reference center in Rio de Janeiro, Brazil. *Am J Respir Crit Care Med* 2000;162:2238-40.
30. Mohan A, Sharma SK. Fibreoptic bronchoscopy in the diagnosis of sputum smear-negative pulmonary tuberculosis: Current status. *Indian J Chest Dis Allied Sci* 2008;50:67-78.