



Intracranial Venous Sinus Reflux on CT Angiography: Benign or Malignant Entity?

Raghav Seth¹ Vikas Bhatia¹ Chirag Jain¹ Ajay Kumar¹

¹Department of Radio-diagnosis and Imaging, PGIMER, Chandigarh, India

Address for correspondence Vikas Bhatia, DM, Neuroradiology Section, Department of Radio-diagnosis and Imaging, PGIMER, Chandigarh 160012, India (e-mail: drvikasbhatia@gmail.com).

Indian J Radiol Imaging 2021;31:1075–1078.

A 55-year-old female patient presented to our hospital with loss of sensorium and right-sided weakness for 5 days. Non-contrast computed tomography (NCCT) revealed left middle cerebral artery (MCA) territory infarct. For confirmation of vascular occlusion, further management, and prognostication, computed tomography angiography (CTA) was performed on 64-detector CT scanner (LightSpeed volume CT [VCT]; GE Healthcare, Milwaukee, Wisconsin, United States) with an axial thickness of 0.625 mm, 120 kVp, and 299 mA, according to the following protocol.

Patient was asked to lie in supine position with arms by her side and a scout was acquired from mid chest to vertex. Seventy-five milliliter of intravenous nonionic iodinated contrast (OMNIPAQUE [iohexol]) containing 300 mg of iodine per milliliter was injected into left antecubital vein with a 100 mL saline chaser at 5 mL/s.

Descending aorta was chosen as the monitoring slice (region of interest) and threshold value was set at 100HU. The scan was acquired from aortic arch to vertex in caudocranial direction in arterial phase (6 seconds) for head and neck and venous phase (15 seconds) for head with saline chase and bolus-tracking technique. CTA confirmed occlusion of left internal carotid artery (ICA) and M1 segment of left MCA with partial reformation of cortical branches. A peculiar finding in the form of opacification of bilateral internal jugular veins (IJV) and transverse sinuses including superior sagittal sinus was seen (► **Fig. 1**). Left-side injection resulted in opacification of left cephalic, basilic and paired brachial veins forming the axillary and subclavian veins. Some opacification of left external jugular vein was seen. Bilateral brachiocephalic veins and superior vena cava were normal in caliber. No reflux was noted into the veins of chest and back (► **Fig. 2**).

CTA is advantageous for its rapid speed of acquisition and has been employed in the diagnosis of arterial obstructions (atherosclerotic plaques, thrombo-emboli), aneurysms, congenital abnormalities and vascular malformations, and arterial dissections. Multiphase images may be acquired using CTA based on the vessel of interest. However, CTA is prone to artifacts that may degrade image quality. Concomitant venous opacification during the early phase of CTA may interfere with detailed visualization of arterial structures. The reduction of this venous artifact is achieved by a saline flush that clears the vein of contrast toward the heart. Rarely, caudo-cephalad blood flow leading to high attenuation in the intracranial veins may be seen. However, the reflux of contrast till the level of dural venous sinuses has been shown only in few studies. It is important to not confuse this retrograde venous reflux with more sinister pathologies, such as a dural arteriovenous fistula.

Associated venous enhancement in arterial phase leads to streak artifacts, distorting the quality of generated images. This may lead to incorrect diagnoses like thrombosis and even dissection of adjacent arteries.¹

Studies have shown that venous reflux may occur till the level of neck veins (brachiocephalic or internal jugular veins) in CTA.^{1–3} Common causes for venous reflux are severe heart failure, stenosis in the brachiocephalic vein, absence of valves or valvular insufficiency in IJV, superior vena cava syndrome, and mediastinal masses.^{4–7} If the scan is acquired in expiratory phase, it can also lead to increased venous reflux due to increased positive thoracic pressure during expiration. A study conducted by Tseng et al³ showed that venous reflux occurred more commonly with intravenous contrast injection in left side arm veins in comparison to right side. Another similar study by Demirpolat et al¹ also showed

published online
January 10, 2022

DOI <https://doi.org/10.1055/s-0041-1741097>.
ISSN 0971-3026.

© 2022. Indian Radiological Association. All rights reserved.
This is an open access article published by Thieme under the terms of the Creative Commons Attribution-NonDerivative-NonCommercial-License, permitting copying and reproduction so long as the original work is given appropriate credit. Contents may not be used for commercial purposes, or adapted, remixed, transformed or built upon. (<https://creativecommons.org/licenses/by-nc-nd/4.0/>)
Thieme Medical and Scientific Publishers Pvt. Ltd., A-12, 2nd Floor, Sector 2, Noida-201301 UP, India

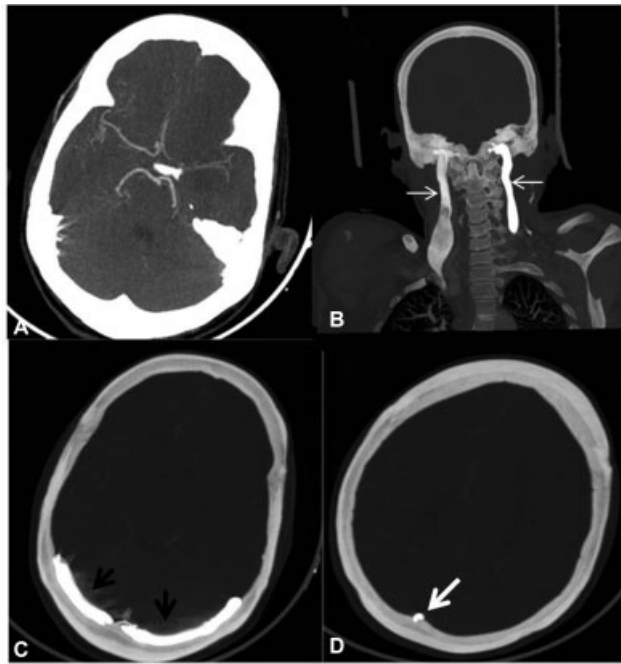

Fig. 1 (A) Axial computed tomography (CT) angiography source images show normal opacification of circle of Willis in arterial phase. (B) Coronal CT images with wide window setting show opacification of bilateral jugular veins (white thin arrows) due to reflux. (C) Axial CT image with wide window setting shows reflux into bilateral transverse sinuses (black arrows). (D) Axial CT image with wide window setting shows reflux into posterior part of superior sagittal sinus.

that the reflux of contrast into neck veins is more common if left arm injection is used. Both the studies conclude that a developmentally decreased retrosternal distance on left side is the cause of this phenomenon as the left brachiocephalic vein is more transverse in course, and delivers a higher amount of undiluted contrast material obscuring the origins of the great vessels. Also, compression of left brachiocephalic vein by aorta can cause reflux into neck veins. In our case, the cause of reflux was likely due to contrast injection from the left arm. However, presence of underlying venous insufficiency or valvular incompetence may be there.

Thoracic breathing and postural change can narrow the space of left brachiocephalic vein and may result in reflux in neck vessels from left side injection. In our case, there was no obvious movement or coughing of the patient during acquisition.

Yen et al⁸ observed jugular venous reflux in six cerebral radionuclide angiograms. In one case, the reflux was likely related to the arm position; but in the other five cases, the cause was unknown.

The reflux of contrast till the level of dural venous sinuses is a rare phenomenon and on reviewing previous literature, we found only one case report by Chen et al.⁹ Similar finding by using magnetic resonance angiography (MRA) was reported by Paksoy et al⁷ who attributed reflux to brachiocephalic venous stenosis.

Venous reflux, when present especially in the inferior dural sinuses, can be a diagnostic dilemma and confused

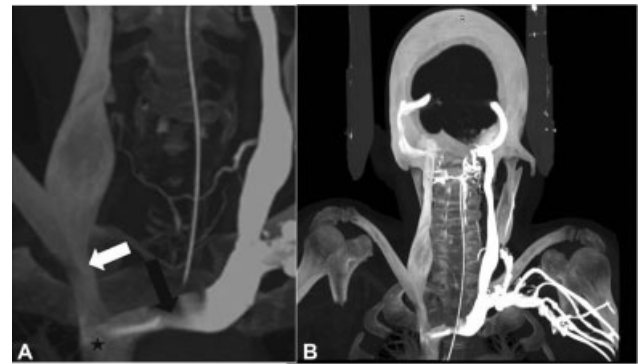


Fig. 2 (A) Coronal maximum intensity projection (MIP) image showing the left (black arrow) and right brachiocephalic veins joining to enter the superior vena cava (star). (B) Coronal MIP image shows contrast injection from left side opacifying the cephalic, basilic, and paired brachial veins forming the left axillary and subclavian vein. No obvious stenosis is seen. Some reflux is seen in the left external jugular vein. No reflux into chest or back veins.

with dural arteriovenous fistulas, which are common in this region along the tentorium. Radionuclide venography or dynamic examination may be performed to differentiate the two. Kim et al¹⁰ speculated that early opacification of the cavernous sinus in the arterial phase of contrast-enhanced (CE)-MRA, ipsilateral jugular venous drainage in the arteriovenous phase of CE-MRA, and ipsilateral retrograde jugular venous flow on neck time-of-flight (TOF)-MRA could differentiate the two findings.

With this report, we establish a key finding of intracranial venous reflux that may be seen in otherwise normal patients who undergo a CTA examination of the head and neck.

Financial Support and Sponsorship
Nil.

Conflicts of Interest
There are no conflicts of interest.

References

- Demirpolat G, Yüksel M, Kavukçu G, Tuncel D. Carotid CT angiography: comparison of image quality for left versus right arm injections. *Diagn Interv Radiol* 2011;17(03):195–198
- Kim JJ, Dillon WP, Glastonbury CM, Provenzale JM, Wintermark M. Sixty-four-section multidetector CT angiography of carotid arteries: a systematic analysis of image quality and artifacts. *AJNR Am J Neuroradiol* 2010;31(01):91–99
- Tseng Y-C, Hsu H-L, Lee T-H, Chen C-J. Venous reflux on carotid computed tomography angiography: relationship with left-arm injection. *J Comput Assist Tomogr* 2007;31(03):360–364
- Friedman BH, Lovegrove FT, Wagner HN Jr. An unusual variant in cerebral circulation studies. *J Nucl Med* 1974;15(05):363–364
- Bok B, Marsault C, Aubin ML, Bar D, Aboulker J. Jugular venous reflux in cerebral radionuclide angiography: an explanation. *Eur J Nucl Med* 1978;3(01):63–65
- Tanaka T, Uemura K, Takahashi M, et al. Compression of the left brachiocephalic vein: cause of high signal intensity of the left sigmoid sinus and internal jugular vein on MR images. *Radiology* 1993;188(02):355–361

- 7 Paksoy Y, Genç BO, Genç E Retrograde flow in the left inferior petrosal sinus and blood steal of the cavernous sinus associated with central vein stenosis: MR angiographic findings. *AJNR Am J Neuroradiol* 2003;24(07):1364–1368
- 8 Yeh EL, Pohlman GP, Ruetz PP, Meade RC. Jugular venous reflux in cerebral radionuclide angiography. *Radiology* 1976;118(03):730–732
- 9 Chen JY, Mamourian AC, Messe SR, Wolf RL. Pseudopathologic brain parenchymal enhancement due to venous reflux from left-sided injection and brachiocephalic vein narrowing. *AJNR Am J Neuroradiol* 2010;31(01):86–87
- 10 Kim E, Kim JH, Choi BS, Jung C, Lee DH. MRI and MR angiography findings to differentiate jugular venous reflux from cavernous dural arteriovenous fistula. *AJR Am J Roentgenol* 2014;202(04):839–846