

# Fungal Malignant Otitis Externa Involves a Cascade of Complications Culminating in Pseudoaneurysm of Internal Maxillary Artery: A Case Report

Authors' Contribution:  
Study Design A  
Data Collection B  
Statistical Analysis C  
Data Interpretation D  
Manuscript Preparation E  
Literature Search F  
Funds Collection G

DEF **Haseeb Ahmad Chaudhary**  
DEF **Wanis H. Ibrahim**  
EF **Zohaib Yousaf**  
F **Ibrahim Yusuf Abubeker**  
E **Anand Kartha**

Department of Medicine, Hamad General Hospital, Hamad Medical Corporation, Doha, Qatar

**Corresponding Author:** Haseeb Ahmad Chaudhary, e-mail: [hchaudhary@hamad.qa](mailto:hchaudhary@hamad.qa)  
**Conflict of interest:** None declared

**Patient:** Male, 66  
**Final Diagnosis:** Pseudoaneurysm of internal maxillary artery secondary to fungal malignant otitis externa  
**Symptoms:** Epistaxis  
**Medication:** —  
**Clinical Procedure:** Functional endoscopic sinus surgery, endovascular embolization  
**Specialty:** Infectious Diseases

**Objective:** Unusual clinical course  
**Background:** Pseudomonas infection is the most common cause of malignant otitis externa (MOE), which typically affects elderly diabetic patients. Fungi are a rare cause of MOE. MOE can be life-threatening if not recognized and treated promptly. It can result in a wide spectrum of complications, including skull-base osteomyelitis, cranial nerve palsy, cerebral venous thrombosis, and brain abscess. Pseudoaneurysm formation of the intracranial vessels is a life-threatening complication of MOE that is seldom reported in the literature.

**Case Report:** We report the case of a 66-year-old diabetic man with MOE who was initially treated with antipseudomonas antibiotics after negative initial culture results. His MOE resulted in a cascade of complications, including facial nerve palsy, skull base osteomyelitis, and sigmoid sinus thrombosis, and culminated in left maxillary artery pseudoaneurysm formation resulting in massive epistaxis and hemodynamic instability. Endovascular embolization resulted in a successful obliteration of the pseudoaneurysm. A subsequent functional endoscopic sinus surgical (FESS) tissue biopsy confirmed *Candida glabrata* as the etiological agent. The patient was successfully treated with antibiotics and antifungal and anticoagulation therapy, and was discharged home in good condition.

**Conclusions:** A high index of suspicion for the diagnosis of fungal MOE, particularly in intractable cases of MOE with negative initial cultures, should be maintained. Pseudoaneurysm formation is a life-threatening complication of MOE that is seldom reported in the literature and should be suspected in any patient with MOE who presents with epistaxis or intracranial bleeding.

**MeSH Keywords:** Aneurysm, False • *Candida Glabrata* • Otitis Externa

Full-text PDF: <https://www.amjcaserep.com/abstract/index/idArt/913469>

1942 — 2 28



## Background

Malignant otitis externa (MOE), also called necrotizing otitis externa, is a serious infection of the external ear and temporal bone. Elderly patients with diabetes are typically affected by the disease. *Pseudomonas aeruginosa* (PSA) is the causative pathogen in 50% to 90% of the patients. Less frequently, other microorganisms may be isolated, especially in non-diabetic patients. Staphylococci, Streptococci, and gram-negative bacilli (e.g., *Klebsiella* spp.) are the etiologic agents in 5% to 20% of cases. Fungi cause MOE in 5% to 20% of these patients [1–4]. The infection begins as an external otitis that progresses into osteomyelitis of the temporal bone. Although the first reported case of MOE in the literature is in 1838 [5], it was only in 1968 that the disease was recognized as a distinct clinical entity and a detailed description of its clinical characteristics emerged [6]. Besides long-standing diabetes, other risk factors include congenital or acquired immune-deficiencies including from prolonged steroid use, malignancies, and chronic renal failure [7]. The presence of certain factors can predict poor outcome in MOE. These factors include long-standing diabetes, development of facial nerve palsy, age above 70 years, and positive computerized tomographic (CT) scan findings of tissue destruction and skull-base osteomyelitis [8]. Because many of the initial presenting symptoms of MOE are also observed in simple forms of otitis externa (e.g., ear pain, discharge, and fullness), a high index of clinical suspicion is required to diagnose MOE, as the outcome can be fatal. MOE is of concern secondary to its proximity to structures in the petrous bone and base of the skull. Complications include mastoiditis, skull-base osteomyelitis, cranial nerve involvement, cerebral venous sinus thrombosis, and brain abscess. Formation of pseudoaneurysms of intracranial arteries is a life-threatening complication of MOE that is seldom reported in the literature. We report a case of MOE initially treated with antipseudomonal antibiotics empirically after obtaining negative initial culture results. His MOE resulted in a cascade of complications culminating in massive epistaxis secondary to an internal maxillary artery pseudoaneurysm. Subsequently, a tissue biopsy obtained under functional endoscopic sinus surgery (FESS) confirmed *Candida glabrata* as the etiologic agent. Multidisciplinary management resulted in successful treatment of the patient's condition, and he was discharged from hospital in good condition.

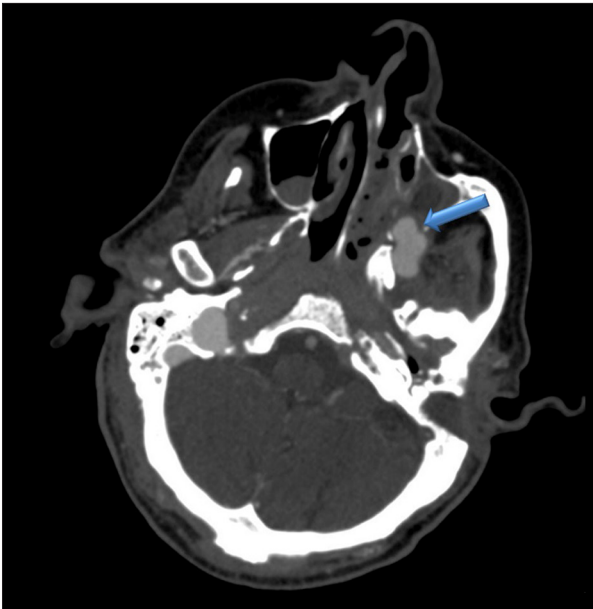
## Case Report

A 66-year-old man with diabetes mellitus presented to the Emergency Department (ED) at Hamad General Hospital with sudden massive epistaxis. Four months prior to this presentation, he was admitted to the hospital with left MOE following presentation with otalgia and ear discharge complicated by mastoiditis and left parotid abscess revealed by the CT scan

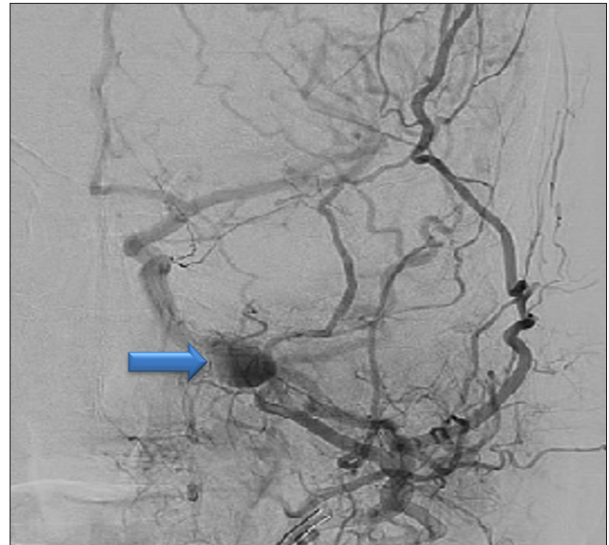
of the head. Initial biopsy from the granulation tissue in the left middle ear showed chronic inflammatory process but revealed no bacteria or fungi. Treatment commenced with intravenous piperacillin/tazobactam for two weeks followed by oral ciprofloxacin for four weeks, with strict diabetes control. Unfortunately, the patient was lost to follow-up after hospital discharge. He developed a sigmoid sinus thrombosis and secondary seizures. Warfarin and levetiracetam were started and courses of antipseudomonal antibiotics were administered. His past medical history was also significant for poorly controlled, insulin-treated type 2 diabetes with an HbA1c of 9.8%, complicated by peripheral vascular disease and left leg above-knee amputation. On this presentation to our Emergency Department, he was drowsy and hypotensive with a blood pressure 80/55mmhg and a pulse rate of 120 beats per minute. He denied having nasal discharge or fever prior to this incident. There was no history of associated hemoptysis, hematemesis, or bleeding from any other site. Systemic examination was unremarkable. Initial laboratory tests showed a white cell count of  $21 \times 10^3/\mu\text{L}$ , hemoglobin of 8.6 g/dl, platelets of  $470 \times 10^3/\mu\text{L}$ , and normal clotting profile with an INR of 1.3, with a questionable adherence to warfarin. Alkaline phosphatase was elevated (330 U/L). His kidney function and electrolytes were within normal ranges. Contrast-enhanced computerized tomography (CT) of the head revealed opacification of the left mastoid air cells and the lower and middle ear, with features of osteomyelitis involving the left petrous bone, mastoid process, and occipital condyle. Imaging also showed previous thrombosis involving the distal left sigmoid sinus and internal jugular vein and opacification of the left maxillary sinus with the possibility of pseudoaneurysm formation in the left maxillary artery (Figure 1). An urgent conventional angiography of the brain confirmed a large pseudoaneurysm, measuring  $2 \times 1.5$  cm, related to the terminal course of the left internal maxillary artery (Figure 2). After initial resuscitation with fluids and blood, emergency endovascular catheter embolization of left maxillary artery pseudoaneurysm was performed using a histoacrylate/lipiodol mixture, with successful total occlusion of the pseudo-aneurysm and control of bleeding. A functional endoscopic sinus surgery (FESS) with biopsy was performed, which showed profuse growth of *Candida glabrata* from the tissue biopsy. Anticoagulation was initiated with warfarin after controlling the bleeding. Intravenous piperacillin/tazobactam and amphotericin B treatment was started, which was later switched to caspofungin, based on final antimicrobial sensitivity results, with additional empiric coverage for *Pseudomonas aeruginosa* (PSA) with oral levofloxacin for a total duration of three months.

## Discussion

Fungi are rare causes of necrotizing or malignant otitis externa (MOE). *Aspergillus* spp. and *Candida albicans* are the most



**Figure 1.** CT head showing left maxillary sinus with lateral wall of erosion and hyperdense lesion along one of the branches of the maxillary artery, representing a pseudoaneurysm.



**Figure 2.** Conventional angiogram revealing a large (2×1.5 cm) pseudoaneurysm related to the terminal left internal maxillary artery.

commonly implicated fungi. *C. glabrata*, *C. parapsilosis*, and *C. ciferrii* have also been reported [9–12]. The exact pathophysiology of fungal MOE is not well understood. In addition to long-standing diabetes and immunodeficiency states, prolonged antibiotic treatment in patients with primary bacterial MOE is an important risk factor for fungal superinfection [12,13]. Use of topical antibiotics has also been linked to the development of secondary otomycosis [14]. The diagnosis of fungal MOE can be very challenging and requires a high index of suspicion, particularly in patients who continue to progress despite the initial treatment of bacterial MOE [13]. It may result in directing the initial empiric antimicrobial against the most common causative micro-organism, which is *Pseudomonas aeruginosa* (PSA), without considering fungal pathogens. It is noteworthy that PSA is also the normal flora of the external auditory canal, so initially positive microbiologic studies may be misleading and can delay the diagnosis of a fungal entity [4,15]. For the diagnosis of MOE, samples of discharge from the auditory canal are usually sent for microbiology examination and culture, and tissue biopsies of granulation tissue from the auditory canal or the skull base can be examined, as was done in our patient [4]. Fungal MOE tends to be more invasive than its bacterial counterpart and subsequently results in numerous complications, although survival is the same in both [16]. The therapy of MOE has evolved tremendously over the last two decades. Toxic antibiotics and morbid surgeries have largely been replaced with well-tolerated oral antibiotics, associated with a 90–100% success rate [13,17]. The introduction of newer, more effective, and safer antibiotics have

changed the indication of surgical debridement from the former first-line treatment to very limited cases that develop bony sequestra or abscesses, which our patient also lacked [13]. The current standard of care for the treatment of MOE is six weeks or more of culture-directed antibiotic therapy. Our case demonstrated a negative initial culture of granulation tissue, which resulted in empiric treatment with piperacillin/tazobactam for two weeks, followed by oral ciprofloxacin, to complete a total of six weeks. High rates of culture-negative specimens in MOE are not uncommon and have been reported from other parts of the world [4]. The 6-week duration is based on the three or four weeks that bone takes to revascularize. Most recent case series mention using combination therapy with two antipseudomonal agents, such as ciprofloxacin and ceftazidime [13,18,19]. Hyperbaric oxygen has also been suggested as a promising adjunct therapy. In a recent report from Tunisia, patients with MOE who were treated with hyperbaric oxygen in addition to antimicrobials demonstrated a higher rate and speed of recovery than those treated with antimicrobials alone [20]. Early initiation of therapy for MOE is paramount to prevent cranial nerve involvement and improve prognosis. Our patient exhibited a lack of response to several courses of antibiotic therapy, which can be attributed to *Candida* being the infectious agent [4,13], although compliance with medication is an aspect that remains questionable. Other conditions that are met with such a response are the presence of more aggressive or multi-resistant organisms, a broader spectrum of bacterial pathogens, and the presence of multiple co-morbidities. Interestingly, our patient had had uncontrolled diabetes mellitus. Recent reports suggest that initiation of empiric antifungal drugs be used for patients who are unresponsive to antibacterial therapy or who relapse after treatment, which is

particularly important in patients who show negative cultures from ear swabs or granulation tissue biopsies [4]. Unfortunately, our patient was lost to follow-up for a significant period after his initial therapy, and presented four months later with several complications. The tissue culture from his left maxillary sinus confirmed *C. glabrata* as the etiologic agent. Although clinical guidelines and recommendations are lacking, the important principles of fungal MOE treatment include aggressive control of diabetes, improvement of immunocompetency when possible, and prolonged administration of adequate doses of antifungal agents. Nevertheless, the optimum duration of therapy remains unknown. Amphotericin B and itraconazole were the favored antifungal drugs for the treatment of fungal MOE in the earlier case reports. However, we treated the patient initially with intravenous amphotericin B and later switched to caspofungin based on our local guidelines, with a prolonged course over three months, which our patient successfully completed.

A severe and life-threatening complication of MOE that is rarely reported in the literature is the formation of pseudoaneurysms of the intracranial arteries. Pseudoaneurysm of an artery can occur due to infection or other causes and is defined as the formation of a saccular lumen within the arterial wall that is contiguous with the lumen of the artery [23,24]. The prevalence of cerebral artery aneurysms due to infection has been reported to represent between 0.7–4% of all cerebral aneurysms [23,25,26]. The mechanisms by which the infection reaches the arterial lumen can be hematogenous seeding or direct invasion of the adventitia of the artery from surrounding infection [27]. Non-treatment or delayed treatment of infected aneurysms often leads to fulminant sepsis, spontaneous arterial rupture, and death. Earlier detection of infected aneurysms is therefore critical for timely treatment to optimize patient

outcome [23,24]. Current state-of-the-art imaging modalities, such as multi-detector CT (MDCT) and magnetic resonance imaging (MRI), have now replaced conventional angiography techniques in the detection of aneurysms that are diagnosed clinically as being due to infection and can assist in the planning of treatment in confirmed cases [23]. In addition to the use of effective long-term antibiotic therapy, there are other modalities of interventions that may be required for aneurysms that are enlarging, ruptured, or have diminished flow. Such interventions include surgical resection and primary anastomosis, balloon occlusion, endovascular embolization/coiling, or stent placement [27]. Our case was successfully managed with endovascular embolization, with complete obliteration of the pseudoaneurysm, without any further episodes of epistaxis, thus enabling the resumption of anticoagulation. To the best of our knowledge, the formation of pseudoaneurysms as a complication of MOE has seldom been reported in the literature. Furthermore, this case report emphasizes that fungal MOE should be a diagnostic consideration in patients with MOE who are unresponsive to or relapse after antibiotic therapy. An empiric antifungal treatment may be justified in such cases [28].

## Conclusions

MOE is a serious condition that can lead to grave consequences. Pseudoaneurysm of the intracranial vessels is a life-threatening complication that is seldom reported in the literature. Lack of initial response of MOE to antibacterial drugs or progression despite the use of these drugs should raise the suspicion of a fungal etiology of MOE. The current guidelines are lacking in terms of antifungal of choice and optimum duration of treatment.

## References:

1. Hatch JL, Bauschard MJ, Nguyen SA et al: Malignant otitis externa outcomes: A study of the University HealthSystem Consortium Database. *Ann Otol Rhinol Laryngol*, 2018; 127(8): 514–20
2. Handzel O, Halperin D: Necrotizing (malignant) external otitis. *Am Fam Physician*, 2003; 68(2): 309–12
3. Ridder GJ, Breunig C, Kaminsky J, Pfeiffer J: Central skull base osteomyelitis: new insights and implications for diagnosis and treatment. *Eur Arch Otorhinolaryngol*, 2015; 272(5): 1269–76
4. Hasibi M, Ashtiani MK, Motassadi Zandani M et al: A treatment protocol for management of bacterial and fungal malignant external otitis: A large cohort in Tehran, Iran. *Ann Otol Rhinol Laryngol*, 2017; 126(7): 561–67
5. Toulmouche MA: Observations d'otorrhée cérébrale; suivis des réflexions. *Gaz Med Paris*, 1838; 6: 422–42 [in French]
6. Chandler JR: Malignant external otitis. *Laryngoscope*, 1968; 78(8): 1257–94
7. Karaman E, Yilmaz M, Ibrahimov M et al: Malignant otitis externa. *J Craniofac Surg*, 2012; 23(6): 1748–51
8. Stern Shavit S, Soudry E, Hamzany Y, Nageris B: Malignant external otitis: Factors predicting patient outcomes. *Am J Otolaryngol*, 2016; 37(5): 425–30
9. Bae WK, Lee KS, Park JW et al: A case of malignant otitis externa caused by *Candida glabrata* in a patient receiving haemodialysis. *Scand J Infect Dis*, 2007; 39(4): 370–72
10. Lancaster J, Alderson DJ, McCormick M: Non-pseudomonal malignant otitis externa and jugular foramen syndrome secondary to cyclosporin-induced hypertrichosis in a diabetic renal transplant patient. *J Laryngol Otol*, 2000; 114(5): 366–69
11. Guevara N, Mahdyoun P, Pulcini C et al: Initial management of necrotizing external otitis: Errors to avoid. *Eur Ann Otorhinolaryngol Head Neck Dis*, 2013; 130(3): 115–21
12. Rubin Grandis J, Branstetter BF 4<sup>th</sup>, Yu VL: The changing face of malignant (necrotizing) external otitis: Clinical, radiological, and anatomic correlations. *Lancet Infect Dis*, 2004; 4(1): 34–39
13. Carlton DA, Perez EE, Smouha EE: Malignant external otitis: The shifting treatment paradigm. *Am J Otolaryngol*, 2018; 39(1): 41–45
14. Jackman A, Ward R, April M, Bent J: Topical antibiotic induced otomycosis. *Int J Pediatr Otorhinolaryngol*, 2005; 69(6): 857–60
15. Bovo R, Benatti A, Ciorba A et al: *Pseudomonas* and *Aspergillus* interaction in malignant external otitis: Risk of treatment failure. *Acta Otorhinolaryngol Ital*, 2012; 32(6): 416–19
16. Hamzany Y, Soudry E, Preis M et al: Fungal malignant external otitis. *J Infect*, 2011; 62: 226–31

17. Lang R, Goshen S, Kitzes-Cohen R, Sadé J: Successful treatment of malignant external otitis with oral ciprofloxacin: report of experience with 23 patients. *J Infect Dis*, 1990; 161: 537–40
18. Courson AM, Vikram HR, Barrs DM: What are the criteria for terminating treatment for necrotizing (malignant) otitis externa? *Laryngoscope*, 2014; 124: 361–62
19. Mahdyoun P, Pulcini C, Gahide I et al: Necrotizing otitis externa: A systematic review. *Otol Neurotol*, 2013; 34: 620–29
20. Mardassi A, Turki S, Lahiani R et al: Is there a real benefit of hyperbaric oxygenotherapy in the treatment of necrotizing otitis externa? *Tunis Med*, 2016; 94(12): 863
21. Mion M, Bovo R, Marchese-Ragona R, Martini A: Outcome predictors of treatment effectiveness for fungal malignant external otitis: A systematic review. *Acta Otorhinolaryngol Ital*, 2015; 35(5): 307–13
22. Halsey C, Lumley H, Luckit J: Necrotising external otitis caused by *Aspergillus wentii*: A case report. *Mycoses*, 2011; 54: e211–13
23. Lee WK, Mossop PJ, Little AF et al: Infected (mycotic) aneurysms: Spectrum of imaging appearances and management. *Radiographics*, 2008; 28(7): 1853–68
24. Kaufman SL, White RI Jr, Harrington DP et al: Protean manifestations of mycotic aneurysms. *Am J Roentgenol*, 1978; 131(6): 1019–25
25. Frazee JG, Cahan LD, Winter J: Bacterial intracranial aneurysms. *J Neurosurg*, 1980; 53(5): 633–41
26. Chun JY, Smith W, Halbach VV et al: Current multimodality management of infectious intracranial aneurysms. *Neurosurgery*, 2001; 48(6): 1203–13
27. Shon AS, Berenson CS: *Pseudomonas aeruginosa* intrapetrous internal carotid artery mycotic aneurysm – a complication of mastoiditis: First reported case. *BMJ Case Rep*, 2013; 2013: pii: bcr2013200005
28. Bowles PF, Perkins V, Schechter E: Fungal malignant otitis externa. *BMJ Case Rep*, 2017; 2017: pii: bcr2016218420