

# The leaves of *Diospyros kaki* exert beneficial effects on a benzalkonium chloride–induced murine dry eye model

Kyung-A Kim,<sup>1,3</sup> Lee Chung Hyun,<sup>2</sup> Sang Hoon Jung,<sup>1,3</sup> Sung Jae Yang<sup>2</sup>

(The last two authors contributed equally to this study.)

<sup>1</sup>Natural Products Research Center, Korea Institute of Science and Technology (KIST), Gangneung, Korea; <sup>2</sup>Department of Ophthalmology, University of Ulsan, Gangneung Asan Hospital, Gangneung, Korea; <sup>3</sup>Department of Biological Chemistry, Korea University of Science and Technology (UST), Daejeon, Korea

**Purpose:** In this study, the beneficial effects of the oral administration of ethanol extract of *Diospyros kaki* (EEDK) were tested on a mouse dry eye model induced by benzalkonium chloride (BAC).

**Methods:** A solution of 0.2% BAC was administered topically to mouse eyes for 14 days, twice daily, to induce dry eye. Various concentrations of EEDK were administered daily by oral gavage for 14 days after BAC treatment. Preservative-free eye drops were instilled in the positive-control group. The tear secretion volume (Schirmer's test), tear break-up time (BUT), and fluorescein score were measured on the ocular surface. BAC-induced corneal damage was tested with hematoxylin-eosin staining. Moreover, apoptotic cell death in the corneal epithelial layer was investigated with terminal deoxynucleotidyl transferase-mediated dUTP nick-end labeling (TUNEL) staining. The protein expression level of interleukin-1 $\alpha$  (IL-1 $\alpha$ ), IL-1 $\beta$ , IL-6, tumor necrosis factor- $\alpha$  (TNF- $\alpha$ ), and monocyte chemoattractant protein-1 (MCP-1) was determined with western blot analysis. Furthermore, squamous metaplasia in the corneal epithelial layer was detected with immunofluorescent staining for cytokeratin-10. The cellular proliferation in the cornea was examined with immunohistochemical staining for Ki-67.

**Results:** EEDK treatment resulted in prolonged BUT, decreased fluorescein score, increased tear volume, and smoother epithelial cells compared with BAC treatment alone in the cornea. Moreover, EEDK treatment inhibited the inflammatory response and corneal epithelial cell death in a BAC-induced murine dry eye model, and changes in squamous cells were inhibited. Proliferative activity in the corneal epithelium cells was improved with EEDK.

**Conclusions:** EEDK could be a potential therapeutic agent in the clinical treatment of dry eye.

Dry eye is a common and multifactorial ocular surface disease that results in symptoms of ocular discomfort, visual disturbance, and tear film instability with potential damage to the ocular surface [1]. Patients often complain of dryness, redness, burning, and a foreign body sensation. In more severe cases, patients suffer from dry eye–related ocular complications, including corneal epithelium damage, squamous metaplasia, and neovascularization [2,3]. Although the definitive mechanism of dry eye has not been entirely clarified, ocular surface inflammation may have a prominent role in the pathogenesis of dry eye [4–8]. Tear secretory gland dysfunction results in changes in tear composition, which stimulates production of inflammatory mediators on the ocular surface [9].

Most ophthalmic solutions contain a preservative to protect the ingredients and prevent bacterial contamination

after the bottle is opened. Benzalkonium chloride (BAC), an antimicrobial agent, is the most widely used preservative agent in ophthalmic solutions today [10]. BAC's effect is largely due to its detergent properties, which destroy bacterial walls, membranes, and cytoplasmic layers.

However, long-term use of BAC-containing ophthalmic solution for glaucoma has been shown to cause dry eye diseases [11]. In vitro experiments demonstrated that BAC induced apoptosis in conjunctival cells associated with inflammatory cytokines [12,13]. In vivo experiments reported that BAC causes the upregulation of inflammatory mediators and infiltration of inflammatory cells in the cornea [12–14].

*Diospyros kaki* has been cultivated throughout Eastern Asia for centuries and is traditionally used in herbal medicine for its beneficial properties, which include anti-atherosclerosis, anti-diabetes, anti-inflammatory, and anti-neurodegenerative effects [15–19]. *D. kaki* leaves contain an abundance of active constituents, including the most common groups of polyphenolic compounds, such as flavonoids, terpenoids, resins, polysaccharides, chlorophyll, carotene, and so on [20,21]. A previous study showed that certain flavonoids and

Correspondence to: Sung Jae Yang, Department of Ophthalmology, University of Ulsan, Gangneung Asan Hospital #415, Bangdong-ri, Sacheon-myeon, Gangneung-si, Gangwon-do, Korea 210-711; Phone: +82-33-610-3943; FAX: +82-33-610-4960; email: d001065@naver.com

terpenoids inhibit inflammatory mediators, which could be beneficial in inflammatory disease's prevention and treatment [22]. Recently, we reported that EEDK attenuates corneal neovascularization induced by alkali burn in vivo [23]. Interestingly, it was also shown that EEDK was effective in ameliorating retinal degeneration in vitro and in vivo [24].

These results suggest that EEDK may be a potential candidate for the treatment of various ocular diseases. However, the beneficial effects of EEDK have not been assessed in a dry eye model. Therefore, the purpose of this study was to investigate the natural protective effects and possible mechanisms of EEDK in a BAC-induced mouse dry eye model.

## METHODS

**Animals:** Male BALB/c mice (6-weeks-old, 20–25 g; Central Lab. Animal Inc., Seoul, South Korea) were housed at 23±0.5 °C and 10% humidity in a 12 h:12 h light-dark cycle. All animals were acclimated at least 1 week, were caged, and were fed animal chow and water ad libitum.

All animal studies were performed in a pathogen-free barrier zone at the Korea Institute of Science and Technology (KIST) Gangneung Institute in accordance with the Association for Research and Vision in Ophthalmology (ARVO) Statement for the Use of Animals in Ophthalmic and Vision Research guidelines. Procedures used in this study were approved by the Animal Care and Use Committee of KIST (No. 2014–011).

**Plant materials:** In June 2013, *D. kaki* leaves were collected from Gangneung in the Gangwon province of South Korea. A voucher specimen (D-521) has been deposited at the KIST Gangneung Institute. Dried *D. kaki* leaves were extracted in 95% ethanol twice and concentrated to dryness with rotary evaporation to obtain ethanol extract of *D. kaki* (EEDK) [24]. For testing, EEDK was dissolved in distilled water.

**BAC-induced dry eye murine model:** BAC was used to induce dry eye in mice, as previously described [25-27]. Mice received 5 µl of 0.2% BAC (Sigma-Aldrich, St. Louis, MO) in sterile PBS (8 g/l, 0.2 g/l KCl, 1.44 g/l Na<sub>2</sub>HPO<sub>4</sub>, 0.24 g/l NaH<sub>2</sub>PO<sub>4</sub>, and pH 7.4) buffer, topically in the eyes, for 14 days, twice daily (10:00 AM and 10:00 PM). Control groups received an equal volume of physiologic saline.

**Experimental procedure:** Forty mice were randomly divided into five groups (n = 8 mice per group). 0.2% BAC was instilled alone in a dry eye (DE) groups. Various concentrations of EEDK (50 mg/kg or 10 mg/kg bodyweight) were administered daily by oral gavage for 14 days after BAC treatment. Control groups were administered an equal

volume of distilled water without EEDK. Preservative-free eye drops (Refresh Plus® lubricant eye drops, Allergan, CA) were instilled in the positive-control group, 4 times daily, for 14 days.

**Tear BUT and fluorescein staining:** Animals were anesthetized with an intraperitoneal injection of a mixture of 1.6 µg/g tiletamine hydrochloride/zolazepam hydrochloride (Zoletil; Virbac Laboratories, Fort Worth, TX) and 0.05 µl/g xylazine hydrochloride (Rompun, Newbury, UK).

To test the tear break-up time (BUT), 2% fluorescein was instilled on the conjunctival sac in anesthetized mice. Lids were closed manually three to four times; thereafter, with the eye held open, the BUT was recorded (in seconds). At the first appearance of dry spots, the stopwatch was stopped.

After the BUT score was recorded, corneal epithelial damage was graded using a blue filter under a slit-lamp microscope (Haag–Streit, Wedel, Germany). The cornea was divided into four quadrants, which were scored separately. Scores from these four regions were summed for a final grade (Total possible: 16 points). The stained area was graded using the 2007 Dry Eye Work Shop (DEWS)-recommended grading system, and grading was performed by two investigators in a blinded manner, as previously described [25] with essential modification, briefly, as follows: 0, absent; 1, slightly punctate staining with fewer than 30 spots; 2, punctate staining with more than 30 spots but not diffuse; 3, severe, diffuse staining but no positive plaque; 4, positive for fluorescein plaque.

**Measurement of tear volume:** The tear volume was measured using a phenol red cotton thread [12] at a similar time of day (9:00 AM) on days 0, 7, and 14. The lower eyelid was pulled down gently, and a 1 mm portion of thread was placed at a specified point approximately one third of the distance from the lateral can thus for 15 s. The red portion of the thread was measured in millimeters. Each eye was tested three times, and the average length of the red portion was used for statistical analysis. After the test, the eyes were closed to avoid excessive exposure and irritation due to the dryness of the ocular surface.

**Hematoxylin and eosin (H&E) staining:** Formalin-fixed eyes were embedded in paraffin and cut into 4 µm vertical slices. Sections were washed in distilled water for 5 min and treated with 0.1% hematoxylin buffer (Sigma-Aldrich) for 8 min at room temperature. Then, the sections were washed and dipped in 1% Eosin Y (Sigma-Aldrich) solution for 1 min. Slides were washed and mounted with mounting solution. Histological analyses of retinal tissues were evaluated under a light microscope (Olympus, Tokyo, Japan).

**Immunofluorescent and immunohistochemical staining:** Corneal sections were deparaffinized and incubated in serum blocking solution to block non-specific binding for 2 h at room temperature. Sections were incubated with primary antibodies, viz., anti-cytokeratin-10, or anti-Ki-67 (Abcam, Cambridge, UK), at 4 °C overnight.

**Immunofluorescent staining:** Sections were washed and incubated with a secondary antibody, anti-rabbit Alexa 488 (Invitrogen, Carlsbad, CA), for 2 h at room temperature in the dark. The sections were washed, then mounted with mounting solution, and covered with a glass coverslip. The fluorescence intensity of the staining was examined using a Leica TCS SP5 confocal system (Leica, Wetzlar, Germany). Appropriate fluorescence filters (Leica) were used: 4',6-diamidino-2-phenylindole (DAPI; ex 360/em 460) and Alexa Fluor 488 (ex 480/em 512).

**Immunochemical staining:** Sections were washed and incubated with a secondary antibody (Horseradish peroxidase [HRP]-conjugated goat anti-mouse immunoglobulin [IgG]; Santa Cruz Biotechnology, Santa Cruz, CA) for 2 h at room temperature in the dark by using the Vectastain Elite ABC kit (Vector Laboratories, Burlingame, CA). The reaction products were developed with diaminobenzidine (DAB, Vector Laboratories, Burlingame, CA), and then mounted with mounting medium. Counterstaining with hematoxylin (Vector Laboratories) was performed with Ki-67 staining. The stained sections were examined under a light microscope (Olympus).

**In situ TdT-mediated TUNEL staining:** We used an in situ terminal deoxynucleotidyl transferase (TdT)-mediated dUTP-biotin nick end-labeling (TUNEL) detection kit (Roche, Welwyn Garden, UK) to indicate apoptosis according to the manufacturer's instructions. TUNEL-positive cells in the cornea epithelial layer were observed using a Leica TCS SP5 confocal system (Leica). The quantification of nuclei with fragmented DNA was performed by calculating the percentage of TUNEL-positive cells from ten random fields for each condition.

**Western blot analysis:** Corneal and conjunctival tissues were surgically removed under anesthesia and washed with cold PBS. Tissues were centrifuged at 14,000 ×g at 4 °C for 10 min and then homogenized using a modular homogenizer (CAT Scientific, Paso Robles, CA) in RIPA buffer (150 mM NaCl, 1.0% IGEPAL CA-630, 0.5% sodium deoxycholate, 0.1% sodium dodecyl sulfate [SDS], 50 mM Tris, pH 8.0, 1× protease inhibitors, and 1 mM phenylmethylsulfonyl fluoride [PMSF]). Homogenates were centrifuged at 14,000 ×g for 20 min, and total protein concentrations were determined with the Bio-Rad Protein Assay kit (Bio-Rad Laboratories,

Hercules, CA). Protein concentrations were evaluated based on the standard curve using bovine serum albumin (BSA).

Proteins were electrophoresed on SDS-polyacrylamide gel electrophoresis (PAGE), electroblotted on a polyvinylidene difluoride (PVDF) membrane (Bio-Rad), and blocked for 1 h at room temperature. The following primary antibodies were incubated at 4 °C overnight: anti-IL-1 $\alpha$  (Biorbyt), anti-IL-1 $\beta$  (Abcam), anti-TNF- $\alpha$  (Abcam), anti-MCP-1 (Novus Biologicals), anti-IL-6 (Abcam), and anti- $\beta$ -actin (loading control; Santa Cruz Biotechnology). The membrane was washed and then incubated with HRP-conjugated goat anti-rabbit or anti-mouse IgG (Santa Cruz Biotechnology) for 2 h at room temperature. After washing, membranes were developed with enhanced chemiluminescent (ECL) solution (Chemiluminescent Substrate; Thermo Scientific, Rockford, IL) band densities were evaluated using Multi Gauge 3.1 software (Fuji Photo Film, Tokyo, Japan).

**Statistical analysis:** All data are presented as the mean  $\pm$  standard error of the mean (SEM). Statistical significance was assessed with a one-way ANOVA (ANOVA) followed by Dunnett's test for multiple group comparisons. A p value of less than 0.5 was considered statistically significant.

## RESULTS

**Stability of tear film and corneal epithelial damage:** We assessed the fluorescein staining score, BUT, and tear volume in BAC-induced corneal damage in mice (Figure 1). The corneal fluorescein staining scores in the control, positive control, and 50 mg/kg EEDK-treated groups were also significantly lower than for the DE group (Figure 1A,B). Similar results were obtained using the BUT. The mean BUT was lower in the DE group and 10 mg/kg EEDK-treated group at 14 days. However, the control, positive control, and 50 mg/kg EEDK-treated groups showed a higher BUT score than the DE group (Figure 1C). There was statistical significance in the BUT results, and the 50 mg/kg EEDK-treated group showed similar effects compared with the positive control.

Tear volume was measured on days 0, 7, and 14 with Schirmer's test (Figure 1D). On day 7, the mean tear volume was lower in the mice in the DE group. The mean tear volumes in the 50 mg/kg EEDK-treated group and the positive-control group were similar but lower than in the control group on day 7. On day 14, the mean tear volumes of the control, positive control, and 50 mg/kg EEDK-treated groups were greater than those of the DE and 10 mg/kg EEDK-treated groups.

Corneal damage was also assessed with H&E staining. There were irregular corneal epithelial cells in the basal layer in the DE and 10 mg/kg EEDK-treated groups (Figure 1E,

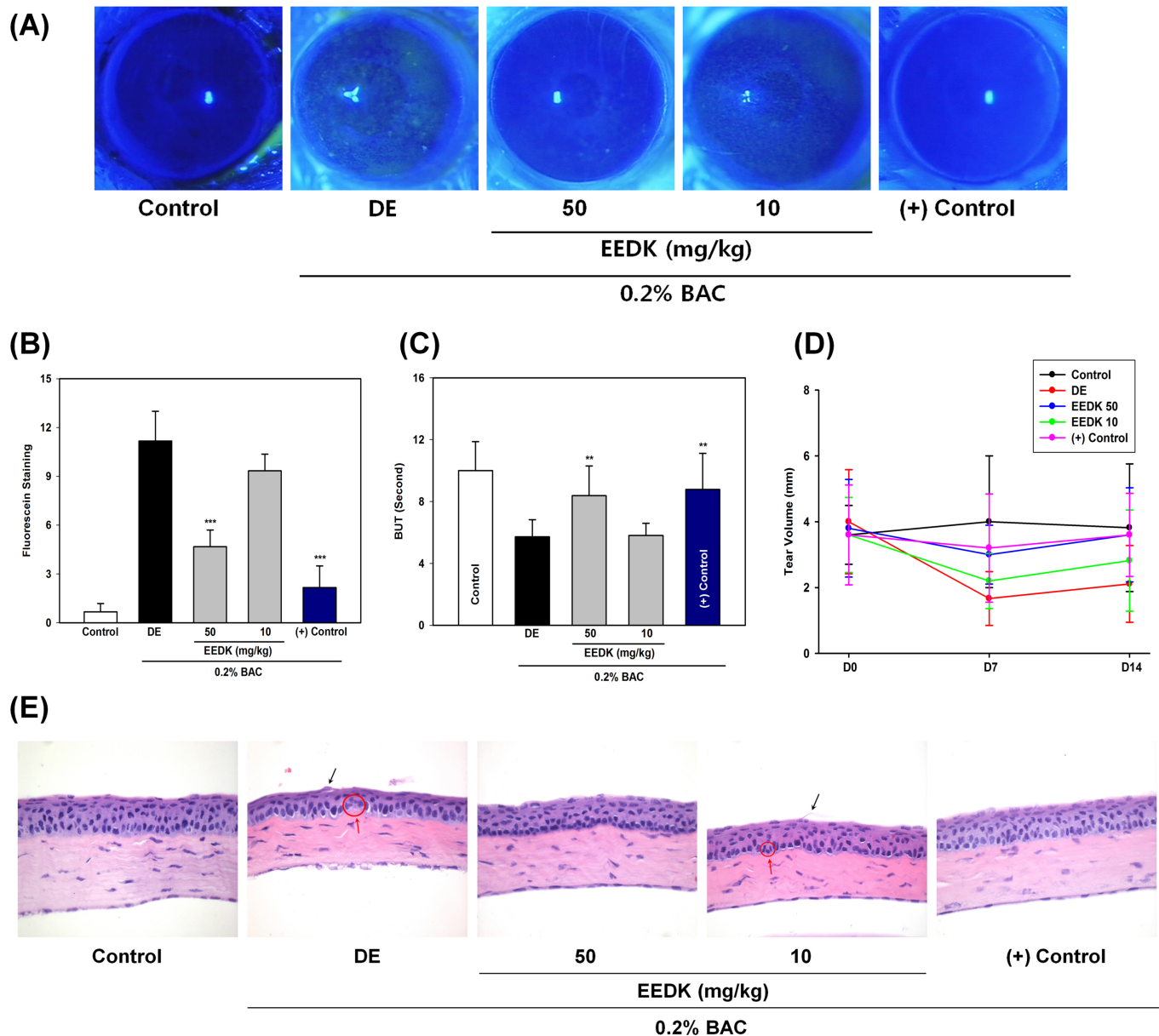


Figure 1. EEDK ameliorated dry eye severity. **A:** Corneal fluorescein staining. **B:** The fluorescein staining score. **C:** Tear break-up time (BUT). **D:** Tear volume with Schirmer's test. **E:** Hematoxylin and eosin (H&E) staining were assessed in all five groups. The treatment groups were administered 50 mg/kg ethanol extract of *Diospyros kaki* (EEDK), 10 mg/kg EEDK, or normal saline. Refresh Plus (preservative-free eye drops, Allergan) was used as the positive control. Original magnification = 400X, scale bars = 50  $\mu$ m. Experimental values are expressed as the mean  $\pm$  standard error of the mean (SEM) from three independent experiments (n = 8 mice per group, \*\*p<0.01, \*\*\*p<0.001).

red circle and arrows). Thinning of the epithelial layer and epithelial surface irregularity were also observed in the DE (Figure 1E-b) and 10 mg/kg EEDK-treated groups (Figure 1E-d). However, the 50 mg/kg EEDK-treated group and the positive-control group were protected against irregularity of the ocular surface and thinning of the epithelial layer. Taken together, these data demonstrated that EEDK ameliorated corneal damage in the BAC-induced dry eye model.

**Inflammation:** We used western blot to examine the expression of inflammatory cytokines in corneal and conjunctival lysates of mice. Notably, compared with the controls, the expressions of IL-1 $\alpha$ , IL-1 $\beta$ , TNF- $\alpha$ , MCP-1, and IL-6 were increased in the DE group (Figure 2). However, inflammatory cytokine expressions were significantly reduced in the 50 mg/kg EEDK-treated and positive-control groups (Figure 2). These results suggest that EEDK decreased the inflammatory



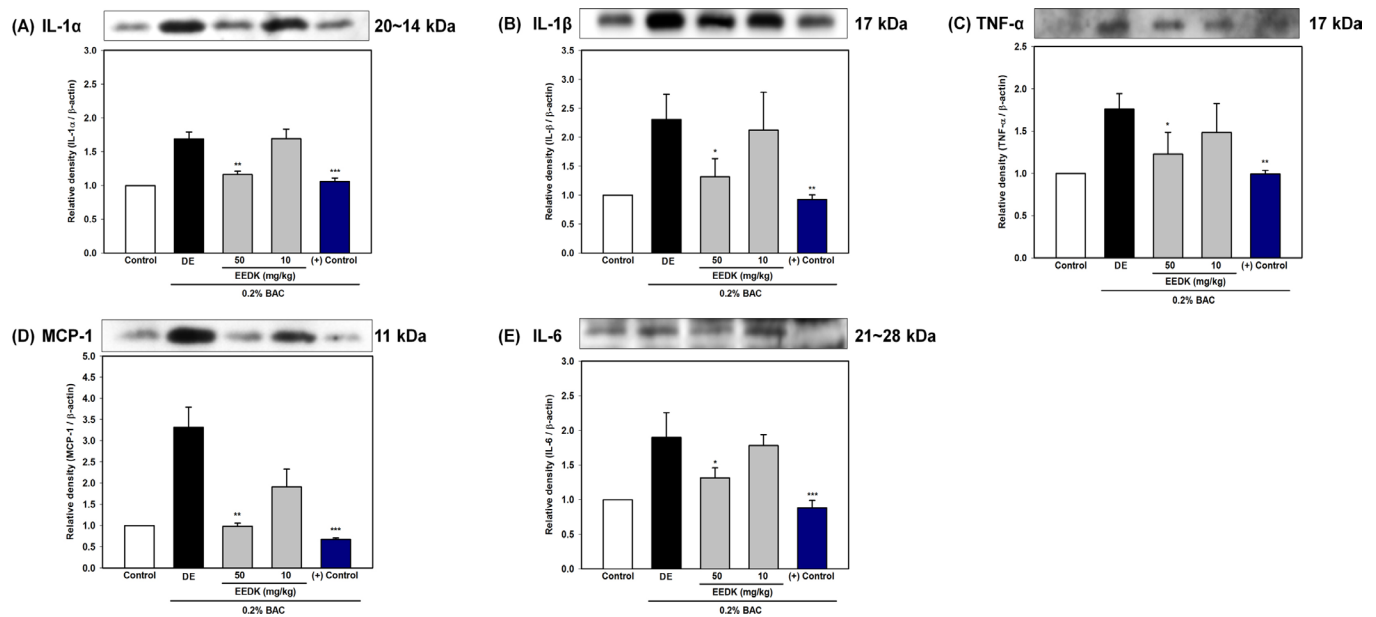


Figure 2. Anti-inflammatory effects of EEDK. The expression of inflammatory cytokines in total lysates from the cornea was assessed with western blot analysis, which detected the immunoreactivity of interleukin (IL)-1α, IL-1β, tumor necrosis factor-α (TNF-α), monocyte chemoattractant protein-1 (MCP-1), and IL-6 after treatment for 14 days. Quantification of relative protein levels, compared to β-actin (Loading control). Experimental values are expressed as the mean ± standard error of the mean (SEM) from three independent experiments (n = 8 mice per group, \*p<0.05, \*\*p<0.01, \*\*\*p<0.001).

reaction in the BAC-induced dry eye model, to the level of the positive-control group.

**Squamous metaplasia and apoptosis:** Inflammatory mediators lead to squamous metaplasia in which corneal epithelial cells are converted into keratinized cells. To evaluate squamous metaplasia, immunofluorescence staining with cytokeratin-10 (A squamous metaplasia marker) was performed. Expression of cytokeratin-10 was increased in the DE (Figure 3B) and 10 mg/kg EEDK-treated groups (Figure 3D), compared with the control group (Figure 3A). Expression of cytokeratin-10 in the 50 mg/kg EEDK-treated (Figure 3C) and positive-control groups (Figure 3E) was lower than that in the DE group.

Next, we asked whether EEDK might halt apoptosis in the cornea in the BAC-induced dry eye model. Supporting this hypothesis, we detected apoptotic cells with TUNEL assay, which stains the 3'-OH ends of fragmented DNA (Figure 4). The TUNEL assays revealed that the number of apoptotic cells was increased in the DE group compared with the control group (Figure 4A,B), whereas the 50 mg/kg EEDK-treated and positive-control groups had a reduced number of apoptotic cells in the corneal epithelium (Figure 4A,B).

**Proliferation of corneal epithelial cells:** Ki-67 is known to be present during active phases of the cell cycle (G1, S, G2, and

mitosis) but absent in resting cells (G<sub>0</sub>) [28]. We investigated the level of Ki-67 to determine the cellular proliferation in the corneal epithelium. Immunohistochemistry for Ki-67 revealed that few Ki-67-positive cells were detected in the control group (Figure 5A) and in the DE group (Figure 5B). However, the EEDK-treated group showed a higher number of Ki-67-positive cells (Figure 5C) in a dose-dependent manner. Ki-67-positive cells were found similarly in the positive-control group (Figure 5E) compared with the 50 mg/kg EEDK-treated group.

## DISCUSSION

Dry eye is a common ocular surface condition, which has various causes. Many experimental and clinical studies have shown that exposure to topical drugs, including preservatives, may cause ocular surface changes [26,29-31].

BAC is a well-known preservative. Although BAC has beneficial properties for ophthalmic solutions, long-term use of BAC decreases the density of the tear film and corneal cells, because the preservative has toxic and proinflammatory effects in humans [32,33]. Corneal cells are particularly sensitive to toxic and inflammatory stress, as they participate in regulating tear film stability [10]. We used a BAC-induced murine dry eye model that shares common pathologic features with human dry eye, such as epithelial apoptosis, tear

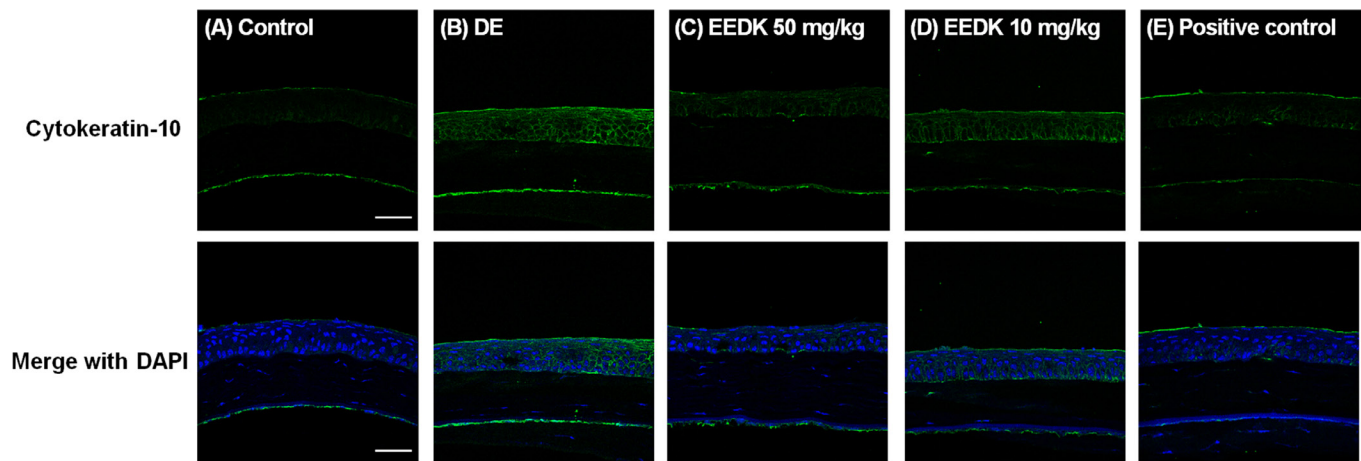


Figure 3. Anti-cytokeratin-10 immunohistochemistry. Representative immunostaining images of sections from the cornea stained with anti-cytokeratin-10 (Green). Nuclei were stained with 4',6-diamidino-2-phenylindole (DAPI), and sections were viewed under a confocal microscope (Original magnification: 630X). **A:** The control group. **B:** The dry eye (DE) group. **C:** The 50 mg/kg ethanol extract of *Diospyros kaki* (EEDK)-treated group. **D:** The 10 mg/kg EEDK-treated group. **E:** The positive-control group (Refresh Plus, preservative-free eye drops, Allergan). The results shown are representative of three independent experiments (n = 8 mice per group).

film defects, and inflammation, which were documented in previous studies [10,27]. We investigated whether the ethanol extract of *D. kaki* (EEDK) was able to protect the cornea in the BAC-induced murine dry eye model. In this study, we showed that the application of EEDK led to an improvement in clinical signs of dry eye and a decreased inflammatory response on the ocular surface of the BAC-induced dry eye model.

The fluorescein staining scores were significantly lower in the 50 mg/kg EEDK-treated group than in the 10 mg/kg EEDK-treated and DE groups (Figure 1A,B). Our results showed that the 50 mg/kg EEDK-treated group had a similar effect on dry eye compared to the positive control, which significantly inhibited corneal damage, with signs of increased BUT (Figure 1C), improved tear volume (Figure 1D), and protected epithelium (Figure 1E) in the cornea. These results support that EEDK contributed to corneal healing in the BAC-induced dry eye model.

Inflammatory cytokines are expressed at higher levels under dry eye conditions, and their overexpression is correlated with a higher rate of cell death [34]. Several proinflammatory cytokines can trigger downstream inflammatory pathways and result in recruitment of inflammatory cells [35]. Thus, inhibiting inflammation has been considered one of the key factors in the treatment of dry eye [36].

In a previous study, we showed that EEDK suppressed corneal neovascularization (CoNV) by inhibiting cytokines, such as vascular endothelial growth factor (VEGF), fibroblast growth factor (FGF), IL-6, and matrix metalloproteinase-2

(MMP-2) [23]. Our data revealed that treatment with 50 mg/kg EEDK inhibited upregulation of inflammatory cytokines, such as IL-1 $\alpha$ , IL-1 $\beta$ , TNF- $\alpha$ , MCP-1, and IL-6, in the cornea and conjunctiva compared with the DE group (Figure 2A).

Squamous metaplasia is a hallmark of various ocular surface disorders, including chronic dry eye [37]. The severity of dry eye and the degree of squamous metaplasia have been established in patients with dry eye conditions [38]. Proinflammatory cytokines are critical in the formation of squamous metaplasia [39]. Cytokeratin-10 expression in the corneal epithelial layer indicates that squamous metaplasia is present, in which epithelial cells are converted into keratinized cells in the cornea. In the DE group, cytokeratin-10 expression was upregulated compared to the control group (Figure 3B). However, less cytokeratin-10 expression was observed in the corneal epithelial layer in the 50 mg/kg EEDK-treated and positive-control groups (Figure 3C,E).

Inflammation also results in increased apoptosis, which has also been implicated in the pathogenesis of dry eye [40]. Furthermore, apoptotic cells have been detected in the cornea and conjunctiva of dry eye animal models [40,41]. We found that treatment with BAC alone resulted in apoptotic cell death in the cornea and stromal layers. However, few apoptotic cells were detected in the positive-control and 50 mg/kg EEDK-treated groups (Figure 3).

Topical instillation of BAC caused ocular surface changes (Figure 1E); it resulted in irregularity, instability, and cracks in the ocular surface (Figure 1E). For these reasons, the negative effects of BAC may include direct damage, such

as apoptosis in the endothelium and posterior stroma. A previous study also showed toxicity to the whole cornea in a dry eye murine model [12]. Together, these results suggest that upregulated inflammatory cytokines, upregulated squamous metaplasia, and increased numbers of apoptotic cells were inhibited by treatment with EEDK (Figure 2, Figure 3, Figure 4).

Based on the Ki-67 cell proliferative index, abnormal proliferation in the conjunctiva has been reported in patients with aqueous-deficient dry eye and Sjögren’s syndrome [28]. However, these results did not correlate with previous studies, in which epithelial cells showed decreased proliferative activity in dry eye conditions [12,28]. In the DE group,

few Ki-67 -positive cells were detected (Figure 5B) compared to the control group (Figure 5A), whereas several Ki-67 -positive cells were detected in the 50 mg/kg EEDK-treated (Figure 5C) and positive-control groups (Figure 5E).

Ki-67 and DNA content can be used to determine cell cycle status. Ki-67 protein is expressed during the G<sub>1</sub>, S, G<sub>2</sub>, and M phases of the cell cycle but not in the quiescent G<sub>0</sub> phase. Wu et al. showed that BAC induces DNA damage in human corneal epithelial cells [42], which ultimately leads to a decrease in DNA content and Ki-67 protein synthesis in corneal cells. However, flavonoids isolated from the leaves of *D. kaki* have been reported to alleviate oxidative stress-induced DNA damage and apoptosis [43]. Overall, these

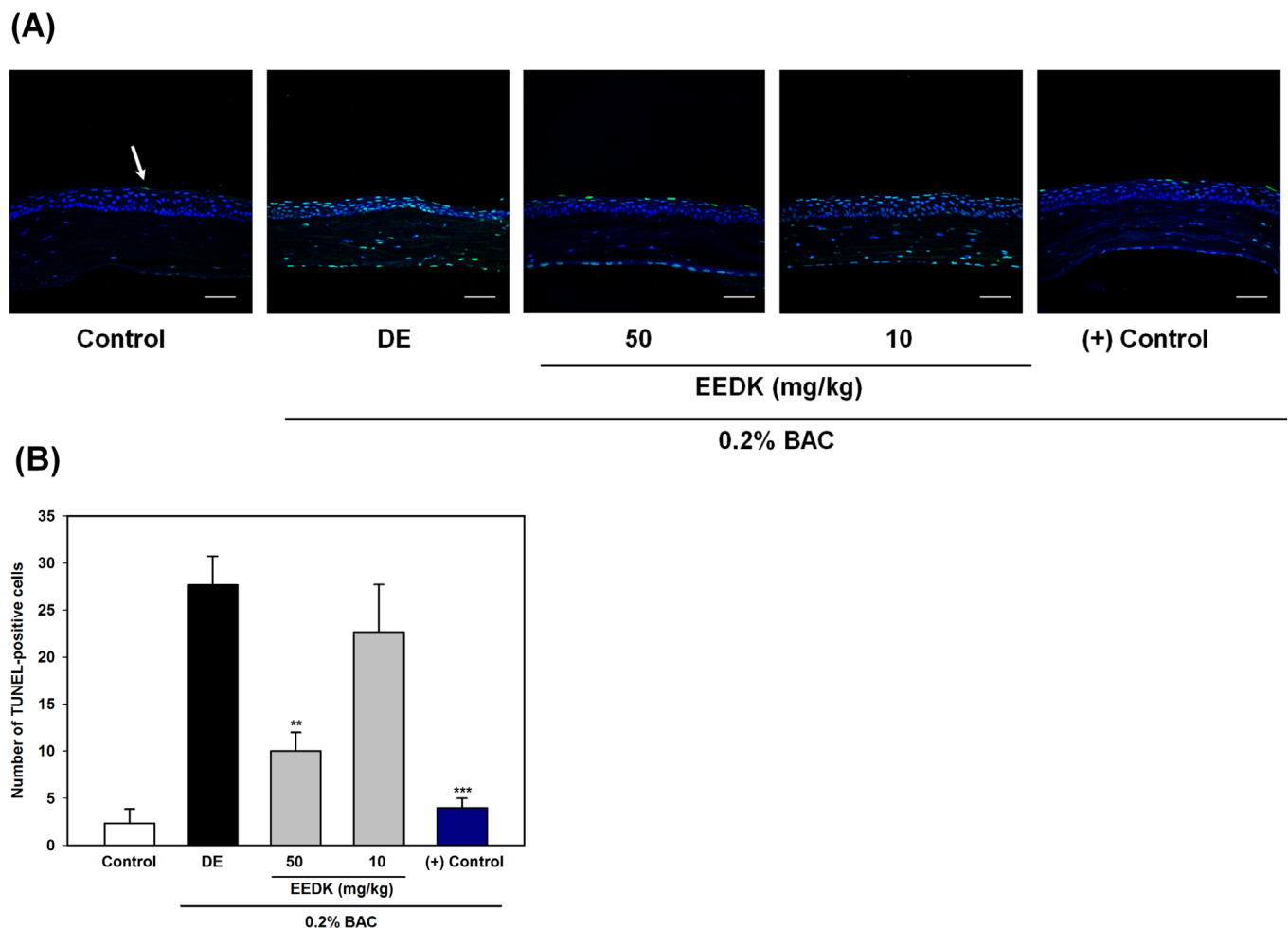


Figure 4. EEDK inhibits apoptosis in the cornea. **A**: Representative images of the cornea were stained with a terminal deoxynucleotidyl transferase-mediated dUTP nick-end labeling (TUNEL) kit (Nuclei were stained with 4',6-diamidino-2-phenylindole [DAPI]) and obtained with confocal microscopy (Original magnification, 630X). An arrow indicates a TUNEL-positive cell (Apoptotic cells). Corneal cross-sections from non-treated (control), benzalkonium chloride (BAC)-treated alone, 50 mg/kg ethanol extract of *Diospyros kaki* (EEDK)-treated, 10 mg/kg EEDK-treated, and positive control (Refresh Plus, preservative-free eye drops, Allergan)-treated mice are shown. **B**: The quantification of TUNEL-positive cells. Scale bar = 50  $\mu$ m. Experimental values are expressed as the mean  $\pm$  standard error of the mean (SEM) from three independent experiments (n = 8 mice per group, \*\*p<0.01, \*\*\*p<0.001).

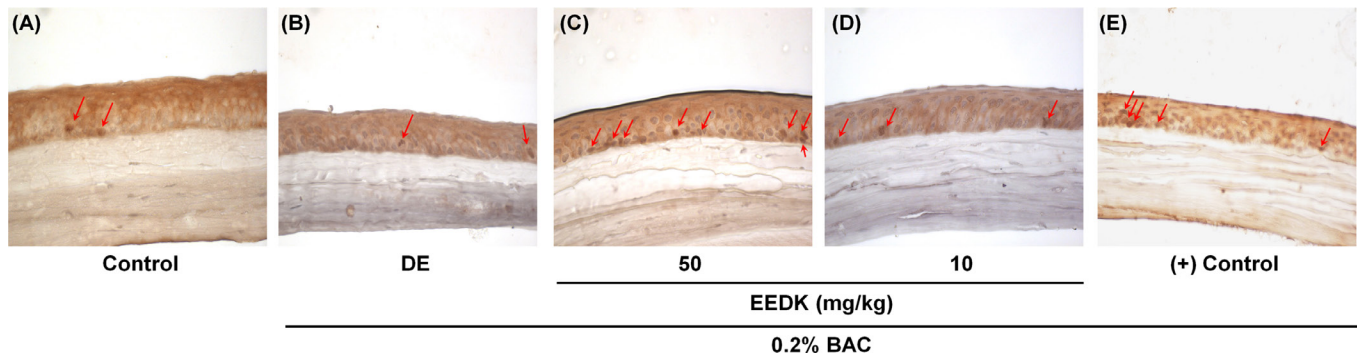


Figure 5. EEDK promotes expression of Ki-67. Representative immunohistochemical staining images of the cornea were stained with Ki-67 antibody (Brown: Ki-67-positive cells) and obtained with light microscopy (original magnification, 400X). **A:** The control group. **B:** The dry eye (DE) group. **C:** The 50 mg/kg ethanol extract of *Diospyros kaki* (EEDK)-treated group. **D:** The 10 mg/kg EEDK-treated group. **E:** The positive-control group (Refresh Plus, preservative-free eye drops, Allergan). An arrow indicates proliferating epithelial cells. Scale bar = 50  $\mu$ m. The results shown are representative of three independent experiments (n = 8 mice per group).

results support the conclusion that treatment with EEDK contributed to proliferation of corneal epithelial cells in a BAC-induced dry eye model.

Based on these results, the presumed mechanisms of the underlying effects of *D. kaki* in the treatment of dry eye in this study include epithelium maintenance by promoting epithelium proliferation and apoptosis inhibition through anti-inflammatory and antioxidant effects.

The leaves of *D. kaki* have been used for various treatments, without reports of toxic effects, over the past hundred years [22]. In the present study, daily oral administration of EEDK in mice did not result in any noticeable toxicity throughout the experiment. The leaves of *D. kaki* have also been approved by the Korea Food and Drug Administration (KFDA) for manufacturing of functional foods and medicines. However, our previous study showed that a high dose may elicit retinotoxicity [24]. Although *D. kaki* might be considered a reliable material in common use, further studies are needed to elucidate the potential effects of *D. kaki*, such as drug–drug interactions, as well as its pharmacokinetics, and its pharmacodynamics.

We performed standardization of EEDK and isolated nine compounds, such as quercetin, kaempferol, and their glycoside-, galactoside-, or galloylated-derivatives in our previous study (Appendix 1) [24]. Quercetin isolated from EEDK attenuates negative influences to the retina following *N*-methyl-*N*-nitrosourea (MNU)-induced retinal damage [24]. However, it is difficult to identify which of these ingredients acted as the bioactive compound in the positive effects of EEDK on dry eye. In the future, studies should be conducted to determine the bioactive compounds of EEDK that are useful for dry eye diseases.

In summary, EEDK can benefit tear film maintenance under dry eye conditions. EEDK showed clinical improvements in BAC-induced mouse dry eye by stabilizing the tear film and maintaining the integrity of the epithelium, and was supported by histologic assessments. Our study indicated that EEDK has great potential to be a beneficial agent in the clinical treatment of dry eye.

#### APPENDIX 1.

To access the data, click or select the words “[Appendix 1.](#)”

#### ACKNOWLEDGMENTS

Sang Hoon Jung (shjung507@gmail.com) and Sung Jae Yang (d001065@naver.com) are co-corresponding authors for this study. This work was funded by Gangneung Asan Hospital (Biomedical Research Center Promotion Fund, 2014-007).

#### REFERENCES

1. Brewitt H, Sistani F. Dry eye disease: the scale of the problem. *Surv Ophthalmol* 2001; 45:Suppl 2S199-202. [PMID: 11587143].
2. Pflugfelder SC, Solomon A, Stern ME. The diagnosis and management of dry eye: a twenty-five-year review. *Cornea* 2000; 19:644-9. [PMID: 11009316].
3. Xu KP, Yagi Y, Tsubota K. Decrease in corneal sensitivity and change in tear function in dry eye. *Cornea* 1996; 15:235-9. [PMID: 8713924].
4. Chotikavanich S, de Paiva CS, Li de Q, Chen JJ, Bian F, Farley WJ, Pflugfelder SC. Production and activity of matrix metalloproteinase-9 on the ocular surface increase in dysfunctional tear syndrome. *Invest Ophthalmol Vis Sci* 2009; 50:3203-9. [PMID: 19255163].



5. Lam H, Bleiden L, de Paiva CS, Farley W, Stern ME, Pflugfelder SC. Tear cytokine profiles in dysfunctional tear syndrome. *Am J Ophthalmol* 2009; 147:198-205. [PMID: 18992869].
6. Solomon A, Dursun D, Liu Z, Xie Y, Macri A, Pflugfelder SC. Pro- and anti-inflammatory forms of interleukin-1 in the tear fluid and conjunctiva of patients with dry-eye disease. *Invest Ophthalmol Vis Sci* 2001; 42:2283-92. [PMID: 11527941].
7. Tishler M, Yaron I, Geyer O, Shirazi I, Naftaliev E, Yaron M. Elevated tear interleukin-6 levels in patients with Sjogren syndrome. *Ophthalmology* 1998; 105:2327-9. [PMID: 9855167].
8. Yoon KC, Jeong IY, Park YG, Yang SY. Interleukin-6 and tumor necrosis factor-alpha levels in tears of patients with dry eye syndrome. *Cornea* 2007; 26:431-7. [PMID: 17457192].
9. Luo L, Li DQ, Corrales RM, Pflugfelder SC. Hyperosmolar saline is a proinflammatory stress on the mouse ocular surface. *Eye Contact Lens* 2005; 31:186-93. [PMID: 16163009].
10. Baudouin C, Labbe A, Liang H, Pauly A, Brignole-Baudouin F. Preservatives in eyedrops: the good, the bad and the ugly. *Prog Retin Eye Res* 2010; 29:312-34. [PMID: 20302969].
11. Rosin LM, Bell NP. Preservative toxicity in glaucoma medication: clinical evaluation of benzalkonium chloride-free 0.5% timolol eye drops. *Clin Ophthalmol* 2013; 7:2131-5. [PMID: 24204115].
12. Xiao X, Luo P, Zhao H, Chen J, He H, Xu Y, Lin Z, Zhou Y, Xu J, Liu Z. Amniotic membrane extract ameliorates benzalkonium chloride-induced dry eye in a murine model. *Exp Eye Res* 2013; 115:31-40. [PMID: 23792171].
13. Burstein NL. Preservative cytotoxic threshold for benzalkonium chloride and chlorhexidine digluconate in cat and rabbit corneas. *Invest Ophthalmol Vis Sci* 1980; 19:308-13. [PMID: 7358482].
14. Pisella PJ, Fillacier K, Elena PP, Debbasch C, Baudouin C. Comparison of the effects of preserved and unpreserved formulations of timolol on the ocular surface of albino rabbits. *Ophthalmic Res* 2000; 32:3-8. [PMID: 10657748].
15. Bei W, Zang L, Guo J, Peng W, Xu A, Good DA, Hu Y, Wu W, Hu D, Zhu X, Wei M, Li C. Neuroprotective effects of a standardized flavonoid extract from *Diospyros kaki* leaves. *J Ethnopharmacol* 2009; 126:134-42. [PMID: 19665536].
16. Bei WJ, Xu AL, Li CY, Cabot PJ, Hermanussen S. Flavonoids from *Diospyros kaki* inhibit the adhesion between lymphocyte and dorsal root ganglion. *Zhong Yao Cai* 2009; 32:740-4. [PMID: 19771850].
17. Izuchi R, Nakai Y, Takahashi H, Ushiana S, Okada S, Misaka T, Abe K. Hepatic gene expression of the insulin signaling pathway is altered by administration of persimmon peel extract: a DNA microarray study using type 2 diabetic Goto-Kakizaki rats. *J Agric Food Chem* 2011; 59:3320-9. [PMID: 21370910].
18. Katsube T, Tabata H, Ohta Y, Yamasaki Y, Anurad E, Shiwaku K, Yamane Y. Screening for antioxidant activity in edible plant products: comparison of low-density lipoprotein oxidation assay, DPPH radical scavenging assay, and Folin-Ciocalteu assay. *J Agric Food Chem* 2004; 52:2391-6. [PMID: 15080652].
19. Kim HH, Kim DS, Kim SW, Lim SH, Kim DK, Shin TY, Kim SH. Inhibitory effects of *Diospyros kaki* in a model of allergic inflammation: role of cAMP, calcium and nuclear factor-kappaB. *Int J Mol Med* 2013; 32:945-51. [PMID: 23921373].
20. Gorinstein S, Zachwieja Z, Foltá M, Barton H, Piotrowicz J, Zemser M, Weisz M, Trakhtenberg S, Martin-Belloso O. Comparative contents of dietary fiber, total phenolics, and minerals in persimmons and apples. *J Agric Food Chem* 2001; 49:952-7. [PMID: 11262055].
21. Izuchi R, Takahashi H, Inada Y. Preparing a carotenoid polyphenol-enriched extract from the peel of persimmon, *Diospyros kaki* L.f. *Biosci Biotechnol Biochem* 2009; 73:2793-5. [PMID: 19966462].
22. Xie C, Xie Z, Xu X, Yang D. Persimmon (*Diospyros kaki* L.) leaves: a review on traditional uses, phytochemistry and pharmacological properties. *J Ethnopharmacol* 2015; 163:229-40. [PMID: 25637828].
23. Yang SJ, Jo H, Kim KA, Ahn HR, Kang SW, Jung SH. *Diospyros kaki* Extract Inhibits Alkali Burn-Induced Corneal Neovascularization. *J Med Food* 2016; 19:106-9. [PMID: 26348484].
24. Kim KA, Kang SW, Ahn HR, Song Y, Yang SJ, Jung SH. Leaves of Persimmon (*Diospyros kaki* Thunb.) Ameliorate *N*-Methyl-*N*-nitrosourea (MNU)-Induced Retinal Degeneration in Mice. *J Agric Food Chem* 2015; 63:7750-9. [PMID: 26260943].
25. Zhang Z, Yang WZ, Zhu ZZ, Hu QQ, Chen YF, He H, Chen YX, Liu ZG. Therapeutic effects of topical doxycycline in a benzalkonium chloride-induced mouse dry eye model. *Invest Ophthalmol Vis Sci* 2014; 55:2963-74. [PMID: 24722696].
26. Xiao X, He H, Lin Z, Luo P, He H, Zhou T, Zhou Y, Liu Z. Therapeutic effects of epidermal growth factor on benzalkonium chloride-induced dry eye in a mouse model. *Invest Ophthalmol Vis Sci* 2012; 53:191-7. [PMID: 22159022].
27. Lin Z, Liu X, Zhou T, Wang Y, Bai L, He H, Liu Z. A mouse dry eye model induced by topical administration of benzalkonium chloride. *Mol Vis* 2011; 17:257-64. [PMID: 21283525].
28. Bozanic D, Saraga-Babic M. Cell proliferation during the early stages of human eye development. *Anat Embryol (Berl)* 2004; 208:381-8. [PMID: 15252731].
29. Leung EW, Medeiros FA, Weinreb RN. Prevalence of ocular surface disease in glaucoma patients. *J Glaucoma* 2008; 17:350-5. [PMID: 18703943].
30. Jaenen N, Baudouin C, Pouliquen P, Manni G, Figueiredo A, Zeyen T. Ocular symptoms and signs with preserved and preservative-free glaucoma medications. *Eur J Ophthalmol* 2007; 17:341-9. [PMID: 17534814].
31. De Saint Jean M, Debbasch C, Brignole F, Rat P, Warnet JM, Baudouin C. Toxicity of preserved and unpreserved

- antiglaucoma topical drugs in an in vitro model of conjunctival cells. *Curr Eye Res* 2000; 20:85-94. [PMID: 10617908].
32. Herreras JM, Pastor JC, Calonge M, Asensio VM. Ocular surface alteration after long-term treatment with an antiglaucomatous drug. *Ophthalmology* 1992; 99:1082-8. [PMID: 1495787].
  33. Rolando M, Brezzo V, Giordano G, Campagna P, Burlando S, Calabria G. The effect of different benzalkonium chloride concentrations on human normal ocular surface - a controlled prospective impression cytologic study. *Lacrimal System* 1991:87-91.
  34. Calonge M, Enriquez-de-Salamanca A, Diebold Y, Gonzalez-Garcia MJ, Reinoso R, Herreras JM, Corell A. Dry eye disease as an inflammatory disorder. *Ocul Immunol Inflamm* 2010; 18:244-53. [PMID: 20482396].
  35. Lin Z, Zhou Y, Wang Y, Zhou T, Li J, Luo P, He H, Wu H, Liu Z. Serine protease inhibitor A3K suppressed the formation of ocular surface squamous metaplasia in a mouse model of experimental dry eye. *Invest Ophthalmol Vis Sci* 2014; 55:5813-20. [PMID: 25103264].
  36. Management and therapy of dry eye disease: report of the Management and Therapy Subcommittee of the International Dry Eye WorkShop (2007). *Ocul Surf* 2007; 5:163-78. [PMID: 17508120].
  37. Murube J, Rivas L. Impression cytology on conjunctiva and cornea in dry eye patients establishes a correlation between squamous metaplasia and dry eye clinical severity. *Eur J Ophthalmol* 2003; 13:115-27. [PMID: 12696629].
  38. Chen YT, Li S, Nikulina K, Porco T, Gallup M, McNamara N. Immune profile of squamous metaplasia development in autoimmune regulator-deficient dry eye. *Mol Vis* 2009; 15:563-76. [PMID: 19365590].
  39. Li S, Nikulina K, DeVoss J, Wu AJ, Strauss EC, Anderson MS, McNamara NA. Small proline-rich protein 1B (SPRR1B) is a biomarker for squamous metaplasia in dry eye disease. *Invest Ophthalmol Vis Sci* 2008; 49:34-41. [PMID: 18172072].
  40. Strong B, Farley W, Stern ME, Pflugfelder SC. Topical cyclosporine inhibits conjunctival epithelial apoptosis in experimental murine keratoconjunctivitis sicca. *Cornea* 2005; 24:80-5. [PMID: 15604871].
  41. Yeh S, Song XJ, Farley W, Li DQ, Stern ME, Pflugfelder SC. Apoptosis of ocular surface cells in experimentally induced dry eye. *Invest Ophthalmol Vis Sci* 2003; 44:124-9. [PMID: 12506064].
  42. Wu H, Zhang H, Wang C, Wu Y, Xie J, Jin X, Yang J, Ye J. Genoprotective effect of hyaluronic acid against benzalkonium chloride-induced DNA damage in human corneal epithelial cells. *Mol Vis* 2011; 17:3364-70. [PMID: 22219631].
  43. Butt MS, Sultan MT, Aziz M, Naz A, Ahmed W, Kumar N, Imran M. Persimmon (*Diospyros Kaki*) Fruit: Hidden Phytochemicals and Health Claims. *Excli Journal* 2015; 14:542-61.

Articles are provided courtesy of Emory University and the Zhongshan Ophthalmic Center, Sun Yat-sen University, P.R. China. The print version of this article was created on 2 April 2016. This reflects all typographical corrections and errata to the article through that date. Details of any changes may be found in the online version of the article.