

Contents lists available at [ScienceDirect](https://www.sciencedirect.com)

International Journal of Surgery Case Reports

journal homepage: www.casereports.com

Rare presentation of community acquired pneumonia resulted in laparoscopic intervention in adult. Case Report

Jessica Naccour^a, Hassan Sabra^b, Mersad Alimoradi^b, Etienne El-Helou^{b,*}, Marwan M. Haddad^c, Henri Bitar^d^a Emergency Medicine Department, Faculty of Medical Sciences, Lebanese University, Mount Lebanon, Lebanon^b General Surgery Department, Faculty of Medical Sciences, Lebanese University, Mount Lebanon, Lebanon^c Radiology Department, Mount Lebanon Hospital, Mount Lebanon, Lebanon^d General Surgery Department, Mount Lebanon Hospital, Mount Lebanon, Lebanon

ARTICLE INFO

Article history:

Received 8 August 2020

Received in revised form 6 September 2020

Accepted 6 September 2020

Available online 14 September 2020

Keywords:

Peritonitis

Surgical abdomen

Abdominal pain mimics

Community acquired pneumonia

Laparoscopy

Case report

ABSTRACT

INTRODUCTION: Community acquired pneumonia usually presents with typical clinical and radiological signs allowing for a quick diagnosis. Nevertheless, pneumonia can infrequently mimic acute abdominal pathologies, leading to invasive unnecessary procedures.

PRESENTATION OF CASE: We report a case of a 44-year-old man, previously healthy, admitted with a diagnosis of a surgical abdomen, investigated with an exploratory laparoscopy after inconclusive imaging and failure of improvement. Clinical evolution revealed the diagnosis of pneumonia.

DISCUSSION: Community acquired pneumonia is a frequently encountered condition. While its clinical presentation is usually related to the respiratory system, extrapulmonary manifestations, including abdominal pain in the pediatric population, are well documented. However, solely severe acute abdominal pain, being as the major presentation, without respiratory symptoms or radiological signs is very rarely reported.

CONCLUSION: Community acquired pneumonia can sometimes be a challenging diagnosis. Acute abdominal pain mimicking a surgical abdomen is an infrequent presentation but can confuse physicians when no radiological or clinical signs of pneumonia are present.

© 2020 The Author(s). Published by Elsevier Ltd on behalf of IJS Publishing Group Ltd. This is an open access article under the CC BY-NC-ND license (<http://creativecommons.org/licenses/by-nc-nd/4.0/>).

1. Introduction

Even though severe abdominal pain is an uncommon presentation of community acquired pneumonia (CAP), the entity should be kept in mind in the differential diagnosis to avoid non-essential interventions [1]. We report a case of an adult man who presented with a picture of frank peritonitis requiring diagnostic laparoscopy. Laparoscopic exploration was normal despite the clear clinical signs heralding peritonitis. A late incidental finding on a later chest X-ray revealed lobar pneumonia. To our knowledge, this is the first reported case of pneumonia presenting with a picture of severe peritonitis necessitating surgical intervention.

This case was reported in accordance with the SCARE criteria [2].

* Corresponding author.

E-mail addresses: jessicanaccour14@hotmail.com (J. Naccour), hassan_sabra_14@hotmail.com (H. Sabra), alimoradi.mersad@gmail.com (M. Alimoradi), Etienne-elhelou@hotmail.com (E. El-Helou), m_haddad@hotmail.com (M.M. Haddad), henribitar@hotmail.com (H. Bitar).

<https://doi.org/10.1016/j.ijscr.2020.09.046>

2210-2612/© 2020 The Author(s). Published by Elsevier Ltd on behalf of IJS Publishing Group Ltd. This is an open access article under the CC BY-NC-ND license (<http://creativecommons.org/licenses/by-nc-nd/4.0/>).

2. Case description

A 44 years-old gentleman, heavy smoker, moderate alcohol consumer with no known food or drug allergies, nor any past medical or surgical history presented to our emergency department for acute onset of abdominal pain. The pain started one day prior to presentation, was continuous, progressively increasing in intensity, and was localized to the right hypochondriac, lumbar, and iliac regions. The patient reported that the pain did not radiate elsewhere and was associated with multiple episodes of vomiting. He denies any cough, dyspnea, or other complaints.

On physical examination, the patient was febrile (Temperature 39 °C), tachycardic (106 beats per minute), normotensive (Blood Pressure 120/80 mmHg), and had normal oxygen saturation (SpO₂ 96%). The abdominal exam revealed abdominal rigidity over the right hemi-abdomen, associated with guarding on the left. Digital rectal exam was normal. Cardiopulmonary auscultation was normal, without any added sounds.

The patient's laboratory studies revealed leukocytosis (WBC > 20,000/μL) with neutrophil shift (PMN 86%), and an elevated CRP (61 mg/L). Total bilirubin was elevated (2.42 mg/dl,

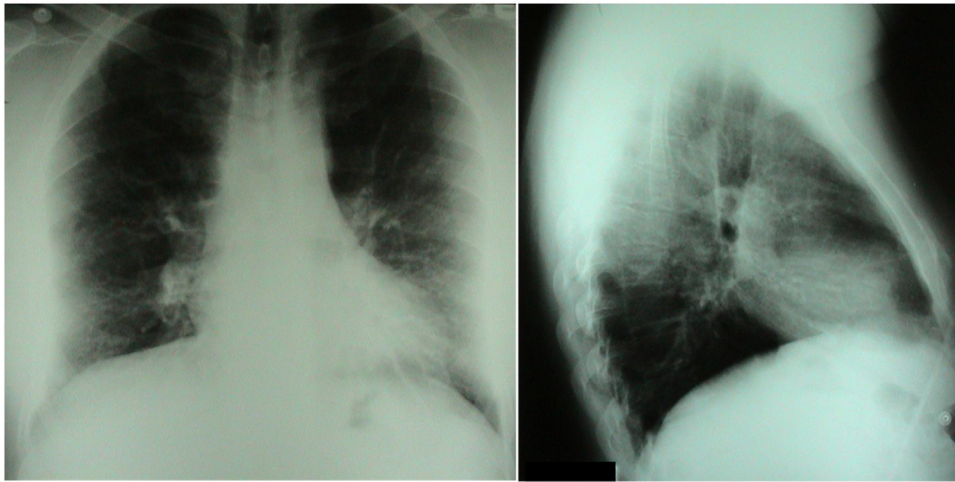


Fig. 1. Chest X-ray (AP and Lateral): Lungs are clear. Both costo-phrenic angles are free.

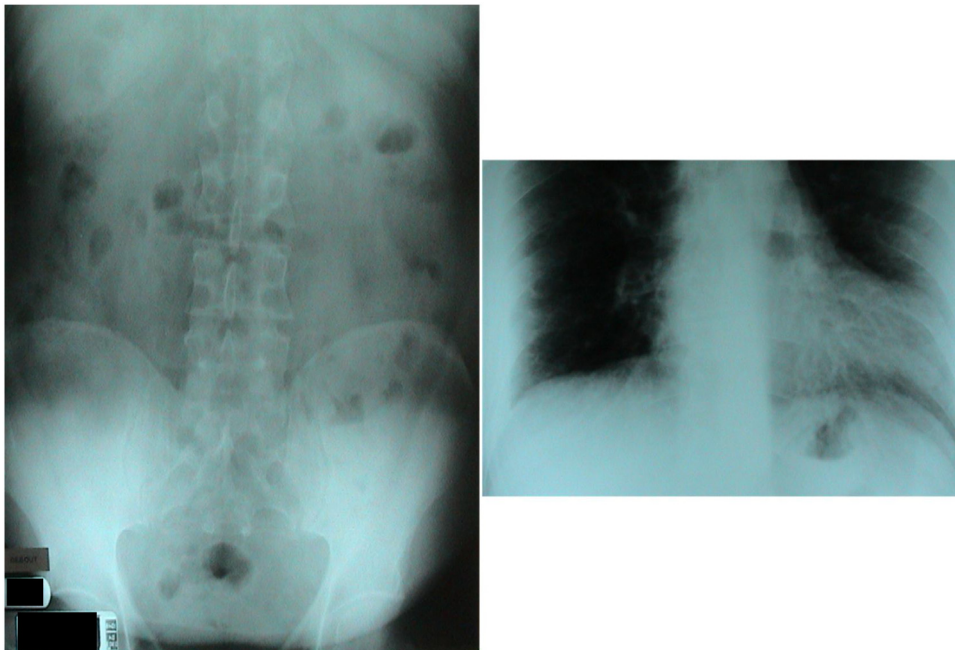


Fig. 2. Abdominal X-ray: No intestinal distension, no air-fluid level, and no pneumoperitoneum.

Direct 1 mg/dl), normal transaminases, and normal pancreatic enzymes. Urine analysis was also normal. Pancultures were ordered.

The chest X-ray showed clear lungs with clear costophrenic angles (Fig. 1). Abdominal X-ray showed no intestinal distension, no air-fluid level, and no pneumoperitoneum (Fig. 2).

Abdominal ultrasonography showed a normal multilithiasic gallbladder and biliary tree. No intraabdominal fluids detected, and the remainder of the echographic exam was normal. An enhanced CT Scan of the abdomen and pelvis showed mild parietal thickening of the duodenum and at the angle of Treitz. No abdominal masses, no ascites, and no other abnormalities were noted.

Faced with this presentation of peritonitis, septicemia, failure to alleviate pain by medications, and the inability to identify a corresponding etiology, we decided to perform a diagnostic laparoscopy after starting broad-spectrum antibiotics (metronidazole and ceftriaxone).

Under general anesthesia, diagnostic laparoscopy was performed by the primary surgeon. No ascites or abnormal masses were seen. The liver, gallbladder, and spleen appeared normal. The stomach and bowels were intact without any suspicious lesions or inflammatory signs. Surgery was aborted with an inconclusive diagnosis and the patient ameliorated well without any surgical complications.

The fever persisted after surgery, however, the abdominal pain was improving and was still the only complaint. On physical examination, the guarding on the right side slightly improved, while the pain in the right upper quadrant persisted. On routine chest auscultation, new right basal crackles were heard. Chest X-ray was ordered and revealed new right lung base infiltrates consistent with pneumonia (Figs. 3 and 4), which was confirmed by a chest CT (Fig. 5). Only after the second postoperative day did the patient develop cough and dyspnea. A diagnosis of CAP was done, and the patient was started on proper antibiotic therapy and was later discharged home after improvement.

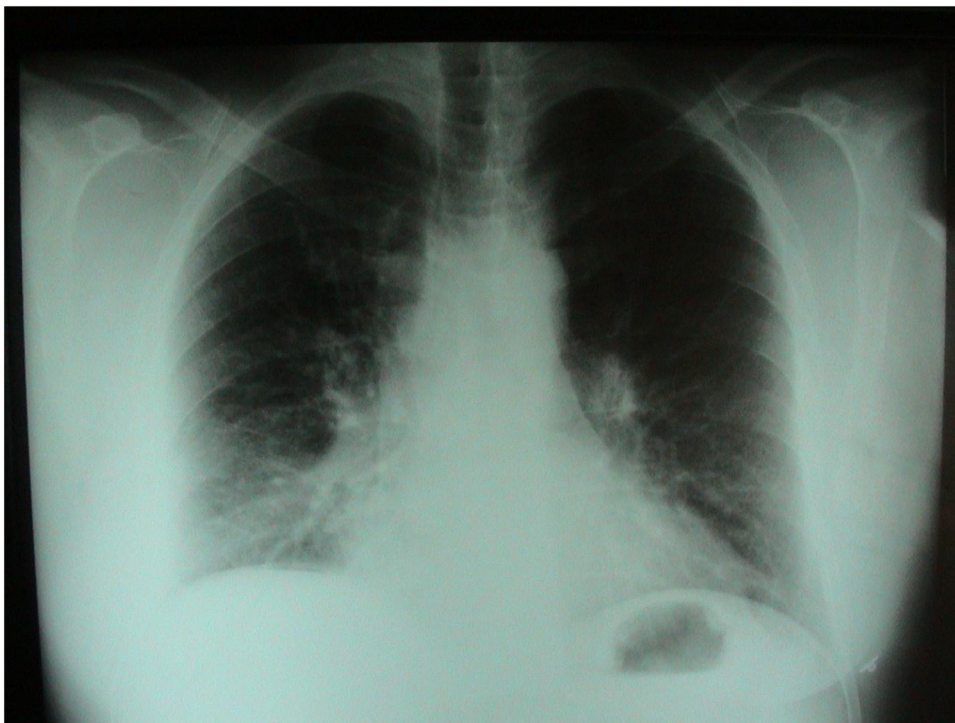

Fig. 3. Chest X-ray (AP): Right lung base infiltrates.

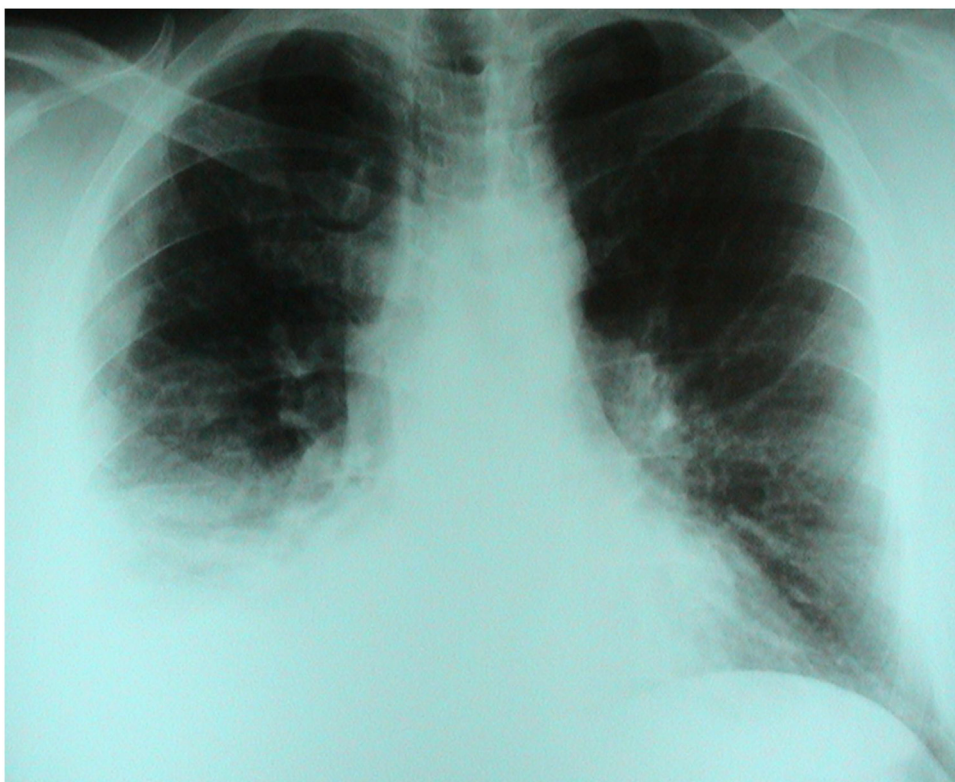

Fig. 4. Chest X-ray (AP): Right lung base consolidation.

3. Discussion

Pneumonia is considered a leading cause of hospitalization among both children and adults. Diagnosis is based on proper history taking, physical examination and identification of underlying

lung disease, and recent travel and smoking history. The diagnosis should be suspected in any patient presenting with cough, fever, and chills [3].

Clinical presentation of CAP in adults is mostly related to respiratory symptoms, typically consisting of cough, dyspnea, changes in

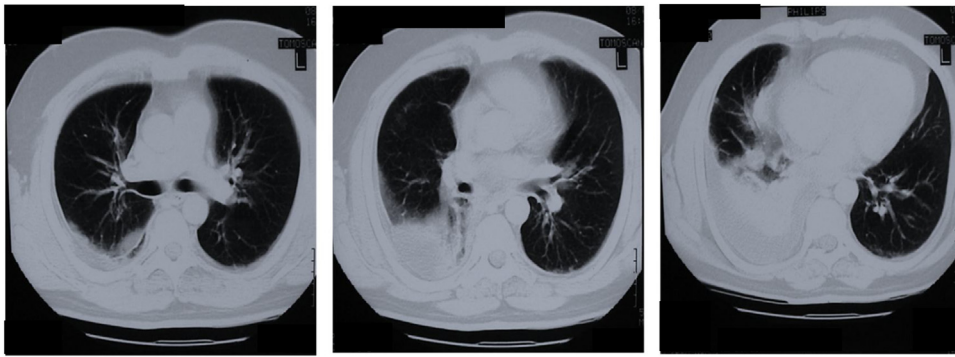


Fig. 5. Chest CT: Right lung base consolidation.

sputum production color, chest discomfort, and fever or hypothermia [1]. This could be associated with pleuritic chest pain, fatigue, anorexia, tachypnea, and hypotension [3]. The physical exam usually reveals decreased air entry, wheezing, tactile fremitus, and crackles [3]. Chest X-ray is the cornerstone in diagnosing pneumonia, however, 10% of patients with typical pneumonia symptoms and a normal chest X-ray will not develop symptoms until after 72 h have passed [3]. After establishing the diagnosis, empiric antibiotic therapy is recommended [3], knowing that the most commonly reported pathogens are streptococcus pneumonia, influenza virus, and human rhinovirus [5].

In pediatric patients, pneumonia is considered as the main extra-abdominal cause of acute abdominal pain [1]. In contrast, abdominal pain occurs only in 8% of pneumonia cases in adults, and it can rarely be the presenting symptom, causing confusion and shifting the differential towards abdominal etiologies. Marked abdominal symptoms in pneumonia may mimic an acute surgical abdomen caused by appendicitis, cholecystitis, perforation, obstruction, and others [4]. Moreover, pneumonia may be associated with other abdominal symptoms such as nausea, vomiting, constipation, and flatulence, leading to further confusion in diagnosis [5]. In patients with chest pathologies presenting with signs of acute abdomen, a chest X-ray is positive in only 10–15% of cases [9].

Pneumonia is not the only reported extra-abdominal etiology that may present as abdominal pain. Abdominal Pain mimics is an entity by itself with a vast differential diagnosis including conditions that may provoke abdominal pain without having any single intraabdominal lesion [6].

Abdominal pain is the most common chief complaint in patients presenting to the emergency department in the United States, and its evaluation can be difficult because the “textbook” presentation seldom presents; a surgical abdomen can present with mild symptoms initially while simple gastroenteritis may sometimes present as severe abdominal pain [7]. Acute abdomen requires precise and rapid diagnosis and treatment to avoid an increase in mortality [9].

Acute right upper quadrant pain is usually related to the hepatobiliary system, nevertheless, it could be a pleuro-abdominal pain due to pneumonia or pulmonary infarction [7]. The American College of Radiology recommends performing ultrasonography followed by CT scan in the investigations of right upper abdominal pain, however, there is no role of chest X-ray in the workup [7]. When an acute abdomen is suspected, laparoscopy is safe and effective in setting the diagnosis without delay while avoiding unnecessary laparotomies. Its diagnostic accuracy ranges from 85 to 100% [8].

There is still no definite explanation of how exactly pneumonia causes abdominal pain [1]. The phenomenon may be explained with lower lobe pneumonia causing irritation of the diaphragm and leading to this abdominal pain [6]. There are no clear stud-

ies discussing this correlation and only a few cases were found in the English literature reporting pneumonia mistaken for abdominal pathologies. Koochak et al. reported a case where the diagnosis of pneumonia was identified within few hours of presentation [4], while Armeni et al. [1] as well as Mizumoto et al. [5] both reported a case of pneumonia presenting with marked abdominal symptoms, diagnosed 72 h after admission [1].

Declaration of Competing Interest

The authors report no declarations of interest.

Funding

This research did not receive any specific grant from funding agencies in the public, commercial, or not-for-profit sectors.

Ethical approval

The study type is exempt from ethical approval.

Consent

Written informed consent was obtained from the patient for publication of this case report and accompanying images.

A copy of the written consent is available for review by the Editor-in-Chief of this journal on request.

Author contribution

Writing the paper: Jessica Naccour, Hassan Sabra.
Data collection: Mersad Alimoradi, Etienne El-Helou.
Supervision: Henri Bitar, Marwan M Haddad.

Registration of research studies

1. Name of the registry: N/A.
2. Unique identifying number or registration ID: N/A.
3. Hyperlink to your specific registration (must be publicly accessible and will be checked): N/A.

Guarantor

Dr Henri Bitar.

Provenance and peer review

Not commissioned, externally peer-reviewed.

Acknowledgements

We would like to thank the Doctors and staff of our institute, and the members of our University, for their continuous support and guidance.

References

- [1] E. Armeni, V. Mylona, G. Karlis, E. Makrygiannis, Pneumonia presenting with lower right abdominal pain and migratory polyarthritits, *Respir. Med. Case Rep.* 5 (2012) 29–30, <http://dx.doi.org/10.1016/j.rmedc.2011.11.001>, Epub 2011 Dec 10. PMID: 26057353; PMCID: PMC3920392.
- [2] R.A. Agha, M.R. Borrelli, R. Farwana, K. Koshy, A. Fowler, D.P. Orgill, For the SCARE Group, The SCARE 2018 statement: updating consensus surgical Case REport (SCARE) guidelines, *Int. J. Surg.* 60 (2018) 132–136.
- [3] S.N. Grief, J.K. Loza, Guidelines for the evaluation and treatment of pneumonia, *Prim. Care* 45 (September (3)) (2018) 485–503, <http://dx.doi.org/10.1016/j.pop.2018.04.001>, PMID: 30115336; PMCID: PMC7112285.
- [4] H. Emadi Koochak, E. Tabibian, S. Rahimi Dehgolan, Abdominal pain as extrapulmonary presentation of pneumonia in an adult: a case report, *Acta Med. Iran.* 55 (February (2)) (2017) 131–133, PMID: 28282711.
- [5] J. Mizumoto, T. Shimizu, All that glitters is not gold, *J. Gen. Fam. Med.* 20 (September (5)) (2019) 180–184.
- [6] J. Palmer, E. Pontius, Abdominal pain mimics, *Emerg. Med. Clin. North Am.* 34 (May (2)) (2016) 409–423, <http://dx.doi.org/10.1016/j.emc.2015.12.007>, Epub 2016 Mar 22. PMID: 27133252.
- [7] B. Mattson, K. Dulaimy, The 4 quadrants: acute pathology in the abdomen and current imaging guidelines, *Semin. Ultrasound CT MR* 38 (August (4)) (2017) 414–423, <http://dx.doi.org/10.1053/j.sult.2017.02.006>, Epub 2017 Feb 20. PMID: 28865530.
- [8] M.F. Sharaf, E.T. Ghalwash, A.A. Ali, Role of laparoscopy in diagnosis and treatment of acute abdominal pain, *Egypt. J. Hosp. Med.* 79 (April (1)) (2020) 442–445.
- [9] T. Mayumi, M. Yoshida, S. Tazuma, A. Furukawa, O. Nishii, K. Shigematsu, T. Azuhata, A. Itakura, S. Kamei, H. Kondo, S. Maeda, The practice guidelines for primary care of acute abdomen 2015, *Jpn. J. Radiol.* 34 (January (1)) (2016) 80–115.

Open Access

This article is published Open Access at [sciencedirect.com](https://www.sciencedirect.com). It is distributed under the [IJSCR Supplemental terms and conditions](#), which permits unrestricted non commercial use, distribution, and reproduction in any medium, provided the original authors and source are credited.