



EXCEPTIONAL CASE

Renal tubular dysgenesis: antenatal ultrasound scanning and molecular investigations in a Saudi Arabian family

Mohamed H. Al-Hamed¹, Wesam Kurdi², Nada Alsahan²,
Qaamariya Ambosaidi², Maha Tulbah² and John A. Sayer³

¹Genetics Department, King Faisal Specialist Hospital and Research Centre, Riyadh, Saudi Arabia, ²Obstetrics and Gynecology Department, KFSH&RC, Riyadh, Saudi Arabia and ³Institute of Genetic Medicine, Newcastle University, International Centre for Life, Newcastle, UK

Correspondence and offprint requests to: Mohamed H. Al-Hamed; E-mail: hamed@kfshrc.edu.sa

Abstract

Autosomal recessive renal tubular dysgenesis (RTD) is a rare lethal disease affecting renal development before birth. RTD is manifested by anuria and severe hypotension resulting in oligohydramnios and birth defects known as Potter's syndrome. Homozygous or compound heterozygous mutations in genes encoding components of the renin–angiotensin system (ACE, AGT, AGTR1 and REN) have been reported to cause RTD. A consanguineous family with a history of multiple stillbirths was investigated using prenatal ultrasound and molecular genetic analysis of an affected foetus. Prenatal ultrasound scan suggested RTD, and a novel homozygous frameshift mutation c.299_300delAA (p.Lys100Serfs*4) in the REN gene was identified by whole-exome sequencing, which segregated with parental DNA samples. RTD remains a rare but important cause of prenatal and perinatal death and may present with antenatally hyperechogenic kidneys.

Key words: antenatal ultrasound scan, mutations, prenatal, renal tubular dysgenesis

Background

Autosomal recessive renal tubular dysgenesis (RTD) is a rare lethal disease affecting renal tubular development before birth [1]. Absent or low numbers of differentiated proximal tubules is a histological feature of this renal disease, leading to an appearance of closely packed glomeruli [2].

RTD is manifested by anuria, hypotension and oligohydramnios, which leads to Potter's syndrome [3]. Although autosomal recessive RTD has been reported in some centres [4], it remains a rare disease and the prevalence is still unknown. Mutations in genes encoding proteins involved in the renin–angiotensin

system (RAS) are responsible [1, 5]. The RAS consists of several proteins that are involved in a series of steps to produce angiotensin II protein, which regulates blood pressure and the balance of electrolytes in the body. Mutations in the RAS genes ACE, AGT, AGTR1 and REN have all been reported to impair the production or function of angiotensin II, leading to RTD [2]. In a study of 48 cases, mutations in ACE accounted for 64.4% of cases of RTD. Mutations in REN, AGT and AGTR1 were seen in 20.8, 8.3 and 6.3% of cases, respectively [2].

REN encodes renin, which is produced by juxtaglomerular cells in the kidney. Circulating renin hydrolyses angiotensinogen

Received: February 24, 2016. Accepted: June 7, 2016

© The Author 2016. Published by Oxford University Press on behalf of ERA-EDTA.

This is an Open Access article distributed under the terms of the Creative Commons Attribution Non-Commercial License (<http://creativecommons.org/licenses/by-nc/4.0/>), which permits non-commercial re-use, distribution, and reproduction in any medium, provided the original work is properly cited. For commercial re-use, please contact journals.permissions@oup.com

into the peptide angiotensin I. A further cleavage step of angiotensin I by endothelial-bound angiotensin-converting enzyme in the lungs produces the vasoactive peptide angiotensin II. REN is located on chromosome 1q32, and biallelic mutations may cause RTD, whilst heterozygous parents of REN-related RTD patients are typically asymptomatic [2]. Specific heterozygous mutations, involving the signal peptide of renin, cause REN-related kidney disease, a progressive form of kidney failure associated with anaemia, hypotension and hyperuricaemia [6], which is part of a group of conditions recently classified as autosomal dominant tubulointerstitial kidney disease (ADTKD) [7].

In this study, we present the clinical and molecular investigations of a family with RTD.

Case report

A first-degree consanguineous couple who had unfortunately had three previous prenatal deaths was referred to the Obstetric High-Risk Clinic at King Faisal Specialist Hospital and Research Center. Previous foetuses had ultrasound scan (USS) features of RTD, with hyperechogenic kidneys and signs of Potter's syndrome. In the first affected pregnancy in 2005, the foetus had USS evidence of anhydramnios and bilateral echogenic kidneys. The mother had a spontaneous preterm delivery at 35 weeks gestation, and the baby died immediately after birth. A year later, she conceived a second pregnancy, where the foetus was diagnosed at 26 weeks gestation, with USS evidence of anhydramnios and bilateral echogenic kidneys. After a spontaneous preterm delivery at 35 weeks, the baby died immediately after delivery. In her third pregnancy in 2008, the foetus was diagnosed following antenatal USS with anhydramnios and bilateral echogenic kidneys at 23 weeks gestational age. Following a spontaneous preterm delivery at 34 weeks, the baby died immediately after delivery.

During the fourth and most recent pregnancy, the mother was assessed at our clinic in early pregnancy. The initial 13 weeks antenatal USS showed normal nuchal translucency in the foetus. Further USS imaging was performed at 16 and 19 weeks gestation. Here, it was noticed that there was a degree of oligohydramnios, but the foetal kidneys appeared normal. However, at 23 weeks gestation, antenatal USS confirmed that both foetal kidneys appeared hyperechogenic and bulky.

Further USS imaging of the kidneys at 26 weeks gestation revealed a left kidney 50.2 mm in length and a right kidney 42.5 mm in length. These values are above the 95th percentile for gestational age. The USS also revealed anhydramnios and a narrow thorax.

Antenatal USS findings are summarized in Table 1 and Figure 1.

The pregnancy continued with no additional complications, and the mother had a spontaneous labour and delivery at 34 weeks gestation. The delivered baby had an early neonatal

death within minutes of birth. Unfortunately, we had no specimens from the child for histological analysis.

The family wished to help determine the molecular cause of the disease. Informed consent was obtained from the family and approved by the Research Advisory Council at King Faisal Specialist Hospital and Research Centre. Blood samples from the affected child and both parents' whole blood were obtained for genetics investigations. DNA was extracted using the Gentra Systems PURE-GENE DNA Isolation kit (Qiagen, USA). Molecular karyotyping (Affymetrix CytoScan® HD Array Kit) was performed on the family to exclude chromosomal aneuploidy and to determine regions of genetics homozygosity in the foetus. No chromosomal abnormalities were detected. Whole-exome sequencing (WES) using foetal DNA was performed in combination with homozygosity mapping. This identified a region of 54.7 Mb of homozygosity on chromosome 1 that included a novel homozygous mutation in REN (c.299_300delAA; p.Lys100Serfs*4) (Figure 1D). Both parents were heterozygous for the REN variant (Figure 1D). *In silico* analysis of the novel variant suggested that this was a pathogenic change (MutationTaster: disease causing) that was absent from the Exome Aggregation Consortium database. The mutation is predicted to lead to a truncated protein or nonsense-mediated decay of the mRNA. It is likely, although not proven, given the lack of DNA samples, that previous miscarriages in this family were due to a homozygous REN mutation in the affected foetuses.

Discussion

A combination of antenatal USS and molecular investigations is a powerful approach to characterize lethal and rare renal diseases. RTD is a challenging disease to diagnose prenatally by ultrasound, and usually the diagnosis is only established at autopsy. In RTD, the affected kidneys are usually normal in size, but some reports suggest that they may be enlarged [8].

It is well known that the differential diagnosis of antenatal enlarged hyperechogenic kidneys is diverse. Antenatal USS should assess renal architecture, renal size, associated abnormalities and amniotic fluid volume. Inherited diseases that cause hyperechogenic foetal kidneys include autosomal dominant and autosomal recessive polycystic kidney diseases, cystic dysplasia, Trisomy 13 and 18, Meckel-Gruber syndrome, Bardet-Biedl syndrome [9] and other ciliopathies. Mutations in TCF2 encoding hepatocyte nuclear factor 1-beta is a more recently recognized important cause of antenatal hyperechogenic kidneys [10]. In our case, the kidneys' size remained within normal limits until 22 weeks gestation. It was not until 26 weeks gestation that enlarged hyperechogenic kidneys were observed, which is a typical age at which to diagnose hyperechogenic kidneys due to the timing of systematic USS examinations performed in the second and third trimesters. Second-trimester

Table 1. Antenatal ultrasound findings in foetus with suspected RTD

Gestation (weeks)	Amniotic fluid	Kidneys	Lungs	Brain	Heart	Liver	Limbs	Facial features	Other features
13	Normal	Normal	Normal	Normal	N/A	N/A	Normal	Normal	Nuchal translucency normal
16	Normal	Normal	Normal	Normal	N/A	Normal	Normal	Normal	
19	Oligohydramnios	Normal	Normal	Dolichocephaly	Normal	Normal	Normal	Normal	
22	Oligohydramnios	Normal	Normal	Dolichocephaly	Normal	Normal	Normal	Normal	Small bladder
26	Anhydramnios	Enlarged	Small	Dolichocephaly	Normal	Normal	Normal	Normal	

N/A, not available.

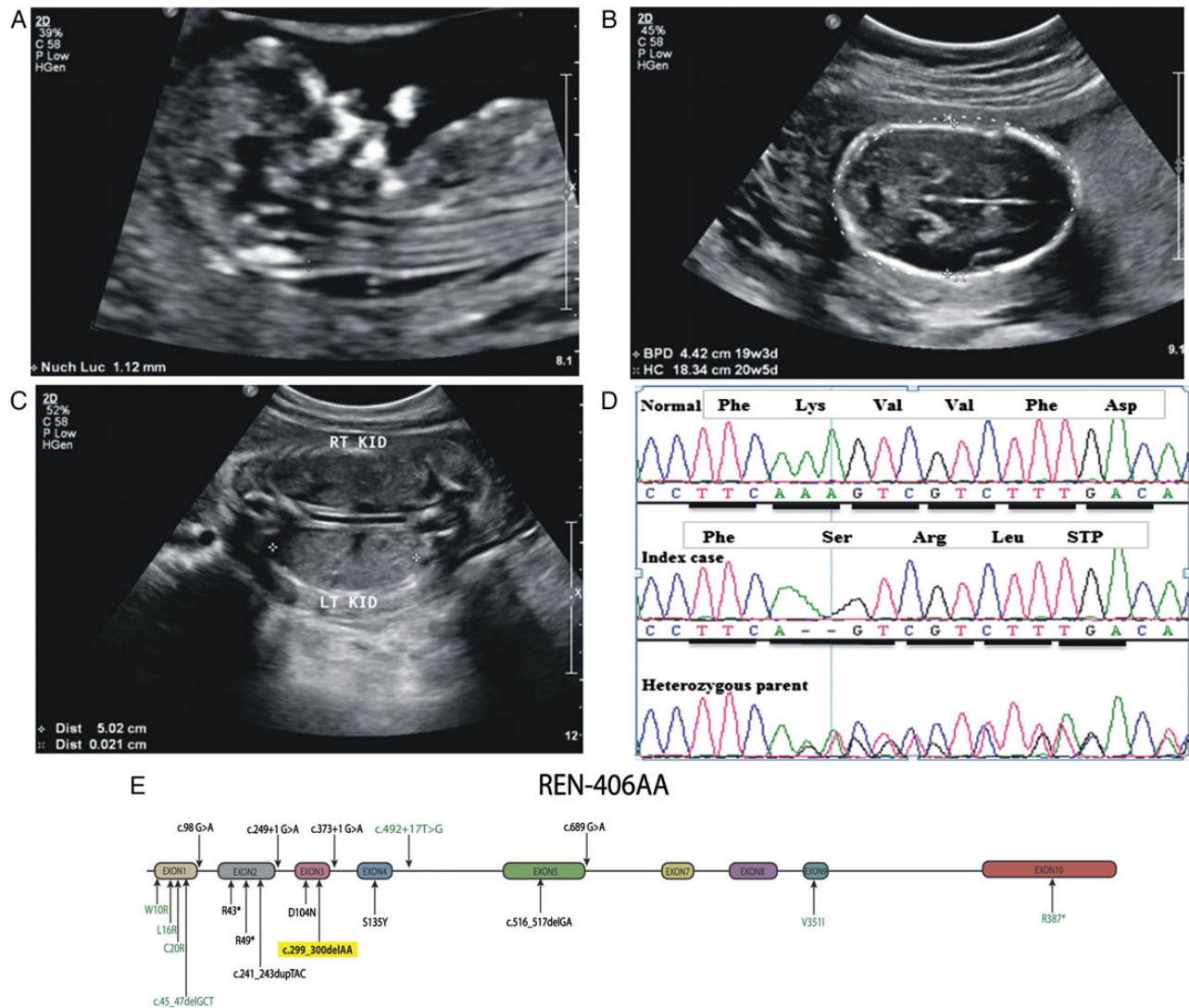


Fig. 1. Prenatal ultrasound images of affected foetus and exon map of *REN* mutations. (A) Thirteen weeks gestation foetus (sagittal view) with a normal nuchal translucency (measuring 1.1 mm). (B) Twenty-two weeks gestation foetus (transverse view) with head showing abnormal shape (dolichocephaly). (C) Twenty-six weeks gestation foetus (coronal view of the abdomen) showing bilateral enlarged, hyperechogenic kidneys. (D) Sequence chromatograms of affected foetus (index case) with one parent and a wild-type control. Foetus has a homozygous small deletion in *REN* (c.299_300delAAA; p.Lys100Serfs*4) which is present heterozygously in parental DNA. (E) Exon map of *REN* and position of known and novel mutations. *REN* gene and exons 1–10 are shown in schematic form. Mutations associated with RTD are shown in black, whilst mutations associated with *REN*-related renal disease (which exclusively affect the peptide signal sequence encoded by exon 1) are shown in green. The novel mutation associated with this study is highlighted in yellow.

oligohydramnios had a poor prognosis in the cases we describe. Third-trimester USS revealed enlarged kidneys and a narrow thorax.

RTD is characterized histologically by an absence of proximal tubular differentiation [11]. Prenatal death and lack of autopsy diagnosis may explain scarce reports in the Arab world. According to the Centre for Arab Genomics Studies database (<http://www.cags.org.ae/>), there are only two reports of familial RTD, one from Palestine [12] and the other from Qatar [13]. Molecular genetic diagnosis has become more accessible with the advent of next-generation sequencing. WES allowed the identification of the causative gene in the family presented. The frameshift mutation c.299_300delAAA identified in *REN* is predicted to cause a truncated protein and may cause nonsense-mediated mRNA decay. A variety of compound heterozygous

and homozygous mutations have been reported to cause RTD (Figure 1E).

In conclusion, by using prenatal USS imaging and WES, we describe a novel homozygous *REN* mutation as the underlying molecular genetic cause of recurrent prenatal death associated with RTD in a consanguineous Saudi Arabian family.

Acknowledgements

We thank all family members for participating in the study. We also thank all team members at Saudi Human Genome project for help in performing exome sequencing. Special thanks to Ms Ghadah A. Al Dakheel for preparing figures for publication. J.A. S. is supported by the Northern Counties Kidney Research Fund and the Medical Research Council (MR/M012212/1).

Conflict of interest statement

None declared.

References

- Gribouval O, Gonzales M, Neuhaus T et al. Mutations in genes in the renin-angiotensin system are associated with autosomal recessive renal tubular dysgenesis. *Nat Gen* 2005; 37: 964–968
- Gribouval O, Moriniere V, Pawtowski A et al. Spectrum of mutations in the renin-angiotensin system genes in autosomal recessive renal tubular dysgenesis. *Hum Mutat* 2012; 33: 316–326
- Uematsu M, Sakamoto O, Nishio T et al. A case surviving for over a year of renal tubular dysgenesis with compound heterozygous angiotensinogen gene mutations. *Am J Med Genet A* 2006; 140: 2355–2360
- Allanson JE, Hunter AG, Mettler GS et al. Renal tubular dysgenesis: a not uncommon autosomal recessive syndrome: a review. *Am J Med Genet* 1992; 43: 811–814
- Kumar D, Moss G, Primhak R et al. Congenital renal tubular dysplasia and skull ossification defects similar to teratogenic effects of angiotensin converting enzyme (ACE) inhibitors. *J Med Genet* 1997; 34: 541–545
- Beck BB, Trachtman H, Gitman M et al. Autosomal dominant mutation in the signal peptide of renin in a kindred with anemia, hyperuricemia, and CKD. *Am J Kidney Dis* 2011; 58: 821–825
- Eckardt KU, Alper SL, Antignac C et al. Autosomal dominant tubulointerstitial kidney disease: diagnosis, classification, and management—a KDIGO consensus report. *Kidney Int* 2015; 88: 676–683
- Hill LM, Hill LA. Renal tubular dysgenesis: a cause of second trimester oligohydramnios. *J Ultrasound Med* 1997; 16: 627–630
- Tsatsaris V, Gagnadoux MF, Aubry MC et al. Prenatal diagnosis of bilateral isolated fetal hyperechogenic kidneys. Is it possible to predict long term outcome? *BJOG* 2002; 109: 1388–1393
- Decramer S, Parant O, Beaufile S et al. Anomalies of the TCF2 gene are the main cause of fetal bilateral hyperechogenic kidneys. *J Am Soc Nephrol* 2007; 18: 923–933
- Schwartz BR, Lage JM, Pober BR et al. Isolated congenital renal tubular immaturity in siblings. *Hum Pathol* 1986; 17: 1259–1263
- Ariel I, Wells TR, Landing BH et al. Familial renal tubular dysgenesis: a disorder not isolated to proximal convoluted tubules. *Pediatr Pathol Lab Med* 1995; 15: 915–922
- Akl K, Hamad B. Pediatric kidney disease in Qatar. *J Bahrain Med Soc* 2004; 6: 9–17