

Case Report

Solitary *Aggregatibacter aphrophilus* tectal abscess in an immunocompetent patient

Tianyi Niu, Alexander M. Tucker, Daniel T. Nagasawa, Marvin Bergsneider

Department of Neurosurgery, David Geffen School of Medicine, University of California, Los Angeles, California, USA

E-mail: *Tianyi Niu - tniu@mednet.ucla.edu; Alexander M. Tucker - atucker@mednet.ucla.edu; Daniel T. Nagasawa - dnagasawa@mednet.ucla.edu; Marvin Bergsneider - mbergsneider@mednet.ucla.edu

*Corresponding author

Received: 19 June 17 Accepted: 15 August 17 Published: 24 October 17

Abstract

Background: A solitary abscess involving the tectum, specifically by *Aggregatibacter aphrophilus*, is an extremely rare condition with no known reported cases to date.

Case Description: Here, we present a case of isolated solitary midbrain tectum abscess in an immunocompetent 28-year-old male who was empirically diagnosed as a primary tectal tumor at an outside hospital where he also underwent placement of a ventriculoperitoneal shunt (VPS) for obstructive hydrocephalus. Eight weeks later he was readmitted with a VPS infection. He was transferred to our institution where the VPS was removed and he was started on broad-spectrum antibiotics. Cerebrospinal fluid (CSF) culture revealed *A. aphrophilus*. All other workup was negative for infectious etiologies. The tectal lesion completely resolved after 15 weeks of intravenous ceftriaxone without surgical aspiration.

Conclusion: We suggest that an empiric diagnosis of tectal glioma should be made with caution for a ring-enhancing mass. CSF should be routinely cultured at the time of operative diversion if abscess is a possibility.

Key Words: *Aggregatibacter aphrophilus*, brainstem abscess, differential diagnosis, solitary brain abscess, tectum

Access this article online

Website:www.surgicalneurologyint.com**DOI:**

10.4103/sni.sni_211_17

Quick Response Code:

INTRODUCTION

Solitary brainstem abscess is a rare diagnosis, with an incidence of less than 0.5% at large tertiary referral centers. Risk factors include right-left heart shunting, immunosuppression, congenital heart disease, and endocarditis, with the causative organism most commonly identified as *Streptococcus* or *Staphylococcus*.^[2] We present a case of an isolated solitary *Aggregatibacter aphrophilus* brainstem abscess initially misdiagnosed as a glioma.

CASE REPORT

An immunocompetent 28-year-old male was empirically diagnosed with a primary tectal tumor at an outside

hospital; his history was negative for intravenous drug use or significant systemic bacterial infection. He presented initially with progressive intermittent headache for more than 6 months. Initial magnetic resonance imaging (MRI)

This is an open access article distributed under the terms of the Creative Commons Attribution-NonCommercial-ShareAlike 3.0 License, which allows others to remix, tweak, and build upon the work non-commercially, as long as the author is credited and the new creations are licensed under the identical terms.

For reprints contact: reprints@medknow.com

How to cite this article: Niu T, Tucker AM, Nagasawa DT, Bergsneider M. Solitary *Aggregatibacter aphrophilus* tectal abscess in an immunocompetent patient. *Surg Neurol Int* 2017;8:257.

<http://surgicalneurologyint.com/Solitary-Aggregatibacter-aphrophilus-tectal-abscess-in-an-immunocompetent-patient/>

showed a 10 mm × 9 mm left midbrain tectum ring-enhancing lesion with associated surrounding edema and mild hydrocephalus [Figure 1]. At the other hospital, he underwent placement of a ventriculoperitoneal shunt (VPS) for obstructive hydrocephalus.

Eight weeks later, he started to have worsening headache, nausea, and intermittent vomiting. He was readmitted with a VPS infection and an abdominal pseudocyst. He was transferred to our institution where the VPS was removed, an external ventriculostomy was placed, and he was started on intravenous ceftriaxone and vancomycin. Cerebrospinal fluid (CSF) profile showed elevated white blood cell (WBC) count of 482 with lymphocyte predominance, suggesting a chronic infection; CSF culture revealed *A. aphrophilus*. His other workup including blood cultures and transthoracic echocardiogram were negative for infectious etiologies. He slowly improved with antibiotic treatment and was weaned off the ventriculostomy after 14 days, without any subsequent recurrence of hydrocephalus. Vancomycin was stopped after 10 days when the culture finalized *A. aphrophilus* sensitive to ceftriaxone. The tectal lesion completely resolved after 15 weeks of intravenous ceftriaxone [Figure 2]. At the 4-month follow-up, he had no headache or any other clinical sequelae.

DISCUSSION

Solitary brainstem abscess is a rare event,^[2] typically resulting from hematogenous spread in individuals who are immunosuppressed or due to intravenous drug abuse. These may also develop after direct inoculation following neurosurgical procedures, trauma, or contiguous spread from infectious foci around the brain or meninges.^[1,4] Predisposing risk factors can both increase a clinician's

index of suspicion for brain abscess but may also suggest a particular causative organism. These risk factors include immunosuppression (*Toxoplasma gondii*, *Cryptococcus neoformans*, *Listeria monocytogenes*, and *Mycobacterium tuberculosis*), inoculation of brain parenchyma via trauma or surgery (*Staphylococcus aureus* and *Staphylococcus epidermidis*), and congenital heart disease or endocarditis (*Streptococcus*, *Staphylococcus*, and mixed infections). In addition, 90% of brain abscesses identified in patients following solid organ transplant are found to be fungal. In case of bacterial abscesses, 27% are polymicrobial. The neurologic sequelae are varied and include headache, focal neurological deficit, decreased consciousness, or seizures. In case of tectal abscesses, occlusion of the cerebral aqueduct can result in life-threatening hydrocephalus and should be treated immediately with CSF diversion. Other causes of serious morbidity can be related to direct mass effect of the abscess, surrounding edema, and abscess rupture with or without ventriculitis.

Differential diagnosis of enhancing tectal lesions includes abscess, primary brain tumors, lymphoma, or metastatic disease. MRI imaging, particularly diffusion-weighted imaging, can accurately diagnosis brain abscess in a majority of cases.^[6] However, definitive diagnosis, speciation, and subsequent antibiotic treatment require culturing biopsy tissue, blood, or CSF.

Although definitive treatment remains controversial, ranging from antibiotics alone^[1] to open aspiration,^[3] it typically begins with broad-spectrum antibiotics until a more focused regimen can be formulated based on microbiological testing. Antibiotic treatment duration commonly lasts for 6–8 weeks with serial neurologic examinations and imaging. Yet, for patients with abscesses greater than 2 cm, diagnostic ambiguity, or a poor clinical presentation, surgical intervention, especially stereotactic aspiration is typically preferred; particularly if the brainstem lesion is superficial.^[3]

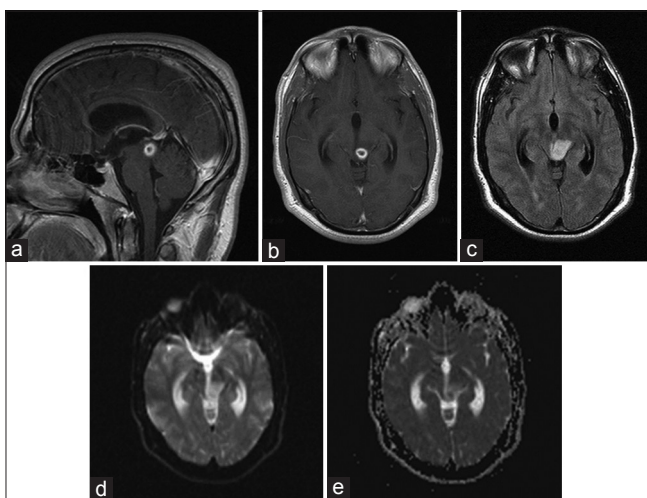


Figure 1: Initial MRI showing tectal ring enhancing mass. (a) Sagittal T1 with contrast; (b) Axial T1 with contrast; (c) Axial FLAIR showing surrounding edema; (d) Axial DWI; (e) Axial ADC

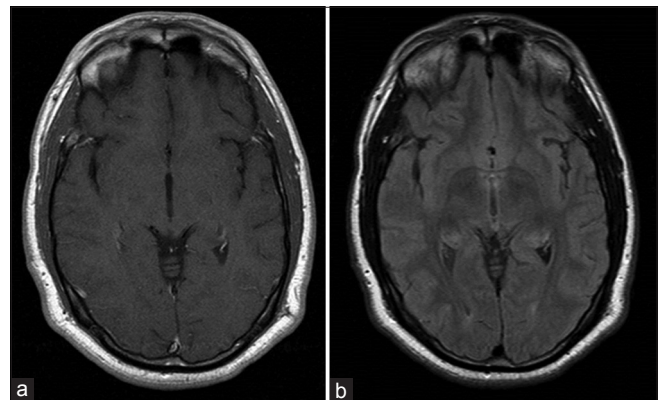


Figure 2: MRI after antibiotic treatment, 15 weeks post-discharge showing complete resolution of the previous tectal mass, without evidence of edema or hydrocephalus. (a) Axial T1 with contrast; (b) Axial FLAIR

In our case, *A. aphrophilus* was isolated from CSF. It is a fastidious, gram-negative, oxidase-negative, catalase-negative coccobacillus.^[1] Identification can be challenging as it takes up to 14 days in culture to show positivity. *A. aphrophilus* is typically believed to be of low pathogenicity, is found in oral flora, and is a member of the *Haemophilus*, *Aggregatibacter*, *Cardiobacterium*, *Eikenella*, *Kingella* (HACEK) group that is often implicated in community-acquired infectious endocarditis.^[4] While brain abscess remains rare,^[5] our case is the first report of a solitary tectal brainstem *A. aphrophilus* abscess. Treatment is typically guided by sensitivities discovered after culture.

CONCLUSION

A high index of suspicion for brain abscess should be considered in a patient with an enhancing tectal lesion, particularly if the DWI shows homogenous restricted diffusion. Diagnosis involves microbiologic culture, which should be kept for at least 14 days to avoid missing slow-growing bacteria such as *A. aphrophilus*. For tectal lesions, hydrocephalus must be promptly treated with CSF diversion. While definitive treatment remains controversial, initial management typically involves antibiotics, often third generation cephalosporins with adequate central nervous system penetrance such as

ceftriaxone, for 6–8 weeks. Patients with large lesions, poor clinical status, or an unknown diagnosis may be considered for surgical drainage and subsequent culture speciation.

Financial support and sponsorship

Nil.

Conflicts of interest

There are no conflicts of interest.

REFERENCES

1. Bogdan M, Zujic Atalic V, Hecimovic I, Vukovic D. Brain abscess due to *Aggregatibacter aphrophilus* and *Bacteroides uniformis*. *Acta Med Acad* 2015;44:181-5.
2. Fulgham JR, Wijidicks EF, Wright AJ. Cure of a solitary brainstem abscess with antibiotic therapy: Case report. *Neurology* 1996;46:1451-4.
3. Hamamoto Filho PT, Zanini MA. Brainstem abscess of undetermined origin: Microsurgical drainage and brief antibiotic therapy. *Sao Paulo Med J* 2014;132:121-4.
4. Jung GW, Parkins MD, Church D. Pyogenic ventriculitis complicating *Aggregatibacter aphrophilus* infective endocarditis: A case report and literature review. *Can J Infect Dis Med Microbiol* 2009;20:e107-9.
5. Maraki S, Papadakis IS, Chronakis E, Panagopoulos D, Vakis A. *Aggregatibacter aphrophilus* brain abscess secondary to primary tooth extraction: Case report and literature review. *J Microbiol Immunol Infect*, 2016;49:119-22.
6. Reddy JS, Mishra AM, Behari S, Husain M, Gupta V, Rastogi M, et al. The role of diffusion-weighted imaging in the differential diagnosis of intracranial cystic mass lesions: A report of 147 lesions. *Surg Neurol* 2006;66:246-50; discussion 250-1.