

Concurrent presentation of cryptococcal meningoencephalitis and systemic lupus erythematosus

Masami Matsumura · Rika Kawamura ·
Ryo Inoue · Kazunori Yamada · Mitsuhiro Kawano ·
Masakazu Yamagishi

Received: 27 August 2010 / Accepted: 1 November 2010 / Published online: 29 December 2010
© Japan College of Rheumatology 2010

Abstract Cryptococcal meningitis is a recognized complication of systemic lupus erythematosus (SLE), with high mortality rates, particularly in those treated with immunosuppressive agents. We describe a patient diagnosed simultaneously with cryptococcal meningoencephalitis and SLE and reviewed four similar cases reported in the literature. In our case, profound low CD4 lymphocyte count and low complement levels were observed. The patient was treated with prednisolone, fluconazole, and 5-flucytosine and evinced good clinical improvement. This case suggests that intrinsic immunological abnormality related to SLE predisposed to opportunistic infections.

Keywords Cryptococcal meningoencephalitis ·
Intrinsic immunological abnormality ·
Systemic lupus erythematosus

Introduction

Despite a significant increase in the survival rate of patients with systemic lupus erythematosus (SLE), infection is a significant cause of morbidity and mortality [1]. The risk factors of infections include immunosuppressive therapies and some manifestations of active SLE itself [2–4]. The central nervous system (CNS) is rare organ system of infections [3], and cryptococcal meningoencephalitis has been described as one of life-threatening causes of CNS infection in patients with SLE [5, 6]. We describe a rare case of simultaneous presentation of cryptococcal meningoencephalitis and SLE. Opportunistic infections can present concurrently with new-onset SLE.

Case report

A 47-year-old man was admitted with a 2-week history of fever, headache, general malaise, and anorexia. He had been well until 10 months before admission when he began to have wrist, knee, and ankle arthritis, which persisted for 4 months and resolved spontaneously. Two weeks prior to presentation, he noted fever of 37–37.8°C in the evenings and lost 2 kg in weight over those 2 weeks. On physical examination, his temperature was 37.2°C, blood pressure 112/62 mmHg, and pulse 60 bpm. Neither skin rash nor oral ulcer was noted; his chest was clear, with no murmurs or rubs. No abdominal tenderness was present, and the liver and spleen could not be palpated. Arthritis was not observed, and meningismus was absent. Other neurological examination was normal. Laboratory values were as follows: leukocytes 3,000/μl; lymphocytes 249/μl; platelets 205,000/μl; serum immunoglobulin G (IgG) 2,520 mg/dl, IgA 140 mg/dl, and IgM 60 mg/dl; total functional

M. Matsumura (✉)
Research Center for Medical Education, Kanazawa University
Graduate School of Medicine, Takara-machi 13-1,
Kanazawa, Ishikawa 920-8641, Japan
e-mail: mmatsu@spacelan.ne.jp

R. Kawamura · R. Inoue · K. Yamada · M. Kawano
Division of Rheumatology, Department of Internal Medicine,
Kanazawa University Graduate School of Medicine,
Kanazawa, Japan

M. Yamagishi
Division of Cardiology, Department of Internal Medicine,
Kanazawa University Graduate School of Medicine,
Kanazawa, Japan

hemolytic complement (CH50) 14 U/ml (normal 32–47 U/ml); C3 56 mg/dl (normal 65–135 mg/dl); C4 5 mg/dl (normal 13–35 mg/dl). Liver enzymes, blood urea nitrogen (BUN), serum creatinine (SCr), serum electrolytes, and urinalysis were all normal. Serum antinuclear antibodies were positive at a titer of 1:2,560, with peripheral pattern. Serum antibodies to double-stranded DNA titer were markedly elevated at 165 IU/ml (normal <12 IU/ml). SLE was diagnosed, and Systemic Lupus Erythematosus Disease Activity Index (SLEDAI) [7] was 5. Low complement, increased DNA binding, and leukopenia were descriptors.

On hospital day 1, loxoprofen sodium (120 mg daily) was prescribed for headache and was somewhat effective. He had been afebrile after admission, but anorexia persisted. On hospital day 8, he complained of neck pain. The next day, hallucination, apraxia, and agnosia appeared. Meningismus was noted. Magnetic resonance imaging (MRI) of the brain with gadolinium contrast showed interhemispheric and occipital meningeal enhancement suggesting adjacent meningitis (Fig. 1). Cerebrospinal fluid (CSF) examination showed 212 white blood cells/ μ l (neutrophils 2, lymphocytes 210, unclassified 29), glucose 60 mg/dl, and protein 146 mg/dl. An India-ink preparation of the CSF revealed mucinous capsule of cryptococcus as a translucent halo surrounding budding yeast. A latex-agglutination test was positive for cryptococcal antigen at a dilution of 1:2,048, and CFS culture grew *Cryptococcus neoformans*. Cryptococcal meningoencephalitis was diagnosed based on clinical manifestations, MRI findings, and

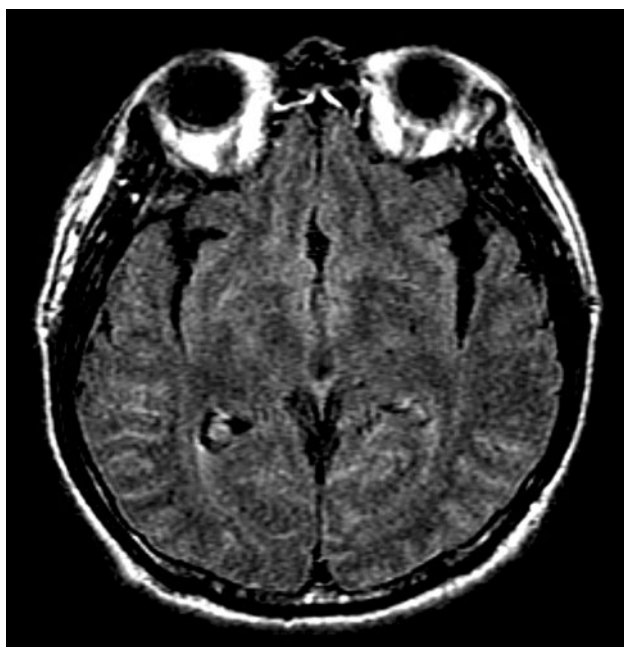


Fig. 1 Brain magnetic resonance imaging (fast, low-angle inversion recovery sequences). Postcontrast view showing enhanced interhemispheric and occipital meninges

CSF examinations. Human immunodeficiency virus (HIV) serology was negative, but lymphocyte and CD4 lymphocyte counts were 200 and 33/ μ l, respectively. CD4/CD8 was 0.47 (normal 0.69–1.74). He was treated with intravenously administered fluconazole (800 mg daily) and 5-flucytosine orally (8,000 mg daily). Prednisolone (30 mg daily) was administered concomitantly to treat SLE. On hospital day 15, headache, neck pain, hallucination, apraxia, agnosia, and meningismus had disappeared completely. After 8-weeks, fluconazole IV was changed to oral administration (400 mg daily). On hospital day 100, CSF examination showed 89 white blood cells/ μ l, (neutrophils 1, lymphocytes 88, and unclassified 1). Cryptococcus was still positive on India-ink staining. However, CFS culture did not grow *C. neoformans*. His lymphocytes, CD4 lymphocytes, CH50, C3, and C4 recovered to 1,100/ μ l, 176/ μ l, 42 U/ml, 99 mg/dl, and 14 mg/dl, respectively. On hospital day 106, he was discharged with good clinical improvement. Oral 5-flucytosine was discontinued at that time. Prednisolone had been tapered to 10 mg daily. He continued taking fluconazole orally (400 mg daily) as maintenance therapy for 12 months. He has remained well for more than 3 years without relapses.

Discussion

The spectrum of infections reported in patients with SLE varies. Gram-positive cocci, gram-negative bacilli, *Mycobacterium tuberculosis*, *Candida albicans*, *C. neoformans*, *Pneumocystis jirovecii*, cytomegalovirus, Epstein–Barr virus, and herpes virus have all been implicated [2–6, 8]. Use of steroids ever [3] and disease activity [2, 4] are significantly associated with infections. SLEDAI score [7] of 4 or higher in outpatients and >8 in hospitalized patients are significant predicting factors for infection development [2, 4]. Death in which infection is the primary cause is significantly associated with the peak corticosteroid dose received as treatment [9]. The major organ systems of infections often include skin, genitourinary, and lung [2–4]. CNS infections are rare in patients with SLE. Gladman et al. [3] reported that CNS infections consisted of four (2.7%) of 148 infection episodes in 93 patients with SLE. Clinical manifestations of CNS infections including headache, cognitive disorder, and acute confusional state, and seizure can mimic manifestations of CNS lupus. CNS infections should be carefully excluded when a patient with SLE displays CNS manifestations, even prior to the initiation of immunosuppressive therapies.

Cryptococcal meningoencephalitis had been described as a rare complication of SLE [5]. However, Hung et al. [6] reported that cryptococcal meningoencephalitis played the major role in CNS infections of patients with SLE. They

retrospectively reviewed 17 cases of CNS infections during a 20-year follow up of 3,165 patients with SLE, and ten (59%) of 17 patients had been diagnosed with cryptococcal meningoencephalitis. The average SLEDAI score in these ten patients was 4.3. Kim et al. [10] reported four cases of cryptococcus meningoencephalitis during a 15-year follow up of 1,155 patients with SLE. SLEDAI scores of these four cases were 8 or higher. The outcome of these patients with cryptococcal meningoencephalitis was uniformly poor. Mortality rates were as high as 40–50% despite antifungal therapy [5, 6]. Headache, fever, diplopia, nausea, and vomiting were symptoms for nonimmunosuppressed patients with CNS cryptococcosis at presentation [11, 12]. Sivalingam et al. [13] reported that normal neurological and CSF examinations did not exclude cryptococcal meningoencephalitis in a patient with SLE. Cryptococcal meningoencephalitis should be considered as a differential in SLE patients presenting even nonspecific symptoms of headaches, fevers, nausea, or vomiting.

Most patients previously reported with cryptococcal meningoencephalitis had received corticosteroid administration when cryptococcal meningoencephalitis was diagnosed [5]. To our knowledge, there have been four previous reports of a patient who developed cryptococcal meningoencephalitis simultaneously with the diagnosis of SLE or prior to immunosuppressive therapy (Table 1) [6, 14–16]. Mok et al. [14] reported that the first case of cryptococcal meningoencephalitis complicating SLE without immunosuppressive therapy. Their case revealed normal CD4 lymphocyte count and low complement levels. The second reported case showed profound hypocomplementemia and lupus nephritis [15]. Hung et al. [6] reported that one of ten patients had cryptococcus meningoencephalitis simultaneously with initial diagnosis of SLE. Chen et al. [16] reported 15 cases with invasive fungal infection in SLE. Their case series included one case of cryptococcal meningoencephalitis complicating SLE without prednisolone administration. All cases were women, and SLEDAI scores in three cases were 4, 7, and 11, respectively (Table 1). Mortality rate was high at 50%.

It is difficult to identify the intrinsic immunological abnormality as the risk for cryptococcal meningoencephalitis development in SLE patients other than immunosuppressive therapy. Host resistance to *C. neoformans* depends primarily on cell-mediated immunity. CD4 lymphocytes, cytotoxic lymphocytes, natural killer cells, activated macrophages, and various cytokines including interleukin 12, granulocyte–macrophage colony-stimulating factor, and interferon- γ are implicated in successful host responses to *C. neoformans* [17]. Decreased CD4 lymphocyte count, natural killer cell activity, and T-cell cytotoxicity are related to SLE clinical activity [18]. In this case, immunosuppressive agents were not administered at cryptococcal meningoencephalitis diagnosis, despite which the patient's CD4 lymphocyte count and complement levels were low. The profound, progressive loss of CD4 lymphocyte in HIV patients correlates with the appearance of cryptococcal meningoencephalitis, with the highest risk found when CD4 lymphocyte counts fall $<100/\mu\text{l}$ [17]. However, CD4 lymphocyte count was normal in the first case report of a patient who developed cryptococcal meningoencephalitis simultaneously with the diagnosis of SLE (Table 1) [14]. Godeau et al. [8] reported that two of six SLE patients had *P. jiroveci* pneumonia prior to corticosteroid administration. Lymphocyte count of one of these two patients was low, at $180/\mu\text{l}$. However, the other patient was not lymphocytopenic. Ecevit et al. [11] described nine nonimmunosuppressed patients with CNS cryptococcosis. Pappas et al. [19] reported that 47 of 157 HIV-negative patients had cryptococcus meningoencephalitis without underlying conditions. Zonios et al. [12] reviewed 53 patients with cryptococcosis and idiopathic CD4 lymphocytopenia. Idiopathic CD4 lymphocytopenia is a syndrome defined by the repeated presence of a CD4 lymphocyte count $<300/\mu\text{l}$ or $<20\%$ of total T cells, with no evidence of HIV infection and no condition that might cause low CD4. Selective defect in lymphocyte responsiveness to *C. neoformans* might explain cryptococcus meningoencephalitis in otherwise normal hosts. CD4 lymphocyte count should be measured in patients with cryptococcus meningoencephalitis without underlying conditions. Complement

Table 1 Clinical characteristics of patients with cryptococcal meningoencephalitis at the diagnosis of systemic lupus erythematosus (SLE) or prior to immunosuppressive therapy

Patient	Ref.	Age/sex	CD4 count ($/\mu\text{l}$)	C3 (mg/dl)	C4 (mg/dl)	SLEDAI	Antifungal therapy	Outcome
1	[14]	48/F	Normal	23	9	4 ^a	AMB/5-FC/Flu	Survived
2	[15]	30/F	ND	24	3	LN	AMB/Flu	Survived
3	[6]	56/F	ND	ND	ND	7	AMB/Flu	Died
4	[16]	ND/F	ND	ND	ND	11	ND	Died
5	This case	47/M	33	56	5	5	5-FC/Flu	Survived

Ref. reference, ND no data was available, LN lupus nephritis, AMB amphotericin B, 5-FC flucytosine, Flu fluconazole, SLEDAI Systemic Lupus Erythematosus Disease Activity Index

^a Calculated based on case description

levels in two previous case reports and in our case were low (Table 1) [14, 15]. Complement has been shown to be an opsonic requirement for in vitro phagocytosis of *C. neoformans* by rat macrophages [20]. Shapiro et al. [21] reported the importance of C3 in defense against cryptococcus infection by demonstrating increased susceptibility for genetically deficient C3 knockout mice. Low CD4 lymphocyte count and/or complement levels might contribute to the development of opportunistic fungal infection in patients with SLE even prior to immunosuppressive therapy.

The recommended therapy for cryptococcal meningoencephalitis in HIV-negative and nontransplant patients includes induction therapy with amphotericin B deoxycholate (0.7–1.0 mg/kg daily) plus flucytosine (100 mg/kg daily) for at least 4 weeks, followed by a consolidation therapy with fluconazole (400–800 mg daily) for 8 weeks and another 6–12 months of reduced-dose of fluconazole (200 mg daily) for maintenance therapy [22]. Nussbaum et al. [23] reported that combination flucytosine and high-dose fluconazole was an optimal regimen for treating cryptococcal meningitis in HIV-seropositive patients. In this case, fluconazole plus flucytosine administration was successful. If toxic side effects of amphotericin B develop, fluconazole plus flucytosine regimen might be considered.

Our case represents the fifth case report of a patient diagnosed with cryptococcal meningoencephalitis concurrent with the diagnosis of SLE. Intrinsic immunological abnormality of SLE itself can predispose to opportunistic infections, even in the absence of immunosuppressive therapies. However, additional case experience is required to confirm their relationship.

Acknowledgment We thank John Gelblum for critical reading of the manuscript.

Conflict of interest None.

References

1. Cervera R, Khamashta MA, Font J, Sebastiani GD, Gil A, Lavilla P, et al. Morbidity and mortality in systemic lupus erythematosus during a 5-year period. *Medicine*. 1999;78:165–75.
2. Zonana-Nacach A, Camargo-Coronel A, Yañez P, Sánchez L, Jimenez-Balderas FJ, Fraga A. Infections in outpatients with systemic lupus erythematosus: a prospective study. *Lupus*. 2001;10:505–10.
3. Gladman DD, Hussain F, Ibañez D, Urowitz MB. The nature and outcome of infection in systemic lupus erythematosus. *Lupus*. 2002;11:234–9.
4. Duffy KNW, Duffy CM, Gladman DD. Infection and disease activity in systemic lupus erythematosus: a review of hospitalized patients. *J Rheumatol*. 1991;18:1180–4.
5. Zimmermann B, Spiegel M, Lally EV. Cryptococcal meningitis in systemic lupus erythematosus. *Semin Arthritis Rheum*. 1992;22:18–24.
6. Hung JJ, Ou LS, Lee WI, Huang JL. Central nervous system infections in patients with systemic lupus erythematosus. *J Rheumatol*. 2005;32:40–3.
7. Bombardier C, Gladman DD, Urowitz MB, Caron D, Chang CH, Austin A, et al. Derivation of the SLEDAI. A disease activity index for lupus patients. *Arthritis Rheum*. 1992;35:630–40.
8. Godeau B, Coutant-Perronne V, Le Thi Huong D, Guillevin L, Magadur G, De Bandt M, et al. *Pneumocystis carinii* pneumonia in the course of connective tissue disease: report of 34 cases. *J Rheumatol*. 1994;21:246–51.
9. Rosner S, Ginzler EM, Diamond HS, Weiner M, Schlesinger M, Fries JF, et al. A multicenter study of outcome in systemic lupus erythematosus II. Causes of death. *Arthritis Rheum*. 1982;25:612–7.
10. Kim HJ, Park YJ, Kim WU, Park SH, Cho CS. Invasive fungal infections in patients with systemic lupus erythematosus: experience from affiliated hospitals of Catholic University of Korea. *Lupus*. 2009;18:661–6.
11. Ecevit IZ, Clancy CJ, Schmalfuss IM, Nguyen MH. The poor prognosis of central nervous system cryptococcosis among non-immunosuppressed patients: a call for better disease recognition and evaluation of adjuncts to antifungal therapy. *Clin Infect Dis*. 2006;42:1443–7.
12. Zonios DI, Falloon J, Huang CY, Chaitt D, Bennett JE. Cryptococcosis and idiopathic CD4 lymphocytopenia. *Medicine*. 2007;86:78–92.
13. Sivalingam SK, Saligram P, Natanasabapathy S, Paez AS. Covert cryptococcal meningitis in a patient with systemic lupus erythematosus. *J Emerg Med*. 2009 [Epub ahead of print].
14. Mok CC, Lau CS, Yuen KY. Cryptococcal meningitis presenting concurrently with systemic lupus erythematosus. *Clin Exp Rheumatol*. 1998;16:169–71.
15. Huston KK, Gelber AC. Simultaneous presentation of cryptococcal meningitis and lupus nephritis. *J Rheumatol*. 2005;32:2501–2.
16. Chen HS, Tsai WP, Leu HS, Ho HH, Liou LB. Invasive fungal infection in systemic lupus erythematosus: an analysis of 15 cases and a literature review. *Rheumatology*. 2007;46:539–44.
17. Gottfredsson M, Perfect JR. Fungal meningitis. *Semin Neurol*. 2000;20:307–22.
18. Horwitz DA, Gray JD. The interaction of T-cells with cells of the innate immune system and B cells in the pathogenesis of SLE. In: Wallace DJ, Hahn BH, editors. *Dubois' lupus erythematosus*, 7th ed. Philadelphia: Lippincott Williams & Wilkins; 2007. p. 133–60.
19. Pappas PG, Perfect JR, Cloud GA, Larsen RA, Pankey GA, Lancaster DJ, et al. Cryptococcosis in human immunodeficiency virus-negative patients in the era of effective azole therapy. *Clin Infect Dis*. 2001;33:690–9.
20. Bolaños B, Mitchell TG. Phagocytosis of *Cryptococcus neoformans* by rat alveolar macrophages. *J Med Vet Mycol*. 1989;27:203–17.
21. Shapiro S, Beenhouwer DO, Feldmesser M, Taborda C, Carroll MC, Casadevall A, et al. Immunoglobulin G monoclonal antibodies to *Cryptococcus neoformans* protect mice deficient in complement component C3. *Infect Immun*. 2002;70:2598–604.
22. Perfect JR, Dismukes WE, Dromer F, Goldman DL, Graybill JR, Hamill RJ, et al. Clinical practice guidelines for the management of cryptococcal disease: 2010 update by the infectious diseases society of America. *Clin Infect Dis*. 2010;50:291–322.
23. Nussbaum JC, Jackson A, Namarika D, Phulusa J, Kenala J, Kanyemba C, et al. Combination flucytosine and high-dose fluconazole compared with fluconazole monotherapy for the treatment of cryptococcal meningitis: a randomized trial in Malawi. *Clin Infect Dis*. 2010;50:338–44.