



Case report

Unusually very late-onset new growth of intraocular retinoblastoma: A case report and review of literature



Yeshigeta Gelaw^{a, c, *}, Shoeib Mohamed Shoukry^{b, c}, Ihab Saad Othman^{b, c}

^a Department of Ophthalmology, College of Health Sciences, Jimma University, Jimma, Ethiopia

^b Departments of Ophthalmology, Kasr EL-Ainie Medical School, Cairo University, Cairo, Egypt

^c Eye and Laser World Hospital, Giza, Egypt

ARTICLE INFO

Article history:

Received 24 July 2016

Received in revised form

3 December 2016

Accepted 22 December 2016

Available online 28 December 2016

Keywords:

Retinoblastoma

Recurrent retinoblastoma

Transpupillary thermotherapy

Brachytherapy

Chemotherapy

Tumor regression

ABSTRACT

Purpose: To report a patient who presented with a very late-onset new growth of intraocular retinoblastoma, which occurred 11 years after the initial combined treatment.

Observations: A 12-year-old monophthalmic female patient presented with bilateral familial retinoblastoma showing new growth of intraocular tumor after 11 years of complete regression following combined local and systemic treatments. The new tumor growth was treated with diode laser transpupillary thermotherapy, ruthenium-106 plaque radiotherapy and adjuvant intravenous chemotherapy and the tumor regressed.

Conclusions and importance: Despite initial satisfactory treatment and complete regression of the tumor, very late-onset new growth of intraocular retinoblastoma can occur. Hence, life-long follow-up in all patients with retinoblastoma is warranted, given the risk for new tumor formation even later in life. To our knowledge, this is the first report of new growth of intraocular retinoblastoma after regression for more than a decade.

© 2016 The Authors. Published by Elsevier Inc. This is an open access article under the CC BY-NC-ND license (<http://creativecommons.org/licenses/by-nc-nd/4.0/>).

1. Introduction

Retinoblastoma is the most common primary ocular malignancy of early childhood and it represents about 4% of childhood cancer and less than 1% of all human cancers. The malignancy can occur in one or both eyes, and may be either unifocal or multifocal. All bilateral retinoblastoma are hereditary while only 10–15% of unilateral retinoblastomas are hereditary.^{1–3}

With modern diagnostic and treatment modalities, the cure rate of retinoblastoma has become excellent. However, survivors of hereditary retinoblastoma are at increased risk of developing recurrent tumors or second malignant neoplasms.^{1,4}

Bilateral tumor, initial large dimensions of tumor (Reese–Ellsworth grouping of I to III), tumor-associated subretinal and or vitreous seeds and younger age at presentation (median age, 2 months) are risk factors for intraocular recurrence or new growth, and tumor recurrence or focal regrowth usually occurs within months to few years after completion of the initial treatment.^{5–7}

We report a very late-onset new growth of intraocular retinoblastoma which occurred 11 years after the initial combined treatment. To our knowledge, this is the first report of new growth of intraocular retinoblastoma after regression for more than a decade.

2. Case report

A twelve-year-old girl, known bilateral familial retinoblastoma patient, presented to Eye and Laser World Hospital in Cairo with a complaint of mild redness and pain in the right eye. The patient was diagnosed to have bilateral retinoblastoma at 6 months of age. She was then treated with enucleation for severe intraocular retinoblastoma in the left eye (International Intraocular Retinoblastoma Classification (IIRC) Group D), and combined systemic chemotherapy and diode laser transpupillary thermotherapy (TTT) for moderate tumor in the right eye (IIRC Group B). Histopathology of the enucleated eye confirmed the diagnosis and the resection margin of the optic nerve was free of tumor. Patient received 6 cycles of two-drug regimen systemic chemotherapy using carboplatin and etoposide at interval of 3 weeks and seven cycles of TTT in the right eye commencing at the 3rd cycle of chemotherapy, and the tumor regressed completely leaving a flat scar or bare sclera

* Corresponding author. Jimma University, P.O.Box: 440, Jimma, Ethiopia.

E-mail addresses: dryeshi@yahoo.com (Y. Gelaw), shoeibshoukry@hotmail.com (S.M. Shoukry), ihabsaad@hotmail.com (I.S. Othman).

(type IV regression) (Fig. 1). Systemic diagnostic work-ups were non-revealing.

During her regular visits for the last eleven years after the initial diagnosis, she was followed with dilated indirect ophthalmoscopy and serial RetCam examinations at the interval of 4 weeks for the first one year to ensure ocular tumor control and every 3–6 months afterward. Her best corrected visual acuity was 1.0, with a normal anterior segment and posterior segment exams with same type IV tumor regression (Fig. 1) in the right eye. The left orbital socket has been clean and tumor free.

In her regular follow-up visit at the age of 12-year, fundus examination of the right eye showed an inferotemporal new tumor focus, away from the border of the regressed tumor foci, with subretinal seeds (Fig. 2A) and all the previous dilated fundus examinations under general anesthesia and with scleral depression did not show any regressed tumor foci (scar) in the area where the new tumor developed (Fig. 2B). The growth had exophytic-endophytic pattern measuring about $10 \times 10 \times 4$ disc diameters. The left orbital socket was within normal. With the diagnosis of very late-onset new growth of intraocular retinoblastoma, she was treated with 3 cycles of two-drug regimen systemic chemotherapy using carboplatin and etoposide at interval of 3 weeks, 4 cycles of TTT (commencing at the 3rd cycle of chemotherapy), ruthenium-106 plaque radiotherapy and supplementary cryotherapy; and the tumor regressed completely (Fig. 3). Currently, the patient is under close follow-up and observation at ophthalmic and general oncology centers.

3. Discussion

The overall goal of treatment of retinoblastoma is to sustain life, keep the eye, preserve vision, and enable cosmetically acceptable outcomes.^{1–3} However, the goal of the treatment is case dependent and varies based on the stage/grade of the tumor, laterality, systemic condition, metastatic potential and/or degree of distant metastasis, the risk of second cancers and the socioeconomic status of the patient.^{3,8}

In the 21st century, availability of advanced diagnostic facilities and treatment modalities has dramatically increased patient survival from around 5% to over 95% in developed countries, making retinoblastoma one of the successes in the treatment and cure of childhood cancers. However, a number of risk factors for metastasis and death have been identified, including optic nerve invasion, massive choroidal invasion, anterior segment rubeosis and tumor

extension to the anterior chamber.^{9,10} Clinically, suspicion of such risk factors usually necessitates enucleation.

Overall, systemic chemotherapy (chemoreduction) for retinoblastoma has significantly increased the survival rate, retention of eyeball and preservation of useful vision despite the critical problem of tumor recurrence months or even years after completion of chemotherapy. Shields CL and colleagues reported a recurrence in 62% of eyes by 5 years of follow-up among children who had retinoblastoma with subretinal seeds. Similarly, for those who had retinoblastoma with vitreous seeds, recurrence was noted in 50% of eyes at 5 years of follow-up.⁷

Appropriate and rational combined local and systemic therapy can effectively inhibit tumor, retain the eyeball and save the vision, significantly higher than single chemotherapy.^{11–13} Balwierz et al. reported eyeball retention rate of 67% after treatment with chemoreduction combined with different forms of focal therapies.¹³ However, new tumor growth or recurrence can still occur during or after such combined therapies.⁶ Tumor regrowth or recurrence is especially notable after discontinuation of chemoreduction.⁷

Lee TC et al. reported new tumor appearance in 47.4% of eyes treated with single agent carboplatin and focal therapy, with a mean time of 4.4 months to tumor appearance following treatment with carboplatin.¹⁴ Similarly, Shields CL et al. reported the occurrence of new tumors in 24% of treated eyes, most of which were in their very young age or had a positive family history of the disease.⁶

A very recent study on clinical efficacy and prognostic factors of chemoreduction combined with local therapy for advanced intraocular retinoblastoma also indicated that chemoreduction combined with TTT, cryotherapy or ¹²⁵I episcleral plaque brachytherapy could effectively control retinoblastoma in a short-term with eyeball retention rate of 81.82% and high recurrence rate of 41.18%.¹⁵

Overall, retinoblastoma recurrence or focal new growth usually occurs within few years after completion of the initial treatment, and rarely develops more than a year after treatment. Most literature reported recurrence or local growth within 2–4 months and maximum up to 4 years after the initial treatment,^{5–7,15} and recurrences and death usually occurs within the first 2 years after diagnosis and treatment.⁵ Most commonly new tumor growth or recurrence appeared in the eyes of children diagnosed at a very young age or who were members of a pedigree with retinoblastoma.^{5,6} Our patient was 6-month old at the time of her initial diagnosis with bilateral familial retinoblastoma. Family history, bilaterality and younger age at the initial diagnosis were, therefore, the most likely risk factors for the growth of new tumor in our case. The new growth of intraocular tumor in our case was treated with adjuvant 3 cycles of systemic chemotherapy, 4 cycles of diode laser transpupillary thermotherapy, ruthenium-106 plaque radiotherapy and supplementary cryotherapy; and the tumor regressed completely.

The unanswered challenge for ophthalmologist and ocular oncologist remains how long retinoblastoma patient be followed for new growth or recurrent tumor after the initial regression following local or combined local and systemic chemotherapy treatments especially for patients with bilateral retinoblastoma, tumors with Reese–Ellsworth grouping of I to III, a very younger age and family history of retinoblastoma.^{5,7} Our patient developed new tumor growth at the age of 12 years, 11 years after the initial diagnosis, and this is far beyond the recommended follow-up period. The loss of a second allele in a growing retina at pubertal age or persisting rare embryonal retinal cell might induce a very late onset new tumor formation.¹⁶ Moreover, the initial tumors in our patient were in the posterior pole and equatorial region while the new tumor growth was in the peripheral retina near to the ora serrata with anterior-posterior dissemination indicating early tumor occurrence in the posterior pole and late occurrence in the

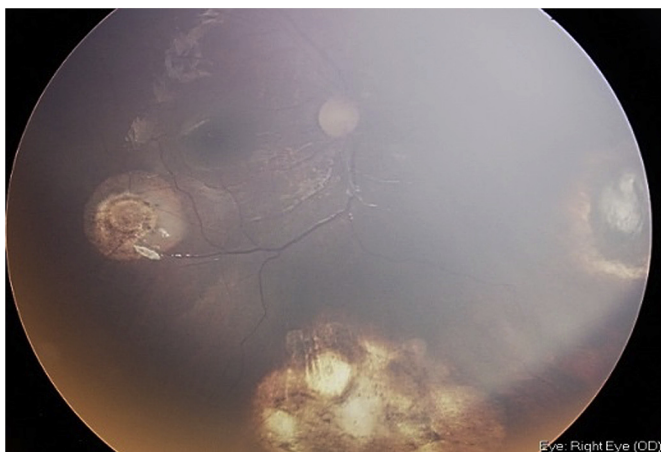


Fig. 1. Wide Field RetCam image showing regressed tumor in the right eye (type IV regression) after the initial combined treatment.

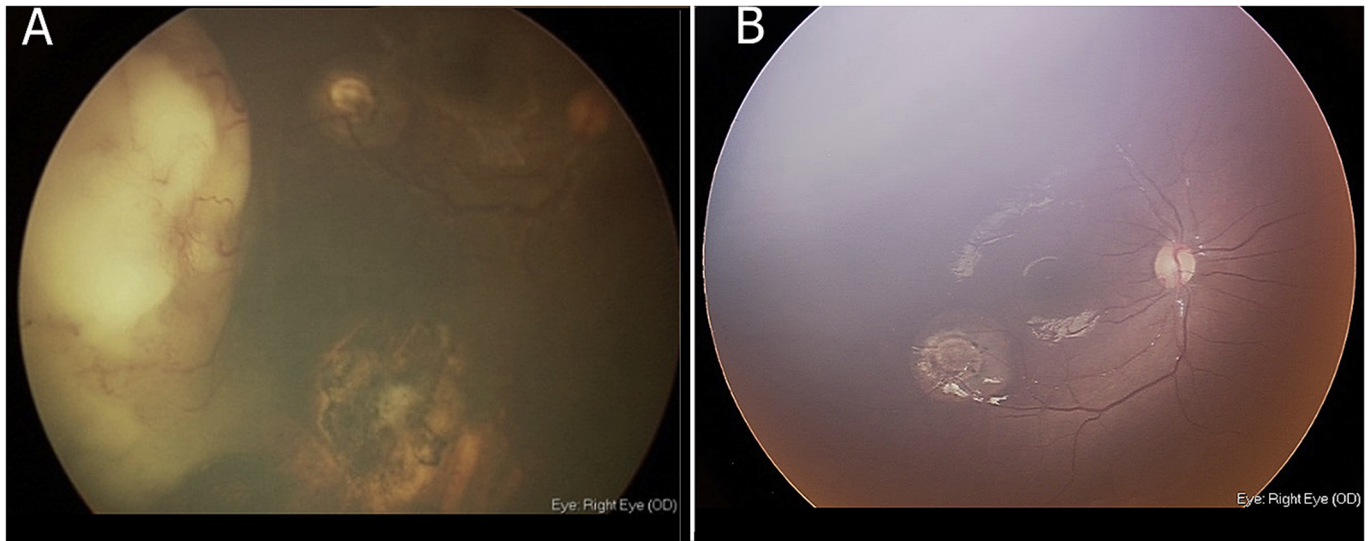


Fig. 2. **A:** Wide Field RetCam image showing new tumor growth at the peripheral fundus in the right eye. **B:** Wide Field RetCam image showing absence of regressed tumor foci at the site of new tumor growth in the right eye.

peripheral retina. This may further show that this very late onset of new tumor growth could be due to loss of second allele in a rare persisting embryonal retinal cell as retinal tumors expansion and embryonal retinal cells differentiation follow similar posterior-to-anterior pattern.^{17,18}

In clinical practice, the usual trend is to follow children below 3 years of age with examination under anesthesia (EUA) at intervals of 2 weeks to 2 months followed by annual office follow-up up to the ages of 6–7 years with the indirect ophthalmoscope and B-scan ultrasonogram once the child has reached age 3–4 years. However, our case indicates these usual follow-up periods are not enough, and lifelong eye exams and follow-ups are required as our case was treated with radiotherapy and is at risk of developing late complications of treatment, such as vitreous hemorrhage, retinal detachment, and radiation retinopathy; and second cancers. Our patient presented with a complaint of mild redness and eye pain. Hence, clinicians and patients and/or parents should have a high index of suspicion for pain or any ocular abnormalities as it may

indicate new growth or relapse of retinoblastoma especially tumors arising from a more anterior location.

4. Conclusions

Despite initial satisfactory treatment and complete regression of the tumor, a very late-onset new growth of retinoblastoma can occur. Hence, long-term follow-up with meticulous fundus examination with indirect ophthalmoscopy and scleral depression (\pm EUA) and/or serial RetCam for a decade or more is warranted, at least for high-risk groups, for timely detection and subsequent treatment. Moreover, for germline retinoblastoma cases who were treated with radiotherapy, like our case, lifelong monitoring is advised for timely detection of late complications of previous treatments and secondary malignancies.

5. Patient consent

The parent of the patient provided oral consent for publication of personal identifying information including medical record details and photographs, which has been documented in writing.

Funding

No funding or grant support.

Authors' order and contributions

We declare the order of the authors is as stated. All the authors collected and interpreted the data; wrote the manuscript. All the authors read and approved the final manuscript.

Conflict of interest

YG, SMS and ISO have no financial disclosures.

Authorship

All authors attest that they meet the current ICMJE criteria for Authorship.

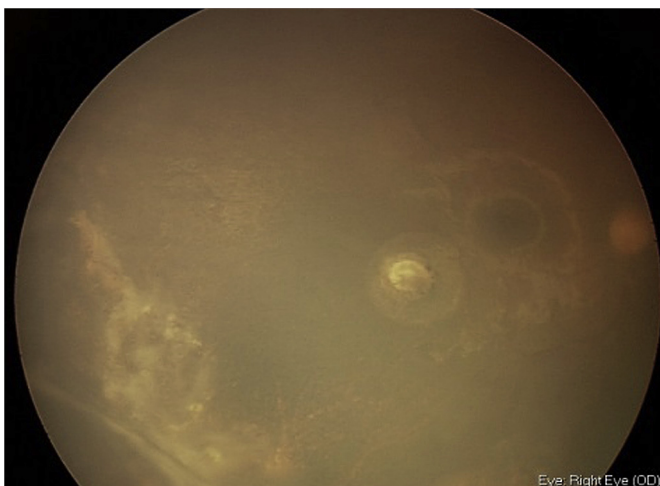

Fig. 3. Wide Field RetCam image showing new tumor growth regression in the right eye after combined treatment.

Acknowledgements

None.

References

1. Abramson DH. Retinoblastoma in the 20th century: past success and future challenges. The Weisenfeld lecture. *Invest Ophthalmol Vis Sci.* 2005;46:2684–2691.
2. Chintagumpala M, Chevez-barrios P, Paysse EA, Plon SE, Hurwitz R. Retinoblastoma: review of current management. *Oncologist.* 2007;12:1237–1246.
3. Klintworth GK. The eye. In: Rubin E, Farber JL, eds. *Pathology.* Philadelphia: J. B. Lippincott; 1994:1480–1482.
4. Moll AC, Imhof SM, Bouter LM, Tan KE. Second primary tumors in patients with retinoblastoma: a review of the literature. *Ophthalmic Genet.* 1997;18:27–34.
5. Wilson MW, Haik BG, Billups CA, Rodriguez-Galindo C. Incidence of new tumor formation in patients with hereditary retinoblastoma treated with primary systemic chemotherapy: is there a preventive effect? *Ophthalmology.* 2007;114:2077–2208.
6. Shields CL, Shelil A, Cater J, Meadows AT, Shields JA. Development of new retinoblastomas after 6 cycles of chemoreduction for retinoblastoma in 162 eyes of 106 consecutive patients. *Arch Ophthalmol.* 2003;121:1571–1576.
7. Shields CL, Honavar SG, Shields JA, Demirci H, Meadows AT, Naduvilath TJ. Factors predictive of recurrence of retinal tumors, vitreous seeds, and sub-retinal seeds following chemoreduction for retinoblastoma. *Arch Ophthalmol.* 2002;120:460–464.
8. Othman IS. Retinoblastoma major review with updates on Middle East management protocols. *Saudi J Ophthalmol.* 2012;26:163–175.
9. Stannard C, Lipper S, Sealy R, Sevel D. Retinoblastoma: a correlation of invasion of the optic nerve and choroid with prognosis and metastasis. *Br J Ophthalmol.* 1979;63:560–570.
10. Shields CL, Shields JA, Baez KA, Cater J, De Potter PV. Choroidal invasion of retinoblastoma: metastatic potential and clinical risk factors. *Br J Ophthalmol.* 1993;77:544–548.
11. Kim JM, Kim JH, Kim SJ, et al. Visual prognosis of retinoblastoma in the posterior pole treated with primary chemotherapy plus local treatments. *Korean J Ophthalmol.* 2010;24:347–352.
12. Shin JY, Kim JH, Yu YS, et al. Eye-preserving therapy in retinoblastoma: prolonged primary chemotherapy alone or combined with local therapy. *Korean J Ophthalmol.* 2010;24:219–224.
13. Balwierz W, Pietrys D, Romanowska-Dixon B, Kobylarz J, Pawińska-Wasikowska K, Moryl-Bujakowska A. Results of combined chemotherapy and local ophthalmic therapy for intraocular retinoblastoma. *Przegl Lek.* 2010;67:404–408.
14. Lee TC, Hayashi NI, Dunkel IJ, Beaverson K, Novetsky D, Abramson DH. New retinoblastoma tumor formation in children initially treated with systemic carboplatin. *Ophthalmology.* 2003;110:1989–1994.
15. Liu Yan, Zhang Xi, Liu Fang, Wang Ke-Lei. Clinical efficacy and prognostic factors of chemoreduction combined with topical treatment for advanced intraocular retinoblastoma. *Asian Pac J Cancer Prev.* 2014;15:7805–7809.
16. Takahashi T, Tamura S, Inoue M, Isayama Y, Sashikata T. Retinoblastoma in a 26-year-old adult. *Ophthalmology.* 1983;90:179–183.
17. Rugh R. X-rays and the retina of the primate fetus. *Arch Ophthalmol.* 1973;89:221–227.
18. Abramson DH, Gombos DS. The topography of bilateral retinoblastoma lesions. *Retina.* 1996;16:232–239.