



Case report

A stepping stone in treating dendritic keratitis



Hosam Sheha, MD, PhD ^{a, b, *}, Sean Tighe, MSc ^{a, b}, Anny M.S. Cheng, MD ^{a, b},
Scheffer C.G. Tseng, MD, PhD ^a

^a Ocular Surface Center, Miami, FL, USA

^b Department of Ophthalmology, Florida International University, Herbert Wertheim College of Medicine, Miami, FL, USA

ARTICLE INFO

Article history:

Received 16 December 2016

Received in revised form

17 May 2017

Accepted 2 June 2017

Available online 6 June 2017

Keywords:

Amniotic membrane

Antiviral

Dendritic keratitis

Interferon

ABSTRACT

Purpose: To report the outcome of self-retained amniotic membrane after debridement in recurrent dendritic keratitis.

Observations: A 70-year-old female with a recurrent dendritic corneal ulcer received debridement followed by placement of self-retained amniotic membrane. Five days after treatment, the patient experienced a complete resolution of symptoms, marked reduction of inflammation, complete re-epithelialization of the cornea and improvement of visual acuity. The corneal surface remained stable for 18 months despite noncompliance in using antiviral therapy.

Conclusions and importance: Self-retained amniotic membrane after debridement appears effective in treating dendritic keratitis. While early debridement is crucial to remove the infected corneal epithelium, amniotic membrane was shown to enhance the healing without scarring or recurrence. Besides the known anti-inflammatory and anti-scarring effects of the amniotic membrane, it may have a potential topical antiviral effect that warrants further investigation.

© 2017 The Authors. Published by Elsevier Inc. This is an open access article under the CC BY-NC-ND license (<http://creativecommons.org/licenses/by-nc-nd/4.0/>).

1. Introduction

Herpes simplex virus (HSV) keratitis is one of the most frequent causes of corneal blindness in the United States and worldwide.¹ Typically, it begins with epithelial involvement which may spontaneously resolve or spread to the stroma and endothelium. Pathogenesis includes viral replication within the infected epithelium, followed by the characteristic dendritic ulceration, immune mediated stromal inflammation and subsequent sight-threatening complications. The strategy for treatment is to eliminate the infectious virus, minimize stromal damage and prevent subsequent corneal scarring, melting or perforation.

Debridement has been used in HSV epithelial keratitis in an attempt to remove the infected epithelium, however it provides inadequate treatment with a high rate of recurrence.² Antiviral therapies are commonly used to target the infectious agent and reduce the recurrence.³ In this regard, oral antiviral agents are recommended over topical antiviral agents due to their superior

safety profile and corneal penetration. However, oral antivirals are also linked to a lack of compliance.^{4,5}

If the disease progresses to immune-mediated keratitis, the priority usually shifts to managing the stromal manifestations due to the potential for irreversible visual loss. Corneal damage observed at this stage is mainly caused by pro-inflammatory molecules released by the infected cells. The associated inflammation can be focal, multifocal, or diffuse and may lead to corneal thinning, scarring, or neovascularization. Available evidence in randomized clinical trials suggests a role for therapeutic doses of oral antivirals combined with judicious use of topical corticosteroids to suppress the associated inflammatory response. However, the use of steroids is controversial as it may induce complications such as flaring up the infection, corneal melting, elevation of the intraocular pressure, cataract, and/or increase the tendency toward recurrence.⁶ Due to these significant side effects, other alternatives are sought to control inflammation and enhance the healing.

Cryopreserved amniotic membrane (CAM) has successfully been used in the treatment of ocular surface disorders induced by infectious keratitis.^{7,8} More specifically, studies have shown that CAM as a temporary patch along with antivirals and corticosteroids can significantly improve HSV keratitis^{9–11} and the action mechanism has been attributed to its known anti-inflammatory and anti-scarring effects.^{12,13} Herein we report a case of recurrent dendritic

* Corresponding author. Ocular Surface Center, 7000 SW 97th Avenue, Suite 213, Miami, FL 33173, USA.

E-mail address: hsheha@ocularsurface.com (H. Sheha).

keratitis that had been successfully treated with self-retaining CAM without the use of antiviral therapy, suggesting CAM may have a potential antiviral effect as well.

2. Case report

A 70-year-old female with a history of stable rheumatoid arthritis had been treated with systemic methotrexate 7.5 mg weekly and prednisolone 2.5 mg daily for 5 years. She had experienced three episodes of dendritic keratitis in less than a year which were treated with topical acyclovir (3%) ointment 5 times per day during the acute phase and prophylactic oral acyclovir 400 mg twice daily between episodes. She developed allergy to her prescription contact lenses and used 0.1% dexamethasone 4 times daily for 10 days after which she presented with worsening in left ocular pain, photophobia, and blurry vision. Slit-lamp examination and fluorescein staining showed left paracentral dendritic corneal ulcer (Fig. 1, top), decreased corneal sensation, conjunctival injection, 20/80 vision, and borderline intraocular pressure of 21 mmHg. Diagnosis of recurrent dendritic keratitis was made based on the history and clinical impression. Under topical anesthesia, gentle corneal epithelial debridement was performed using a dry weck-cel

(Microsponge™, Alcon®) (Fig. 1, middle left) to remove the loose epithelium at the edge of the dendritic ulcer. Then, a self-retained CAM (PROKERA Slim®, Bio-Tissue Inc. Miami, FL) was placed and the baseline epithelial defect was detected by fluorescein staining (Fig. 1, middle right). No topical antiviral was used to avoid its known toxicity to the corneal epithelium so oral acyclovir 200 mg 5 times per day was prescribed. However, the patient reported that they did not use it.

Five days after treatment, the CAM dissolved and Prokera was removed. The ocular discomfort disappeared, inflammation was reduced, the corneal epithelium healed completely (Fig. 1, bottom left), and the visual acuity improved to 20/30. During the 18 months follow up, the corneal surface remained stable without recurrence despite the patient not taking systemic antiviral (Fig. 1, bottom right).

3. Discussion

Although debridement is a commonly used procedure in HSV epithelial keratitis, studies have demonstrated that 50% of patients usually develop recurrence within a week if antiviral agents were not used.^{2,3} Moreover topical corticosteroids are usually

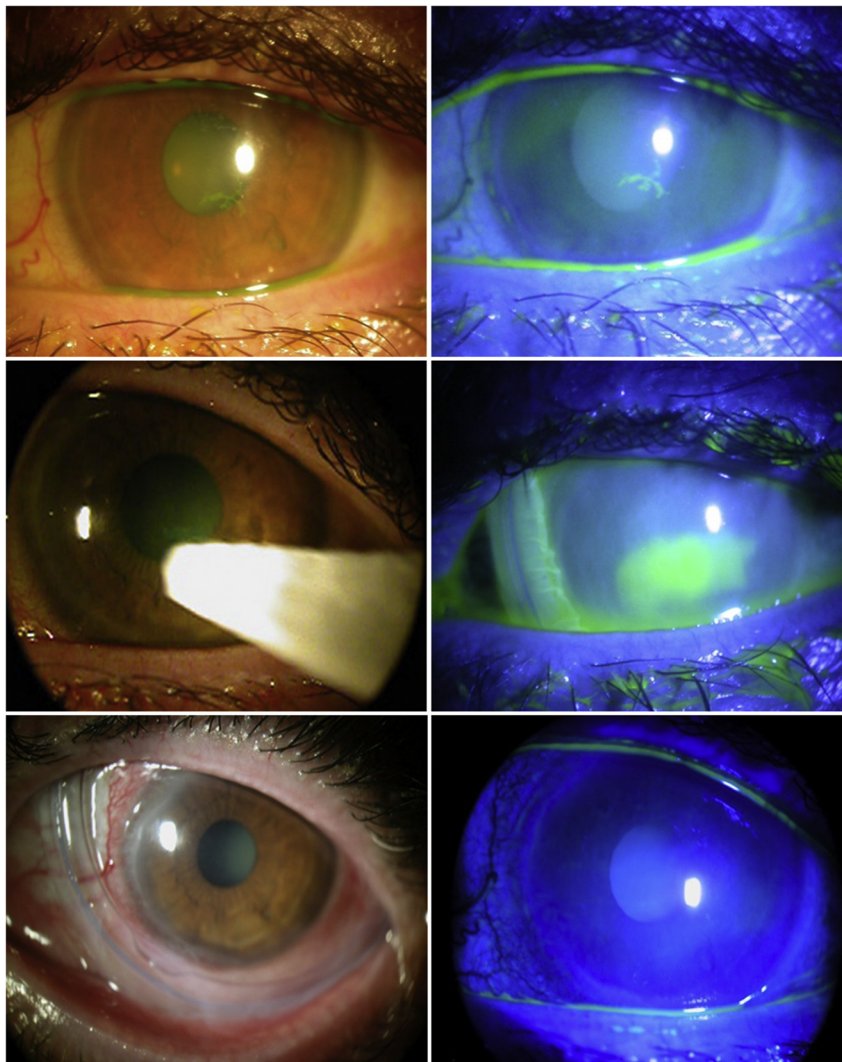


Fig. 1. Treatment of acute dendritic keratitis. Recurrent dendritic corneal ulcer (Top), treated with self-retained cryopreserved amniotic membrane after debridement (Middle), complete epithelization was achieved within 5 days and remained stable without recurrence (Bottom).

recommended to shorten the duration of active HSV stromal keratitis,^{14–17} however there remains excessively high failure rates (50%¹⁸ and 75%¹⁹) after ten weeks of treatment. In this report, despite the lack of antiviral and steroid therapy, the corneal surface healed and remained stable for 18 months with no recurrence when CAM was used as a first line treatment after debridement. In fact, the healing was relatively faster compared to the patient's previous 3 episodes, within the past year, which were treated with debridement, antiviral and steroids. These finding suggests CAM may have a topical antiviral effect along with its known anti-inflammatory and anti-scarring actions.

CAM has been used in a murine model of herpes simplex virus-induced necrotizing keratitis, in which it effectively entrapped stroma neutrophils and mononuclear cells, including macrophages and lymphocytes, and facilitated their rapid apoptosis.^{9,13,20} These experimental findings demonstrate CAM's anti-inflammatory role in treating ulcerative non-healing HSV keratitis with²¹ adjuvant antiviral therapy to reduce inflammation, promote healing, and improve vision. Similar to our findings, CAM has also been shown to treat HSV keratitis without antivirals.^{10,22} These findings are supported by the notion that AM is rich in interferon (IFN) which has been demonstrated to have anti-proliferative and cross-species anti-viral activities.²³ More specifically, IFN induced the expression of the 2'-5' oligoadenylate synthetase (OAS) enzyme that induces degradation of viral and cellular RNAs and thereby blocks viral infection. Additionally, AM contains cystatin E, an analogue of cysteine proteinase inhibitor, which is known to inhibit proteolytic cleavage required for viral replication.^{24,25} Collectively, these evidences support the concept that CAM may have antiviral potential and may further explain its effectiveness in herpetic keratitis.^{26–30}

Limitations of the study include lack of obtaining specimen for culture to confirm the diagnosis, the study is limited to one case, and it is possible the outcome would have been similar without CAM. However, it warrants further controlled studies to evaluate CAM's potential antiviral effect.

4. Conclusion

In conclusion, self-retained CAM after debridement was used in treating dendritic keratitis. While early debridement can be used to remove the infected corneal epithelium, CAM can enhance the healing without scarring. Besides the known anti-inflammatory and anti-scarring effects of CAM, it may have a potential topical antiviral effect as well. Further studies are needed to confirm the direct antiviral effect of CAM to provide an alternative therapy for viral keratitis. This may provide a preferred treatment over topical antivirals, particularly for patients with pre-existing ocular surface disease who are at high risk for toxicity from topical medications.

Patient consent

The patient provided a written consent to receive the above treatment according to the Declaration of Helsinki and to use details of this case for publication in compliance with HIPPA. IRB approval was not required in this case report.

Acknowledgments and disclosures

Funding

The development of PROKERA[®] was supported in part with grant number EY014768 from the National Institute of Health (NIH) and National Eye Institute (NEI). The contents represent the authors' opinion and not necessarily represent the opinion of the NIH or NEI.

Conflict of interest

The Authors are employees of Tissue Tech Inc. that holds patents on the methods of preservation and clinical uses of amniotic membrane graft and PROKERA[®]. Dr. Tseng is the founder and a major shareholder of Tissuetech Inc.

Authorship

All authors attest that they meet the current ICMJE criteria for Authorship.

Acknowledgements

None.

Other

This Case Report was presented at the annual meeting of the American Society of Cataract and Refractive Surgery (ASCRS) in San Diego 2015.

References

- Liesegang TJ. Herpes simplex virus epidemiology and ocular importance. *Cornea*. 2001;20:1–13.
- Coster DJ, Jones BR, Falcon MG. Role of debridement in the treatment of herpetic keratitis. *Trans Ophthalmol Soc U. K.* 1977;97:314–317.
- Jones BR, Coster DJ, Fison PN, Thompson GM, Cobo LM, Falcon MG. Efficacy of acycloguanosine (Wellcome 248U) against herpes-simplex corneal ulcers. *Lancet*. 1979;1:243–244.
- Porter SM, Patterson A, Kho P. A comparison of local and systemic acyclovir in the management of herpetic disciform keratitis. *Br J Ophthalmol*. 1990;74:283–285.
- Falcon MG, Jones BR. Antivirals for the therapy of herpetic eye disease. *Trans Ophthalmol Soc U. K.* 1977;97:330–332.
- Coutinho AE, Chapman KE. The anti-inflammatory and immunosuppressive effects of glucocorticoids, recent developments and mechanistic insights. *Mol Cell Endocrinol*. 2011;335:2–13.
- Sheha H, Liang L, Li J, Tseng SC. Sutureless amniotic membrane transplantation for severe bacterial keratitis. *Cornea*. 2009;28:1118–1123.
- Kim JS, Kim JC, Hahn TW, Park WC. Amniotic membrane transplantation in infectious corneal ulcer. *Cornea*. 2001;20:720–726.
- Heiligenhaus A, Bauer D, Meller D, Steuhl KP, Tseng SC. Improvement of HSV-1 necrotizing keratitis with amniotic membrane transplantation. *Investig Ophthalmol Vis Sci*. 2001;42:1969–1974.
- Heiligenhaus A, Li H, Hernandez Galindo EE, Koch JM, Steuhl KP, Meller D. Management of acute ulcerative and necrotising herpes simplex and zoster keratitis with amniotic membrane transplantation. *Br J Ophthalmol*. 2003;87:1215–1219.
- Shi W, Chen M, Xie L. Amniotic membrane transplantation combined with antiviral and steroid therapy for herpes necrotizing stromal keratitis. *Ophthalmology*. 2007;114:1476–1481.
- Tseng SC, Espana EM, Kawakita T, et al. How does amniotic membrane work? *Ocul Surf*. 2004;2:177–187.
- Bauer D, Wasmuth S, Hennig M, Baehler H, Steuhl KP, Heiligenhaus A. Amniotic membrane transplantation induces apoptosis in T lymphocytes in murine corneas with experimental herpetic stromal keratitis. *Investig Ophthalmol Vis Sci*. 2009;50:3188–3198.
- Wilhelmus KR, Coster DJ, Jones BR. Acyclovir and debridement in the treatment of ulcerative herpetic keratitis. *Am J Ophthalmol*. 1981;91:323–327.
- Epstein RJWK. *Dendritic Keratitis-will Wiping it off Wipe it Out?*. Chicago: Year Book Medical Publishers; 1989:85–99.
- Guess S, Stone DU, Chodosh J. Evidence-based treatment of herpes simplex virus keratitis: a systematic review. *Ocul Surf*. 2007;5:240–250.
- Kastner JK, Weiss SM, Kulikowski CA, Dawson CR. Therapy selection in an expert medical consultation system for ocular herpes simplex. *Comput Biol Med*. 1984;14:285–301.
- Wilhelmus KR, Gee L, Hauck WW, et al. Herpetic Eye Disease Study. A controlled trial of topical corticosteroids for herpes simplex stromal keratitis. *Ophthalmology*. 1994;101:1883–1895.
- Barron BA, Gee L, Hauck WW, et al. Herpetic Eye Disease Study. A controlled trial of oral acyclovir for herpes simplex stromal keratitis. *Ophthalmology*. 1994;101:1871–1882.
- Bauer D, Hennig M, Wasmuth S, et al. Amniotic membrane induces peroxisome proliferator-activated receptor-gamma positive alternatively activated macrophages. *Investig Ophthalmol Vis Sci*. 2012;53:799–810.

21. Shi W, Chen M, Xie L. Amniotic membrane transplantation combined with antiviral and steroid therapy for herpes necrotizing stromal keratitis. *Ophthalmology*. 2007;114:1476–1481.
22. Chen H-J, Pires RTF, Tseng SCG. Amniotic membrane transplantation for severe neurotrophic corneal ulcers. *Br J Ophthalmol*. 2000;84:826–833.
23. Franco GR, de Carvalho AF, Kroon EG, et al. Biological activities of a human amniotic membrane interferon. *Placenta*. 1999;20:189–196.
24. Bjorck L, Grubb A, Kjellen L, Cystatin C. A human proteinase inhibitor, blocks replication of herpes simplex virus. *J Virol*. 1990;64:941–943.
25. Korant BD, Brzin J, Turk V. Cystatin, a protein inhibitor of cysteine proteases alters viral protein cleavages in infected human cells. *Biochem Biophys Res Commun*. 1985;127:1072–1076.
26. de Koning EW, van Bijsterveld OP, Cantell K. Combination therapy for dendritic keratitis with acyclovir and alpha-interferon. *Arch Ophthalmol*. 1983;101:1866–1868.
27. Colin J, Chastel C, Renard G, Cantell K. Combination therapy for dendritic keratitis with human leukocyte interferon and acyclovir. *Am J Ophthalmol*. 1983;95:346–348.
28. Cantell K. Development of antiviral therapy with alpha interferons: promises, false hopes and accomplishments. *Ann Med*. 1995;27:23–28.
29. Sundmacher R. *Interferon in Ocular Viral Diseases*. London: Academic Press; 1982.
30. Sundmacher R. Use of nucleoside analogues in the treatment of herpes simplex virus eye diseases. *Metab Pediatr Syst Ophthalmol*. 1983;7:89–94.