

Acute pancreatitis, a rare complication of afferent loop obstruction: A case report

SAGE Open Medical Case Reports
Volume 10: 1–6
© The Author(s) 2022
Article reuse guidelines:
sagepub.com/journals-permissions
DOI: 10.1177/2050313X221078723
journals.sagepub.com/home/sco



Hao Li¹ , Yucheng Sun¹, Zhenyu Wang¹, Zixiang Ji¹, Junqiang Xu¹ and Fengzhe Cui²

Abstract

Afferent loop (A-loop) obstruction presenting as acute pancreatitis is a rare clinical entity. We report a case of A-loop obstruction that occurred 15 years after Billroth II gastrectomy, leading to acute pancreatitis and accompanied by duodenal perforation and peritonitis. A 63-year-old man complaining of upper abdominal pain, distention, and nausea was referred to our hospital. The patient was previously treated with antibiotics and gastrointestinal decompression at the primary healthcare institute after being diagnosed with acute pancreatitis. However, the symptoms did not improve. Upon inter-hospital transportation, he experienced a period of relief from the pain but soon developed signs of diffuse peritonitis. Laboratory examination showed elevated serum amylase and lipase. A computed tomography scan revealed slight edema of the pancreas, a dilated and fluid-filled bowel loop across the mid-abdomen, and fluid accumulation in the abdominal cavity and pelvis. An emergency laparotomy was conducted, followed by symptomatic treatments. The patient had an uneventful recovery and was discharged in 4 weeks.

Keywords

Afferent loop obstruction, acute pancreatitis, Billroth II subtotal gastrectomy, duodenal perforation, peritonitis

Date received: 19 July 2021; accepted: 19 January 2022

Introduction

Some clinical conditions can cause acute obstruction of the afferent loop (A-loop). Past surgical history may shed light on the etiology of intestinal obstruction.¹ Without prior surgery or any apparent cause, intussusception, gallstone ileus, and neoplasms are suspected.^{2–4} The incidence of A-loop obstruction after Billroth II (Bi-II) subtotal gastrectomy is low (0.3%–1.0%), similar between open and laparoscopic surgery.^{5–7} Kim et al. reported that after undergoing laparoscopic distal gastrectomy with Bi-II reconstruction, 4 out of 386 (1.01%) gastric cancer patients developed A-loop obstruction. The leading causes are adhesion and intestinal herniation. For A-loop obstruction, the interval between primary gastrectomy and emergency operation ranged from 4 to 540 d (median 33 d).⁶

Common A-loop obstruction symptoms are bowel distention due to accumulation of intestinal secretions and obstruction of the pancreaticobiliary tree. The latter can lead to an increase in serum amylase or lipase. Although acute and chronic forms of A-loop syndrome have been reported, chronic partial obstruction is more common in clinical manifestations.⁸ Chronic A-loop syndrome presents postprandial abdominal pain relieved by bilious vomiting as

intraluminal pressure in the afferent limb overcomes obstruction. If a severe obstruction occurs, the distended A-loop may not sufficiently pass through its contents. Therefore, a “closed-loop obstruction” appears and causes acute abdominal pain. The A-loop can be compromised if it worsens, resulting in perforation and peritonitis. Here, we report a case of an obstructed A-loop that occurred 15 years after the Bi-II subtotal gastrectomy. The case highlights a rare clinical entity of acute pancreatitis (AP) secondary to A-loop obstruction, followed by duodenal perforation and peritonitis.

Case presentation

A 63-year-old man was initially admitted to a local healthcare institute to treat lacunar infarcts for 10 days when he

¹Department of General Surgery, Affiliated Hospital of Yanbian University, Yanji, P.R. China

²Department of General Surgery, Dunhua People's Hospital, Dunhua, P.R. China

Corresponding Author:

Hao Li, Department of General Surgery, Affiliated Hospital of Yanbian University, 1327 Juzi Street, Yanji 133000, Jilin, P.R. China
Email: lih@ybu.edu.cn



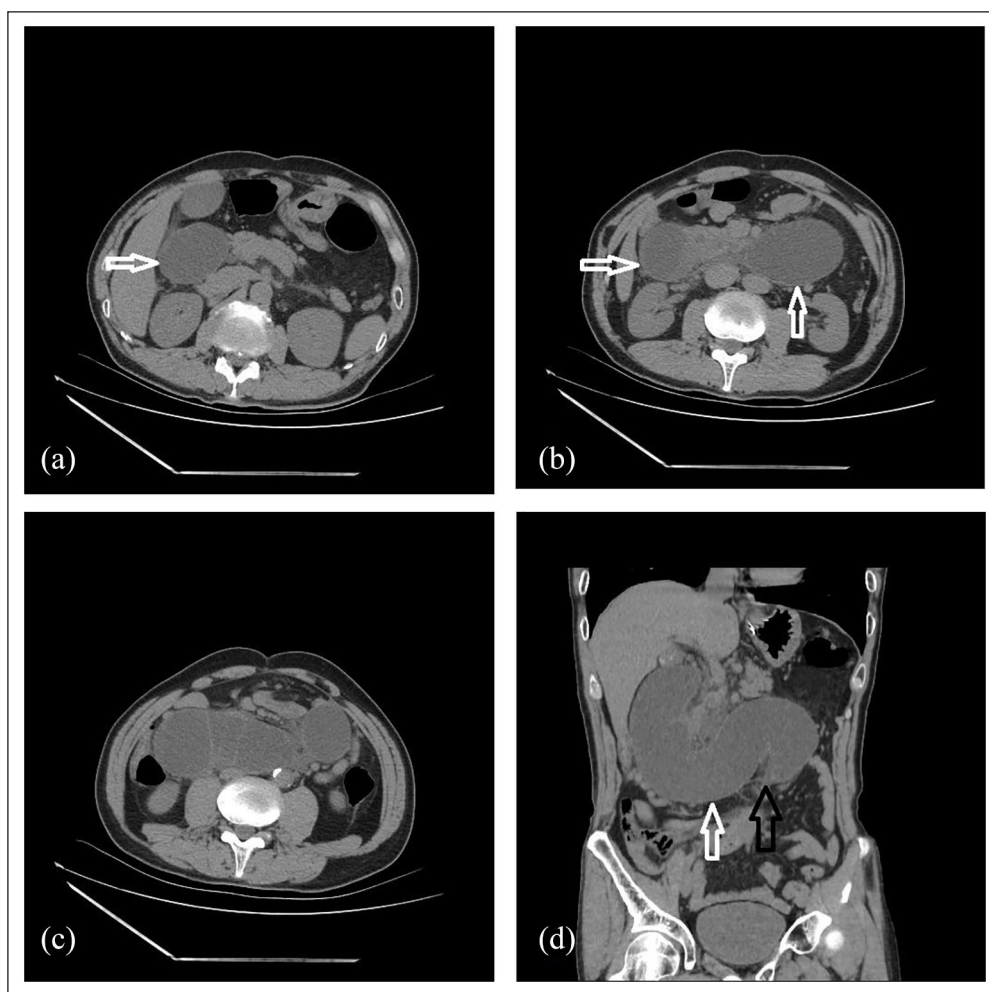


Figure 1. Plain CT scans of the whole abdomen at the primary healthcare institute. It showed dilatation of duodenum and proximal jejunal loops (white arrow) (a)–(c); duodenal dilation and stenosis above the umbilical level (black arrow) (d). No fluid accumulation was observed in the abdominal cavity.

presented upper abdominal colicky pain radiating to the lower back, accompanied by mild distention, low-grade fever, and nausea without vomiting. The patient had Bi-II subtotal gastrectomy due to gastric perforation 15 years prior.

Initial computed tomography (CT) scan revealed duodenal dilation and stenosis at the umbilical level (Figure 1). Other images also suggested mild pancreatic edema, high-density shadows in the gallbladder, and abdominal fat stranding. Laboratory tests showed a white blood cell count of $13.02 \times 10^9/L$ (range: $4\text{--}10 \times 10^9/L$), neutrophil % of 88.50% (range: 40%–70%), serum amylase or lipase levels of 630 U/L (range: 0–103 U/L) and 363.10 U/L (range: 0–60 U/L), and urine amylase level of 7035 U/L (range: 0–900 U/L). The patient was diagnosed with AP involving paralytic ileus and received 4 days of AP targeting treatments, including antibiotics, inhibition of pancreatic secretion, and 2 days of gastrointestinal decompression, which drained clear non-bilious fluid. However, the symptoms did

not improve. The patient was referred to our ward. He felt temporary relief from the pain during the inter-hospital transportation/referral process (~5 h, including the COVID-19 test). But soon, he developed severe abdominal rigidity, guarding, and rebound tenderness. The patient's abdomen appeared distended on physical examination with no peristaltic movement. Bowel sounds were scanty (1–2 times/min). Percussion produced a dull note throughout the abdomen and the shifting dullness was negative. Tenderness/guarding was prominent in the right upper quadrant, the xiphoid process, and the left costal margin. A sausage-shaped mass with minimal mobility was palpable in the right upper quadrant. Murphy's sign was (–). Our first clinical considerations were AP, intestinal obstruction, and diffuse peritonitis. He was admitted for emergency surgery.

At admission, the patient's blood tests revealed that serum amylase (277 U/L) and lipase (1627 U/L) were significantly higher than usual. Other blood biochemistry and liver function tests were within normal ranges, except that the white

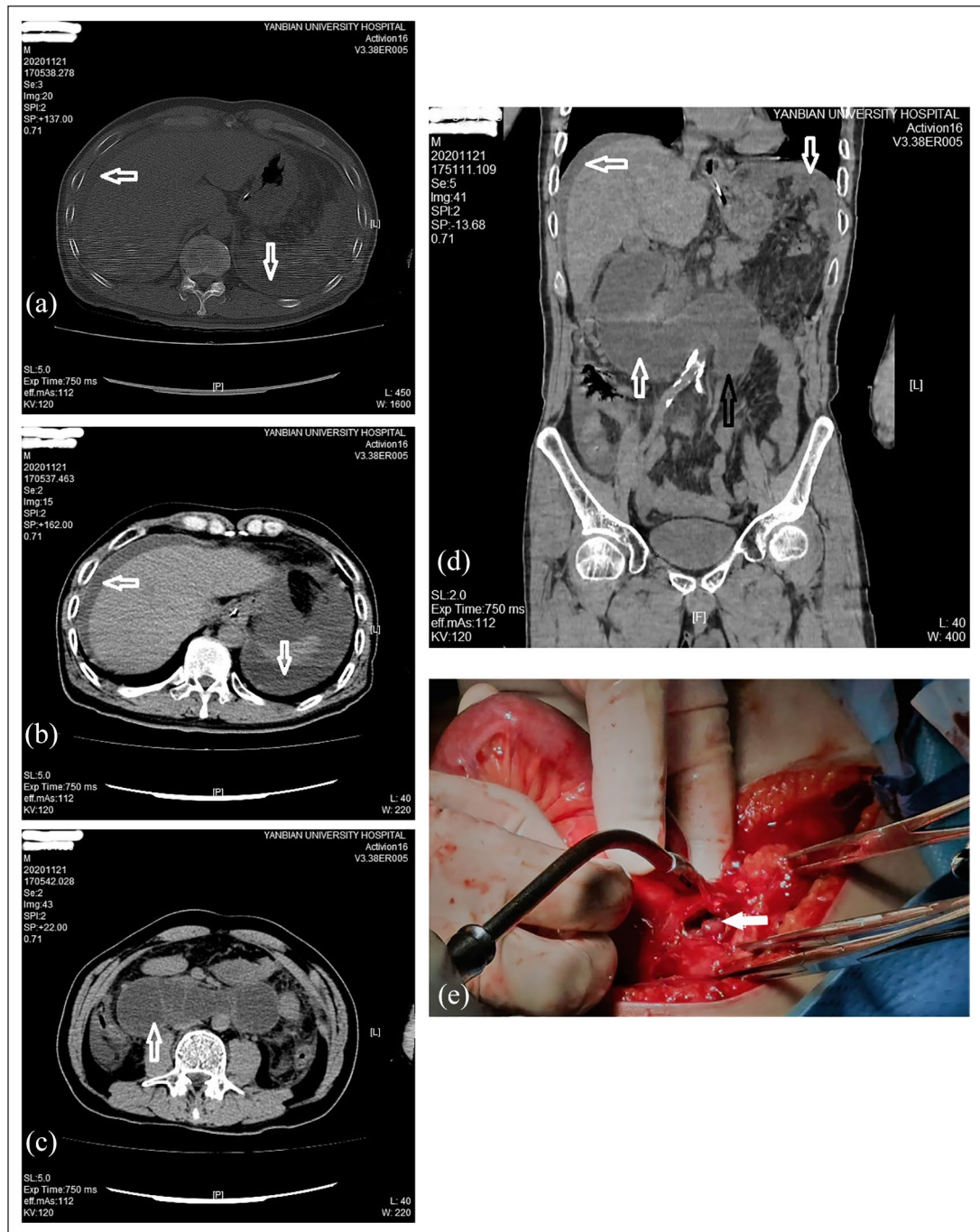


Figure 2. Abdominal CT scans upon admission to our emergency department secured the diagnosis of the A-loop obstruction and further discovered peritoneal effusion. It presented sub-diaphragmatic fluid 5 h after the previous scan (white arrow) (a, b); a dilated and fluid-filled duodenum across the mid-abdomen proximal to the suspected closed-loop obstruction (white arrow) and an obstruction site (black arrow) (c, d); a perforation found on the anterior wall of the horizontal duodenum proximal to the attachment of the Treitz ligament (white arrow) (e).

blood cell count of $2.03 \times 10^9/L$ and the serum potassium level of 3.0 mmol/L (range: $3.5\text{--}5.5 \text{ mmol/L}$) were slightly lower than usual. We performed another CT scan 5 h apart from the previous one before leaving the primary hospital. It confirmed a fluid-filled dilated duodenal loop across the mid-abdomen proximal to the suspected closed-loop intestinal

obstruction (Figure 2). In addition, fluid accumulation was discovered in the abdominal cavity and pelvis, which was not shown in the CT scans 5 h prior (Figure 1).

The emergency operation revealed extensive adhesions in the upper abdomen, and $\sim 500 \text{ mL}$ of bilious fluid was collected from the peritoneal cavity. The peritoneal fluid was

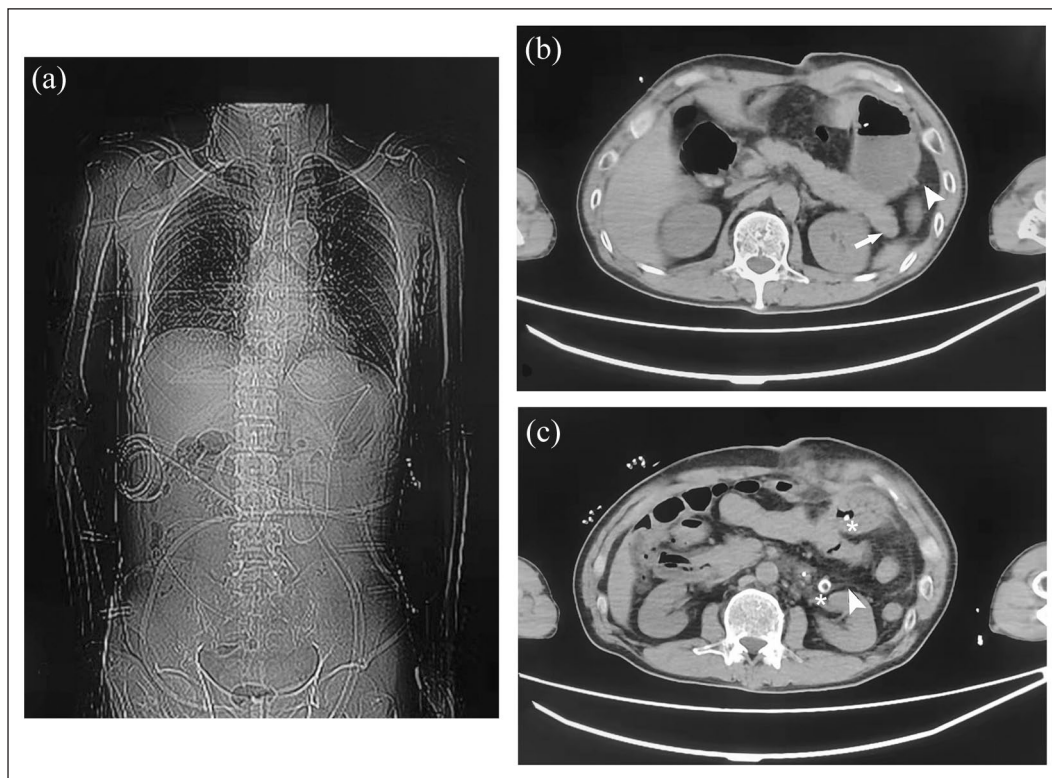


Figure 3. Abdominal CT scans illustrated favorable postoperative imaging appearances. It showed a recovery of duodenal dilation (a); pancreatic edema slightly subsided in the neck but remained in the tail (white arrow); abdominal fluid disappearing on the liver surface and in the splenic fossa (white arrowhead); and colon distention, fat stranding, and the presence of abdominal drainage and enteral feeding tubes (white asterisk) (b, c).

tested positive for amylase (>2000 U/L). The pancreas appeared mildly edematous. The original gastrointestinal anastomosis performed was a Bi-II subtotal gastrectomy (antecolic jejunal loop). Due to the presence of adhesions, the gastrointestinal anastomosis rotated retrogradely 90° , leading to complete obstruction of the A-loop, causing a distended proximal duodenum and jejunum. A 0.5 cm irregularly shaped perforation was found on the anterior wall of the horizontal duodenum proximal to the attachment of the Treitz ligament (Figure 2). No ulcer or tumor was located adjacent to the rupture. Our final diagnosis was mild acute edematous pancreatitis (based on the 2012 revised Atlanta classification for AP),⁹ intestinal obstruction, and diffuse peritonitis. The APACHE-II severity score was 7.

We performed an intraoperative dissection to loosen the adhesion around the gastrointestinal anastomosis and repair the rupture. The C-reactive protein (CRP) level was 74.40 mg/L (range <5 mg/L) at 16 h after admission (8 h after surgery). Postoperative CT imaging illustrated a recovery of duodenal dilation and abdominal ascites. Pancreatic edema appeared slightly subsided in the neck but remained in the tail, confirming the diagnosis of mild acute edematous pancreatitis (Figure 3). No specific treatment was provided for pancreatitis, but serum amylase and lipase levels were

monitored consecutively. On the second day after surgery, the blood amylase level returned to normal, and the lipase level continued to decrease and returned to normal on the fifth day after the operation. He went through an uneventful recovery after symptomatic treatment and was discharged 4 weeks after the surgery.

Discussion

Most A-loop obstruction occurs in the early postoperative period, which rarely develops in 10 years.^{10–13} Per se, it is infrequent to observe A-loop obstruction after a remote history of Bi-II gastrojejunostomy presenting AP. After a thorough search of the literature in PubMed, we identified 24 manuscripts (including reviews) published up to 2021, describing A-loop obstruction secondary to gastrectomy, which presented AP complications. In the literature, the causes of A-loop obstruction include internal herniation, adhesion, malignant mass, enterolith, and so on. However, only one case is similar to ours, in which the patient experienced epigastric pain, nausea without vomiting, and obstruction of the A-loop was resolved by laparoscopic adhesionolysis.¹⁴

Our patient had a Bi-II subtotal gastrectomy 15 years ago. Due to extensive postoperative abdominal adhesion,

gastrojejunal anastomosis acted as the fulcrum for rotation of the afferent limb, resulting in complete mechanical obstruction in the initial segment of the jejunum. It impeded the passage of pancreatic fluid and refluxed duodenal fluid into the pancreatic duct, causing pancreatitis. Furthermore, since the A-loop obstruction was not recognized and treated at the early stages, the afferent loop was compromised, resulting in perforation and peritonitis. However, because of the diversion of the subtotal gastrectomy, this 'sausage-like' loop only contains fluid but not air. Although a 0.5 cm perforation was in the duodenum, it did not release much free air in the abdomen, unlike other intestinal perforations.

As noted, the patient initially presented minimal A-loop obstructive symptoms, but more AP-like symptoms, such as colicky abdominal pain under the xiphoid process that radiates to the back, distention, and nausea (no vomiting throughout the course); laboratory examination revealed that serum amylase or lipase levels were at least 3 times greater than the upper limit of expected value, which was the gold standard for diagnosis of AP.¹⁴ According to the 2012 revised Atlanta classification for AP, two of three criteria for diagnosing AP were met.⁹ Besides, mild pancreatic edema was observed in the emergency laparotomy and the postoperative CT scans. Hence, we classified this patient's AP as mild acute edematous pancreatitis.

Moreover, the most common causes of AP are biliary diseases and alcohol overuse. CT scan suggested gallstones in the neck of the gallbladder, but no dilation, bile stones, or stenosis was found in the common bile duct. Laboratory workup revealed that bilirubin and liver enzymes were normal. Therefore, biliary pathology is ruled out as the cause of AP. Interestingly, AP secondary to A-loop obstruction confused the overall clinical manifestations. The patient was first diagnosed with AP involving paralytic ileus at the primary healthcare institute and was given AP targeting therapy for 4 days, including 2 days of gastrointestinal decompression, but the symptoms did not improve instead worsened. Anatomical changes from Billroth II gastrectomy often lead to bile-containing fluid extracted through gastrointestinal decompression. When gastrointestinal decompression showed clear and bile-free gastric juice, complete A-loop obstruction should be highly suspected. However, knowing that mechanical obstruction remains a significant diagnostic consideration, because CT and emergency laparotomy confirmed no signs of ischemia or necrosis in the intestine, there was insufficient evidence to support open surgery.

An expedient diagnosis and minimally invasive surgery are the favorable therapeutic approaches for patients diagnosed with acute A-loop obstruction. Kim et al. reported a case of a 67-year-old patient with A-loop syndrome presenting as AP. The patient was not eligible for surgical correction but received an exceptional outcome with an endoscopically placed nasogastric/enteric tube.¹⁵ Laparoscopy is one of the diagnostic and therapeutic options but less invasive for patients suspected of the A-loop obstruction mimicking AP.¹⁶

The patient felt temporary relief from the pain during inter-hospital transportation, suspecting that the change of position released the obstruction of the A-loop or the duodenal perforation reduced pressure. Unfortunately, the patient developed severe diffuse abdominal pain with tenderness/rebound tenderness and rigidity. A CT scan also shows fluid accumulation in the abdominal cavity, highly indicative of duodenal perforation and acute peritonitis. Luckily, after surgical correction of the A-loop obstruction and repair of the rupture, the patient had an uneventful recovery.

Conclusion

Acute A-loop obstruction that causes secondary AP complicates early diagnosis and management. A high index of suspicion is the key when clinicians evaluate a patient with the relevant surgical history and AP-like symptoms.

Declaration of conflicting interests

The author(s) declared no potential conflicts of interest with respect to the research, authorship, and/or publication of this article.

Funding

The author(s) received no financial support for the research, authorship, and/or publication of this article.

Ethical approval

Our institution does not require approval for reporting individual cases or case series.

Informed consent

Written informed consent was obtained from the patient for his anonymized medical information to be published in this article.

ORCID iD

Hao Li  <https://orcid.org/0000-0001-9441-6776>

References

1. Rami Reddy SR and Cappell MS. A systematic review of the clinical presentation, diagnosis, and treatment of small bowel obstruction. *Curr Gastroenterol Rep* 2017; 19(6): 28.
2. Diaz JJ, Jr Bokhari F, Mowery NT, et al. Guidelines for management of small bowel obstruction. *J Trauma* 2008; 64: 1651–1664.
3. Kendrick ML. Partial small bowel obstruction: clinical issues and recent technical advances. *Abdom Imaging* 2009; 34(3): 329–334.
4. Attard JA and MacLean AR. Adhesive small bowel obstruction: epidemiology, biology and prevention. *Can J Surg* 2007; 50(4): 291–300.
5. Aoki M, Saka M, Morita S, et al. Afferent loop obstruction after distal gastrectomy with Roux-en-Y reconstruction. *World J Surg* 2010; 34(10): 2389–2392.
6. Kim DJ, Lee JH and Kim W. Afferent loop obstruction following laparoscopic distal gastrectomy with Billroth-II gastrojejunostomy. *J Korean Surg Soc* 2013; 84(5): 281–286.

7. Cao Y, Kong X, Yang D, et al. Endoscopic nasogastric tube insertion for treatment of benign afferent loop obstruction after radical gastrectomy for gastric cancer: a 16-year retrospective single-center study. *Medicine* 2019; 98(28): e16475.
8. Blouhos K, Boulas KA, Tsalis K, et al. Management of afferent loop obstruction: Reoperation or endoscopic and percutaneous interventions? *World J Gastrointest Surg* 2015; 7: 190–195.
9. Sarr MG. 2012 revision of the Atlanta classification of acute pancreatitis. *Pol Arch Med Wewn* 2013; 123: 118–124.
10. Pickleman J and Lee RM. The management of patients with suspected early postoperative small bowel obstruction. *Ann Surg* 1989; 210(2): 216–219.
11. Dias AR and Lopes RI. Biliary stone causing afferent loop syndrome and pancreatitis. *World J Gastroenterol* 2006; 12: 6229–6231.
12. Maeda M, Kobayashi A, Kawasoe J, et al. [A case of rupture of post-gastrectomy afferent loop obstruction due to invasion by pancreatic cancer]. *Gan To Kagaku Ryoho* 2010; 37(12): 2364–2366.
13. Uriu Y, Kuriyama A, Ueno A, et al. Afferent loop syndrome of 10 years' onset after gastrectomy. *Asian J Surg* 2019; 42(10): 935–937.
14. Brooks S, Phelan MP, Chand B, et al. Markedly elevated lipase as a clue to diagnosis of small bowel obstruction after gastric bypass. *Am J Emerg Med* 2009; 27(9): 1167.e5–e7.
15. Kim HJ, Kim JW, Kim KH, et al. [A case of afferent loop syndrome treated by endoscopic drainage procedure using nasogastric tube]. *Korean J Gastroenterol* 2007; 49(3): 173–176.
16. Vettoretto N, Pettinato G, Romessis M, et al. Laparoscopy in afferent loop obstruction presenting as acute pancreatitis. *JSLs* 2006; 10(2): 270–274.