

Case Report

Arrhythmic Mitral Valve Prolapse and Mitral Annulus Disjunction in Heritable Aortic Disease

Drake A. Comber, MSc,^a Ashley DeGraaf, MSc,^b Derek Human, BM BCh, MA,^b Amanda Barlow, MD,^a Praveen Indraratna, MBBS,^{c,d} Gnalini Sathanathan, MBBS,^{e,†} and Zachary Laksman, MD, MSc^{a,e,‡}

^aDepartment of Medicine, University of British Columbia, Vancouver, British Columbia, Canada

^bSt Paul's Hospital, Vancouver, British Columbia, Canada

^cDepartment of Radiology, St Paul's Hospital, Vancouver, British Columbia, Canada

^dFaculty of Medicine, University of New South Wales, Sydney, New South Wales, Australia

^eDepartment of Cardiology, Saint Paul's Hospital, Vancouver, British Columbia, Canada

ABSTRACT

Patients with heritable aortic disease (HAD) have an increased risk of ventricular arrhythmias and sudden cardiac death. Although mitral valve prolapse is common in HAD, mitral annulus disjunction (MAD) has only recently been described in these patients. This under-recognized condition may be a contributing factor to otherwise unexplained ventricular arrhythmias and sudden cardiac death in patients with HAD. This case series describes 3 patients in an adult HAD clinic who have concomitant mitral valve prolapse, MAD, and malignant arrhythmias. These cases may represent a unique disease entity or overlap syndrome, and they introduce MAD as a potential arrhythmogenic risk marker in HAD.

RÉSUMÉ

Les patients atteints de maladie aortique héréditaire (MAH) présentent un risque accru d'arythmie ventriculaire et de mort subite d'origine cardiaque. Bien que le prolapsus valvulaire mitral soit fréquent dans les cas de MAH, la disjonction annulaire mitrale (DAM) n'a été décrite que récemment chez ces patients. Cet état méconnu peut être un facteur contribuant à des arythmies ventriculaires autrement inexplicables et à la mort subite d'origine cardiaque chez les patients atteints de MAH. Cette série de cas décrit trois patients d'une clinique de MAH pour adultes qui présentent un prolapsus valvulaire mitral, une DAM et des arythmies malignes en concomitance. Ces cas peuvent représenter une entité morbide unique ou un syndrome de chevauchement, et laissent entendre que la DAM pourrait être un nouveau marqueur du risque arythmogène associé à la MAH.

Cases

Case 1 is a 26-year-old male with Marfanoid features (Ghent score: 5) and a negative aortopathy gene panel (Supplemental Appendix S1). Transthoracic echocardiography demonstrated bileaflet mitral valve prolapse (MVP) and mitral annulus disjunction (MAD; maximal distance 14 mm at the posterolateral wall; Fig. 1A, top). He had moderate mitral regurgitation with preserved left ventricle (LV) dimensions and ejection fraction. His aortic root measured 3.3 cm (z-score:

0.52). He developed exercise-induced ventricular tachycardia (VT; Fig. 2A) and received an implantable cardioverter defibrillator (ICD), which recorded several episodes of non-sustained VT and one episode of polymorphic VT. He is treated with nadolol. Due to device implantation, gadolinium-enhanced cardiac magnetic resonance (CMR) imaging could not be performed.

Case 2 is a 19-year-old male with a clinical diagnosis and family history of Marfan syndrome (MFS, Ghent score: 8), and no genetic testing. Transthoracic echocardiography demonstrated bileaflet MVP and MAD (maximal distance 18 mm at the posterolateral wall), with moderate to severe mitral regurgitation (Fig. 1, D-F). His LV was dilated, with an end-diastolic diameter of 70 mm and an end-systolic diameter of 42 mm, with an ejection fraction of 57%. His aortic root was dilated at 4.5 cm (z-score: 4.76). He had atrial fibrillation and frequent ventricular ectopy (2523 premature ventricular contractions in 24 hours, 1.6% of total QRS complexes). An electrocardiogram showed ventricular ectopy originating from the mitral annulus (Fig. 2B). A VT stimulation study showed

Received for publication May 29, 2021. Accepted June 23, 2021.

Ethics Statement: This study was approved by the institutional ethics review board and adhered to all relevant ethical guidelines.

[†]Co-senior authors.

Corresponding author: Dr Zachary Laksman, Department of Medicine, University of British Columbia, Room 211-1033 Davie St, Vancouver, British Columbia V6E 1M7, Canada. Tel.: +1-604-806-8256; fax: +1-604-806-9274.

E-mail: zlaksman@mail.ubc.ca

See page 1399 for disclosure information.

Novel Teaching Points

- MAD should be recognized and quantitatively assessed in patients with HAD.
- Patients with HAD and concomitant MVP and MAD should be evaluated for arrhythmia.
- More research is required to improve the yield of genetic testing and assist in arrhythmia risk stratification in patients with HAD.

inducible ventricular fibrillation, prompting ICD insertion. His ICD subsequently recorded several brief episodes of VT and one discharge for VT/ventricular fibrillation (Fig. 2C). He is treated with digoxin, valsartan, sotalol, and aspirin. Due to device implantation, gadolinium-enhanced CMR imaging could not be performed.

Case 3 is a 45-year-old female with MASS syndrome (mitral valve prolapse, aortic root diameter at upper limits of normal for body size, stretch marks of the skin, and skeletal conditions

similar to Marfan syndrome), a variant in the *FBNI* gene (Supplemental Appendix S1), and a family history of sudden cardiac death (SCD). Transthoracic echocardiography revealed bileaflet MVP and suspected MAD with mild mitral regurgitation. Her LV dimensions and ejection fraction were normal. Her aortic root measured 3.0 cm (z-score: -0.83). CMR imaging (Fig. 1, G-H) confirmed the presence of MAD (maximal distance 12 mm) and no areas of delayed gadolinium enhancement. A 24-hour Holter monitor (Fig. 2D) revealed sinus rhythm with frequent ventricular ectopy (1018 [1.1%] in 24 hours). The patient is managed conservatively.

Discussion

This case series uniquely describes 3 patients with heritable aortic disease (HAD) and ventricular arrhythmias (VAs), in the setting of MVP and MAD, although all 3 patients display distinctly different clinical and genetic characteristics. MAD refers to the abnormal atrial displacement of the mitral valve leaflet hinge point and is common in the setting of MVP. MAD has been described as a risk factor for malignant MVP.

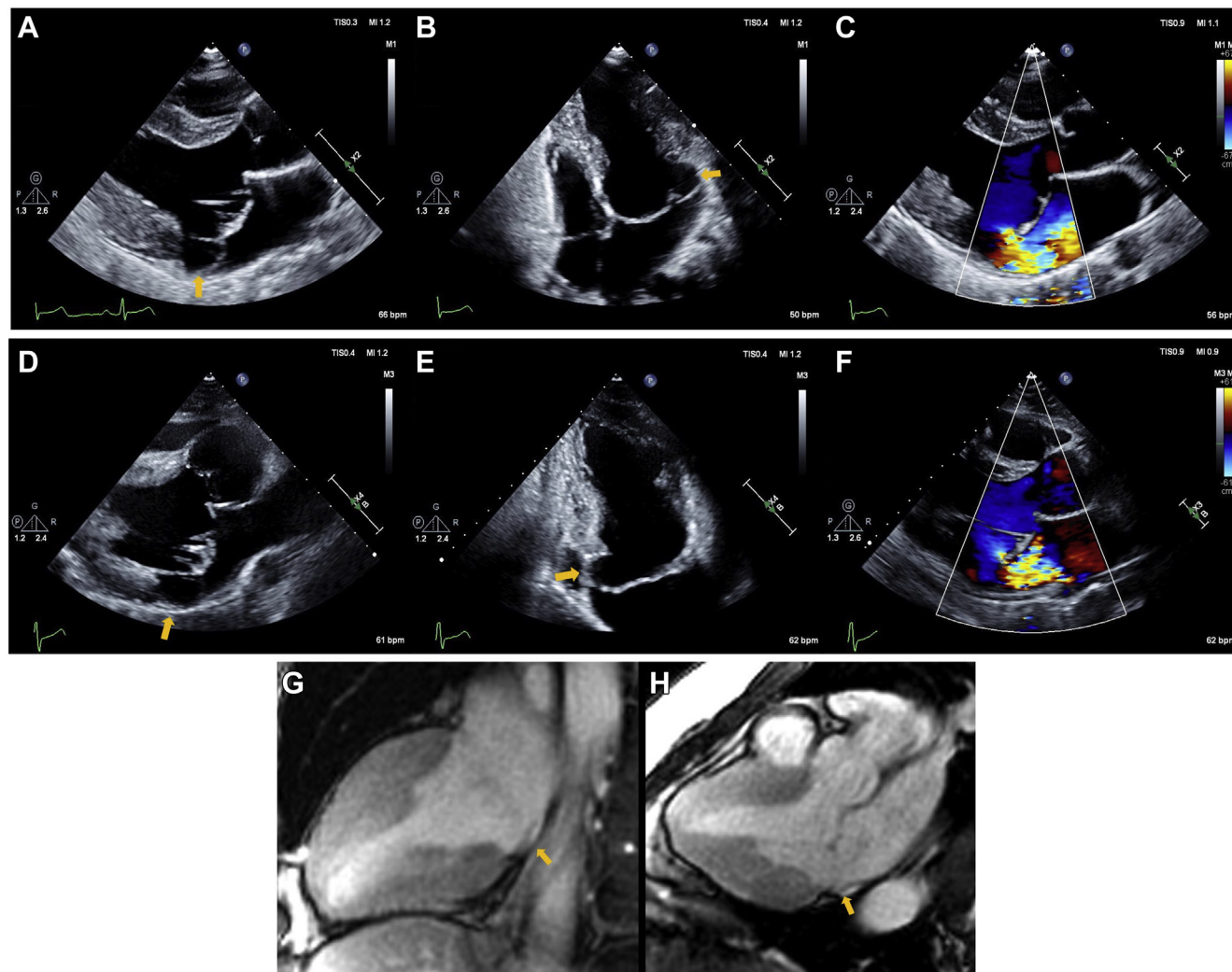


Figure 1. Imaging: (A-C) case 1 mitral annulus disjunction (MAD) seen in the posterolateral and anterolateral wall. (D-F) Case 2 MAD seen in the posterolateral and inferior wall. (G,H) Case 3 MAD seen in the inferior and inferolateral wall. **Yellow arrows** indicate areas of MAD.

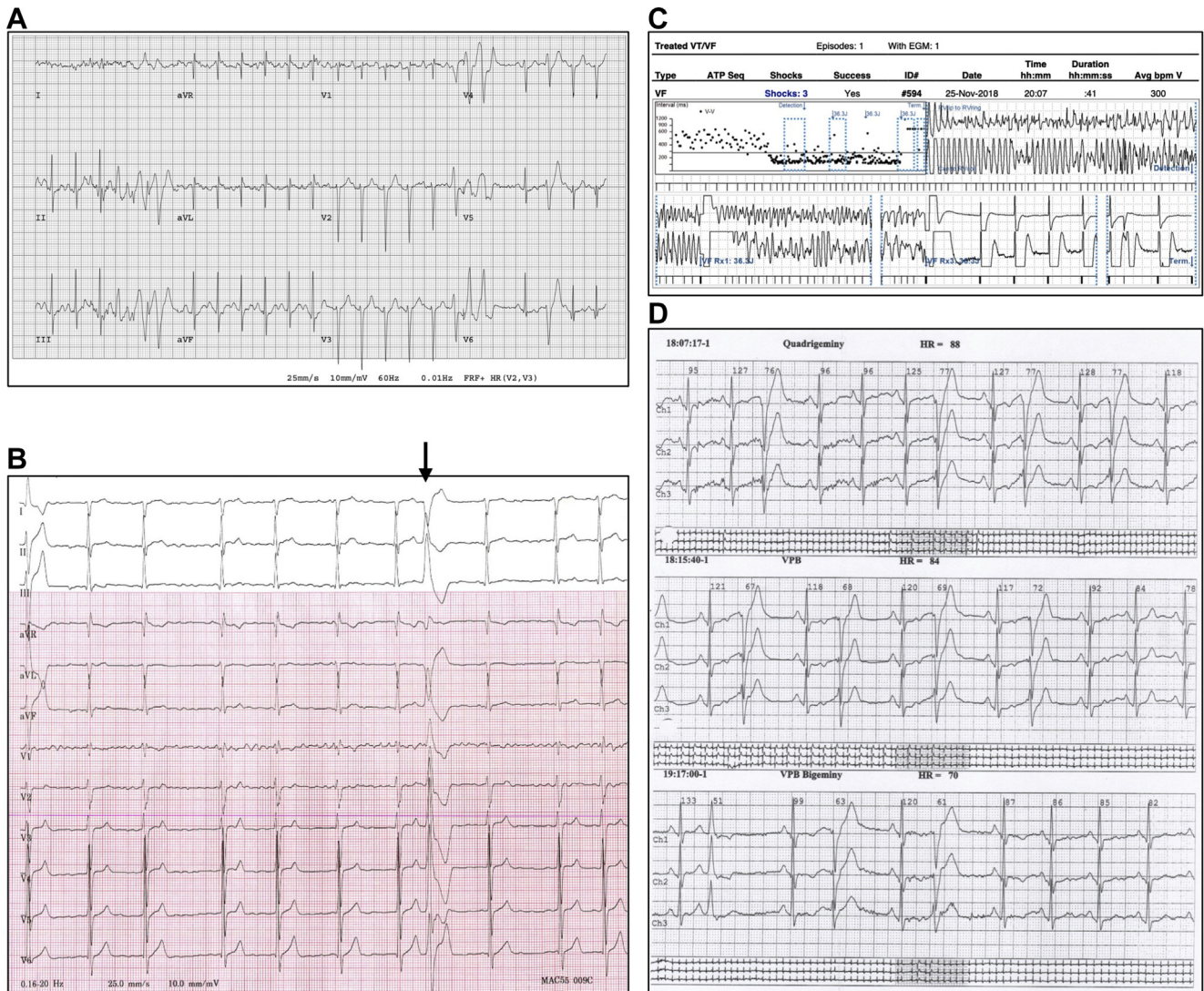


Figure 2. Electrophysiology: **(A)** Case 1: Graded exercise stress test shows brief triplets of rapid polymorphic ventricular tachycardia (VT). **(B, C)** Case 2: 12-lead electrocardiogram shows a ventricular ectopic localizing to the mitral annulus (**black arrow**), and implantable cardioverter defibrillator (ICD) report shows discharge due to ventricular fibrillation (VF). **(D)** Case 3: 24-hour Holter monitor shows frequent ventricular ectopics.

Others include bileaflet prolapse, younger age, myocardial fibrosis, and enlarged cardiac chambers.¹ Interestingly, MAD can occur without MVP, and arrhythmic MAD is associated with younger age, lower LV ejection fraction, and papillary muscle fibrosis.² Although VA and SCD have been described in children and adults with MFS, the mechanism and associated risk markers are not well elucidated.³ VA in MFS is associated with MVP and previous aortic surgery, and it is correlated with mitral regurgitation severity, increasing LV dimensions, and increasing Ghent score.⁴ Up to 40% of patients with MFS and Loey–Dietz syndrome demonstrate echocardiographic evidence of MAD, which is associated with aortic events at a younger age and a greater need for mitral surgery. Furthermore, MAD is more common in patients with documented VA.⁵

With emerging clinical experience linking MAD and MVP to risk of SCD, this case series highlights 3 patients who present with features of malignant MVP and MAD with underlying HAD. As yet unclear is whether this case series

highlights a unique disease entity with a common pathophysiologic substrate, represents unique patients with overlap syndromes, or introduces MAD as an arrhythmogenic risk marker in aortopathy syndromes. This report highlights the variability in clinical presentation and the current limitations in genetic testing in this subset of aortic patients. Arrhythmia risk stratification in patients with HAD and complex structural heart disease can be challenging, emphasizing the need for more research in this area.

Limitations

Our case series has important limitations. All patients did not undergo the same genetic testing ([Supplemental Appendix S1](#)), and expanding the genes under investigation in this cohort may play a role in the future. Although cardiac fibrosis has been implicated as a risk factor for ventricular arrhythmias in related disorders, we were unable to quantitate fibrosis by

CMR imaging, owing to ICD implantation in 2 patients. Finally, future research with large cohorts is required to delineate the arrhythmogenic risk related to MAD, and in patients with vs without HAD.

Funding Sources

This project received funding from the Cardiology Academic Practice Plan from the University of British Columbia (Z.L.). The other authors have no funding sources to declare.

Disclosures

The authors have no conflicts of interest to disclose.

References

1. Essayagh B, Sabbag A, Antoine C, et al. Presentation and outcome of arrhythmic mitral valve prolapse. *J Am Coll Cardiol* 2020;76:637-49.
2. Dejgaard LA, Skjølsvik ET, Lie ØH, et al. The mitral annulus disjunction arrhythmic syndrome. *J Am Coll Cardiol* 2018;72:1600-9.
3. Yetman AT, Bornemeier RA, McCrindle BW. Long-term outcome in patients with Marfan syndrome: is aortic dissection the only cause of sudden death? *J Am Coll Cardiol* 2003;41:329-32.
4. Mah DY, Sleeper LA, Crosson JE, et al. Frequency of ventricular arrhythmias and other rhythm abnormalities in children and young adults with the Marfan syndrome. *Am J Cardiol* 2018;122:1429-36.
5. Chivulescu M, Krohg-Sørensen K, Scheirlynck E, et al. Mitral annulus disjunction is associated with adverse outcome in Marfan and Loeys–Dietz syndromes. *Eur Hear J Cardiovasc Imaging* 2020 Dec 6: jeaa324.

Supplementary Material

To access the supplementary material accompanying this article, visit *CJC Open* at <https://www.cjopen.ca/> and at <https://doi.org/10.1016/j.cjco.2021.06.013>.