



OPEN ACCESS

CASE REPORT

Rare histotype of sporadic Creutzfeldt-Jakob disease, clinically suspected as corticobasal degeneration

Bension Shlomo Tilley,¹ Colin Smith,² Nicola Pavese,³ Johannes Attems³¹Department of Medicine, Imperial College London, London, UK²National Creutzfeldt-Jakob Disease Research and Surveillance Unit, University of Edinburgh, Edinburgh, UK³Institute of Neuroscience, Newcastle University, Newcastle Upon Tyne, UK**Correspondence to**

Mr Bension Shlomo Tilley, bt1112@ic.ac.uk

Accepted 15 February 2019

SUMMARY

Sporadic Creutzfeldt-Jakob disease (sCJD) is a rare neurodegenerative disease that can mimic other neurological disorders. We present a case of sCJD in a 64-year-old man that presented with corticobasal syndrome and survived for 3 years. He presented initially with dementia, hemiparkinsonism and alien limb phenomenon and was diagnosed with corticobasal degeneration, ultimately progressing to immobility and akinetic mutism. With a normal MRI 1 year before onset, his neuroimaging 1 year later revealed abnormal DaTscan, cortical and hippocampal atrophy with ventricular dilatation on MRI, and diffusion-weighted cortical ribboning and thalamic hyperintensity. Postmortem, the patient's brain was collected by the Parkinson's UK Tissue Bank. Prion protein immunohistochemistry revealed widespread diffuse microvacuolar staining without kuru-type plaques. Hyperphosphorylated tau was only found in the entorhinal cortex and hippocampus. This case highlights the clinical heterogeneity of sCJD presentation and the important inclusion of CJD in the differential diagnosis of atypical presentations of neurodegenerative disease.

BACKGROUND

Creutzfeldt-Jakob disease (CJD) is a transmissible spongiform encephalopathy caused by the pathological accumulation of aberrant prion protein (PrP), neuronal death and spongiform change throughout the brain. With an incidence of approximately 1 in 1 000 000, CJD is a rare but fatal condition. CJD has several possible aetiologies: sporadic (sCJD), familial, iatrogenic (iCJD) and variant CJD (vCJD) in which PrP is transmitted to humans across a species barrier. Different aetiologies of CJD present with different clinical and pathological phenotypes. vCJD typically has an earlier age of onset of approximately 26 years,¹ compared with sCJD in which only 4.5% of cases present before the age of 40 years. vCJD typically presents with behavioural and psychiatric symptoms followed later by sensory abnormalities, ataxia and dementia. In contrast, iCJD and sCJD are more likely to show a clinically and pathologically heterogeneous picture. Histologically, florid plaques are seen in vCJD, whereas iCJD and sCJD can show varying severities of PrP deposition, including 'kuru-like' plaques. Here we present a case of sCJD with an atypical presentation with parkinsonism, prominent early dementia and death within 3 years of symptom onset. We have been able to perform a detailed neuropathological

investigation, and have identified this case as a rare subtype of this rare disease, with an unusually long disease course.

CASE PRESENTATION

A 64-year-old male patient who had previously been investigated for tension headaches presented with a 2-year history of memory impairment, reduced attention and alertness. These were present alongside an 'alien' left arm with numbness and cramps, mild resting and postural tremor, bradykinesia, increased tone and reduced arm swing, more so on the left. He exhibited amnesia for recent events, executive dysfunction, anomia and apractagnosia. This clinical syndrome met the consensus diagnostic criteria for probable sporadic corticobasal degeneration (CBD), given the asymmetric limb bradykinesia and rigidity, multiple higher cortical signs.² He retained only partial insight into his condition. He did not smoke and took minimal alcohol. The family history was negative for neurological disease.

INVESTIGATIONS

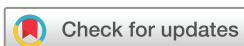Initial Mini Mental State Examination yielded a score of 28/30 with deficits in recall and visuospatial function. Addenbrooke's cognitive examination yielded a score of 74/100 with prominent deficits in memory, fluency, language and visuospatial domains. There was no evidence of rapid eye movement-sleep behaviour disorder, visual hallucinations or fluctuating cognition, which are core features for the diagnosis of dementia with Lewy bodies (DLB).³ DaTScan revealed heterogeneous uptake bilaterally in the basal ganglia (figure 1A) more so on the right than left, which does not suggest Parkinson's disease. During investigation for tension headaches 1 year previously, an MRI scan was performed which showed T2-weighted hyperintensities in the basal ganglia and cortical white matter (figure 1B,C), but an otherwise normal cerebrum (figure 1D). By 2-years postpresentation, the MRI showed significant cortical and hippocampal atrophy on MRI (figure 1E), cortical ribboning and thalamic high signal on diffusion-weighted imaging (figure 1F).

DIFFERENTIAL DIAGNOSIS

An initial working differential diagnosis of CBD or DLB, despite a lack of DLB core clinical features,³ was made.

TREATMENT

The patient was prescribed 10mg daily of the cholinesterase inhibitor donepezil.



© BMJ Publishing Group Limited 2019. Re-use permitted under CC BY-NC. No commercial re-use. See rights and permissions. Published by BMJ.

To cite: Tilley BS, Smith C, Pavese N, et al. *BMJ Case Rep* 2019;**12**:e228305. doi:10.1136/bcr-2018-228305

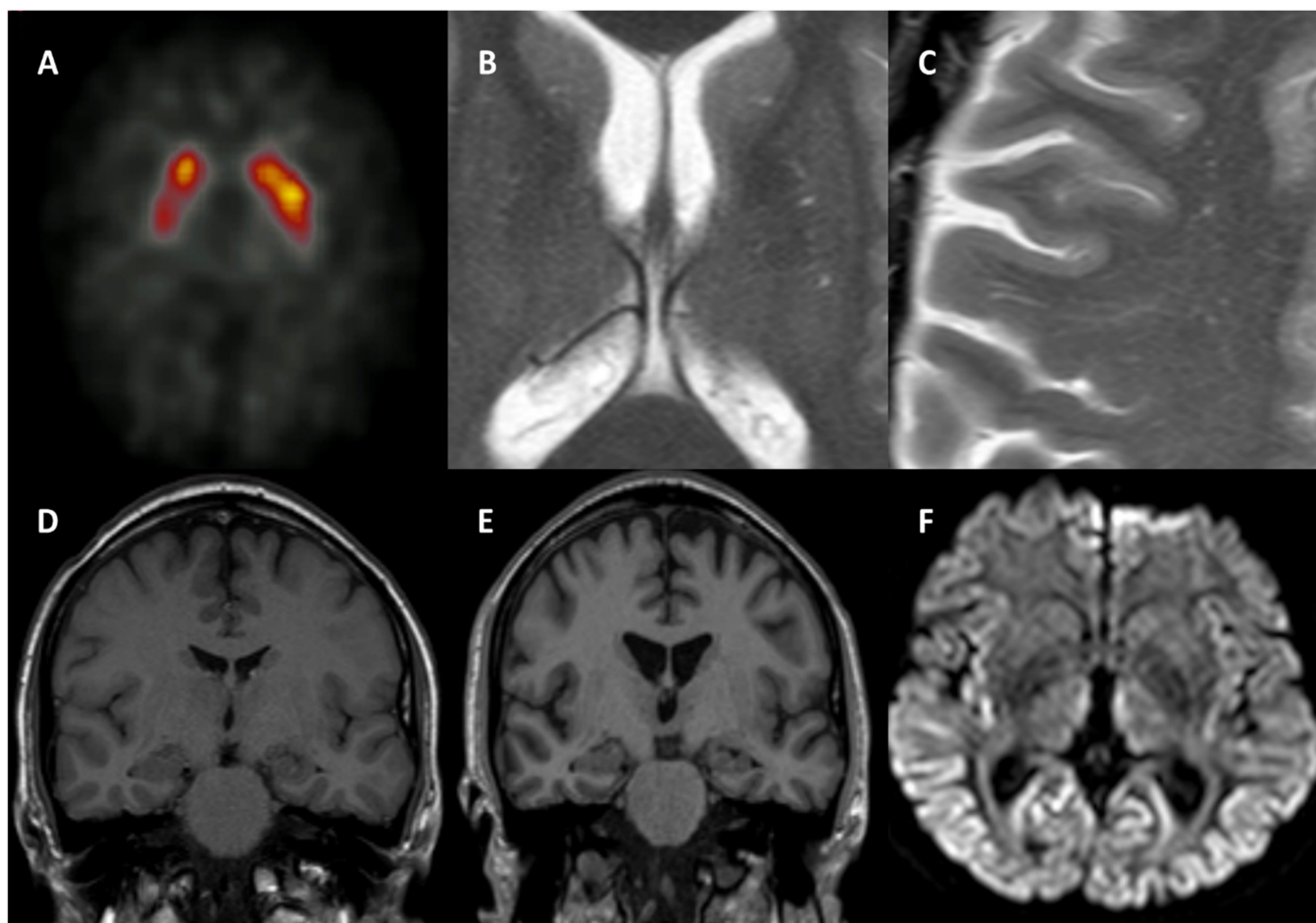


Figure 1 Neuroimaging findings. (A) DaTscan of basal ganglia 1 year after onset showing heterogeneous but atypical reduced uptake. (B) T2-weighted MRI showing hyperintensities in the basal ganglia (C) T2-weighted MRI showing hyperintensities in cerebral white matter at 1 year before onset. (D) Coronal MRI from 1 year before onset (background of chronic headaches). (E) Coronal MRI from 1 year after onset showing significant cortical and hippocampal atrophy and ventricular dilatation. (F) Diffusion-weighted MRI from 1 year after onset showing hyperintense cortical ribboning in the frontal, parietal and occipital cortices, insula and thalamus.

OUTCOME AND FOLLOW-UP

By the next visit, at 3 months after presentation, significant deficits in global cognition were noted, despite cholinesterase inhibition. At 6 months, the patient had developed marked fatigue, word-finding difficulties and a stammer which severely impeded speech. Significant deficits in cognition were also present: a Rowland University Dementia Assessment Scale was applied, yielding a score of 9/30 with marked deficits in praxis, visuo-constructive function, judgement, memory and language. Rivastigmine was prescribed in place of donepezil.

By 1.5 years after initial examination, his parkinsonism had worsened considerably with increased tremor and rigidity of the left hand, multiple falls, bilateral apraxia and bradykinesia of the hands (worse on the left), a fixed flexion deformity of the left hand. Reduced upgaze was noted on examination, raising the possibility of a diagnosis of an atypical parkinsonian syndrome. An initial dose of levodopa was prescribed in the form of 62.5 mg of levodopa, taken to times per day. However, there was no clear response to levodopa.

By 2 years postpresentation, the patient had become wheelchair-bound, was experiencing rest tremors bilaterally, postural instability, significant axial and limb rigidity and akinetic

mutism. Neuroimaging showed significant cortical and hippocampal atrophy, ventricular dilatation, diffusion-weighted cortical ‘ribboning’ in the frontal and occipital cortices and basal ganglia hyperintensities. The patient passed away soon after due to causes secondary to parkinsonism. His brain was collected by the Parkinson’s UK Tissue Bank at Imperial College London.

Gross macroscopic examination revealed cortical and cerebellar atrophy, dilatation of the ventricular system but a well-pigmented substantia nigra.

Microscopically, prominent microvacuolation (figure 2A-F) was found in the cortex, striatum hippocampus, cerebellum and thalamus. Immunostaining for α -synuclein revealed no immunopositive structures in any region. There were frequent amyloid- β plaques in the frontal, temporal, entorhinal and transentorhinal cortices and striatum. Immunostaining for hyperphosphorylated tau revealed moderate neurofibrillary tangle and neuropil thread pathology in the entorhinal and transentorhinal cortices only. A diagnosis of spongiform encephalopathy was made and the case was sent to the National CJD Research and Surveillance Unit in Edinburgh for further neuropathological assessment.

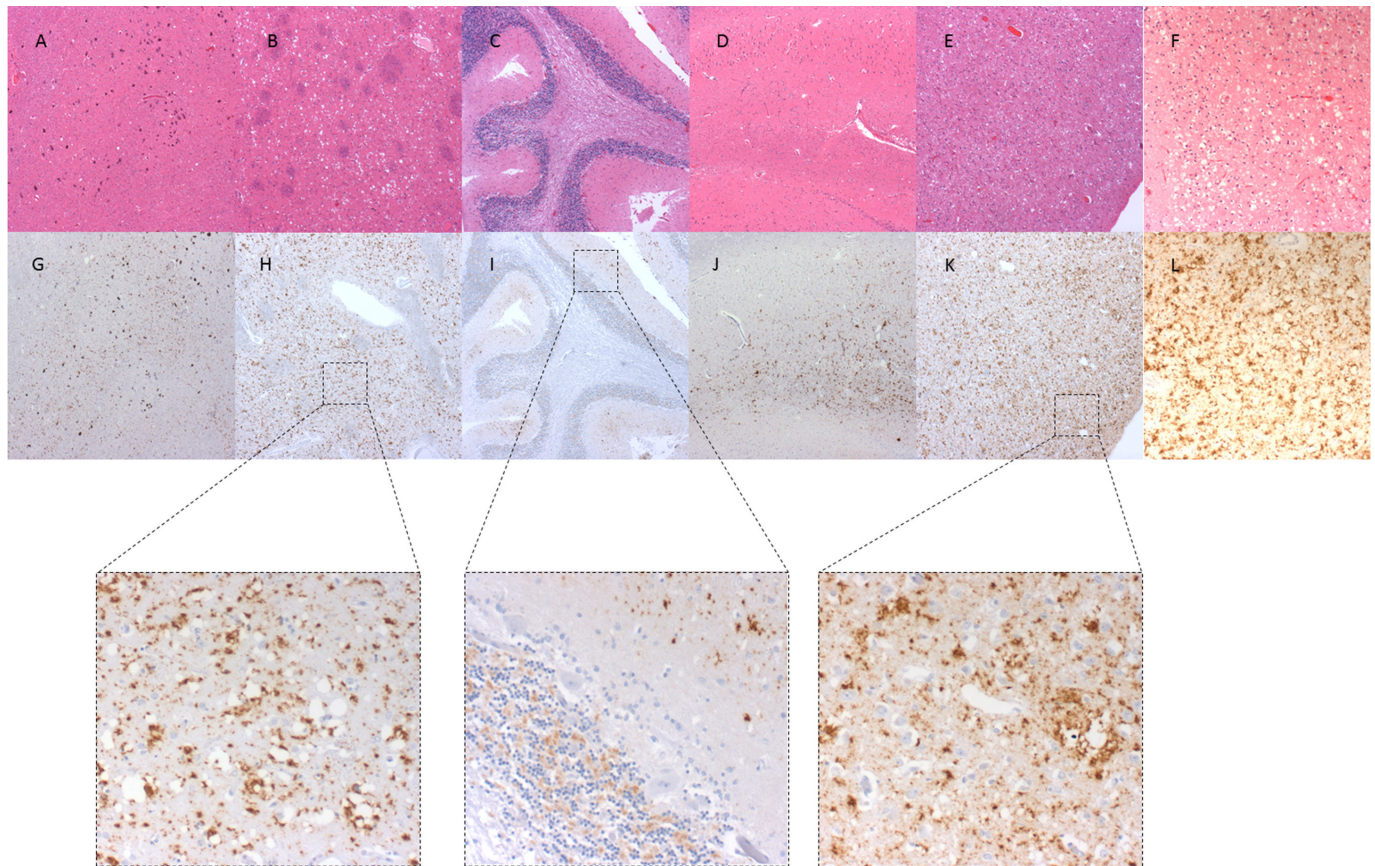


Figure 2 Neuropathology slides for the substantia nigra, caudate, cerebellum, hippocampus and cingulate gyrus. Top row: H&E stained slides, (A) substantia nigra, (B) caudate, (C) cerebellum, (D) hippocampus, (E) cingulate gyrus, (F) frontal cortex. Bottom row: slides immunostained with antibodies against prion protein, (G) substantia nigra, (H) caudate, (I) cerebellum, (J) hippocampus, (K) cingulate gyrus, (L) frontal cortex. Images taken with ImageProPlus V.7.0 at $\times 400$ magnification ($\times 1000$ for F & L to show intense vacuolation in cortex). Inset are $\times 2000$ magnification images of pathology from caudate, cerebellum and cingulate gyrus.

Immunostaining for PrP (figure 2G-L) revealed widespread deposition in an intense perivacuolar pattern, without kuru-type plaques. Severe deposition was found throughout the cortex and basal ganglia, while the hippocampus, substantia nigra and cerebellum were relatively spared.

Western blot analysis confirmed a protease-resistant PrP with regional variation of the PrP isoforms present. In the frontal cortex, the type 2A isoform was detected with a low molecular weight (LMWt) band. The type 1A isoform was detected in the cerebellum, again with a LMWt band.

Analysis of the codon 129 polymorphism in the PrP gene showed that this patient was a methionine/valine heterozygote. Full sequence analysis of the PrP gene found no pathogenic mutations.

DISCUSSION

We report a case, clinically thought to be CBD, but at post-mortem was found to be sCJD. This was a diagnosis that was not considered due to a long disease course, meaning that no cerebrospinal fluid (CSF) analysis for 14-3-3 protein was performed. However, the specificity of this test has been questioned. In one study, a false positive rate of approximately 30% was found in a population with 14-3-3 protein detected in the CSF who also met diagnostic criteria for probable sCJD.⁴ Only 59% of this population were found to have sCJD and, interestingly, none were found to have CBD pathology.⁴ A diagnostic test such as real-time quaking induced conversion (RT-QuIC), with

a similar sensitivity to 14-3-3 CSF analysis but a specificity rate of 98%–100%^{5,6} would have been a more useful test for the diagnosis of CJD before the patient's death. Nonetheless, histological, immunohistochemical and biochemical analysis of this case confirms a diagnosis of sCJD of the met/val heterozygote PrP strain 2 (MV2) subtype classification. sCJD MV2 can be further subdivided as being predominantly cortical (C), as having kuru-like plaques (K), or a mixture (K+C). The pathology in this case was predominantly of a cortical type with absence of kuru-type plaque pathology, allowing a further subclassification into the MV2C (cortical) histotype: a relatively rare form of a rare disease.

While the clinical phenotype is variable, sCJD should always be considered in any patient with a rapidly progressing dementia. However, as this case shows, sCJD should also be considered in cases with slower progression, particularly when the symptoms are atypical for more common disorders such as CBD or DLB. sCJD MV2C has been described as having a longer clinical duration, and typically presents with ataxia, but can present with extrapyramidal symptoms such as parkinsonism. The present case showed an atypical parkinsonian syndrome with alien limb phenomenon, suggestive of a corticobasal syndrome. Corticobasal syndrome was previously reported in a case of CJD by Zhang *et al*, but this lacked pathological workup of the case.⁷ Similarly, Erdal *et al* found corticobasal symptoms in a case of CJD confirmed by CSF biomarker analysis.⁸ Lee and colleagues sought to characterise the clinical syndrome in cases of sCJD

presenting with CBS.⁹ Their data showed that the clinical syndrome is highly variable between cases. However, they found that the clinical features most prevalent in sCJD-CBS cases were alien limb phenomena, limb apraxia, rigidity, sensory loss, myoclonus and cognitive impairment, all of which were present in the case we have presented. Marin *et al* reported a case of suspected CJD causing a clinical syndrome similar to DLB,¹⁰ however this report also lacked pathological confirmation of the diagnosis. In a previous cohort study, 46% of sCJD patients met clinical diagnostic criteria for DLB.¹¹ CJD is one of the main differential diagnoses for DLB. Because cases with the MV2C subtype have a slower disease onset and progression than typical sCJD, which is usually fatal within 6–12 months, they can frequently be misdiagnosed.

There are multiple diagnostic neuroimaging findings for sCJD, some of which were present in this case and are atypical for both CBD and DLB. These include diffuse-weighted imaging (DWI) findings of high signal in the cortex and basal ganglia. Further to this, specific polymorphisms of sCJD show different patterns of DWI lesions, whereby cases that are PrP codon 129 homozygotes generally show focal, and heterozygotes more diffuse abnormalities.¹² In this case, diffuse cortical ‘ribboning’ was observed, and hyperintensity in the thalamus (a finding present in at least 43% of heterozygous sCJD).¹²

Our clinical diagnostic criteria for neurodegenerative disorders more generally lack specificity, with a number of comorbid pathologies being noted in clinicopathological studies of clinically defined conditions such as Alzheimer’s disease, where α -synuclein, tau DNA binding protein-43 and vascular pathology are found to significantly contribute to the neurodegeneration.^{13–15} Though this case demonstrated the clinical diagnostic criteria for probable CBD, it also exhibited signs suggestive of probable CJD by University of California San Francisco criteria¹⁶: dementia, extrapyramidal features, higher cortical signs (such as apraxia) and akinetic mutism with typical neuroimaging findings. There is a need in the wider field to address the high error rate in the diagnostic criteria for neurodegenerative diseases such as sCJD or CBD.

Learning points

- ▶ Sporadic Creutzfeldt-Jakob disease (sCJD) is an important differential diagnosis in cases of atypical neurodegenerative syndromes.
- ▶ Diffusion-weighted imaging alongside other imaging and cerebrospinal fluid real-time quaking induced conversion can aid diagnosis in atypical cases.
- ▶ sCJD should be considered in all cases with severe and rapid cerebral atrophy demonstrated on MRI.

Acknowledgements This manuscript would not have been possible without the generous donation of the patient to the Parkinson’s UK Tissue Bank and the kind help of his family in giving consent for the publication of this case study. BST studies are funded by the Jean Shanks Foundation and National Institute on Aging, National Institutes of Health, grant code: NIA AG12411.

Contributors BST was responsible for the clinical audit of the case at the Parkinson’s UK Tissue Bank; was involved in drafting the manuscript. NP was the consultant neurologist who cared for the patient in clinic; was involved in drafting the manuscript. CS was responsible for the neuropathological assessment of the case at the National CJD Surveillance Unit, Edinburgh; was involved in drafting the manuscript. JA was responsible for the initial neuropathological assessment of the case on behalf of the Parkinson’s UK Tissue Bank; was involved in drafting the manuscript.

Funding The authors have not declared a specific grant for this research from any funding agency in the public, commercial or not-for-profit sectors.

Competing interests None declared.

Patient consent for publication Next of kin consent obtained.

Provenance and peer review Not commissioned; externally peer reviewed.

Open access This is an open access article distributed in accordance with the Creative Commons Attribution Non Commercial (CC BY-NC 4.0) license, which permits others to distribute, remix, adapt, build upon this work non-commercially, and license their derivative works on different terms, provided the original work is properly cited and the use is non-commercial. See: <http://creativecommons.org/licenses/by-nc/4.0/>

REFERENCES

- 1 Will RG, Steiner M, Stewart GE, *et al*. Diagnosis of new variant Creutzfeldt-Jakob disease. *Ann Neurol* 2000;47:575–82 <http://www.ncbi.nlm.nih.gov/pubmed/10805327>.
- 2 Armstrong MJ, Litvan I, Lang AE, *et al*. Criteria for the diagnosis of corticobasal degeneration. *Neurology* 2013;80:496–503.
- 3 McKeith IG, Boeve BF, Dickson DW, *et al*. Diagnosis and management of dementia with Lewy bodies: Fourth consensus report of the DLB Consortium. *Neurology* 2017;89:1–13.
- 4 Pecku L, Delasnerie-Lauprêtre N, Brandel JP, *et al*. Accuracy of diagnosis criteria in patients with suspected diagnosis of sporadic Creutzfeldt-Jakob disease and detection of 14-3-3 protein, France, 1992 to 2009. *Euro Surveill* 2017;22:1–8.
- 5 McGuire LI, Peden AH, Orrú CD, *et al*. Real time quaking-induced conversion analysis of cerebrospinal fluid in sporadic Creutzfeldt-Jakob disease. *Ann Neurol* 2012;72:278–85.
- 6 McGuire LI, Poggioli A, Poggolini I, *et al*. Cerebrospinal fluid real-time quaking-induced conversion is a robust and reliable test for sporadic creutzfeldt-jakob disease: An international study. *Ann Neurol* 2016;80:160–5.
- 7 Zhang Y, Minooshima S, Vesselle H, *et al*. A case of creutzfeldt-jakob disease mimicking corticobasal degeneration. *Clin Nucl Med* 2012;37:e173–e175.
- 8 Erdal Y, Cimen Atalar A, Emre U. Sporadic creutzfeldt-jacob disease presenting with symptoms of corticobasal degeneration: A case report. *Journal of Neurology and Neuroscience* 2016;07:1–4.
- 9 Lee W, Simpson M, Ling H, *et al*. Characterising the uncommon corticobasal syndrome presentation of sporadic Creutzfeldt-Jakob disease. *Parkinsonism Relat Disord* 2013;19:81–5.
- 10 Marin LF, Felicio AC, Bichuetti DB, *et al*. Clinical findings in creutzfeldt-jakob disease mimicking dementia with lewy bodies. *Arq Neuropsiquiatr* 2008;66:741–3.
- 11 Tartaglia MC, Johnson DY, Thai JN, *et al*. Clinical overlap between Jakob-Creutzfeldt disease and Lewy body disease. *Can J Neurol Sci* 2012;39:304–10.
- 12 Meissner B, Kallenberg K, Sanchez-Juan P, *et al*. MRI lesion profiles in sporadic Creutzfeldt-Jakob disease. *Neurology* 2009;72:1994–2001.
- 13 Uchikado H, Lin W-L, DeLucia MW, *et al*. Alzheimer Disease With Amygdala Lewy Bodies. *J Neuropathol Exp Neurol* 2006;65:685–97.
- 14 Rabinovici GD, Carrillo MC, Forman M, *et al*. Multiple comorbid neuropathologies in the setting of Alzheimer’s disease neuropathology and implications for drug development, Alzheimer’s Dement. *Transl. Res. Clin. Interv* 2017;3:83–91.
- 15 Spiers-Jones TL, Attems J, Thal DR. Interactions of pathological proteins in neurodegenerative diseases. *Acta Neuropathol* 2017;134:187–205.
- 16 Budka H, Aguzzi A, Brown P, *et al*. Neuropathological diagnostic criteria for Creutzfeldt-Jakob disease (CJD) and other human spongiform encephalopathies (prion diseases). *Brain Pathol* 1995;5:459–66.

Copyright 2019 BMJ Publishing Group. All rights reserved. For permission to reuse any of this content visit <https://www.bmj.com/company/products-services/rights-and-licensing/permissions/>
BMJ Case Report Fellows may re-use this article for personal use and teaching without any further permission.

Become a Fellow of BMJ Case Reports today and you can:

- ▶ Submit as many cases as you like
- ▶ Enjoy fast sympathetic peer review and rapid publication of accepted articles
- ▶ Access all the published articles
- ▶ Re-use any of the published material for personal use and teaching without further permission

For information on Institutional Fellowships contact consortiasales@bmjgroup.com

Visit casereports.bmj.com for more articles like this and to become a Fellow