

# Interposition of the Posterior Cruciate Ligament into the Medial Compartment of the Knee Joint on Coronal Magnetic Resonance Imaging

Hyun Su Kim, MD<sup>1</sup>, Young Cheol Yoon, MD<sup>1,2</sup>, Ki Jeong Park, MD<sup>1</sup>, Joon Ho Wang, MD<sup>3</sup>,  
Bong-Keun Choe, MD<sup>4</sup>

Departments of <sup>1</sup>Radiology and <sup>3</sup>Orthopedic Surgery, Samsung Medical Center, Sungkyunkwan University School of Medicine, Seoul 06351, Korea; <sup>2</sup>Department of Medical Device Management and Research, SAIHST, Sungkyunkwan University, Seoul 06351, Korea; <sup>4</sup>Department of Preventive Medicine, Kyung Hee University School of Medicine, Seoul 02454, Korea

**Objective:** The purpose of our study was to evaluate the overall prevalence and clinical significance of interposition of the posterior cruciate ligament (PCL) into the medial compartment of the knee joint in coronal magnetic resonance imaging (MRI).

**Materials and Methods:** We retrospectively reviewed 317 consecutive patients referred for knee MRI at our institution between October 2009 and December 2009. Interposition of the PCL into the medial compartment of the knee joint on proton coronal MRI was evaluated dichotomously (i.e., present or absent). We analyzed the interposition according to its prevalence as well as its relationship with right-left sidedness, gender, age, and disease categories (osteoarthritis, anterior cruciate ligament tear, and medial meniscus tear).

**Results:** Prevalence of interposition of PCL into the medial compartment of the knee joint was 47.0% (149/317). There was no right (50.0%, 83/166) to left (43.7%, 66/151) or male (50.3%, 87/173) to female (43.1%, 62/144) differences in the prevalence. There was no significant association between the prevalence and age, or the disease categories.

**Conclusion:** Interposition of the PCL into the medial compartment of the knee joint is observed in almost half of patients on proton coronal MRI of the knee. Its presence is not associated with any particular factors including knee pathology and may be regarded as a normal MR finding.

**Index terms:** Knee; Posterior cruciate ligament; Anatomic variation; Magnetic resonance imaging

## INTRODUCTION

Magnetic resonance imaging (MRI) provides effective

Received August 27, 2015; accepted after revision January 4, 2016.

**Corresponding author:** Young Cheol Yoon, MD, Department of Radiology, Samsung Medical Center, Sungkyunkwan University School of Medicine, 81 Irwon-ro, Gangnam-gu, Seoul 06351, Korea.

- Tel: (822) 3410-6454 • Fax: (822) 3410-0084
- E-mail: [youngcheol.yoon@gmail.com](mailto:youngcheol.yoon@gmail.com)

This is an Open Access article distributed under the terms of the Creative Commons Attribution Non-Commercial License (<http://creativecommons.org/licenses/by-nc/3.0>) which permits unrestricted non-commercial use, distribution, and reproduction in any medium, provided the original work is properly cited.

visualization of normal alignment and morphology of the posterior cruciate ligament (PCL) (1, 2). Besides, it can demonstrate injury of the PCL and associated structural abnormalities. On MRI, the normal PCL is shown as a well circumscribed very low signal intensity band coursing between the medial femoral condyle and the posterior tibia. Sagittal plane imaging, with the ability to best demonstrate cruciate ligament along its anatomic course, is the most widely applied and studied imaging plane for detecting PCL abnormality (1, 3, 4). Due to the complex nature of the PCL anatomy, coronal image serves an important supplementary role to sagittal image in detecting PCL abnormality (1, 5). The posterior segment of PCL is the vertically oriented portion that is located in the intercondylar notch adjacent

to the lateral aspect of the medial femoral condyle (6). The PCL then curves anteriorly and the horizontal portion appears, which is depicted as ovoid shaped, low signal structure within the intercondylar notch on coronal MRI (7). The injuries involving horizontal and vertical portions of the PCL may be more readily identified on coronal images, even though they are often detected on sagittal images (1).

In daily practice, we occasionally see prominent medial-oriented PCL fibers between the horizontal and vertical portions of the PCL on coronal images. This segment of PCL usually appears as a wavy structure between the medial femoral condyle and medial tibial plateau. Since the wavy contour of ligament structure is often related to partial tear (4, 8, 9), it is necessary to clarify its clinical significance. However, there are no reports on this imaging finding, as well as its significance. Therefore, the purpose of this study was to evaluate the overall prevalence and clinical significance of interposition of the PCL into the medial compartment of the knee joint, as observed from coronal MRI. We also evaluated the relationship between prevalence and side (right or left), gender, age, and underlying disease categories.

## MATERIALS AND METHODS

### Patient Selection

Our Institutional Review Board approved the study, and waived the requirement for patient informed consent. Between October 2009 and December 2009, 455 consecutive patients underwent knee MRI and standard knee radiograph including weight bearing anterior-posterior and lateral projections at our institution. Among these patients, 138 patients with conditions that could affect the course of PCL (43 patients with synovial disease, 42 patients with history of PCL injury or abnormal MR finding in terms of signal intensity or thickness, 26 patients had a history of previous knee surgery, 13 patients with a tumorous condition of the knee, 5 patients with fracture, 6 patients with infection of the knee, and 3 pediatric patients whose physes were not closed) or those who did not have proton density-weighted (PDW) coronal images were excluded. Patients whose physes were not closed were excluded because we thought that bony growth and remodeling of immature bone may affect the anatomic relation between ligament and bone, including the angle and morphology of the PCL (2, 10).

A final total of 317 patients (age range, 12–79 years; mean age, 42.9 years) were included in the study, of whom

173 were men (age range, 16–72 years; mean age, 38.4 years) and 144 were women (age range, 12–79 years; mean age, 48.2 years). For patients who underwent surgery after MRI, operation records were reviewed for any abnormality of PCL.

### MRI Techniques

All of the MRIs were performed on a 3T scanner (Achieva; Philips Medical Systems, Eindhoven, the Netherlands). The knee was relaxed and placed into a dedicated 8-channel knee coil in a slightly flexed position. All studies included coronal turbo spin-echo (TSE) PDW images. Image parameters were as follows; the time of repetition range, 2200 msec; time of echo values, 30 msec; matrix, 220 x 247; field of view, 16 cm; slice thickness, 4 mm; interslice gap, 1 mm; number of average, 2; and echo train length, 15. Fat saturated PDW axial images, PDW and T2-weighted sagittal images, and three-dimensional TSE coronal images were also obtained.

### Image Analysis

Two radiologists (with 10 and 2 years' experience in musculoskeletal MR imaging, respectively) retrospectively reviewed PDW coronal images with a 4-mm slice thickness on a picture archiving and communication system (GE Medical Systems Integrated Imaging Solutions, Mt. Prospect, IL, USA) along with a LCD monitor (MDL9DLB020; Totoku, Tokyo, Japan). For evaluating of PCL interposition, a straight line was drawn (Figs. 1, 2) between the inferomedial corner of the medial femoral condyle and medial tibial spine. Interposition of the PCL into the medial compartment of the knee joint was evaluated by two scales, positive or negative, by consensus. It was classified as negative when the medial margin of the PCL was located lateral to the line (Fig. 1). When the medial margin of the PCL was located medial to the line, it was classified as positive (Fig. 2). For the analysis, diseases were divided into four categories (normal knee MRI, osteoarthritis [OA], the anterior cruciate ligament [ACL] tear, and medial meniscus [MM] tear). Patients without gross structural abnormality on knee MRI other than interposition of the PCL were categorized as "normal knee MRI". Patients with radiographic findings of grade 2 or higher on Kellgren-Lawrence grading scale were categorized as OA group by consensus of the same radiologists. The presence or absence of tears of the ACL and MM were recorded by consensus of the same radiologists. However, we excluded patients if

## Interposition of the PCL on Coronal Knee MRI

there was ACL or MM degeneration related to OA.

Operation records were reviewed by one of the authors for confirmation of arthroscopic findings of cruciate ligaments and menisci.

### Statistical Analysis

Statistical analysis was performed using PASW statistic software (version 18.0; SPSS Inc., Chicago, IL, USA). We analyzed the relation between the prevalence and side (right or left), gender, and disease categories using chi-square test. We analyzed the relation between the prevalence and age using Student's *t* test. A *p* value < 0.05 was considered to indicate a statistically significant difference.

## RESULTS

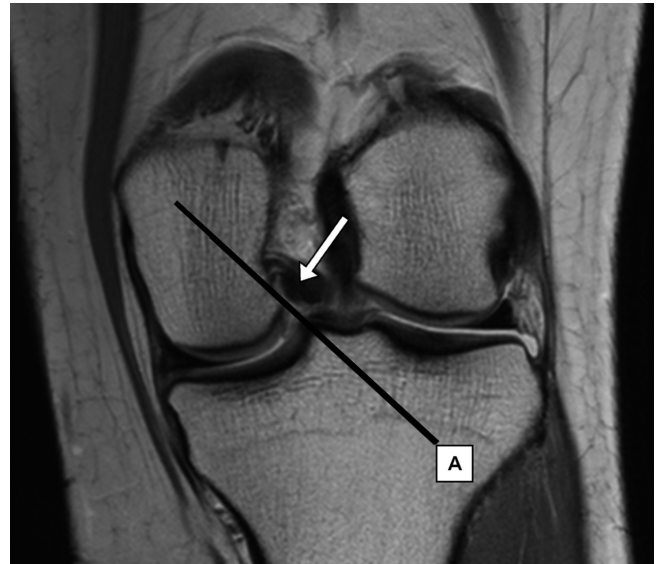The prevalence of interposition of the PCL into the medial compartment of the knee joint and the result of statistical analysis was summarized in Table 1.

### Prevalence

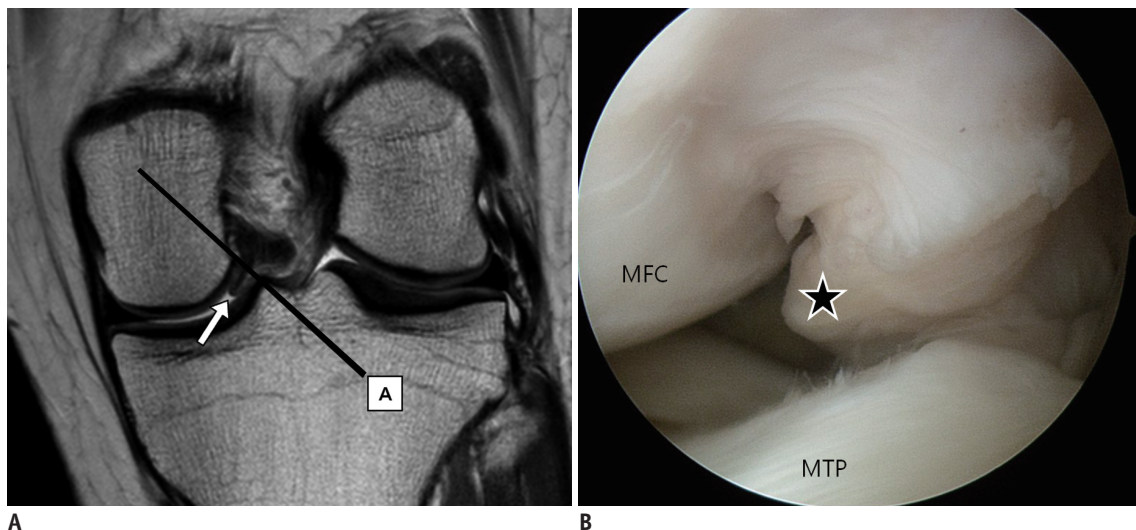
The prevalence of interposition of the PCL into the medial compartment of the knee joint was 47.0% (149/317), with a prevalence of 50.0% (83/166) for the right knee and 43.7% (66/151) for the left knee. In terms of gender, the prevalence of males was 50.3% (87/173) and females, 43.1% (62/144).

### Relation–Side, Gender, and Age

Prevalence showed no significant right (50.0%, 83/166) or left (43.7%, 66/151) predominance (*p* = 0.518). Male (50.3%, 87/173) and female (43.1%, 62/144) differences were also not statistically significant (*p* = 0.415). There was



**Fig. 1.** 47-year-old woman with low grade chondral lesion at retro-patellar cartilage. Proton density weighted (repetition time, 2200 msec; echo time, 30 msec) coronal MR image of left knee. Medial margin of PCL is located lateral to line between inferomedial corner of medial femoral condyle and medial tibial spine (arrow). This case was classified as negative for interposition of PCL into medial compartment of knee joint. PCL = posterior cruciate ligament



**Fig. 2.** 44-year-old woman with partial tear of anterior cruciate ligament. Proton density weighted (repetition time, 2200 msec; echo time, 30 msec) coronal MR image (A) of left knee shows focal outward bulging contour at medial margin of PCL, confined to medial side of line between inferomedial corner of medial femoral condyle and medial tibial spine (arrow). This case was classified as positive for interposition of PCL into medial compartment of knee joint. Arthroscopic image of medial compartment obtained with knee flexion position (B) shows same focal outward bulging contour of PCL (asterisk) between medial femoral condyle (MFC) and medial tibial plateau (MTP). PCL = posterior cruciate ligament

no significant correlation between prevalence and age ( $p = 0.418$ ).

**Prevalence and Relation–Disease Categories**

When the disease was divided into four categories, there were 78 knee joints without structural abnormality on MRI, 85 OA, 56 ACL tears, and 111 MM tears (Fig. 3). There were 20 cases of coexistent tear of the ACL and MM. Prevalence of interposition of the PCL into the medial compartment of

the knee were 51.3% (40/78) in knee joints with normal MRI, 50.6% (43/85) in OA, 32.1% (18/56) in ACL tears and 39.6% (44/111) in MM tears. There was no significant relation between prevalence and disease categories (normal knee MRI vs. OA,  $p = 0.983$ ; normal knee MRI vs. ACL tear,  $p = 0.084$ ; normal knee MRI vs. MM tear,  $p = 0.055$ ).

**Operation Records**

After undergoing a knee MRI, 66 patients underwent arthroscopic surgery (45 patients underwent internal derangement repair surgery, 13 underwent chondroplasty and microfracture, 4 patients underwent lateral retinacular release, and 4 patients underwent soft tissue excision for impingement). Among the patients who underwent arthroscopic surgery, 24 (36.4%, 24/66) showed interposition of the PCL on preoperative knee MRI. There was no reported tear or degeneration of the PCL on operation records.

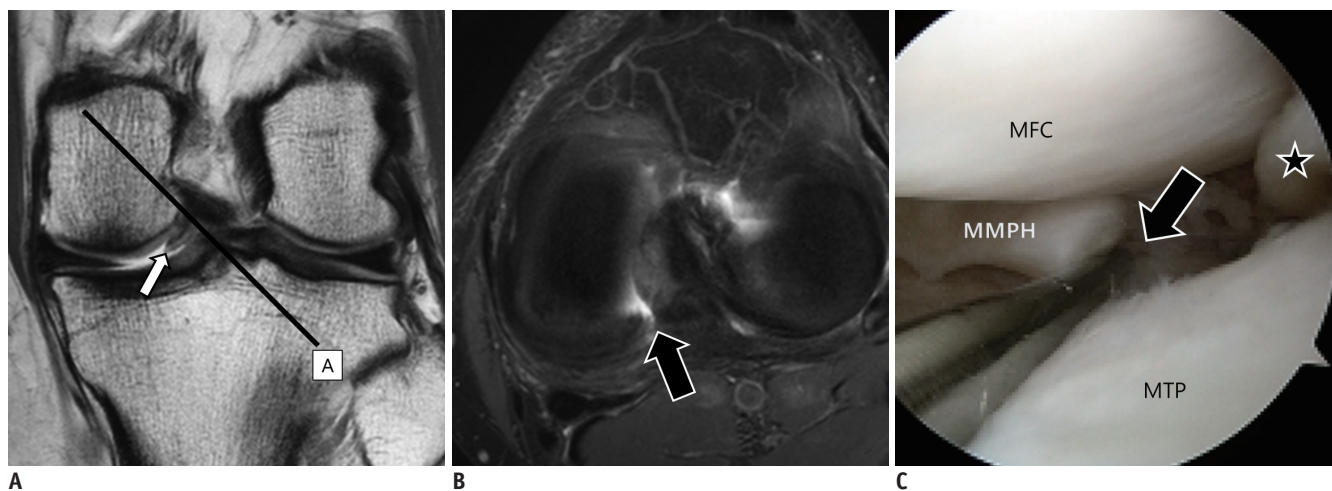
**Table 1. Prevalence and Its Relation to Clinical Variables of Interposition of PCL into Medial Compartment of Knee Joint**

	Prevalence	<i>P</i>
Overall	149/317 (47.0%)	
Side		0.518
Right	83/166 (50.0%)	
Left	66/151 (43.7%)	
Gender		0.415
Male	87/173 (50.3%)	
Female	62/144 (43.1%)	
Disease		
Normal knee MRI	40/78 (51.3%)	
OA	43/85 (50.6%)	0.983*
ACL tear	18/56 (32.1%)	0.084*
MM tear	44/111 (39.6%)	0.055*
Age		0.418

\**P* values were measured by comparison with normal knee MRI group. ACL = anterior cruciate ligament, MM = medial meniscus, OA = osteoarthritis, PCL = posterior cruciate ligament

**DISCUSSION**

Our study results indicated that interposition of the PCL into the medial compartment of the knee joint is a common imaging finding in almost half of the patients on coronal MRI. Neither age nor gender was relevant factor for the prevalence, which suggested that this imaging feature is unlikely to be related with aging process or



**Fig. 3. 49-year-old man with transverse tear of medial meniscus.**

Proton density weighted (repetition time, 2200 msec; echo time, 30 msec) coronal MR image (A) of left knee shows focal outward bulging contour at medial margin of PCL, confined to medial side of line between inferomedial corner of medial femoral condyle and medial tibial spine (arrow). This case was classified as positive for interposition of PCL into medial compartment of knee joint. Fat suppressed proton density weighted (repetition time, 2530 msec; echo time, 30 msec) axial MR image (B) shows full thickness transverse tear of medial meniscus posterior horn. Arthroscopic image of medial compartment obtained with knee flexion position (C) shows focal outward bulging contour of PCL (asterisk) between medial femoral condyle (MFC) and medial tibial plateau (MTP) and transverse tear of medial meniscus posterior horn (MMPH) (arrow). PCL = posterior cruciate ligament

gender predominance. In cases that had arthroscopic surgery, no gross abnormality regarding PCL was identified on operation records. Even though surgery was performed in minority of cases, this also supports that wavy contour seen on interposed segment of PCL is not attributed to a true abnormality. We were unable to identify the clinical significance of the PCL interposition to the medial compartment in comparison of prevalence and statistical analysis among normal and diseased patients. Moreover, the prevalence was even higher in normal patients, as compared with those in patients with OA, ACL, or MM tear. Since ACL and MM are in close location in the knee joint with the PCL, we suspected possible clinical relationship between injury of these structures with the PCL interposition to the medial compartment. Especially, in case of ACL tear, abnormality of PCL such as 'PCL buckling' can be identified as indirect sign (11, 12). However, there was no meaningful relationship of the PCL interposition with these patients.

Several reports have described the relationship between OA and PCL (13-15). Most PCLs in OA knees were histologically degenerated regardless of the grade of arthritis (14) and associated with synovitis in adjacent structure (15). Moreover, age greater than 60 years is associated with decreased collagen diameter of the PCL in patients with OA (13). These previous reports suggested that OA could affect PCL; however, there was no significant difference in the prevalence of interposition of the PCL into the medial compartment of the knee between normal knee joints and OA in this study.

One possible explanation for this imaging feature is the variance of anatomic configuration and physiologic characteristic of PCL. The PCL is a complex, anisometric continuum of fibers, composed of two inseparable fiber bundles that can be functionally divided into anterior lateral and posterior medial fiber components (16). The *in situ* forces for these bundles differ at various knee flexion angles (16, 17). In general, the PCL is predominantly taut in flexion and lax in extension, which is the usual imaging position (1, 16-18). Hence, variability of the PCL laxity exists among normal subjects. In addition, cadaveric studies have revealed a wide variation of attachment site and course of fiber for the PCL (16, 19-21). Depending on the variability of the physiologic laxity and anatomical course of the PCL, interposition of the PCL into the medial compartment of the knee joint may have been scanned on coronal MRI.

In addition to the intrinsic limits of any retrospective

study, the current study had several other limitations. First, we could not correlate the interposition of the PCL with symptoms or signs. It is not easy to distinguish whether symptoms originate from the PCL interposition to the medial compartment or from other pathology since symptoms regarding the knee joint is usually nonspecific and vague. Even for patients who underwent arthroscopic surgery and had grossly intact PCLs, there still is a chance for occurrence of clinical symptom related to PCL. There may have been potential bias since all the study subjects were symptomatic patients, hence, inclusion of healthy volunteers for comparison in the future study would be beneficial. In addition, follow-up MRI was not evaluated to confirm if the imaging feature is transient or permanent. Furthermore, definition of interposition of the PCL to the medial compartment can be considered arbitrary. However, this may be a meaningful approach as an initial study, since there are no earlier studies on this imaging finding.

In conclusion, interposition of the PCL into the medial compartment of the knee joint is observed in almost half of patients on proton coronal MRI of the knee. Its presence is not associated with any particular factors including knee pathology and may be regarded as a normal MR finding.

## REFERENCES

1. Sonin AH, Fitzgerald SW, Hoff FL, Friedman H, Bresler ME. MR imaging of the posterior cruciate ligament: normal, abnormal, and associated injury patterns. *Radiographics* 1995;15:551-561
2. Kim HK, Laor T, Shire NJ, Bean JA, Dardzinski BJ. Anterior and posterior cruciate ligaments at different patient ages: MR imaging findings. *Radiology* 2008;247:826-835
3. Turner DA, Prodromos CC, Petasnick JP, Clark JW. Acute injury of the ligaments of the knee: magnetic resonance evaluation. *Radiology* 1985;154:717-722
4. Rodriguez W Jr, Vinson EN, Helms CA, Toth AP. MRI appearance of posterior cruciate ligament tears. *AJR Am J Roentgenol* 2008;191:1031
5. Fitzgerald SW, Remer EM, Friedman H, Rogers LF, Hendrix RW, Schafer MF. MR evaluation of the anterior cruciate ligament: value of supplementing sagittal images with coronal and axial images. *AJR Am J Roentgenol* 1993;160:1233-1237
6. Roberts CC, Towers JD, Spanghel MJ, Carrino JA, Morrison WB. Advanced MR imaging of the cruciate ligaments. *Radiol Clin North Am* 2007;45:1003-1016, vi-vii
7. Stoller DW. *Magnetic resonance imaging in orthopaedics and sports medicine*. 3rd ed. Baltimore: Lippincott Williams & Wilkins, 2007
8. Chen WT, Shih TT, Tu HY, Chen RC, Shau WY. Partial and

- complete tear of the anterior cruciate ligament. *Acta Radiol* 2002;43:511-516
9. Bolog N, Hodler J. MR imaging of the posterolateral corner of the knee. *Skeletal Radiol* 2007;36:715-728
  10. Ogden JA. Injury to the growth mechanisms of the immature skeleton. *Skeletal Radiol* 1981;6:237-253
  11. Robertson PL, Schweitzer ME, Bartolozzi AR, Ugoni A. Anterior cruciate ligament tears: evaluation of multiple signs with MR imaging. *Radiology* 1994;193:829-834
  12. Boeree NR, Ackroyd CE. Magnetic resonance imaging of anterior cruciate ligament rupture. A new diagnostic sign. *J Bone Joint Surg Br* 1992;74:614-616
  13. Akisue T, Stulberg BN, Bauer TW, McMahon JT, Wilde AH, Kurosaka M. Histologic evaluation of posterior cruciate ligaments from osteoarthritic knees. *Clin Orthop Relat Res* 2002;(400):165-173
  14. Mullaji AB, Marawar SV, Simha M, Jindal G. Cruciate ligaments in arthritic knees: a histologic study with radiologic correlation. *J Arthroplasty* 2008;23:567-572
  15. Roemer FW, Kassim Javaid M, Guermazi A, Thomas M, Kiran A, Keen R, et al. Anatomical distribution of synovitis in knee osteoarthritis and its association with joint effusion assessed on non-enhanced and contrast-enhanced MRI. *Osteoarthritis Cartilage* 2010;18:1269-1274
  16. Fanelli GC, Beck JD, Edson CJ. Current concepts review: the posterior cruciate ligament. *J Knee Surg* 2010;23:61-72
  17. Fox RJ, Harner CD, Sakane M, Carlin GJ, Woo SL. Determination of the in situ forces in the human posterior cruciate ligament using robotic technology. A cadaveric study. *Am J Sports Med* 1998;26:395-401
  18. Ortiz GJ, Schmotzer H, Bernbeck J, Graham S, Tibone JE, Vangsness CT Jr. Isometry of the posterior cruciate ligament. Effects of functional load and muscle force application. *Am J Sports Med* 1998;26:663-668
  19. Osti M, Tschann P, Künzel KH, Benedetto KP. Anatomic characteristics and radiographic references of the anterolateral and posteromedial bundles of the posterior cruciate ligament. *Am J Sports Med* 2012;40:1558-1563
  20. Edwards A, Bull AM, Amis AA. The attachments of the fiber bundles of the posterior cruciate ligament: an anatomic study. *Arthroscopy* 2007;23:284-290
  21. Gali JC, Esquerdo P, Almagro MA, da Silva PA. Radiographic study on the tibial insertion of the posterior cruciate ligament. *Rev Bras Ortop* 2015;50:342-347