

Anti-ulcer and ulcer healing potentials of *Musa sapientum* peel extract in the laboratory rodents

Samuel Adetunji Onasanwo, Benjamin Obukowho Emikpe¹, Austin Azubuike Ajah, Taiwo Olayemi Elufioye²

Departments of Physiology, Faculty of Basic Medical Sciences, College of Medicine, ¹Veterinary Pathology, Faculty of Veterinary Medicine, ²Pharmacognosy, Faculty of Pharmacy, University of Ibadan, Ibadan, Nigeria

Submitted: 16-08-2012

Revised: 07-09-2012

Published: 22-05-2013

ABSTRACT

Background: This study investigated the anti-ulcer and ulcer healing potentials of the methanol extract of *Musa sapientum* peel in the laboratory rats. **Materials and Methods:** Methanol extract of the peels on *Musa sapientum* (MEMS) was evaluated for its anti-ulcer using alcohol-induced, aspirin-induced, and pyloric ligation-induced models, and for its ulcer healing employing acetic acid-induced ulcer models in rats. **Results:** The findings from this experiment showed that MEMS (50, 100 and 200 mg/kg, b.w.) anti-ulcer and ulcer healing activity ($P \leq 0.05$) is dose-dependent. Also, MEMS exhibited healing of the ulcer base in all the treated groups when compared with the control group. **Conclusion:** The outcomes of this experiment revealed that the anti-ulcer effect of MEMS may be due to its anti-secretory and cyto-protective activity. The healing of the ulcer base might not be unconnected with basic fibroblast growth factors responsible for epithelial regeneration.

Key words: Anti-ulcer, *Musa sapientum*, peptic ulcer, ulcer healing

Access this article online

Website:

www.phcogres.com

DOI: 10.4103/0974-8490.112423

Quick Response Code:



INTRODUCTION

The development of new anti-ulcer drugs from medicinal plants is an attractive proposition, because diverse chemical compounds with anti-ulcer activities have been isolated from these plants,^[1] and they have shown to produce promising results in the treatment of gastric ulcers.^[2] The bioactive molecules (generally alkaloids, glycosides, lupeols, essential oils, e.t.c) isolated from crude extracts have been used directly as therapeutic agents or as starting materials for the synthesis of useful drugs or serve as a model for pharmacologically active compounds in the process of drugs in synthesis.^[3]

General review of references indicates that the anti-ulcerogenic effects of many taxa of medicinal plants have been assessed worldwide,^[4] and that many plant species have been used to alleviate gastric symptoms such as gastric pain, inflammation, etc. in folk medicine.^[5-8]

Musa sapientum (Family: Musaceae), known as banana, is a

familiar tropical fruit. It finds its origin from native South-Western Pacific home and spread to India later on. Later, it spreads into the Islands of the Pacific and to the West Coast of Africa as early as 200-300 BC.^[9] *Musa sapientum* is a treelike perennial herb that grows 5-9 m in height, with tuberous rhizome, hard, long pseudo-stem. The inflorescence is big with a reddish-brown bract, and it is eaten as vegetables, and the ripe fruits are sweet. Various researchers have reported that bananas pulp protect the gastric mucosa in the laboratory animals against NSAIDs and other ulcerogens. Also, it appears to stimulate growth of the gastric lining after damage has occurred.^[10] The use of *Musa sapientum* pulp in peptic ulcer as a component of herbal medicine has been evaluated and found effective.^[11] Dunjić and co-worker^[12] reported that pectin and phosphatidylcholine in green banana strengthens the mucous-phospholipid layer that protects the gastric mucosa. Lewis and co-workers^[13] reported that leucocyanidin, a natural flavonoid from the unripe banana (*Musa sapientum*) pulp, protects the gastric mucosa from erosions. Leucocyanidin and the synthetic analogues, hydroxyethylated leucocyanidin and tetra-allyl leucocyanidin were found to protect the gastric mucosa in aspirin-induced erosions in rat by increasing gastric mucus thickness.^[14] Goel and co-workers^[10] reported anti-ulcerogenic activity of banana pulp powder in aspirin-, indomethacin-, phenylbutazone-, prednisolone-induced

Address for correspondence:

Dr. Samuel A. Onasanwo, Department of Physiology, Faculty of Basic Medical Sciences, University of Ibadan, Nigeria.
E-mail: samphil2002@yahoo.com

gastric ulcers, and cysteamine- and histamine-induced duodenal ulcers in rats and guinea-pigs, respectively.

Furthermore, people from the South-Western Nigeria do blend the dried *Musa sapientum* peels with the yam flour, which is one of their staple foods. Folklore has it that this meal has ameliorative effect on the patients with gastric pain and ulcer. Since there has not been any scientific anti-ulcer report on the dried peels of the ripe banana, this made the assessment and evaluation of the fruit peels of *Musa sapientum* for anti-ulcer activity imperative. Therefore, the present study was undertaken with the main objective of evaluating the anti-ulcer and ulcer healing potentials of methanol extract of *Musa sapientum* fruit peel.

MATERIALS AND METHODS

Plant materials and preparation

Musa sapientum peels were collected from local vendors around University of Ibadan and were air-dried under shade during harmattan (dry) season (December-January). It was identified and authenticated by personnel. The peels were extracted by cold extraction for 96 hours using 100% methanol. Briefly, the powdered, dried peels were percolated in 100% methanol for 24 hours each time for 4 times. The filtered extract was concentrated in Rotavapor. The extraction yielded 8.4% of a semi-solid residue of methanol extract of *Musa sapientum* (MEMS). The semi-solid sample was stored at 4°C until when needed.

Experimental animals

Male Sprague Dawley rats weighing (160-180 g) were purchased from the Central Animal House, Faculty of Basic Medical Science, College of Medicine, University of Ibadan, Ibadan, Nigeria. Animals were kept in raised mesh bottom cages to prevent coprophagy and kept in environmentally controlled rooms (25 ± 2°C, 12 hr light and dark cycle), with free access to water. They were kept under standard laboratory conditions and were fed with standard rat's pellet (Ladokun Feeds, Nigeria) with water *ad libitum*. They were acclimatized for 5 days, after which they were randomly divided into groups in each phase of the experiments. All procedures in this study conformed to the guiding principles for research involving animals as recommended by the Declaration of Helsinki and the Guiding principles in the care and use of animals,^[15] and as approved by the Research Ethical Committee, University of Ibadan, Nigeria. The "Principle of Laboratory Animal Care" (NIH publication No. 85-23) guidelines and procedures were considered in this study (NIH publication revised, 1985).^[16]

Chemicals and drugs

All chemicals/reagents were purchased from Sigma

Chemical Co. (St. Louis, MO, USA), unless otherwise stated. Glacial acetic acid and Tween 20 was purchased from S.D. Fine Chemical Pvt. Ltd. (Mumbai, India). The standard drugs were suspended in 2.5% Tween 80/normal saline. All other chemicals were of analytical grade.

Anti-ulcer studies

The rats were deprived of food for 24 hrs before the experiments, but allowed free access to clean water. The study was carried out with the induction of ulcer under acute and chronic models.

Acute ulcer models

Alcohol-induced gastric ulcer (AL) in rats: Gastric ulcer was induced in rats by administering cold absolute alcohol (1 ml/200 g p.o.) body weight.^[17] Omeprazole (OMP) and MEMS were administered 45 minutes before alcohol treatment. The animals were sacrificed 1 hour after the treatments, and the stomachs were excised along the greater curvature to observe gastric lesions for the determination of ulcer index.

Aspirin-induced gastric ulcers (ASP) in rats: Aspirin (150 mg/kg) p.o. was administered to induce ulcer after 45 minutes after treating the animal with MEMS (50, 100, and 200 mg/kg) p.o. in different groups, and omeprazole (10 mg/kg, p.o.). The animals were sacrificed by cervical dislocation 5 hours after aspirin treatment,^[18] and the stomach was dissected out, and the lesion was scored.

Pyloric ligation-induced gastric ulcer (PL) in rats: This was done by ligating the pyloric end of the stomach of rats under chloral hydrate anesthesia (300 mg/kg, i.p.).^[19] After 45 minutes of OMP and MEMS administration, the abdominal part of the animal was incised along the midline, and the stomach was exposed. The pyloric end was ligated without damage to the blood vessels or any organ, and the stomach was carefully placed back into the stomach, and the abdomen was stitched. After 4 hours of surgery, rats were sacrificed, and the gastric juice was collected. 10 ml of the effluent was collected and titrated against 0.01 N NaOH using freshly prepared phenolphthalein as an indicator, for the determination of total acidity [Table 1].

Chronic ulcer model

Acetic acid-induced ulcer model: Gastric kissing ulcers were induced using acetic acid with a little modification.^[20] After 24 hours of fasting, the rat's stomach was exposed under anesthesia. The glandular walls of the stomach were clamped with a pair of eye forceps rings, and 0.2 ml of acetic acid solution (40% v/v distilled water) was injected into the intra-luminal glandular portion of the stomach, and then withdrawn

after 45 seconds. The abdomen was sutured, and rats were allowed to recover post-operation at the recovery bay. On the 1st day of the experiment (3 days after surgery), rats were orally administered with OMP (10 mg/kg) and MEMS (200 mg/kg). Histological studies were performed according to the methods described by Oghiara and Okabe.^[21] At autopsy, the ulcers were embedded in paraffin and sectioned at 5 μm and routinely stained with Hematoxylin and Eosin. The tissue contraction, regeneration of the ulcerated mucosa and inflammatory exudates were observed under the microscope. Photomicrographs were also taken.

Measurement of ulcer index

Ulcers in the acute models were scored with the help of magnascope under 5X magnification using the ulcer scoring criteria.^[22] The following criteria were used to grade the incidence or severity of the lesions: no ulcer = 0, shading of epithelium = 10, petechial and frank hemorrhages = 20, one or two ulcers = 30, more than two ulcers = 40, perforated ulcers = 50. Ulcer index was calculated from scorings described as follows: $UI = (Us + Up) \times 10^{-1}$, where Us = mean severity of ulcer score; Up = percentage of animals with ulcer incidence. Percentage protection index (in case of anti-ulcer studies) and healing index (ulcer-healing study) is calculated as follows: Percentage protection index = $(Uc - Ut) C^{-1} \times 100$, where Uc = ulcer index in control group; Ut = ulcer index in treated group.

Statistical analysis

The results were expressed as mean ± S.E.M. Data of ulcer index was analyzed by non-parametric ANOVA followed by Dunnett's multiple comparison test, while other data was evaluated by one-way ANOVA followed by post hoc Newman-Keul's test using Graph-Pad PRISM 5 software. P -value < 0.05 was considered significant.

RESULTS

Anti-ulcer effects of *musa sapientum* peel extract (MEMS)

The doses of MEMS (50, 100, 200 mg/kg) showed significant anti-ulcer effect against ulcers induced in all the models in a dose-dependent manner. In ASP, AL, and PL, MEMS at doses of 50, 100, 200 mg/kg body weight showed protection index of (23.08, 41.00, 56.39)%, (21.77, 53.70, 71.98)% and (14.26, 55.81, 94.62)%, respectively. The omeprazole (10 mg/kg) showed protection index of 84.92% and 85.74% in ASP and PL, respectively, while and sucralfate showed 85.88% protection in AL. In all models, the effect of MEMS is statistically significant in comparison to the control as shown in Figure 1.

Data are represented as mean ± S.E.M. Statistical analysis was done by one-way ANOVA. * P < 0.05, ** P < 0.01 in comparison with the control group (n = 6).

Histological assessment of the ulcer healing effect of MEMS in acetic acid-induced ulcers

The sections of untreated control group showed localized area of epithelial denudation marked with necrosis and exposure of the basement membrane on day 3, and this progressed on day 7 [Figure 2a] while on day 12, there were very little regeneration [Figure 2d].

In OMP-treated group, there was gradual epithelial regeneration on the 3rd day, which progressed with slight regeneration and re-epithelization on day 7 [Figure 2b] while on day 12, there is evidence of marked regeneration and angiogenesis [Figure 2e].

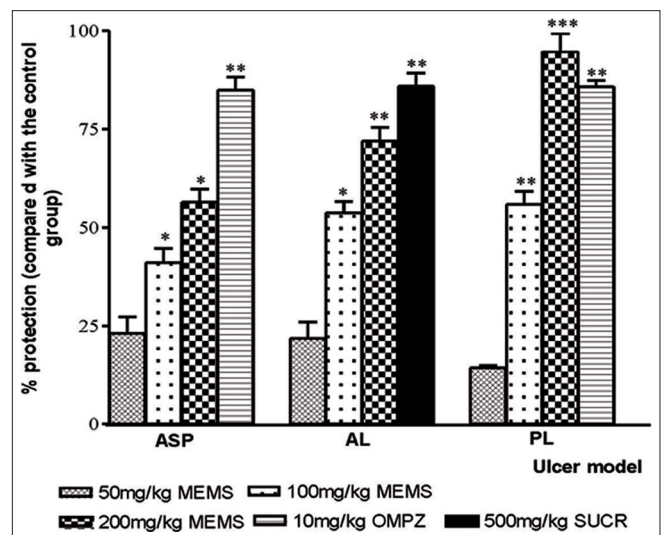


Figure 1: Effect of methanol extract of *Musa sapientum* (50, 100, 200 mg/kg), omeprazole (10 mg/kg), and sucralfate (500 mg/kg) on the percentage protection of ulcer index in the acute ulcer models in rats. Data are represented as mean ± S.E.M. Statistical analysis was done by one-way ANOVA. * P < 0.05, ** P < 0.01 and *** P < 0.001 in comparison with the control group (n = 6)

Table 1: Effect of methanol extract of *Musa sapientum* (50, 100, 200mg/kg) and omeprazole (10mg/kg) on total acidity pyloric ligation-induced uleer model in rats.

Treatment group	Dose	Total Acidity (μEq/ml/hrs)
Control (distilled water)	10 ml/kg	22.89 ± 3.12
MEMS	50 mg/kg	19.46 ± 3.97
MEMS	100 mg/kg	12.71 ± 1.54
MEMS	200 mg/kg	10.42 ± 3.81*
Omeprazole	10 mg/kg	7.36 ± 0.86**

In MEMS-treated, from day 3, there is gradual epithelial regeneration, which was coupled with angiogenesis after 7 days of treatment [Figure 2c] while on day 12, the regeneration and angiogenesis was moderate and near complete regeneration [Figure 2f].

DISCUSSION AND CONCLUSION

The exploration of natural products and medicinal plants extracts has become the most interesting and attractive sources of new therapy for various gastrointestinal disorders, especially in the treatment of peptic ulcers in various experimental models for evaluating anti-ulcer drugs.^[23,24]

In this study, the anti-ulcerogenic and ulcer healing activities of methanol extract of *Musa sapientum* (MEMS) were investigated using different acute ulcer models including aspirin-induced, alcohol-induced and pylorus ligation-induced ulcers, and chronic ulcer model induced by glacial acetic acid solution. The responses of the experimentally-induced ulcerated animals in various treatment groups to MEMS were necessary to evaluate both anti-secretory and cyto-protective potentials of MEMS since a natural product with both properties has been speculated to be a better ulcer therapy.^[25] Also, it has been suggested that candidate for an effective drug against peptic ulcer should basically act either by reducing the aggressive factors on gastro-duodenal mucosa or by increasing mucosal resistance against them.^[26]

Considering the fact that dried *Musa sapientum* peel forms part of the meal of people of gastric disorders in South-West Nigeria, this study evaluated the anti-ulcer activity of its methanol extract.

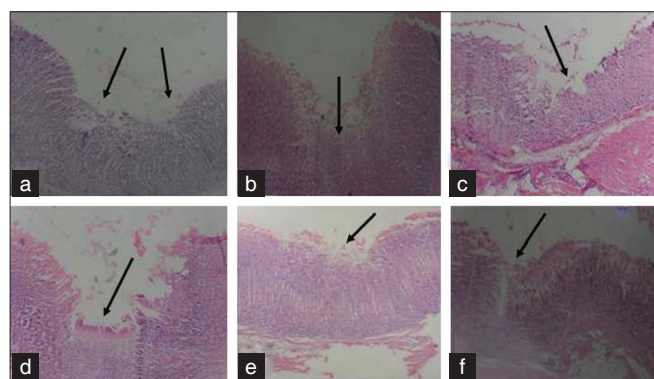


Figure 2: Sections of (a) ulcerated stomach of control groups untreated with MEMS; (b) ulcerated stomach of rat treated with OMP; (c) ulcerated stomach of rat treated with MEMS, after 7 days of treatment. Sections of (d) ulcerated stomach obtained from acetic acid-induced ulcer model in control rats; (e) ulcerated stomach rats treated with OMP; (f) ulcerated stomach treated with MEMS, after 12 days of treatment. The arrow points towards regeneration and angiogenesis

In this research work, the cyto-protective efficacy of MEMS against a NSAIDs-induced ulcer model was assessed. Aspirin induces ulcers due to their effect on cyclooxygenase enzyme leading to reduced prostaglandin production and increase in acid secretion.^[27,28] The results from our study revealed that MEMS-treated rats exhibited significant increase in the percentage protection against aspirin-induced ulcer in a dose-dependent manner as compared with the control. Aspirin has been reported to convert hydroperoxyl group, generated from generalized lipid peroxidation accompanying cell damage, to hydroxy fatty acids, a reaction that releases damaging free radicals, which ultimately leads to cell death in the gastric tissue.^[29-31] The MEMS might have scavenged the free radicals produced.

Direct necrotizing effect of ethanol and subsequent necrosis of superficial epithelial cells on gastric mucosa form the basis of gastric ulceration and erosion in the ethanol-induced ulcers model.^[32,33] The anti-ulcerogenic efficacy of any drug against ethanol-induced ulcers has been suggested to be through cyto-protective pathway. Hence, ethanol-induced ulcers will be inhibited by agents that enhance mucosal defensive factors.^[24,34] The dose-dependent anti-ulcer potentials of MEMS in the AL model in this study when compared with the control group showed that it has cyto-protective property. Moreover, ethanol is metabolized in the body and releases superoxide anion and hydroperoxy-free radicals, implicating MEMS-free radical scavenging possibilities.

In pyloric ligation-induced ulcer model, increase in gastric acid secretion has been implicated in the severe ulceration of the rat gastric mucosa.^[35] while the auto-digestion of gastric mucosa has been attributed to the accumulation of pepsin.^[28,36] MEMS produced significant protection at both 100 mg/kg and 200 mg/kg with 200 mg/kg MEMS showing gastro-protective potential higher than the standard drug (omeprazole, 10 mg/kg). Further study with total acidity estimation revealed reduction of total gastric acidity in a dose-dependent manner, with significant reduction produced by 200 mg/kg MEMS comparable to OMP (10 mg/kg), a standard anti-secretory drug.

Furthermore, the ulcer healing potentials of MEMS was evaluated through acetic acid-induced chronic ulcer model. This model was chosen and has been used by many researchers, because it produces gastric lesion with the aid of the eye forceps, which is similar to human chronic ulcers. In this model, acetic acid produced mucosal injury, which was confined to the glandular stomach.^[25,31] This model lacks adhesion of ulcer base to underlying liver as observed in some other models of ulcer induction. Various authors have reported the suitability of this model for ulcer-healing studies^[37] and showed that various anti-

secretory agents like omeprazole^[38] and cyto-protective agents like sucralfate^[39] were effective in this model. Their efficacy has been attributed to their anti-secretory and cyto-protective effects of these standard drugs. Ulcer-healing is a complex process that involves combination of wound retraction and re-epithelialization.^[40-42] In addition to anti-secretory activity, other potential mechanisms involved in ulcer-healing include angiogenesis in granulation tissue.^[43] Ulcer-healing depends on regeneration of mucosal glandular structure and migration of epithelial cells to cover ulcer crater. We observed that the groups administered with effective dose (200 mg/kg) of MEMS and OMP (10 mg/kg) showed quick regenerative abilities and re-epithelialization of the ulcerated gastric mucosa than other group, which was induced with ulcer using acetic acid.

MS has significantly reduced size of ulcer base (measure of protection) after ulcer induction, which increased from day 3 with mild regeneration, which progressed with moderate regeneration and angiogenesis on day 7 and 10 while on day 12 treatment, complete regeneration of mucosal glandular structure was well evidenced at the ulcer base. This healing property may be due to its cyto-protective activity coupled with anti-secretory effect. This acceleration in the healing of the ulcer base might be due to protection of basic fibroblast growth factors. Basic fibroblast growth factor is considered to be responsible for epithelial regeneration in case of acid-induced ulcers. Based on this study, it can be concluded that the efficacy of *Musa sapientum* in all ulcer models mainly may be due to more of its cyto-protective effect in comparison to its anti-secretory effect.

In conclusion, the etiology of ulcers produced in different ulcer models is diverse. Since MEMS peel has been found effective in all models depicting its anti-ulcerogenic activity along with its ulcer-healing effect, MEMS and its active constituents may emerge as more effective therapeutic agent to counter gastric ulcer incidence and ulcer healing. However, isolation of active secondary metabolites that may be responsible for the anti-ulcer and ulcer-healing potentials will be required.

ACKNOWLEDGEMENT

We sincerely acknowledge the support of the University of Ibadan Senate Research Grant (Number SRG/COM/2010/1A) given in support of this research.

REFERENCES

- Lewis DA, Hanson PJ. Anti-ulcer drugs of plant origin. *Prog Med Chem* 1991;28:201-31.
- Hiruma-Lima CA, Gracioso JS, Toma W, Almeida AB, Paula AC, Brasil DS, et al. Gastroprotective effect of aparisthman, a diterpene isolated from *Aparisthium cordatum*, on experimental gastric ulcer models in rats and mice. *Phytomedicine* 2001;8:94-100.
- Shah N, Groves A, Anderson DJ. Alternative neural crest cell fates are instructively promoted by TGF β superfamily members. *Cell* 1996;85:331-43.
- Yesilada E, Gurbuz I. A compilation of the studies on the antiulcerogenic effects of medicinal plants. In: Singh S, Singh VK, Govil JN, editors. *Recent Progress in Medicinal Plants*, Vol. 2. Phytochemistry and Pharmacology. Houston, TX: SCI Tech Publishing LLC; 2003. p. 111-74.
- Sezik E, Zor M, Yesilada E. Traditional medicine in Turkey. II. Folk medicine in Kastamonu. *Int J Pharmacogn* 1992;30:233-9.
- Sezik E, Yesilada E, Honda G, Takaishi Y, Takeda Y, Tanaka T. Traditional medicine in Turkey X. Folk medicine in Central Anatolia. *J Ethnopharmacol* 2001;75:95-115.
- Yesilada E, Honda G, Sezik E, Tabata M, Fujita T, Tanaka T, et al. Traditional medicine in Turkey. V. Folk medicine in the inner Taurus Mountains. *J Ethnopharmacol* 1995;46:133-52.
- Baytop T. *Therapy with Medicinal Plants in Turkey Past and Present*. 2nd ed. Istanbul: Nobel Tip Kitapevi; 1999.
- Rahman MM. Invasive plants of Sundarbans. Interim report under SBCEP project. Bangladesh: (IUCN) International Union for Conservation of Nature; 2003. p. 32.
- Goel RK, Gupta S, Shankar R, Sanyal AK. Anti-ulcerogenic effect of banana powder (*Musa sapientum* var. *paradisica*) and its effect on mucosal resistance. *J Ethnopharmacol* 1986;18:33-44.
- Goel RK, Sairam K, Rao CV. Role of gastric antioxidant and anti-*Helicobacter pylori* activities in antiulcerogenic activity of plantain banana (*Musa sapientum* var. *paradisica*). *Indian J Exp Biol* 2001;39:719-22.
- Dunjić BS, Svensson I, Axelson J, Adlercreutz P, Ar'Rajab A, Larsson K, et al. Green banana protection of gastric mucosa against experimentally induced injuries in rats. A multicomponent mechanism? *Scand J Gastroenterol* 1993;28:894-8.
- Lewis DA, Fields WN, Shaw GP. A natural flavonoid present in unripe plantain banana pulp (*Musa sapientum* L. var. *paradisica*) protects the gastric mucosa from aspirin-induced erosions. *J Ethnopharmacol* 1999;65:283-8.
- Lewis DA, Shaw GP. A natural flavonoid and synthetic analogues protect the gastric mucosa from aspirin-induced erosions. *J Nutr Biochem* 2001;12:95-100.
- World Medical Association, American Physiological Society. Guiding principles for research involving animals and human beings. *Am J Physiol Regul Integr Comp Physiol* 2002;283:R281-3.
- P.H.S (Public Health Service) (1996). Public health service policy on humane care and the use of laboratory animals. US Department of Health and Humane services. Washington, DC; Human Health Research Act; 1985; p. 158.
- Suleyman H, Akcay F, Altinkaynak K. The effect of nimesulide on the indomethacin- and ethanol-induced gastric ulcer in rats. *Pharmacol Res* 2002;45:155-8.
- Goel RK, Das DG, Sanyal AK. Effect of vegetable banana powder on changes induced by ulcerogenic agents in dissolved mucosubstances of gastric juice. *Indian J Gastroenterol* 1985;4:249-51.
- Shay M, Komarov SA, Fels SS, Meranze D, Gruenstein M, Sipler H. A simple method for the uniform production of gastric ulceration in the rat. *Gastroenterology* 1945;5:43-61.
- Tsukimi Y, Okabe S. Validity of kissing gastric ulcers induced in rats for screening of antiulcer drugs. *J Gastroenterol Hepatol* 1994;9:S60-5.

21. Ogihara Y, Okabe S. Effect and mechanism of sucralfate on healing of acetic acid-induced gastric ulcers in rats. *J Physiol Pharmacol* 1993;44:109-18.
22. Srivastava SK, Nath C, Gupta MB, Vrat S, Sinha JN, Dhawan KN, *et al.* Protection against gastric ulcer by verapamil. *Pharmacol Res* 1991;23:81-6.
23. Borrelli F, Izzo AA. The plant kingdom as a source of anti-ulcer remedies. *Phytother Res* 2000;14:581-91.
24. Toma W, Hiruma-Limab CA, Guerrero AR, Brito S. Preliminary studies of *Mammea americana* L. (Guttiferae) bark/latex extract point to an effective antiulcer effect on gastric ulcer models in mice. *Phytomedicine* 2005;12:345-50.
25. Dharmani P, Kuchibhotla VK, Maurya R, Srivastava S, Sharma S, Palit G. Evaluation of anti-ulcerogenic and ulcer-healing properties of *Ocimum sanctum* Linn. *J Ethnopharmacol* 2004;93:197-206.
26. Faloni-de-Andrade S, Lemos M, Comunello E, Noldin VF, Filho VC, Niero R. Evaluation of the antiulcerogenic activity of *Maytenus robusta* (Celastraceae) in different experimental ulcer models. *J Ethnopharmacol* 2007;113:252-7.
27. Bhargava KP, Gupta MB, Tangri KK. Mechanism of ulcerogenic activity of indomethacin and oxyphenbutazone. *Eur J Pharmacol* 1973;22:191-5.
28. Goel RK, Bhattacharaja SK. Gastroduodenal Mucosal Defense and Mucosal Protective Agents. *Indian J Exp Biol* 1991;29:701-14.
29. Van-Kolfschten AA, Zandberg P, Jager LP, Noordwijk V. The influence of paracetamol on the erosive activity of indomethacin in the rat stomach. *Agents Action* 1983;12:247-53.
30. Scheiman JM. In: Dubais RN, Giardiello FM, editors. NSAIDs, Eicosonoids and the Gastroenteric Tract. Vol. 25. Philadelphia: Saunders; 1996. p. 279-89.
31. Umamaheswari M, Asokkumar K, Rathidevi R, Sivashanmugam AT, Subhadradevi V, Ravi TK. Antiulcer and in vitro antioxidant activities of *Jasminum grandiflorum* L. *J Ethnopharmacol* 2007;110:464-70.
32. Miller TA, Henagan JM. Indomethacin decreases resistance of gastric barrier to disruption by alcohol. *Dig Dis Sci* 1984;29:141-9.
33. Oates PJ, Hakkinen JP. Studies on the mechanism of ethanol-induced gastric damage in rats. *Gastroenterology* 1988;94:10-21.
34. Morimoto Y, Shimohara K, Oshima S, Sukamoto T. Effects of the new anti-ulcer agent KB-5492 on experimental gastric mucosal lesions and gastric mucosal defensive factors, as compared to those of terpenone and cimetidine. *Jpn J Pharmacol* 1991;57:595-605.
35. Martin MJ, Motilva V, Alarcon de la Lastra C. Quercetin and naringenin: Effects on ulcer formation and gastric secretion in rats. *Phytotherapy Res* 1993;7:150-3.
36. Tan PV, Penlap VB, Nyasse B, Nguemo JD. Antiulcer actions of the bark methanol extract of *Voacanga africana* in different experimental ulcer models in rats. *J Ethnopharmacol* 2000;73:423-8.
37. Okabe S, Pfeiffer CJ. Chronicity of acetic acid ulcer in the stomach. *Dig Dis Sci* 1972;7:612-29.
38. Ishihara M, Ito M. Influence of aging on gastric ulcer healing activities of cimetidine and omeprazole. *Eur J Pharmacol* 2002;444:209-15.
39. Tsukimi Y, Nozue C, Okabe S. Effects of leminoprazole, omeprazole and sucralfate on indomethacin-induced delayed healing of kissing gastric ulcers in rats. *J Gastroenterol Hepatol* 1996;11:335-40.
40. Helpap B, Hattori T, Gedigk P. Repair of gastric ulcer. A cell kinetic study. *Virchows Arch A Pathol Anat Histol* 1981;392:159-70.
41. Helander HF. Morphological studies on the margin of gastric corpus wounds in the rat. *J Submicrosc Cytol* 1983;15:627-43.
42. Szabo S, Hollander D. Pathways of gastrointestinal protection and repair: Mechanisms of action of sucralfate. *Am J Med* 1989;86:23-31.
43. Tarnawski A, Hollander D, Krause WJ, Dabros W, Stachura J, Gergely H. "Healed" experimental gastric ulcers remain histologically and ultrastructurally abnormal. *J Clin Gastroenterol* 1990;12:S139-47.

Cite this article as: Onasanwo SA, Emikpe BO, Ajah AA, Elufioye TO. Anti-ulcer and ulcer healing potentials of *Musa sapientum* peel extract in the laboratory rodents. *Phcog Res* 2013;5:173-8.

Source of Support: Nil, **Conflict of Interest:** None declared.