

Available online at www.sciencedirect.com

ScienceDirect

Biomedical Journal

journal homepage: www.elsevier.com/locate/bj

Original Article

Aggressive cytoreduction and multiple subpial cortical transections may obtain good surgical outcomes in refractory epilepsy with multiple epileptic foci



Hsiang-Yao Hsieh ^{a,h}, Chun-Wei Chang ^{a,h}, Mei-Yun Cheng ^{a,h,e},
 Jiun-Lin Yan ^{f,h}, Siew-Na Lim ^{a,h}, Wei-En Johnny Tseng ^{a,g,h},
 Hsing-I. Chiang ^{a,h}, Han-Tao Li ^{a,h}, Bao-Luen Chang ^{a,h}, Chih-Hong Lee ^{a,h},
 Chih Yin Lin ^{a,h}, Tony Wu ^{a,c,h,**}, Chen-Nen Chang ^{b,d,h,*}

^a Department of Neurology, Chang Gung Memorial Hospital at Linkou, Taoyuan, Taiwan

^b Department of Neurosurgery, Chang Gung Memorial Hospital at Linkou, Taoyuan, Taiwan

^c Department of Neurology, Xiamen Chang Gung Hospital, China

^d Department of Neurosurgery, Xiamen Chang Gung Hospital, China

^e Institute of Molecular Medicine, National Tsing Hua University, Hsinchu, Taiwan

^f Department of Neurosurgery, Chang Gung Memorial Hospital at Keelung, Keelung, Taiwan

^g Program in Biomedical Engineering, Chang Gung University, Taoyuan, Taiwan

^h College of Medicine, Chang Gung University, Taoyuan, Taiwan

ARTICLE INFO

Article history:

Received 23 November 2018

Accepted 2 March 2020

Available online 14 April 2020

Keywords:

Refractory epilepsy

Cytoreduction

Topectomy

Lesionectomy

Multiple subpial cortical transection

ABSTRACT

Backgrounds: Epilepsy surgery is the most efficacious therapeutic modality for patients with medical refractory epilepsy, especially resective surgery. However, the variable etiologies and multiple epileptic foci are usually associated with the outcomes. The aim of this study was to demonstrate that combination of different intervention procedures might be an alternative option for patients of refractory epilepsy.

Methods: We retrospectively analyzed pre-operative and post-surgical outcomes in 30 patients who received epilepsy surgery between January 1, 2010 and December 31, 2014 at Chang Gung Memorial Hospital (CGMH), Linkou, according to Engel's classification.

Results: Twenty-six of the 30 patients (86.7%) had good outcomes, sum of class I and class II after epilepsy surgery. The good outcome rate of our complicated group was 80.0% (12/15), compared to 93.3% (14/15) in the simple group, but no significant differences between the two groups ($p = 0.569$). Four patients whose epileptic foci involved eloquent area and received multiple subpial cortical transection, and good outcome rate was 75% (3/4). At last,

* Corresponding author. Department of Neurosurgery, Chang Gung Memorial Hospital at Linkou, 5, Fusing St., Gueishan, Taoyuan 333, Taiwan.

** Corresponding author. Department of Neurology, Chang Gung Memorial Hospital at Linkou, 5, Fusing St., Gueishan, Taoyuan 333, Taiwan.

E-mail addresses: tonywu@adm.cgmh.org.tw (T. Wu), changcn.med@hotmail.com (C.-N. Chang).

Peer review under responsibility of Chang Gung University.

<https://doi.org/10.1016/j.bj.2020.03.003>

2319-4170/© 2020 Chang Gung University. Publishing services by Elsevier B.V. This is an open access article under the CC BY-NC-ND license (<http://creativecommons.org/licenses/by-nc-nd/4.0/>).

six patients had previously failed epilepsy surgery and received a reoperation, with a good outcome rate of 83.3% (5/6).

Conclusion: After complete pre-surgical evaluation and combined interventional procedures, the patients with refractory epilepsy had satisfactory outcomes and few neurological complications. Moreover, re-operation can improve the outcome in some patients who previously failed epilepsy surgery.

At a glance of commentary

Scientific background on the subject

Combination therapy of lesionectomy, topectomy, and MST for complicated patients with multiple lesions or epileptic foci might provide a chance of good seizure outcome.

What this study adds to the field

In patients failed previous epilepsy surgery, combination therapy is an option for further epilepsy management.

Epilepsy is one of most common neurological disorders, and involves paroxysmal attacks which can lead to severe injury. Although an increasing number of new antiepileptic drugs (AEDs) have been developed in recent decades which can partially relieve seizures, about one third of patients with epilepsy are still medically intractable [1], even use ketogenic diet [2–4]. Diagnostic advances including structural and functional imaging, long-term video-electroencephalography (VEEG), invasive monitoring, and surgical mapping are important to confirm precisely the epileptogenic zones in different lobes or different hemispheres before resective or palliative surgery. As a result, epilepsy surgery can achieve immediate and lasting seizure control.

Many surgical procedures are used in epilepsy surgery. Traditionally, the goal of epilepsy surgery is complete removal of the epileptogenic zone without causing permanent neurological deficits. The development of gamma knife radiosurgery for lesional focal epilepsy provides another choice of non-invasive method for seizure foci within an eloquent area or surgically challenging brain regions that maybe associated with a high risk of complications after open surgery. This method has been extensively used for refractory epilepsy with arteriovenous malformations, cavernomas, tumors, hypothalamic hamartomas, and mesial temporal epilepsy with hippocampal sclerosis [5].

For medial temporal lobe epilepsy, anterior temporal lobectomy has been shown to improve seizure frequency or even stop seizures, especially in patients with mesial temporal lobe sclerosis [6–8]. Functional imaging modalities such as functional magnetic resonance imaging (fMRI), ethyl cysteine dimer-single-photon emission computed tomography (SPECT), and 18F-fluorodeoxyglucose position emission

tomography (FDG-PET) can help to delineate the relationship between anatomical structures and epileptogenic zones [9,10]. In tumor-related temporal lobe epilepsy, gross-total lesionectomy combined with foci topectomy has been reported to be more beneficial than lesionectomy alone, with a reported 87% of patients achieving seizure freedom. In addition, disconnection procedures of multiple subpial cortical transection (MST) commonly used in combination with resective epilepsy surgery with multiple foci or foci involving an eloquent cortex, especially in frontal lobe epilepsy, may provide additional benefits in reducing seizures [11,12]. The combination of several different interventional procedures for complicated refractory epilepsy with lesions and variable epileptic foci therefore seems to be a reasonable approach to achieve seizure freedom.

Materials and methods

Indication for epilepsy surgery and pre-operative evaluation

All the patients who underwent epilepsy surgery for the treatment of refractory seizures at our hospital over a 5-years period from January 1, 2010 to December 31, 2014 at Chang Gung Memorial Hospital (CGMH), Linkou were collected in this study. All of the patients underwent routine preoperative workup for drug-resistant epilepsy at the Department of Neurology, Neurosurgery, Neuroradiology and Nuclear Medicine at CGMH. Demographic data including gender, age at seizure onset, seizure pattern, etiology of epilepsy, duration of epilepsy, frequency of seizures, duration between seizure onset and surgery, follow-up period, and post-surgical outcomes were recorded. These patients were followed to December 2016, at least 2 years after surgery. The frequencies of seizures before and after surgery were recorded to assess seizure outcome. In addition, data on the first seizure after surgery and adjustments in AEDs before and after surgery were also recorded. The pre-surgical evaluation protocol included VEEG, brain magnetic resonance imaging (MRI), SPECT or FDG-PET.

Each patient completed VEEG to confirm seizure pattern, and pre-surgical intracranial electro-corticography (ECoG) recording and functional brain mapping. ECoG was recorded for 7 days to clarify the ictus, epileptogenic zones and related lobes. According to our standard protocol, we tapered or stopped the current AEDs during ECoG recording so that we could record more than two seizures to clarify epileptogenic zones. In addition, all patients received repeatedly intra-operative ECoG during epilepsy surgery to clarify the real epileptogenic margin.

We divided the patients into different groups by epileptogenic foci-related lobes (confirmed by ECoG), etiology and MRI findings, and surgical procedures to clarify the outcomes. The epileptic foci could be correlated to brain lesion or not. The 30 patients were divided into two groups, A and B. Group A meant simple group, included patients with epileptic foci located over one lobe with or without well-defined brain lesions. Group B meant complicated groups, included patients with multiple epileptic foci over two or more lobes; for example, unilateral fronto-temporal lobes or bilateral temporal lobes. The lesion and epileptic foci may locate in the same or different lobes in group B. The brain MRI findings included normal well-defined lesions (such as cavernoma) or ill-defined lesions such as gliosis or encephalomalacia due to trauma, meningoencephalitis.

Statistical analysis

We used Independent t-test to compare continuous data between two groups, including seizure onset, age at surgery, duration between seizure onset and surgery, and post-operative follow-up period. Besides, Fisher's exact test was used for surgery outcome between-group differences.

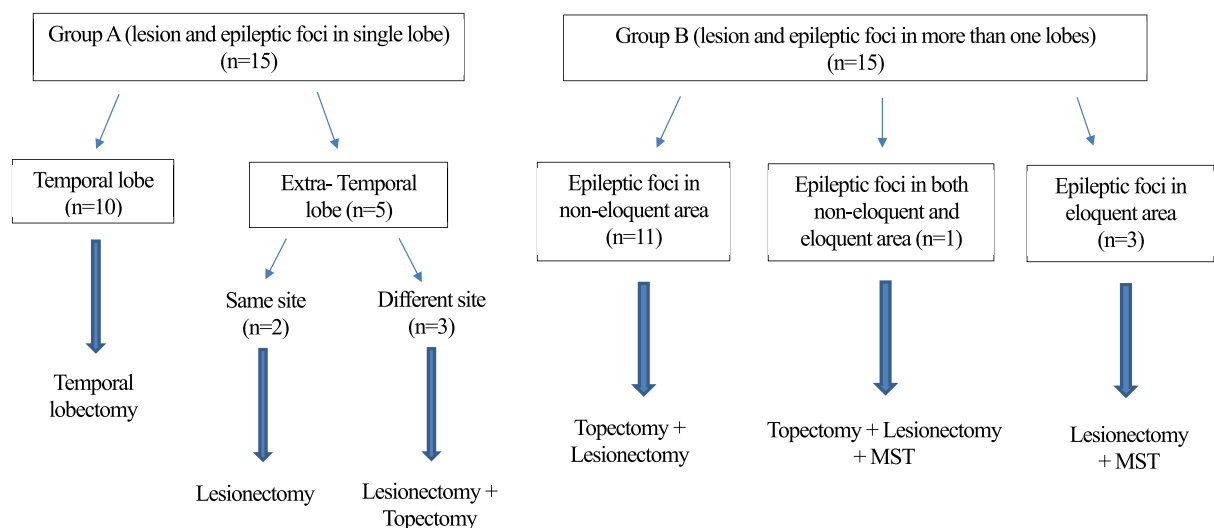
Surgical procedures

The patients underwent one or more surgical procedure including lesionectomy, partial or total temporal lobectomy, frontal or temporal topectomy (F-topectomy or T-topectomy), also called “cytoreduction”, or in combination with MST, depending on the epileptic foci by VEEG, intra-operative ECoG, seizure pattern, imaging findings, foci localized over an eloquent or non-eloquent cortex, and clinical presentations individually [13]. Maximum resection of epileptogenic zones

was performed when the regions involved were functionally considered to be relatively “silent” or “non-eloquent” according to pre-surgical and intra-operative ECoG and functional mapping. If the seizure foci were identified in both hemispheres, the predominant foci were resected first, and then additional monitoring was performed to determine the activity in the contralateral foci before considering resection or other palliative treatment.

We had different surgical procedures in group A and B, and the flowchart of surgical treatment, patient numbers were described in Fig. 1. For example, when a patient in group B had a brain lesion, and we detected epileptogenic zones more than the lesion, or even in different lobes, we performed lesionectomy first as complete as possible. The next step was to detect the margin and confirm whether there were any residual epileptiform discharges to decide whether we needed to perform further resection. If the epileptogenic zones did not involve eloquent areas, we preferred modified or total lobectomy (in temporal lobe), or combined topectomy of epileptic foci in extra-temporal lobe as maximum as possible. Whereas, in the patient whose epileptogenic zones involved eloquent areas, we chose modified topectomy and combined with MST to reduce seizures and prevent complications. Based on invasive ictal and interictal recordings, epilepsy surgery can be tailored individually by resecting the lesion, surrounding epileptogenic zone, and sparing the functionally intact cortex.

For the patients in whom brain imaging showed no obvious lesions or ill-defined lesions such as gliosis due to traumas or previous surgery, the neurosurgeon chose temporal lobectomy, topectomy or in combination with MST. MST was usually used in the patients whose epileptic foci were located over an eloquent area, usually the frontal lobe involving motor, sensory or language areas.



n: patient numbers

MST: multiple subpial cortical transection

Fig. 1 The flowchart of surgical treatment about refractory epilepsy in our patients (n = 30).

Evaluation of outcomes

We reviewed the frequency of seizures per month before and after epilepsy surgery to evaluate the outcomes. Every patient was followed up at our outpatient department for at least 24 months; if the patient was lost to follow-up, we attempted to contact them and ask about seizure control. Changes in seizure control after surgery were evaluated according to Engel's classification as follows: Class I, free of disabling seizures; IA, completely seizure free since surgery; IB, non-disabling simple partial seizures only since surgery; IC, some disabling seizures after surgery, but free of disabling seizures for at least 2 years; Class II, almost seizure free; IIA, initially free of disabling seizures but now with rare seizures; IIB, rare disabling seizures since surgery; and IIC, more than a few disabling seizures since surgery, but few seizures in the last 2 years; Class III, worthwhile improvement, usually >50% reduction in seizure frequency; Class IV, no worthwhile improvement. We defined a "good outcome" as being class I or II. Pre-surgical complications, complications during evaluation and monitoring, and post-operative complications and neurological deficits were also recorded.

Results

Total 32 patients with epilepsy received surgery during the 5 years. We excluded two patients who were lost to follow-up within 2 years after surgery to meet Engel's classification. Of

the 30 enrolled patients, the age at onset of seizures was 3–51 years (21.4 ± 11.0 years), the age at receiving surgery was 19–63 years (37.8 ± 9.0 years), and the duration between seizure onset and surgery was 1–54 years (16.6 ± 11.0 years). The follow-up period after epilepsy surgery was 29–91 months (52.5 ± 13.8 months). The overall "good outcome" rate was 86.7% (26/30).

Twenty-four of the 30 patients had unprovoked seizures during pre-surgical ECoG recording, and every patient had one or more ictal or interictal foci recorded in pre-surgical ECoG, brain mapping, and intra-operative ECoG. The etiologies, MRI findings and demography of group A and B were listed in [Table 1](#).

Overall the post-surgical outcomes of epileptic foci located in a single lobe (group A, simple group) and multiple lobes (group B, complicated group) were similar and showed no significant differences. In group A, the good outcome rate was 93.3% (14/15), compared to 80% (12/15) in groups B. In group A (15 patients), the epileptic foci involved the temporal lobe in 10 patients, the frontal lobe in four, and the parietal lobe in one. Analyzing the seizure patterns in group A, we found simple partial seizures in two patients, complex partial seizures in four, and the other nine patients presented with focal seizures with secondary generalization. After intra-operative ECoG and brain mapping, among those 10 patients with T lobe epilepsy, the neurosurgeon chose lesionectomy, T-topectomy or even T lobectomy. In the other four patients with F lobe epilepsy, the neurosurgeon chose lesionectomy, and may combined F- topectomy. The only one patient with parietal lobe epilepsy received lesionectomy. In group B, epileptic foci involved two lobes in 13 patients, and

Table 1 Analysis of epilepsy surgery in 30 patients with epileptic foci involving single lobes (group A) and multiple lobes (group B) by ECoG.

Group	A: simple group	B: complicated group	p value
Epileptic foci-related lobes	single lobe	multiple lobes	
Patient numbers (M/F)	15 (9/6)	15 (9/6)	
Etiology	cavernoma 4 (hemangioma s/p op ^a 1), tumors 3 (oligodendroglioma s/p op ^a 1; glioma p r-knife 1), cortical dysplasia 1, gliosis 4 (trauma 3, cerebral palsy s/p op ^a 1), MTS 1, no obvious lesion 2	cavernoma 1, DNET1, gliosis 6 (trauma 5, both trauma and meningitis 1), cortical dysplasia s/p op ^a 1, ganglioglioma s/p op ^a 1, oligodendroglioma s/p op ^a 1, MTS 1, no obvious lesion 3.	
Surgical procedure	Lobectomy, topectomy, or lesionectomy,	temporal lobectomy, T-/F- topectomy; or combined MST or lesionectomy	
Seizure onset (years old)	3-51 (23.7 ± 14.5)	6-44 (19.2 ± 12.1)	0.368
Age at surgery (years old)	19-51 (34.1 ± 8.8)	19-63 (41.6 ± 11.4)	0.052
Duration between seizure onset and surgery (years)	1-25 (10.7 ± 10.6)	1-54 (22.4 ± 14.0)	0.016 ^a
Post-operation follow-up period (months)	35-91 (55.1 ± 17.6)	29-73 (49.9 ± 15.3)	0.400
Outcomes (Engel's classification)			
Class I	13 (86.6%)	6 (40.0%)	
Class II	1 (6.7%)	6 (40.0%)	
Class III + IV	1 (6.7%)+ 0 (0%)	3 (20.0%)+ 0 (0%)	
Good outcome (class I + II, %)	14 (93.3%)	12 (80.0%)	

Abbreviations: DNET: dysembryoplastic neuroepithelial tumor; MTS: mesial temporal sclerosis; MST: multiple subpial cortical transection; T-topectomy: temporal topectomy; F- topectomy: frontal topectomy; ECoG: electro-corticography.

^a "s/p op": "status post operation", the patient had received tumor resection or epilepsy surgery before.

three lobes in two patients. Three patients had epileptic foci over bilateral hemispheres. Four patients had complex partial seizures, and the other 11 patients presented with focal seizures with secondary generalization.

The neurosurgeon chose partial or total temporal lobectomy, T- or F- topectomy, or in combination with MST for patients in group B. Four of our patients whose epileptogenic zones involved eloquent areas received MST with cytor-education were listed in Table 2. The rate of good outcome of these four patients was 75% (3/4). None of the four patients in our series belonged to class IV, and only one patient was classified as being class III. However, little information is available with regards to surgical failure.

Discussion

The failure of epilepsy surgery may be caused by multiple or widespread epileptogenic zones, or limited resection of the suspected epileptogenic zones [14,15]. Reviewing previous studies, maximal, extensive surgical resection has been reported to be significant associated with seizure freedom for temporal lobe tumors [16,17], cavernous malformations [5,18] and other tumors [19]. Our results showed that lesionectomy, repeated intra-operative ECoG to detect epileptic foci for maximal resection of the surrounding tissues, topectomy and/or in combination with MST may obtain good seizure freedom and few neurological complications. There were no obvious differences in most items among the two groups in our study, except duration between seizure onset and surgery (P value < 0.05, see Table 1). The average duration between seizure onset and surgery was significant longer in group B. We think that the patients in group B were relative refractory, and were thought to be difficult for surgical treatment before. So patients in group B usually had longer duration to evaluate epilepsy surgery when medical therapy failed.

Therefore, we suggest performing as extensive cytor-education as possible, not only to resect the lesions in the epileptogenic zones which do not involve eloquent areas, but also to exclude the possibility of surgical treatment through the etiology. In addition, because no significant differences of outcome were found between simple or complicated groups in our patients, so we suggest that no matter the epileptic foci located in single or multiple lobes, epileptic surgery might be considered as early as possible when medical treatment is not effective.

The patients with epileptic foci involving an eloquent area, especially in frontal lobe, are usually difficult to surgery. Therefore, MST and topectomy were usually necessary [12,20–22]. The rate of good outcome in our four patients receiving MST was 75%, no significant differences with total patients in group B.

With regards to the etiology, the patients with cortical dysplastic lesions and post-traumatic gliosis, meningo-encephalitis and traumatic brain injuries had a higher risk of recurrence, and surgical treatment were not preferred for these patients [8,23,24]. Among our patients, six had received epilepsy surgery or tumor surgery, but failed before. We still performed epilepsy surgery again for them. Three of them were in group A, and the other three patients were in group B.

Table 2 Our 4 patients received multiple subpial cortical transection.

	Patient 1	Patient 2	Patient 3	Patient 4
gender	F	F	M	M
Seizure pattern	CPS	focal Sz with GTCS	focal Sz with GTCS	focal Sz with GTCS
Epileptic foci after ECoG (lobes)	Lt F-T	Rt F-T and Lt T	Rt F-T	Rt F-P
Seizure Onset (y/o)	31	6	11	6
Age of surgery (y/o)	51	46	38	19
Duration between seizure onset and surgery (yrs)	20	40	27	13
MRI findings/etiology	Local Gliosis/trauma	Normal/cryptogenic	Normal/cryptogenic	cortical dysplasia and gliosis/congenital
Surgical methods	Frontal and temporal topectomy, MST, thermocoagulation	Frontal Topectomy, MST	Frontal Topectomy, MST	Frontal Topectomy, MST
Involve eloquent area	motor, sensory, language	motor and sensory	motor	motor, sensory
Follow-up period	41	67	72	64
Outcomes (according to Engel's classification)	class IC	class IIC	class IB	class III

Abbreviations: Sz: seizure; CPS: complex partial seizures; GTCS: generalized tonic-clonic seizures; ECoG: electro-corticography; MST: multiple subpial cortical transection.

The etiologies of them were listed at Table 1. After evaluating the outcomes of these six patients, five were classified as being class I and one as class III. The rate of a good outcome was therefore 83.3% (5/6). We believed that a second epilepsy surgery might be an option for patients with failed previous epilepsy surgery [9,24–27], after complete pre-surgical and intra-operative evaluation.

Reviewing the complications in our 30 patients, four patients received two surgeries during admission. The complication rate related to epilepsy surgery overall was 13.3% (4/30). Three patients had epidural or subdural hematomas during ECoG recording, and required another surgery before cytorreduction (10.0%, 3 in 30 patients); and only one had a mild subdural hematoma after topectomy and received another surgery later (3.3%, 1 in 30 patients). Previous studies showed that most common complications during intra-operative ECoG and epilepsy surgery were cerebrospinal fluid leakage and subdural hematoma [28,29]. The major complication in our patients were subdural hemorrhage that happened during ECoG recording; no cerebrospinal fluid leakage, deep vein thrombosis or sepsis were found [30]. Carefully monitoring consciousness, neurological deficits and ECoG findings (such as asymmetric decreased voltage) of these patients are important in early detection.

There are several limitations to this study, including the retrospective design, lack of a control group for AEDs adjustments, and a lack of comparisons of ketogenic diet [2–4], vagus nerve stimulation [25] or other techniques such as deep brain stimulation.

Conclusion

In our experience, adequate resective surgery of temporal lobectomy or lesionectomy, in combination with topectomy of epileptic foci or MST over eloquent area may achieve good surgical outcomes in patients with refractory epilepsy with multiple epileptic foci with few and non-permanent neurological complications. In addition, although resective reoperation is preferable, it should be performed in only carefully selected patients. Further studies are warranted to confirm our results and the effect in complicated patients and in patients who have failed surgery.

Conflict of interest

There is no conflict of interest.

Acknowledgements

This study was supported by the Chang Gung Epilepsy Center, Lin-Kou. We also thank the neurosurgeons Dr. Chun-Wei Chang and Dr. Jiun-Lin Yan, and Dr. Mei-Yun Cheng for pre-surgical ECoG mapping for each patient.

REFERENCES

- [1] Kwan P, Brodie MJ. Early identification of refractory epilepsy. *N Engl J Med* 2000;342:314–9.
- [2] Kossoff EH, Wang HS. Dietary therapies for epilepsy. *Biomed J* 2013;36:2–8.
- [3] Liu YM, Wang HS. Medium-chain triglyceride ketogenic diet, an effective treatment for drug-resistant epilepsy and a comparison with other ketogenic diets. *Biomed J* 2013;36:9–15.
- [4] Wang HS, Lin KL. Ketogenic diet: an early option for epilepsy treatment, instead of a last choice only. *Biomed J* 2013;36:16–7.
- [5] Siegel AM, Roberts DW, Harbaugh RE, Williamson PD. Pure lesionectomy versus tailored epilepsy surgery in treatment of cavernous malformations presenting with epilepsy. *Neurosurg Rev* 2000;23:80–3.
- [6] Engel J Jr, Wiebe S, French J, Sperling M, Williamson P, Spencer D, et al. Practice parameter: temporal lobe and localized neocortical resections for epilepsy. *Epilepsia* 2003;44:741–51.
- [7] Engel J Jr, Wiebe S, French J, Sperling M, Williamson P, Spencer D, et al. Practice parameter: temporal lobe and localized neocortical resections for epilepsy: report of the quality standards subcommittee of the American academy of Neurology, in association with the American epilepsy society and the American association of neurological surgeons. *Neurology* 2003;60:538–47.
- [8] McIntosh AM, Kalnins RM, Mitchell LA, Fabinyi GC, Briellmann RS, Berkovic SF. Temporal lobectomy: long-term seizure outcome, late recurrence and risks for seizure recurrence. *Brain* 2004;127:2018–30.
- [9] Noachtar S, Borggraefe I. Epilepsy surgery: a critical review. *Epilepsy Behav* 2009;15:66–72.
- [10] Noachtar S, Peters AS. Semiology of epileptic seizures: a critical review. *Epilepsy Behav* 2009;15:2–9.
- [11] Spencer S, Huh L. Outcomes of epilepsy surgery in adults and children. *Lancet Neurol* 2008;7:525–37.
- [12] Bonini F, McGonigal A, Scavarda D, Carron R, Regis J, Dufour H, et al. Predictive factors of surgical outcome in frontal lobe epilepsy explored with stereoelectroencephalography. *Neurosurgery* 2018;83:217–25.
- [13] Wiebe S. Brain surgery for epilepsy. *Lancet* 2003;362:s48–9.
- [14] Hennessy MJ, Elwes RD, Binnie CD, Polkey CE. Failed surgery for epilepsy. A study of persistence and recurrence of seizures following temporal resection. *Brain* 2000;123 Pt 12:2445–66.
- [15] Wyler AR, Hermann BP, Richey ET. Results of reoperation for failed epilepsy surgery. *J Neurosurg* 1989;71:815–9.
- [16] Englot DJ, Han SJ, Berger MS, Barbaro NM, Chang EF. Extent of surgical resection predicts seizure freedom in low-grade temporal lobe brain tumors. *Neurosurgery* 2012;70:921–8.
- [17] Lombardi D, Marsh R, de Tribolet N. Low grade glioma in intractable epilepsy: lesionectomy versus epilepsy surgery. *Acta Neurochir Suppl* 1997;68:70–4.
- [18] Komotar RJ, Mikell CB, McKhann GM 2nd. “Epilepsy surgery” versus lesionectomy in patients with seizures secondary to cavernous malformations. *Clin Neurosurg* 2008;55:101–7.
- [19] Englot DJ, Berger MS, Barbaro NM, Chang EF. Factors associated with seizure freedom in the surgical resection of glioneuronal tumors. *Epilepsia* 2012;53:51–7.
- [20] Mosewich RK, So EL, O’Brien TJ, Cascino GD, Sharbrough FW, Marsh WR, et al. Factors predictive of the outcome of frontal lobe epilepsy surgery. *Epilepsia* 2000;41:843–9.

- [21] Spencer SS, Schramm J, Wyler A, O'Connor M, Orbach D, Krauss G, et al. Multiple subpial transection for intractable partial epilepsy: an international meta-analysis. *Epilepsia* 2002;43:141–5.
- [22] Devinsky O, Romanelli P, Orbach D, Pacia S, Doyle W. Surgical treatment of multifocal epilepsy involving eloquent cortex. *Epilepsia* 2003;44:718–23.
- [23] Téllez-Zenteno JF, Henández Ronquillo L, Moien-Afshari F, Wiebe S. Surgical outcomes in lesional and non-lesional epilepsy: a systematic review and meta-analysis. *Epilepsy Res* 2010;89:310–8.
- [24] Ryzí M, Brázdil M, Novák Z, Hemza J, Chrastina J, Ošlejšková H, et al. Long-term outcomes in patients after epilepsy surgery failure. *Epilepsy Res* 2015;110:71–7.
- [25] Vale FL, Ahmadian A, Youssef AS, Tatum WO, Benbadis SR. Long-term outcome of vagus nerve stimulation therapy after failed epilepsy surgery. *Seizure* 2011;20:244–8.
- [26] Surges R, Elger CE. Reoperation after failed resective epilepsy surgery. *Seizure* 2013;22:493–501.
- [27] Muthaffar O, Puka K, Rubinger L, Go C, Snead OC 3rd, Rutka JT, et al. Reoperation after failed resective epilepsy surgery in children. *J Neurosurg Pediatr* 2017;20:134–40.
- [28] Onal C, Otsubo H, Araki T, Chitoku S, Ochi A, Weiss S, et al. Complications of invasive subdural grid monitoring in children with epilepsy. *J Neurosurg* 2003;98:1017–26.
- [29] Rolston JD, Ouyang D, Englot DJ, Wang DD, Chang EF. National trends and complication rates for invasive extraoperative electrocorticography in the USA. *J Clin Neurosci* 2015;22:823–7.
- [30] Rolston JD, Englot DJ, Cornes S, Chang EF. Major and minor complications in extraoperative electrocorticography: a review of a national database. *Epilepsy Res* 2016;122:26–9.