

[ CASE REPORT ]

## A Functional Parathyroid Cyst from the Hemorrhagic Degeneration of a Parathyroid Adenoma

Atsuko Uehara<sup>1</sup>, Tomo Suzuki<sup>1,2</sup>, Yutaro Yamamoto<sup>3</sup>, Masataka Hasegawa<sup>1</sup>, Kenichiro Koitabashi<sup>1</sup>, Masahiko Yazawa<sup>1</sup>, Junki Koike<sup>4</sup> and Yugo Shibagaki<sup>1</sup>

### Abstract:

A 77-year-old man with a history of hypertension, prostate hyperplasia, and urolithiasis was admitted for acute kidney injury caused by hypercalcemia. Neck ultrasonography showed a large cyst adjacent to the right lower thyroid lobe. Although a <sup>99m</sup>Tc sestamibi scan was negative, an extremely high intracystic intact parathyroid hormone level suggested that the cyst had a parathyroid origin and that a functional parathyroid cyst was present. Immunohistochemical staining for the calcium-sensing receptor (CaSR) after right lower parathyroidectomy revealed CaSR-positive cells lining the cyst, indicating that the functional parathyroid cyst had originated from the hemorrhagic degeneration of a parathyroid adenoma.

**Key words:** hypercalcemia, primary hyperparathyroidism, acute kidney injury, functional parathyroid cyst

(Intern Med 59: 389-394, 2020)

(DOI: 10.2169/internalmedicine.3319-19)

### Introduction

Parathyroid cysts are relatively rare, with an incidence of 0.08-3.41% among all patients with parathyroid disease (1). Most parathyroid cysts are nonfunctional, but 10-15% of cysts secrete parathyroid hormone (PTH), and these are called functional parathyroid cysts (2). Functional parathyroid cysts are present in 1-2% of patients with primary hyperparathyroidism (3).

Positive findings on <sup>99m</sup>Tc (<sup>99m</sup>Tc) sestamibi scans of functional parathyroid cysts are less frequent than for non-cystic parathyroid adenomas (4), and ultrasonography is not effective at distinguishing between cysts with parathyroid origins and those with thyroid origins (5); therefore, identifying cystic parathyroid adenomas is challenging. However, measuring intracystic PTH levels in fine-needle aspirates from cysts is useful for diagnosing functional parathyroid cysts (6-8).

Several mechanisms have been postulated to underlie the development of functional parathyroid cysts, and this report shows that the hemorrhagic degeneration of a parathyroid

adenoma can cause a functional parathyroid cyst.

### Case Report

A 77-year-old man with a 3-month history of fatigue, cognitive dysfunction, thirst, constipation, and appetite loss was admitted to our hospital with acute kidney injury (AKI) and severe hypercalcemia. He had a medical history of hypertension, prostate hypertrophy, and calcium phosphate urolithiasis, for which he had been prescribed telmisartan, amlodipine, magnesium oxide, naftopidil, and mirabegron.

On admission, the patient's blood pressure was 105/66 mmHg, and his heart rate was 76 beats/min. A physical examination revealed a 3×3-cm soft, non-tender mass in the right lower thyroid lobe. His laboratory test results were as follows: serum creatinine level, 3.9 (baseline, 0.8) mg/dL; estimated glomerular filtration rate, 12.7 mL/min/1.73 m<sup>2</sup>; serum albumin level, 4.5 g/dL; serum calcium level, 15.0 mg/dL (no baseline data); and serum phosphate level, 3.5 mg/dL. The patient's laboratory results are shown in Table. Electrocardiography showed a shortened QT interval, with a corrected QT interval of 0.39 seconds.

<sup>1</sup>Division of Nephrology and Hypertension, Department of Internal Medicine, St. Marianna University School of Medicine, Japan, <sup>2</sup>Department of Nephrology, Kameda Medical Center, Japan, <sup>3</sup>Division of Metabolism and Endocrinology, Department of Internal Medicine, St. Marianna University School of Medicine, Japan and <sup>4</sup>Department of Pathology, St. Marianna University School of Medicine, Japan

Received: May 10, 2019; Accepted: August 26, 2019; Advance Publication by J-STAGE: October 7, 2019

Correspondence to Dr. Atsuko Uehara, atsuko\_mori@hotmail.com

Subsequent investigations showed that the patient's plasma intact PTH (iPTH) level was 1,040 pg/mL (reference range, 10-65 pg/mL), urinary calcium/creatinine ratio was 228.9 mg/g creatinine, and his femoral neck and lumbar spine T-scores were -1.7 and -2.3, respectively. The level of tartrate-resistant acid phosphatase 5b (TRACP5b), a bone resorptive marker, was 1,410 mU/dL (reference range, 170-590), while that of bone alkaline phosphatase (BALP), a bone formation marker, was 29.0  $\mu$ g/L (reference range, 3.7-

20.9, Table). Based on this clinical information, primary hyperparathyroidism was diagnosed.

Ultrasonography of the neck demonstrated a 54×42×28 mm cyst adjacent to the thyroid gland, but no mass that could be identified as a parathyroid adenoma or parathyroid hyperplasia was detected (Fig. 1A). The cyst had low echogenicity, and there were no signs of intracystic hemorrhaging. Doppler ultrasonography of the neck revealed no flow around the thyroid. Computed tomography (CT) revealed the presence of a large cyst adjacent to the thyroid gland that compressed the trachea and moved it to the left (Fig. 1B). Bilateral nephrocalcinosis was seen, but neither a ureteral stone nor hydronephrosis was evident. CT also revealed a 22×17-mm right adrenal mass. The patient's adrenal hormone levels were not elevated, which excluded primary aldosteronism, pheochromocytoma, and Cushing's syndrome and indicated that the adrenal mass was a nonfunctional adenoma. Brain magnetic resonance imaging did not reveal any abnormalities, such as a pituitary adenoma or brain atrophy. A <sup>99m</sup>Tc sestamibi scan did not show focal retention compatible with a parathyroid adenoma in the neck or mediastinum.

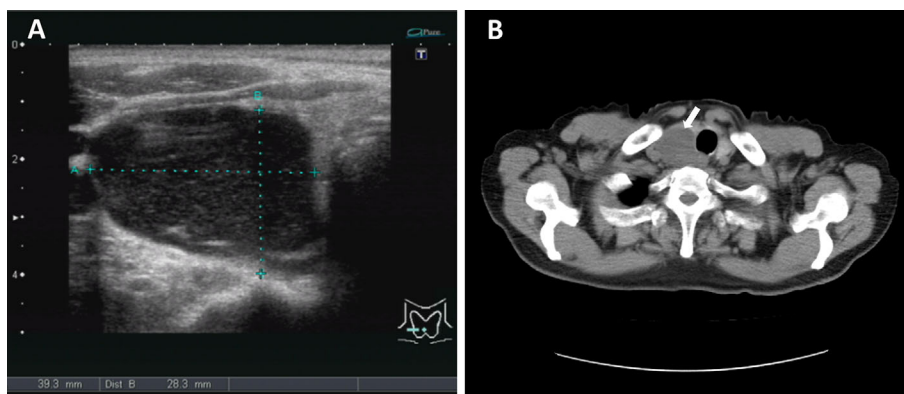
To determine whether the neck cyst was associated with the parathyroid glands, thyroid gland, or neither, fine-needle aspiration of the cyst fluid was performed. Before performing fine-needle aspiration, we considered the possibility of parathyroid cancer and concluded it to be very low because there were no signs of metastasis, including in the lymph nodes, and the ratio of whole PTH to iPTH was less than 1. These observations suggested that the cyst was benign. Fine-needle aspiration revealed the color of the cystic fluid to be dark brown, and the patient's intracystic iPTH level was markedly higher (359,000 pg/mL) than his serum iPTH level. The patient was thus diagnosed with primary hyperparathyroidism caused by a functional parathyroid cyst.

During his admission, the patient's hypercalcemic AKI was treated with a normal saline infusion (2 L/day) and elcatonin (80 U/day) for 3 days as well as alendronate (900  $\mu$ g) for 4 days; his calcium and creatinine levels improved

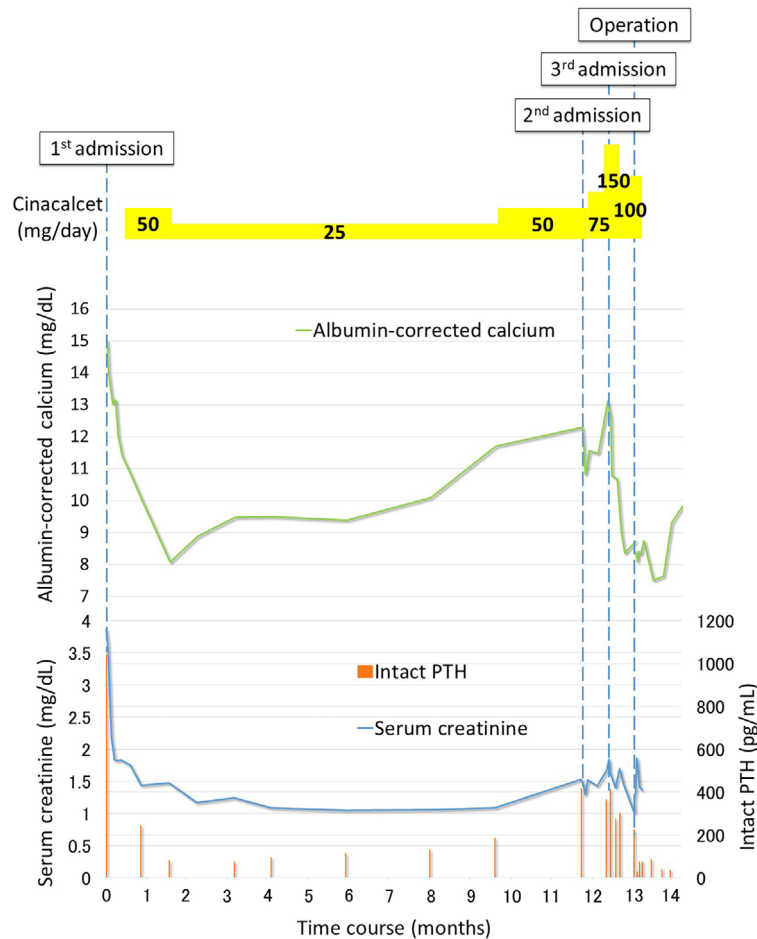
**Table. Initial Laboratory Results.**

| Parameter                         | Level | Reference range |
|-----------------------------------|-------|-----------------|
| Hemoglobin, g/dL                  | 12.6  | 11.0-14.0       |
| Blood urea nitrogen, mg/dL        | 48.5  | 8.0-22.0        |
| Serum creatinine, mg/dL           | 3.86  | 0.6-1.0         |
| eGFR, mL/min/1.73 m <sup>2</sup>  | 12.7  | 90-120          |
| Serum albumin, g/dL               | 4.5   | 4.1-5.1         |
| Serum sodium, mEq/L               | 135   | 135-140         |
| Serum potassium, mEq/L            | 4.9   | 3.5-5.1         |
| Serum chloride, mEq/L             | 101   | 97-109          |
| Serum calcium, mg/dL              | 15.0  | 8.8-10.3        |
| Serum ionized calcium, mEq/L      | 3.92  | 2.0-2.7         |
| Serum phosphorus, mg/dL           | 3.5   | 2.5-4.5         |
| Serum magnesium, mEq/L            | 4.5   | 1.8-2.4         |
| Alkaline phosphatase, IU/L        | 380   | 44-147          |
| Intact PTH, pg/mL                 | 1,040 | 10-65           |
| Whole PTH, pg/mL                  | 502   | 8.3-38.7        |
| PTH-rP, pmol/L                    | <1.1  | <1.1            |
| 1,25-dihydroxyvitamin D, pg/mL    | 39    | 20-60           |
| TRACP5b, mU/dL                    | 1,410 | 170-590         |
| BALP, $\mu$ g/L                   | 29.0  | 3.7-20.9        |
| FECa, %                           | 11.8  | NA              |
| Calcium/creatinine ratio, mg/g Cr | 228.9 | <140            |
| TmP/GFR, mg/dL                    | 1.93  | 2.3-4.3         |

BALP: bone alkaline phosphatase, Cr: creatinine, eGFR: estimated glomerular filtration rate, FECa: fractional excretion of calcium, NA: not available, PTH: parathyroid hormone, PTH-rP: parathyroid hormone related protein, TmP/GFR: ratio of tubular maximum reabsorption rate of phosphate to glomerular filtration rate, TRACP5b: tartrate-resistant acid phosphatase-5b



**Figure 1.** (A) Ultrasonography showing a large cyst with low echogenicity adjacent to the right lower thyroid gland. (B) Computed tomography showing a large cyst (arrow) compressing the trachea.



**Figure 2.** The serum calcium, serum creatinine, intact parathyroid hormone levels, and cinacalcet dose administered after the patient was admitted to our hospital for the first time. When the patient's serum albumin level was  $<4.0$  g/dL, the albumin-corrected calcium level was calculated as total calcium (mg/dL)  $+0.8 \times [4.0 - \text{serum albumin (g/dL)}]$ . The serum calcium level was stable for eight months following cinacalcet initiation, after which it began to increase, requiring frequent admissions.

to 10.8 mg/dL and 1.75 mg/dL, respectively, by 18 days after admission, and his symptoms (cognitive dysfunction and appetite loss) subsided.

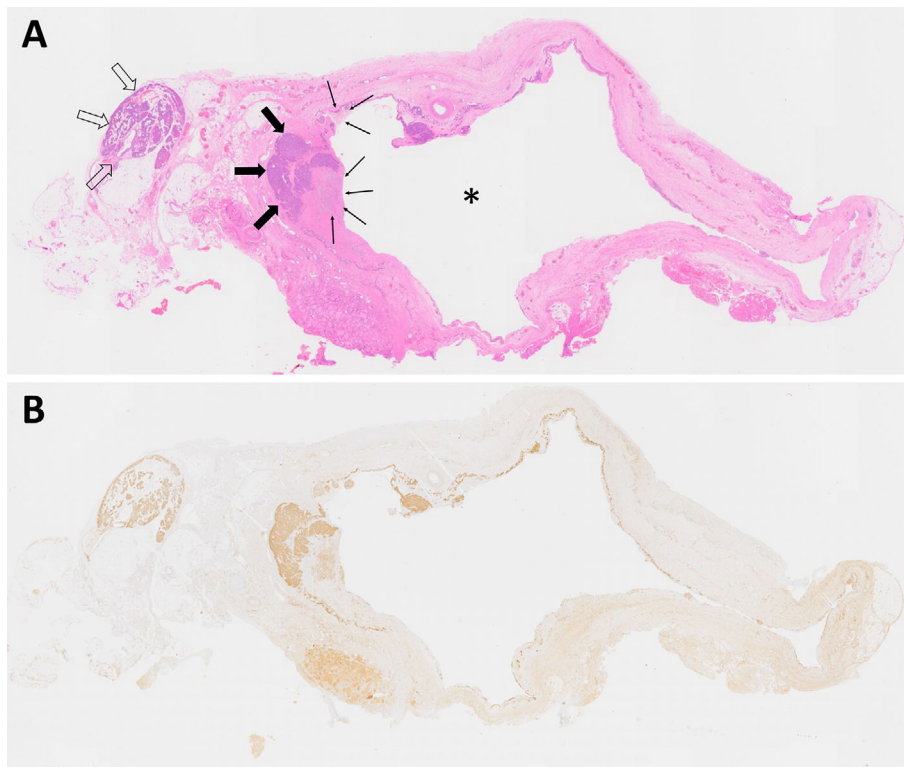
Although we recommended right lower parathyroidectomy, the patient was reluctant to undergo this procedure. Thus, cinacalcet (50 mg) was administered in an attempt to reduce his iPTH and calcium levels, but the hypercalcemia was refractory to treatment, even after the cinacalcet dose was increased to 150 mg; the patient was readmitted to the hospital twice in 1 year for AKI secondary to hypercalcemia (Fig. 2). The patient finally agreed to undergo parathyroidectomy one year later, and right lower parathyroidectomy was performed. Postoperatively, the patient's iPTH and calcium levels normalized rapidly. The patient was discharged six days after the operation, and his calcium and iPTH levels remained stable for two years without postoperative complications.

The histopathological findings showed a parathyroid adenoma with an adjacent cyst and atrophy of the normal rim of the parathyroid tissue. Hemosiderin, red blood cells, and a granuloma were present inside the parathyroid adenoma

and the cyst, suggesting hemorrhaging (Fig. 3A). Immunohistochemical staining for the calcium-sensing receptor (CaSR) revealed that the cyst was lined with 1 layer of CaSR-positive cells, and that the adenoma and atrophied parathyroid cells were also CaSR-positive, indicating that the origin of the parathyroid adenoma had been dissected (Fig. 3B). Unfortunately, immunohistochemical staining for PTH could not be performed in our institution; however, hematoxylin and eosin staining showed that the bulk of oxyphil cells were connected to the layer cells surrounding the cyst, indicating that the CaSR-positive cells were equivalent to parathyroid cells. Accordingly, the functional parathyroid cyst was shown to be derived from the hemorrhagic degeneration of a parathyroid adenoma.

## Discussion

We encountered a patient with a functional parathyroid cyst that arose from the hemorrhagic degeneration of a parathyroid adenoma and caused hypercalcemia and AKI until parathyroidectomy was performed. This patient's findings



**Figure 3.** (A) Hematoxylin and Eosin staining showing a parathyroid adenoma (thick arrows) with adjacent atrophic parathyroid tissue (open arrows), cyst formation (asterisk), and hemorrhaging inside both the adenoma and cyst (thin arrows). (B) Immunohistochemical staining for the calcium-sensing receptor (CaSR) revealed that the cyst was lined with one layer of CaSR-positive cells, suggesting a functional parathyroid cyst.

emphasize the importance of detecting high intracystic PTH levels for identifying a cystic parathyroid adenoma and underscore the value of performing pathological analyses to determine the mechanism by which a cyst in the anterior neck or adjacent to thyroid can arise from a parathyroid adenoma.

Like non-cystic parathyroid adenomas, functional parathyroid cysts can cause hypercalcemia, urolithiasis, and osteoporosis, but unlike non-cystic parathyroid adenomas, parathyroid cysts can compress adjacent tissues (9). In our patient, the cyst had compressed the trachea to shift toward the left, although this was asymptomatic. Notably, the sensitivity of  $^{99m}\text{Tc}$  sestamibi scans for functional parathyroid cysts is lower (29%) than that for non-cystic parathyroid adenomas (68-95%) (4). In our patient, as the  $^{99m}\text{Tc}$  sestamibi scan was negative, a parathyroid adenoma could not be detected. In addition, ultrasonography does not provide any information about whether these cysts arise from the parathyroid or thyroid glands, which makes identifying the cystic mass as a parathyroid adenoma difficult (5). The intracystic iPTH levels in fine-needle aspirates are useful for determining whether a cyst is a parathyroid cyst, thyroid cyst, or non-functional cyst (6-8). However, before performing fine-needle aspiration, determining whether or not the cyst is related to parathyroid cancer is important because fine-needle aspiration is contraindicated in parathyroid cancer due to the

risk of seeding along the needle tract (10).

Parathyroid cancer is suspected based on several factors, including an extremely high level of PTH, the presence of metastatic lesions, and a ratio of whole PTH to iPTH exceeding 1 (11). In our patient, the high levels of iPTH suggested a risk of parathyroid cancer; however, the absence of metastatic lesions and the ratio of whole PTH to iPTH being less than 1 led us to conclude that the possibility of parathyroid cancer was very low. In addition, the patient's history of calcium phosphate urolithiasis and the presence of bilateral nephrocalcinosis indicated that the patient had been exposed to chronic hypercalciuria, suggesting that the parathyroid lesion was benign. Of note, another complication of fine-needle aspiration of a parathyroid cyst is intracystic hemorrhaging, which can exacerbate hypercalcemia. We therefore performed aspiration in an in-hospital setting and closely monitored the patient's calcium level. In our patient, the iPTH level in the cyst fluid was much higher than that in the plasma, indicating that the cyst had a parathyroid origin and that resection of this cyst was indicated, as it could result in resolution of hyperparathyroidism.

The presumptive mechanisms underlying the occurrence of functional parathyroid cysts include their congenital acquisition, microcyst coalescence, and the infarction of or hemorrhaging into a parathyroid adenoma (12). In our patient, the immunohistochemical analysis showed that the

cyst was lined with one layer of CaSR-positive cells and that the microcysts within the atrophic parathyroid tissue were CaSR-negative, which excluded the possibility of microcyst coalescence. In addition, hematoxylin and eosin staining showed that hemorrhaging was present inside the adenoma and cyst, suggesting that the functional parathyroid cyst was derived from the hemorrhagic degeneration of a parathyroid adenoma.

Treating a functional parathyroid cyst involves resecting the cyst (13), fine-needle aspiration of the intracystic fluid (14), or injecting sclerosing agents into the cyst (15). Fine-needle aspiration is less invasive than dissecting parathyroid cysts, but the remission rate remains at 33%, and the recurrence rate is high. Intracystic injection of sclerosing agents is also less invasive than dissecting parathyroid cysts, but the cysts are lined by a layer of parathyroid cells only, and there is a high risk of leakage of the sclerosing agent that can cause fibrosis within the surrounding tissues, which might result in nerve injury. Furthermore, the failure of sclerosing therapy can increase the risks and morbidity associated with any subsequent surgical procedure (13). The first-line treatment of a functional parathyroid cyst is surgical dissection. In patients who cannot tolerate surgery as a consequence of systemic complications, including cardiovascular disease, or if a patient does not wish to undergo a surgical procedure, medical treatment with cinacalcet seems to be effective. Indeed, the effectiveness of cinacalcet in treating primary hyperparathyroidism caused by parathyroid adenomas or parathyroid hyperplasia has been described (16-19). However, the effectiveness of cinacalcet in treating a functional parathyroid cyst has not been reported. Our patient began cinacalcet treatment after the first episode of hypercalcemia and AKI, and it was effective for several months, but the hypercalcemia eventually became refractory to treatment. The parathyroid adenoma and cyst were CaSR-positive, which suggested that cinacalcet treatment should have been effective. As seen in Fig. 2, the patient's calcium level increased abruptly just before the third admission. There were no signs of acute intracystic hemorrhaging, such as bulging or tenderness of the neck mass, and the urine calcium level was 102.9 mg/gCr, which was relatively low despite hypercalcemia. We suspect that despite the patient's denials, he stopped taking the medication, likely causing the treatment to become ineffective. A previous article reported that 88% of patients with intractable primary hyperparathyroidism administered cinacalcet experienced treatment-related adverse events, including nausea, vomiting, and paresthesia, leading to withdrawal from the study in 24% (20).

We described a patient with a functional parathyroid cyst that arose from the hemorrhagic degeneration of a parathyroid adenoma. To our knowledge, this is the first report that describes a functional parathyroid cyst lined by CaSR-positive parathyroid cells. These findings will encourage clinicians who encounter patients with similar lesions to identify parathyroid cysts by analyzing fine-needle aspirates from the cysts and dissecting the causative lesions.

**The authors state that they have no Conflict of Interest (COI).**

## References

- Halenka M, Fryszak Z, Koranda P, Kucerova L. Cystic parathyroid adenoma within a multinodular goiter: a rare cause of primary hyperparathyroidism. *J Clin Ultrasound* **36**: 243-246, 2008.
- Wani S, Hao Z. Atypical cystic adenoma of the parathyroid gland: case report and review of literature. *Endocr Pract* **11**: 389-393, 2005.
- McCoy KL, Yim JH, Zuckerbraun BS, Ogilvie JB, Peel RL, Carty SE. Cystic parathyroid lesions: functional and nonfunctional parathyroid cysts. *Arch Surg* **144**: 52-56, 2009.
- Johnson NA, Yip L, Tublin ME. Cystic parathyroid adenoma: sonographic features and correlation with <sup>99m</sup>Tc-sestamibi SPECT findings. *AJR Am J Roentgenol* **195**: 1385-1390, 2010.
- Suzuki K, Sakuta A, Aoki C, Aso Y. Hyperparathyroidism caused by a functional parathyroid cyst. *BMJ Case Rep* **2013**: 2013.
- Yalcin Y, Mete T, Aktimur R, et al. A case of primary hyperparathyroidism due to intrathyroidal parathyroid cyst. *Case Rep Endocrinol* **2014**: 2014.
- Ippolito G, Palazzo FF, Sebag F, Sierra M, De Micco C, Henry JF. A single-institution 25-year review of true parathyroid cysts. *Langenbecks Arch Surg* **391**: 13-18, 2006.
- Sumana BS, Sabaretnam M, Sarathi V, Savith A. Functional parathyroid cystic adenoma: a rare cause of hypercalcemic crisis with primary hyperparathyroidism. *Indian J Pathol Microbiol* **58**: 487-490, 2015.
- Papavramidis TS, Chorti A, Pliakos I, Panidis S, Michalopoulos A. Parathyroid cysts: a review of 359 patients reported in the international literature. *Medicine (Baltimore)* **97**: e11399, 2018.
- Kim J, Horowitz G, Hong M, Orsini M, Asa SL, Higgins K. The dangers of parathyroid biopsy. *J Otolaryngol Head Neck Surg* **46**: 4, 2017.
- Cavelier E, Daly AF, Betea D, et al. The ratio of parathyroid hormone as measured by third- and second- generation assays as a marker for parathyroid carcinoma. *J Clin Endocrinol Metab* **95**: 3745-3749, 2010.
- Makino T, Sugimoto T, Kaji H, et al. Functional giant parathyroid cyst with high concentration of CA19-9 in cystic fluid. *Endocr J* **50**: 215-219, 2003.
- El-Housseini Y, Hübner M, Boubaker A, Bruegger J, Matter M, Bonny O. Unusual presentations of functional parathyroid cysts: a case series and review of the literature. *J Med Case Rep* **11**: 333, 2017.
- Ing SW, Pelliteri PK. Diagnostic fine-needle aspiration biopsy of an intrathyroidal parathyroid gland and subsequent eucalcemia in a patient with primary hyperparathyroidism. *Endocr Pract* **14**: 80-86, 2008.
- Fortson JK, Patel VG, Henderson VJ. Parathyroid cysts: a case report and review of the literature. *Laryngoscope* **111**: 1726-1728, 2001.
- Shoback DM, Bilezikian JP, Turner SA, McCary LC, Guo MD, Peacock M. The calcimimetic cinacalcet normalizes serum calcium in subjects with primary hyperparathyroidism. *J Clin Endocrinol Metab* **88**: 5644-5649, 2003.
- Peacock M, Bilezikian JP, Klassen PS, Guo MD, Turner SA, Shoback D. Cinacalcet hydrochloride maintains long-term normocalcemia in patients with primary hyperparathyroidism. *J Clin Endocrinol Metab* **90**: 135-141, 2005.
- Khan A, Khan Y, Raza S, et al. Functional parathyroid cyst: a rare cause of malignant hypercalcemia with primary hyperparathyroidism—a case report and review of the literature. *Case Rep Med* **2012**: 851941, 2012.
- Takeuchi Y, Takahashi S, Miura D, et al. Cinacalcet hydrochloride relieves hypercalcemia in Japanese patients with parathyroid can-

cer and intractable primary hyperparathyroidism. *J Bone Miner Metab* **35**: 616-622, 2017.

20. Marcocci C, Chanson P, Shoback D, et al. Cinacalcet reduces serum calcium concentrations in patients with intractable primary hyperparathyroidism. *J Clin Endocrinol Metab* **94**: 2766-2772, 2009.

The Internal Medicine is an Open Access journal distributed under the Creative Commons Attribution-NonCommercial-NoDerivatives 4.0 International License. To view the details of this license, please visit (<https://creativecommons.org/licenses/by-nc-nd/4.0/>).

---

© 2020 The Japanese Society of Internal Medicine  
*Intern Med* 59: 389-394, 2020