

Partial anomalous hepatic venous drainage into left-sided atrium with right isomerism: A case report with review of literature

Ishan Kumar, Anmol Bhatia¹, Kushaljit S Sodhi, Niranjan Khandelwal

Department of Radiodiagnosis and Imaging, and ¹GE Radiology Section, Department of Gastroenterology, Post Graduate Institute of Medical Education and Research, Chandigarh, India

Correspondence: Dr. Anmol Bhatia, GE Radiology Section, Department of Gastroenterology, Post Graduate Institute of Medical Education and Research, Chandigarh - 160 012, India. E-mail: anmol_bhatia26@yahoo.co.in

Abstract

Right isomerism, also known as Ivemark syndrome, is an unusual degree of symmetry of some of the abdominothoracic viscera reflecting bilateral right-sidedness. We report an exceedingly rare occurrence of anomalous drainage of the left hepatic vein to the left-sided atrium in a patient of right isomerism. With this case report, we further endorse that the isomerism of atrium might extend beyond the appendages, a view that has been long dismissed by the existing literature.

Key words: Anomalous; drainage; hepatic; left atrium; venous

Introduction

Heterotaxy syndromes (HS) constitute disorders involving abnormal lateralization and arrangement of the abdominal viscera, thoracic organs, and atria of the heart along right-left axis of the body. HS is categorized into two major recognized groups, namely, the right and left atrial isomerism because atrial isomerism forms the major component of these disorders. However, the current literature strongly favors the use of the term atrial appendage isomerism because it has been shown that, based on morphological assessment, the degree of isomerism of atrium has been unequivocally present only in atrial appendages.^[1] Various cardiovascular and noncardiovascular complex disorders are often associated with these syndromes, which are in general more severe in right isomerism.^[2]

Right isomerism reflects bilateral right-sidedness of abdominothoracic organs and is commonly associated with asplenia. The incidence of this disease is approximately 1/10000–1/40000 births.^[3] We report an exceedingly rare occurrence of anomalous drainage of left hepatic vein in a patient of right isomerism.

Case Report

A 3-month-old infant presented to the pediatric clinic of our institute with chief complaints of respiratory distress since birth. There was no history of bluish discoloration of the skin, fever, or cough. Transthoracic echocardiography revealed mild enlargement of the right atrium and right ventricle with double outlet right ventricle (DORV),

Access this article online

Quick Response Code:



Website:
www.ijri.org

DOI:
10.4103/0971-3026.209208

This is an open access article distributed under the terms of the Creative Commons Attribution-NonCommercial-ShareAlike 3.0 License, which allows others to remix, tweak, and build upon the work non-commercially, as long as the author is credited and the new creations are licensed under the identical terms.

For reprints contact: reprints@medknow.com

Cite this article as: Kumar I, Bhatia A, Sodhi KS, Khandelwal N. Partial anomalous hepatic venous drainage into left-sided atrium with right isomerism: A case report with review of literature. Indian J Radiol Imaging 2017;27:177-80.

atrioventricular canal defect, and partial anomalous pulmonary venous return.

Computed tomography angiography (CTA) of the thorax was planned to delineate the vascular anatomy prior to surgery. CTA was performed on a 64-slice multidetector computed tomography (MDCT) scanner (Toshiba Aquilion V3.30ER001 Toshiba America Medical Systems) and was evaluated on Aquarius Intuition workstation (Terrarecon version 3.4). CTA showed situs ambiguous in the form of bilateral trilobar bronchi, with D-loop [Figure 1A]. Single SVC was seen draining into the right-sided atrium. Right and middle hepatic veins were seen joining IVC, which was seen draining into the right-sided atrium. However, two left hepatic veins were seen showing abnormal termination into the left-sided atrium [Figure 1B]. Pulmonary veins draining from the left upper lobe were seen joining into persistent vertical vein, which was then joining the left brachiocephalic vein, and thereby SVC subsequently, suggesting partial anomalous pulmonary venous drainage (PAPVD) [Figure 1C]. Right side pulmonary veins as well as inferior pulmonary vein on the left side were seen to form a common channel, which was joining left-sided atrium posteriorly [Figure 1D]. There was a large defect at the junction of the atrium and the ventricle suggestive of atrioventricular canal defect (AVCD), with a common valve guarding the atrioventricular junction. Mixed atrioventricular connection was seen with right-handed

ventricular topology (D-loop). Right sided chambers were dilated. DORV was seen with the aorta positioned left-sided relative to the pulmonary trunk [Figure 1E]. Pulmonary trunk and its subsequent branches were normal. Aortic arch was right sided. Patches of pulmonary consolidations were seen in bilateral lower lobes. Abdominal sections revealed absence of spleen (suggestive of asplenia) with an enlarged midline liver. With all these findings detected on CTA, a diagnosis of heterotaxy syndrome (DORV, AV canal defect, PAPVD, and asplenia with abnormal subdiaphragmatic venous drainage) was offered.

Discussion

The continued existence of multiple terms such as “situs ambiguous,” “heterotaxy syndromes,” atrial appendage “isomerism,” asplenia/polysplenia syndrome, to describe the disharmony associated with abnormal lateralization of thoracoabdominal organs, highlights the fact that none of these terms are unequivocally optimal. Hence, if the description of these disorders is to be meaningful, it should specifically account for each organ separately.^[1] By convention, these disorders are segregated into right and left isomerism.

CTA is useful to evaluate children with known or suspected congenital heart disease on the basis of echocardiographic findings, which need to be further characterized, and also to evaluate extracardiac anomalies before intervention.^[4] The pulmonary vasculature, aorta, and its branches may be inadequately visualized at echocardiography due to limited acoustic window, which necessitates further assessment with CTA. Catheter-directed cardiac angiography is limited by its inability to simultaneously evaluate systemic and pulmonary vasculature as well as its two-dimensional nature against the three-dimensional evaluation, which is possible with CTA.^[4] Moreover, cardiac catheterization is invasive, requires general anesthesia, and has a higher complication rate, requires a larger volume of contrast material,^[4] and is associated with a greater radiation dose to the patient as against CTA.

Right isomerism, historically known as Ivemark syndrome, can present with a constellation of various cardiovascular and extracardiac anomalies. The most consistent features of this disorder are right atrial appendage isomerism, absence of spleen, bilateral trilobed lungs, abnormal pulmonary venous return, pulmonary outflow tract obstruction, common atrium, AV valve abnormality, and discordant ventriculoarterial connection. Other less consistent cardiac anomalies associated with this disease are abnormal systemic venous drainage, ventricular hypoplasia, and right-sided aortic arch.^[5] In addition to the the cardiac and bronchopulmonary anomalies, various genitourinary, central nervous system (CNS), endocrine, and musculoskeletal anomalies are also described.^[3]

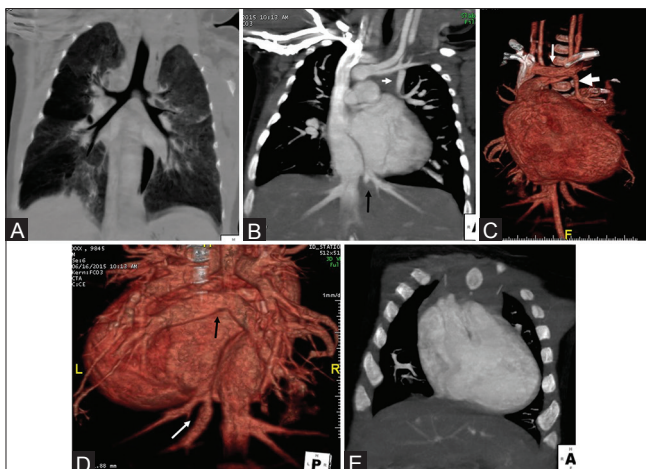


Figure 1 (A-E): (A) MDCT coronal reconstructed image showing bilateral trilobed lungs. (B) MDCT coronal maximum intensity projection (MIP) image showing hepatic veins draining into the left atrium (black arrow). In addition, anomalous drainage of the pulmonary veins from the left upper lobe draining into the persistent vertical vein is also seen (white arrow). (C) MDCT volume rendered (VR) image showing the pulmonary veins from the left upper lobe draining into the persistent vertical vein (thick arrow) which is joining into the left brachiocephalic vein (thin arrow). (D) MDCT VR image showing the common channel formed by left and right-side pulmonary veins (black arrow). Also seen are the hepatic veins draining into the left atrium (white arrow). (E) MDCT coronal reconstructed MIP image showing the origin of the aorta and pulmonary artery from the right ventricle suggestive of double outlet right ventricle

Abnormal systemic venous return has been previously described with the so-called “congenital asplenia syndrome.” In a study by Hashmi *et al.* among 91 patients of right HS, various anomalous venoatrial discordance were identified, predominantly in the form of double SVC, single left SVC, bilateral SVC without a connecting innominate vein, IVC draining into left-sided atrium, total and partial anomalous hepatic venous drainage to the right-sided atrium.^[4] However, direct connection of a hepatic vein to the left-sided atrium, as in the index case, is extremely uncommon.

Only few cases of abnormal congenital hepatic venous return to the left atrium has been described in the literature.^[6-10] Even minority of these are, however, in the clinical setting of HS. Tofeig *et al.* described a case of right isomerism, in which left-sided shunt of hepatic veins developed as a consequence of surgical procedure.^[11] Giamberti *et al.* described two patients with right isomerism, which was corrected with fenestrated Fontan’s procedure, in which right to left shunts developed from the IVC through the liver to a hepatic vein draining to left atrium.^[12] Rubino *et al.*, in postmortem study of the preserver hearts, also described drainage of the hepatic veins to the left-sided atrium in the right isomerism. They also observed that the separately draining IVC, and hepatic veins are interconnected via a large venous sinus in many of these.^[13] In another retrospective analysis of postmortem specimens, Uemura *et al.* noted bilateral atrial drainage of the right and left hepatic venous channels in the setting of HS, although he found it to be more common in left isomerism.^[14] To the best of our knowledge, the index case is first to report congenital bilateral hepatic venous returns based on imaging of the living patient.

Various other anomalies that have been reported in association of this anomaly include the presence of intrapulmonary shunts, interrupted IVC, ventriculoarterial discordance (Tetralogy of Fallot and DORV), anomalous pulmonary venous drainage, right-sided aortic arch, patent foramen ovale, bicuspid pulmonary valve, and infundibular pulmonic stenosis.^[6-10] Development of the intrapulmonary shunts in these patients is postulated to be caused due to the deprivation of an unknown hepatic factor as a result of exclusion of hepatic venous blood from the lung, as often seen as the complications of Glenn shunt and Fontan procedure.^[6,7] The absence of intrapulmonary shunts in the index case can be explained by the fact that only left-sided veins were anomalous, and right and middle hepatic vein were draining into the right atrium, and thus entering pulmonary circulation. Furthermore, the presence of atrioventricular septal defect allows the blood mixture at the atrial level, which would be sufficient to provide hepatic venous flow to the lungs.

The index case has several striking features:

- Right-to-left shunt due to partial anomalous hepatic venous drainage to the left atrium

- Left-to-right shunt due to partial anomalous pulmonary venous return to right atrium
- A complete atrioventricular canal defect which might be allowing unrestricted interatrial and interventricular communication
- DORV which further hypothetically brings about the averaging of the saturations of pulmonary and systemic flow.

Presence of both the left-to-right and right-to-left shunt with a large intercommunicating cardiac AVCD raises a dilemma as to what should be the appropriate treatment and whether or not a surgical intervention is necessary. With bidirectional shunt anomalies, it is possible to have an equal ratio of blood flow to pulmonary and systemic circulation.^[15] The unusual occurrence of bidirectional isolated shunts in this case mandates an embryological and etiological explanation. Persistence of left vitelline vein is postulated to provide connection between the liver and left atrium.^[11] It is again imperative to note that isolated left-sided anomalous hepatic venous return to the left atrium has never been reported, which might explain and reflect in its unique association with HS.

Our case is also remarkable by the fact that it raises important question contrary to the long held view that atrial isomerism is not a real thing and should be more aptly described as atrial appendage isomerism.^[14,16,17] Separate hepatic venous drainage of the left and right-sided hepatic veins into the right and left-sided atrium invites explanations that whether the degree of isomerism extends beyond the appendages.

Conclusion

To conclude, this case report augments the existing sparse literature regarding this anomaly and describes its new associations. To the best of our knowledge, this is the first reported case of bilateral drainage of hepatic veins in the clinical setting of HS demonstrated by MDCT angiography, which is a very effective investigation in the diagnosis of complex congenital heart disease over direct invasive procedures.

Financial support and sponsorship

Nil.

Conflicts of interest

There are no conflicts of interest.

References

1. Loomba RS, Hlavacek AM, Spicer DE, Anderson RH. Isomerism or heterotaxy: Which term leads to better understanding? *Cardiol Young* 2015;25:1037-43.
2. Rose V, Izukawa T, Moes CAF. Syndromes of asplenia and polysplenia: A review of cardiac and non-cardiac malformations in 60 cases with special reference to diagnosis and prognosis. *Br Heart J* 1975;37:840-52.

3. Chen H. Ivemark Syndrome. In: Chen H, editor. Atlas of Genetic diagnosis and counselling. New Jersey: Humana press; 2006. P 549-52.
4. Hashmi A, Abu-Sulaiman R, McCrindle BW, Smallhorn JF, Williams WG, Freedom RM. Management and outcomes of right atrial isomerism: A 26-year experience. *J Am Coll Cardiol* 1998;31:1120-6.
5. Dillman JR, Hernandez RJ. Role of CT in the Evaluation of Congenital Cardiovascular Disease in Children. *Am J Roentgenol* 2009;192:1219-31.
6. Stoller JK, Hoffman RM, White RD, Mee RB. Anomalous hepatic venous drainage into the left atrium: An unusual cause of hypoxemia. *Respir Care* 2003;48:58-62.
7. Lee J, Menkis AH, Rosenberg HC. Reversal of pulmonary arteriovenous malformation after diversion of anomalous hepatic drainage. *Ann Thorac Surg* 1998;65:848-9.
8. Yee KF. Anomalous termination of a hepatic vein in the left atrium. *Arch Pathol* 1968;85:219-23.
9. Mantri RR, Bajaj R, Shrivastava S. Multiple anomalies of caval veins in a patient with pulmonic stenosis. *Int J Cardiol* 1994;46:172-4.
10. Kloppenburg GT, Post MC, Mager HJ, Schepens MA. Rerouting Anomalous Hepatic Venous Connection to the Left Atrium. *Ann Thorac Surg* 2010;90:638-40.
11. Tofeig M, Walsh KP, Arnold R. Transcatheter occlusion of a post-Fontan residual hepatic vein to pulmonary venous atrium communication using the Amplatzer septal occluder. *Heart* 1998;79:624-6.
12. Giamberti A, Anderson RH, de Leval MR. Intrahepatic right-to-left shunting after the Fontan operation. *Cardiol Young* 2002;12:308-10.
13. Rubino M, Van Praagh S, Kadoba K, Pessotto R, Van Praagh R. Systemic and pulmonary venous connections in visceral heterotaxy with asplenia. *JCTVS* 1995;110:641-50.
14. Uemura H, Ho SY, Devine WA, Kilpatrick L, Anderson RH. Atrial appendages and venoatrial connections in hearts from patients with visceral heterotaxy. *Ann Thorac Surg* 1995;60:561-9.
15. Sommer RJ, Hijazi ZM, Rhodes JF. Pathophysiology of congenital heart disease in the Adult. *Circulation* 2008;117:1090-9.
16. Anderson RH. Is isomerism of the atrial appendages a real thing? *Cardiol Young* 1995;5:207-8.
17. Van Praagh R, Van Praagh S. Atrial isomerism in the heterotaxy syndromes with asplenia, or polysplenia, or normally formed spleen: An erroneous concept. *Am J Cardiol* 1990;66:1504-6.