

Available online at www.sciencedirect.com

ScienceDirect

journal homepage: www.elsevier.com/locate/radcr

Case report

Quadrilateral space syndrome induced by a large degenerative osteophyte [☆]

Thymur Ali Chaudhry, MD^{a,*}, Adam M. Doedtman, BS^a, Elek Wellman, BS^a, Daniel Stanton, MD^{a,b}

^aDepartment of Diagnostic Radiology, Southern Illinois University School of Medicine, 800 E. Carpenter Street, Box 43, Room 1F084, Springfield, IL 62769 USA

^bCentral Illinois Radiological Associates, Ltd. at Saint John's Hospital, 800 E. Carpenter St., Springfield, IL 62769, USA

ARTICLE INFO

Article history:

Received 22 May 2021

Revised 1 June 2021

Accepted 2 June 2021

Keywords:

quadrilateral space syndrome

MRI

teres minor

denervation

rotator cuff injury

axillary nerve

ABSTRACT

A 41-year-old gentleman presented with decreased range of motion. Initial radiographs demonstrated extensive osteoarthritic changes involving the glenohumeral joint with a large inferior oriented osteophyte. Subsequent MRI of the shoulder was obtained which demonstrated isolated fatty atrophy of the teres minor and, to a lesser extent, deltoid muscles. The axillary nerve was visualized entering the quadrilateral space which, although, was severely narrowed secondary to the large osteophyte. The patient's clinical symptoms and MRI findings were consistent with quadrilateral space syndrome. The patient wanted to attempt conservative therapy first; and therefore, subsequently underwent physical therapy with improvement of shoulder strength and range of motion.

© 2021 The Authors. Published by Elsevier Inc. on behalf of University of Washington.

This is an open access article under the CC BY-NC-ND license

(<http://creativecommons.org/licenses/by-nc-nd/4.0/>)

Introduction

The quadrilateral space is a small anatomic region inferior and posterior to the glenohumeral joint, defined by muscles, bone and fibrous tissue. This space is bordered laterally by the shaft of the humerus, medially by the long head of the triceps brachii, superiorly by the teres minor and inferiorly by the teres major [1] (Fig. 8). Both the axillary nerve, or one of its major branches, and posterior circumflex humeral artery run posteriorly through this space, supplying the teres minor and

deltoid muscles. Quadrilateral Space Syndrome (QSS) is an uncommon diagnosis characterized by shoulder pain secondary to compression of the axillary nerve and/or posterior humeral circumflex artery as they traverse through the quadrilateral space [2,3]. Literature on QSS is limited, as rotator cuff pathology is much more common. It is largely a diagnosis of exclusion with many cases misdiagnosed [4]. QSS can be an important consideration in the differential of a patient presenting with vague shoulder pain of unknown etiology.

We present an interesting case of QSS secondary to a large, degenerative osteophyte in a 41-year-old man. The patient

[☆] Competing Interest: None

* Corresponding author. T.A. Chaudhry

E-mail address: thymur.a.chaudhry@gmail.com (T.A. Chaudhry).

<https://doi.org/10.1016/j.radcr.2021.06.002>

1930-0433/© 2021 The Authors. Published by Elsevier Inc. on behalf of University of Washington. This is an open access article under the CC BY-NC-ND license (<http://creativecommons.org/licenses/by-nc-nd/4.0/>)

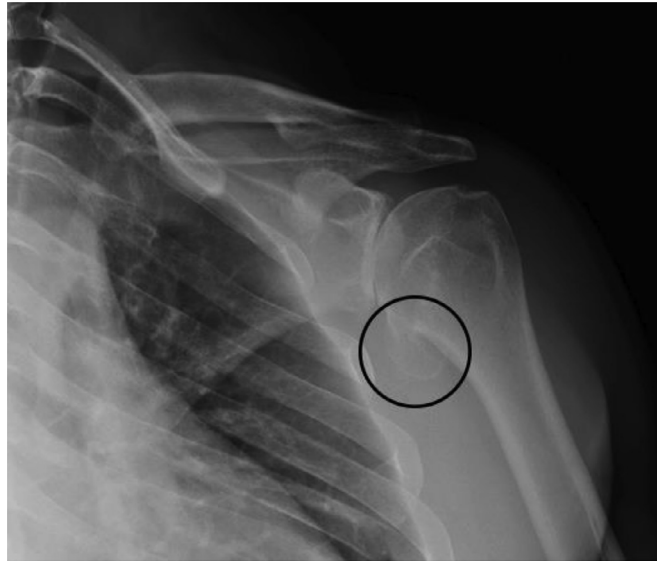


Fig. 1 – A Grashey view of the left shoulder radiograph demonstrates a large inferior osteophyte (black circle).

presented with decreased shoulder range of motion concerning for a rotator cuff tear. Although there were rim rent tears noted of the supra- and infraspinatus tendons, additional atrophy of the teres minor and deltoid muscles was noted on MRI imaging. Evaluation of the quadrilateral space revealed neurovascular impingement by a large osteophyte from the humeral head. While there have been several reported cases of osteophyte-induced QSS, none have displayed radiographic findings of atrophy to this extent [5].

Case presentation

A 41-year-old male presented to his primary care physician with a ten-year history of worsening left anterior shoulder pain and decreased range of motion. A detailed history revealed that the shoulder pain and range of motion deficits had progressed over several years, resulting in significant functional impairment and reduced range of motion in the left upper limb. Furthermore, this patient stated that the shoulder pain will wake him at night if the arm is left unsupported. He denies any past direct trauma to the left upper extremity but shares a history of shoulder dislocations, six-to-seven times, suffered during jiu jitsu training. No dislocations have occurred in the past year. He has no prior left upper extremity surgeries, has not participated in physical therapy in the past and was not currently taking any medications at the time of initial evaluation.

On physical examination, decreased active and passive range of motion in abduction, adduction, internal and external rotation of the left shoulder was appreciated. There was decreased strength on internal rotation, with associated pain and crepitation. Positive empty can and belly press tests were noted on examination. Radiographs and MRI were obtained for further evaluation.

Initial radiographs demonstrated extensive osteoarthritic changes involving the glenohumeral joint with a large inferiorly oriented osteophyte (Fig. 1). Subsequent MRI of the left shoulder demonstrated advanced arthritis of the glenohumeral joint with juxta-articular subcortical cysts and large osteophytes. A large osteophyte from the inferior humeral head was shown impinging on the quadrilateral space and axillary nerve (Figs. 5, 6 and 7) The teres minor muscle was asymmetrically atrophied compared to the other rotator cuff muscles (Figs. 2, 3 and 4). Mild partial insertional rim rent tears of the supraspinatus and infraspinatus were also appreciated (Not shown).

A large osteophyte impinged and narrowed the quadrilateral space through which the axillary nerve traversed. This constellation of findings, in addition to the patient's clinical symptoms and physical exam findings, was most consistent with QSS. This patient was referred to physical therapy by his primary care provider for strength and range of motion training. He was also referred to orthopedic surgery for evaluation and further management. The initial management plan included conservative, symptomatic treatment with continuation of physical therapy and NSAIDs for pain as needed. The option of future surgical intervention aimed at excision of the osteophyte was also discussed if physical therapy rehabilitation failed.

Discussion

QSS more commonly affects younger adults, ages 25-35 with a history of repetitive upper extremity activity and rarely presents as a result of an acute, traumatic injury [6]. Initial presentation is usually vague, requiring a comprehensive history and physical exam. Cahill and Palmer were the first to describe QSS in 1980, describing clinical features of diffuse pain of the shoulder region, paresthesias in a non-

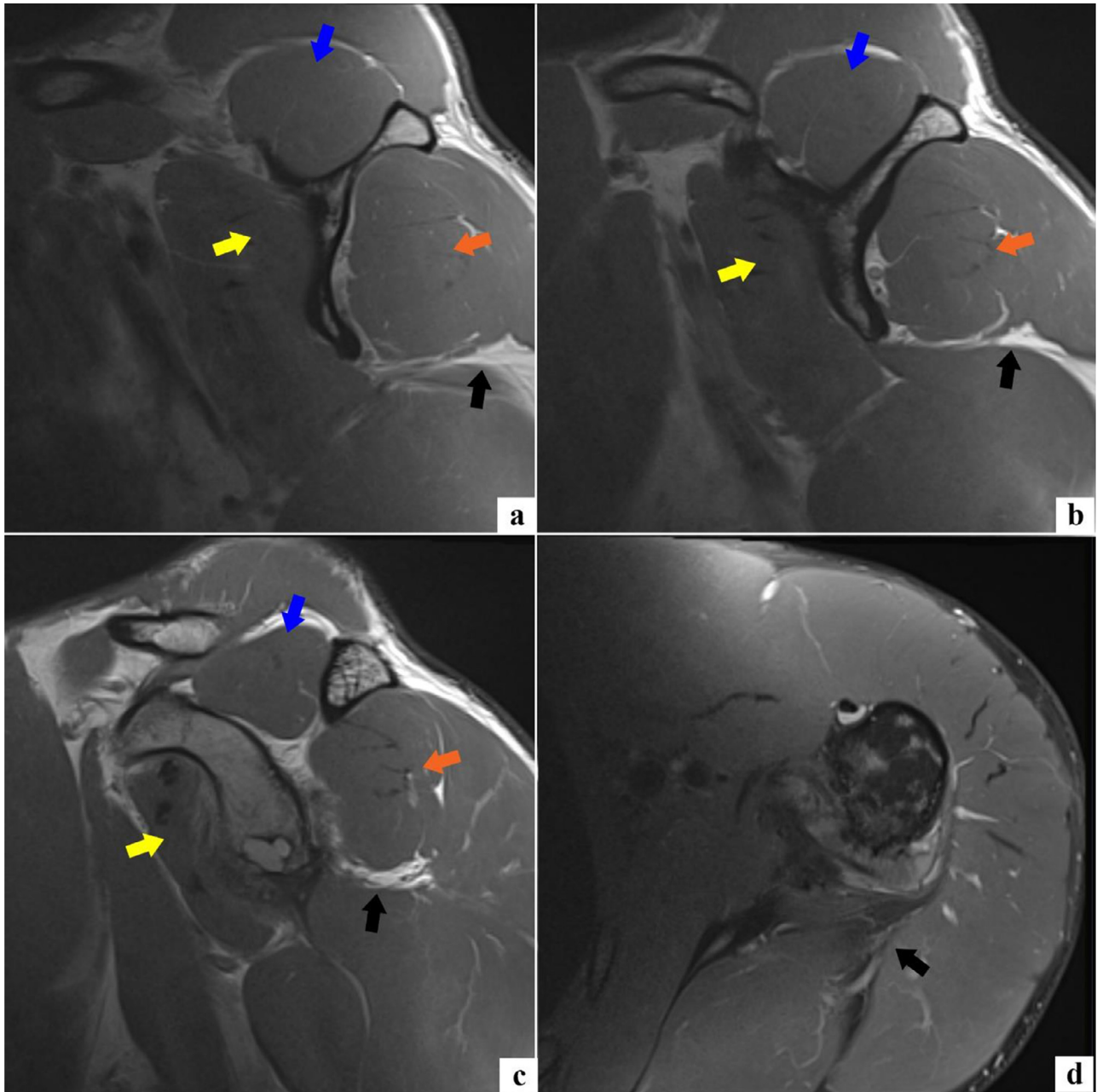


Fig. 2 – Sagittal T1 MRI of the left shoulder at the level of the scapula body (A) with 5mm cuts lateral (B-C) through the scapula body demonstrates marked isolated atrophy of the teres minor muscle (black circle). The infraspinatus (orange arrow), supraspinatus (blue arrow) and subscapularis muscles (yellow arrow) demonstrate normal muscle bulk. An axial T1 fat-saturated image at the level of the inferior aspect of the glenoid and mid-scapular body (D) demonstrates marked fatty atrophy of the teres minor muscle (black arrow). This appears hypointense since the axial sequence was fat-saturated.

dermatomal pattern and point tenderness above the quadrilateral space posteriorly [6]. Cahill's findings are characterized today as features of neurogenic QSS (nQSS). Other features of nQSS include weakness, muscular atrophy and fasciculations [1]. Vascular QSS (vQSS) was later described as a distinct, second etiology of QSS with predominant symptoms of ischemia [1]. Patients with vQSS typically present with a history of poikilothermia, pallor and cyanosis of the involved limb [7]. As seen in this case, the 41-year-old patient presented with

symptoms concerning for axillary nerve compression and nQSS.

The axillary nerve originates from the posterior cord of the brachial plexus which contains nerve roots from C5 and C6. The axillary nerve will initially course posterior and then take a course anterior to the subscapularis muscle. It will then dive inferiorly to the inferolateral border of the subscapularis and enter into the quadrilateral space with the posterior circumflex humeral vessels. The axillary nerve will then run along

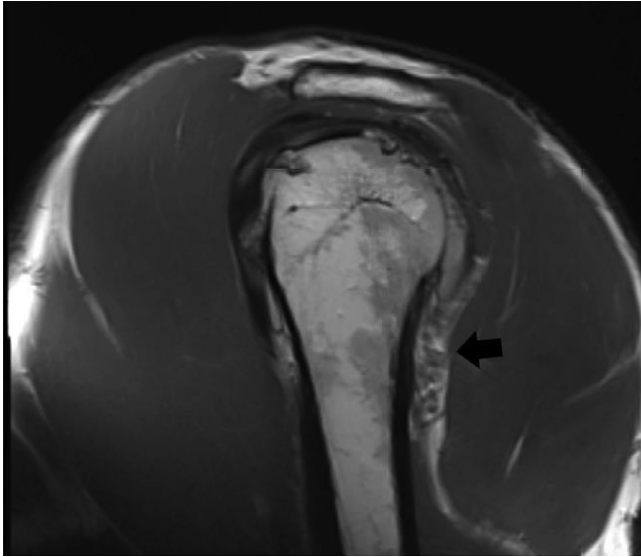


Fig. 3 – Sagittal T1 MRI of the left shoulder at the level of the proximal humerus demonstrates isolated atrophy of the teres minor muscle (black arrow) in relation to the other rotator cuff muscles.

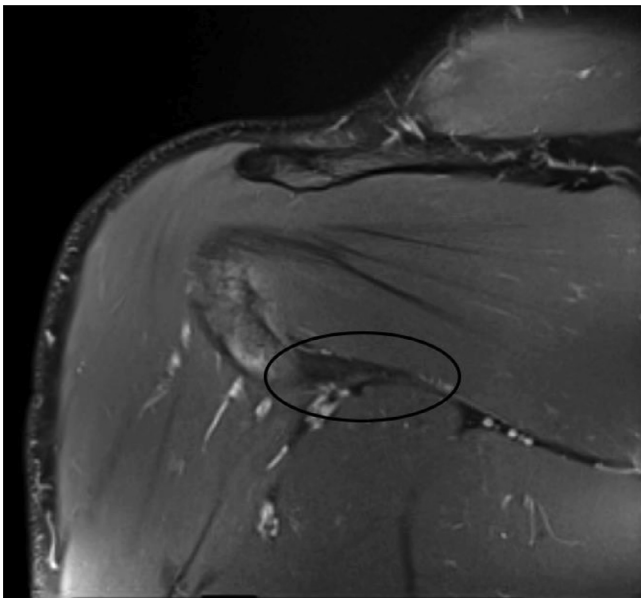


Fig. 4 – Coronal proton density with fat saturation at the level of the posterior cortex of the left humerus demonstrates isolated fatty atrophy of the teres minor muscle (black circle). There is loss of signal on fat saturation confirming fatty atrophy.

the neck of the humerus and divide into anterior and posterior branches (Fig. 8). The anterior branch will provide innervation to the deltoid muscle and the posterior branch will provide sensory supply to the overlying cutaneous tissue, motor supply to the posterior deltoid and motor supply to the teres minor muscle [8]. The course and branches of the axillary nerve

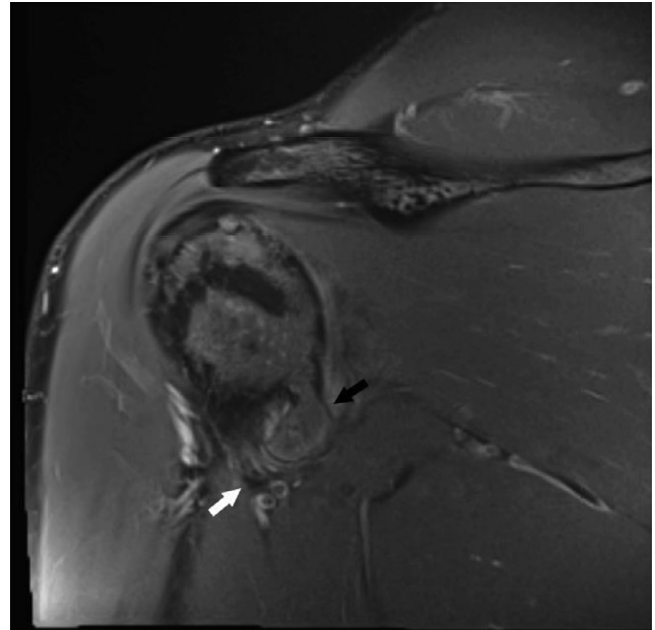


Fig. 5 – Coronal proton density with fat saturation image at the level of the quadrilateral space demonstrates a large osteophyte (black arrow) narrowing the quadrilateral space and exerting mass effect upon the traversing axillary nerve (white arrow).

explain the variable involvement of the deltoid in addition to the teres minor [3,9]. Vascular compromise would subsequently cause neuropathy from ischemia of the nerves and/or supplied muscles.

Literature of QSS has offered a limited understanding of pathophysiology and the various mechanisms of this rare diagnosis [2,3,10]. Compression by fibrotic bands have been more commonly documented in reported cases of QSS, forming as a result of repetitive mechanical trauma, hypertrophy, scarring and adhesion [11–13]. Various other etiologies have been reported with lower incidence. Neurovascular impingement by paralabral cysts, masses, hematomas, fractures and lipomas have all been documented in cases of nQSS [5,14–16]. Mechanical trauma, aneurysms and pseudoaneurysms of the posterior circumflex humeral artery (PHCA) have been documented in cases of vQSS [1]. In rare instances anatomical variations of the vascular supply have also been described in cases of vQSS [11]. The clinical neurovascular symptomatology of QSS is neither sensitive nor specific for diagnosis and must be supported radiologically to exclude more common etiologies of shoulder pain, weakness, paresthesias and decreased range of motion [17,18]. The anatomical relationship between the muscles and bone comprising the quadrilateral space is dynamic. The pathomechanics related to variable anatomy in this region induces compression of the quadrilateral space and axillary nerve. Repetitive activity and mechanics resulting in maximum quadrilateral space compression include abduction (overhead motion) and external rotation. In these positions, this patient's osteophyte, or any sizable lesion, will im-

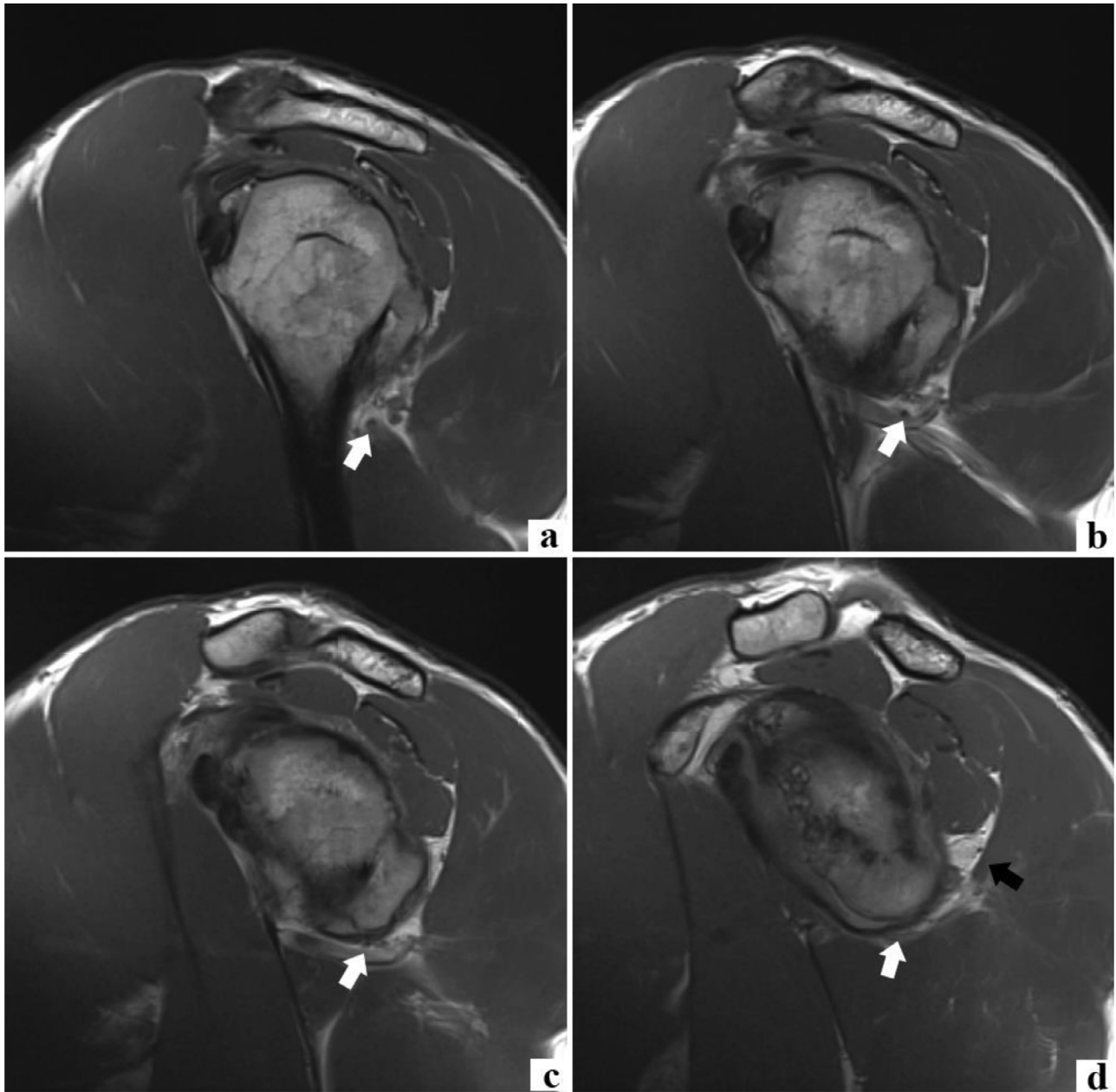


Fig. 6 – A series of T1 MRI sagittal images through the left shoulder going from most lateral at the level of the humeral head (A) to more medial at the level of the glenoid (D) demonstrates the quadrilateral space and axillary nerve (white arrow). The large osteophyte exerts mass effect upon the axillary nerve and narrows the quadrilateral space. Redemonstrated is fatty atrophy of the teres minor muscle (D, black arrow).

pinch upon the quadrilateral space and exacerbate compressive symptoms.

MRI is the standard initial imaging modality in suspected cases of neurogenic QSS. This modality allows for a refined evaluation of soft tissue structural/anatomical defects in addition to localized fatty atrophy of the teres minor. In addition, denervation edema can be demonstrated in early/acute cases, increasing sensitivity [2,18]. The teres minor is difficult to isolate during physical examination testing since the infraspinatus is a more powerful external rotator muscle [3]. MRI findings are most useful when correlated with the patient's clinical

presentation and symptomatology. As seen in this patient, a large osteophyte was identified as the cause of axillary nerve compromise in the quadrilateral space. Osteophytes may form as a result of chronic osteoarthritis, prior trauma or displaced healing of a fracture involving the shoulder girdle [5]. Being able to identify a space-occupying lesion impinging upon the quadrilateral space is unique since the quadrilateral space itself appears normal in most cases of quadrilateral space syndrome [4]. Incidental insertional rim tears of the supraspinatus and infraspinatus were also found, ultimately influencing the clinical course and management.

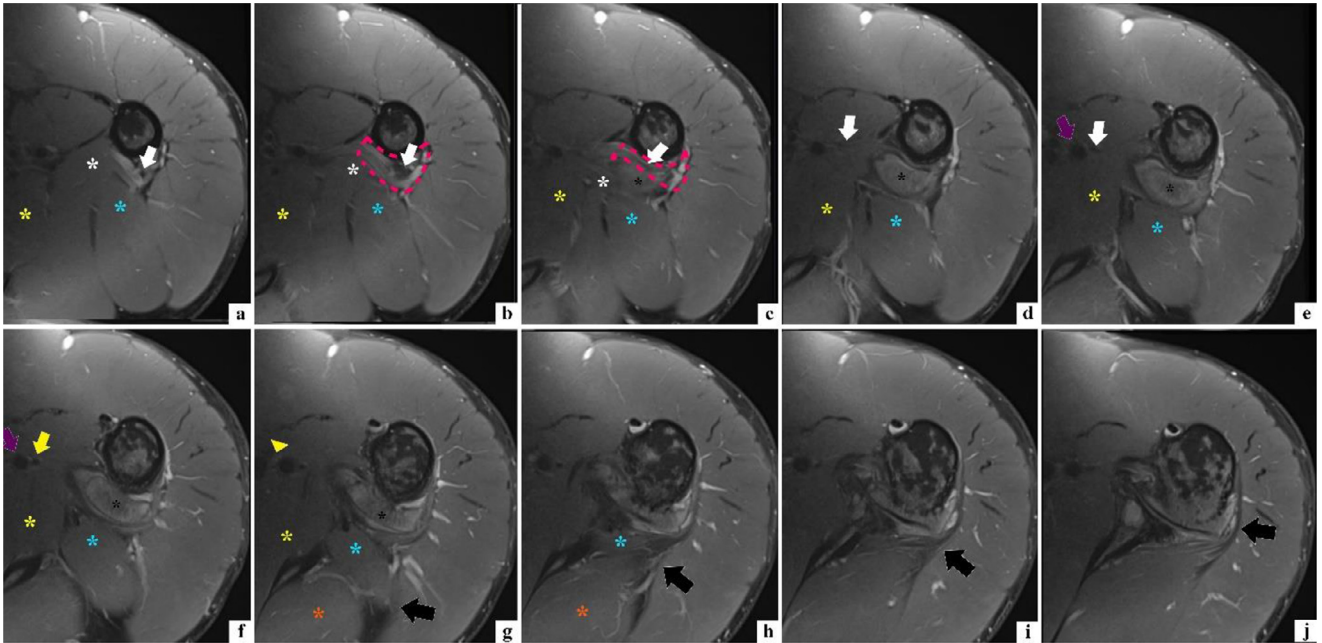


Fig. 7 – A series of axial T1 fat-saturated images are shown starting at the level of the proximal humerus (A) scrolling cranial up to the level of the glenohumeral joint (j). The quadrilateral space is outlined by the pink dotted line (B and C). The axillary nerve (white arrow) is seen within the quadrilateral space (B) with mass effect from the large inferohumeral osteophyte (C). The axillary nerve origin from the brachial plexus is seen (G) denoted by the yellow arrowhead. The axillary artery (purple arrow) is adjacent to the axillary nerve (white arrow) and brachial plexus (yellow arrow head). The musculocutaneous nerve (yellow arrow) is then seen next to the axillary artery (purple arrow) more superiorly. The borders of the quadrilateral space are the proximal humerus, teres major (white asterisk), long head triceps (blue asterisk) and teres minor (black arrow). The teres minor is again noted to be asymmetrically fatty atrophied compared to the other rotator cuff muscles (G-J). Fatty atrophy is hypointense on these T1 fat-saturated images.

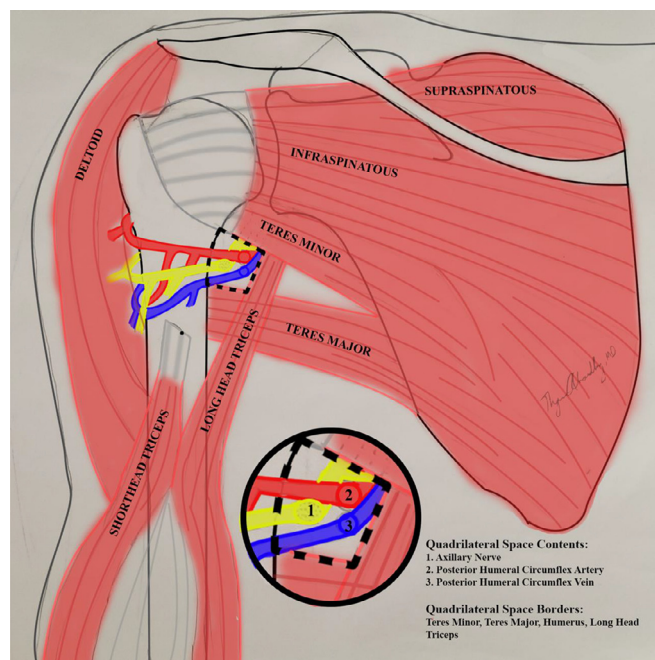


Fig. 8 – Anatomic drawing of the contents and borders of the Quadrilateral space.

In addition to MRI, the use of arteriography, electromyogram (EMG) and ultrasound have also provided supportive evidence in select patients in the diagnosis of QSS [1]. For cases of vascular QSS and concerns of ischemia, subclavian arteriogram or MR angiography have been successfully utilized in detecting lesions of the PHCA. Angiography allows for better visualization of thrombotic and embolic occlusions of the PHCA and its distal branches [7]. Several cases utilizing EMG have documented decreased amplitude along the axillary nerve, but the low sensitivity of EMG limits its diagnostic capabilities [4]. Ultrasound has not been studied in QSS like MRI, MR angiography or EMG, but does provide a cheaper and quick visualization of flow through the PHCA when using doppler [19].

Idiopathic teres minor atrophy, Parsonage-Turner syndrome and rotator cuff tearing are additional differential considerations. Idiopathic teres minor atrophy is often due to compression of the teres minor branches of the axillary nerve. No distinct source of impingement is identified on imaging. This is more common than quadrilateral space syndrome and will present in older patients of 50-70 years-of-age in contrast to patients with quadrilateral space syndrome usually presenting in younger patients of 25-35 years-of-age [1,4,10]. Parsonage-Turner syndrome is an acute idiopathic neuritis involving the brachial nerves. Although exact etiology is unknown, a viral origin is suspected. The most common involved nerve is the suprascapular nerve which innervates both the supra- and infra-spinatus muscles. There can also be involvement of the subscapular and axillary nerves. Involvement of other muscles would be suspected for a Parsonage-Turner syndrome to be considered more likely [20]. In addition, MRI findings would demonstrate acute denervation changes with hyperintensity on T2 and PD weighted imaging in the acute setting [20]. Rotator cuff tearing would be another differential consideration in the context of rotator cuff atrophy. However, one would expect to see muscle belly retraction, tendinosis and at least high-grade parietal to full thickness tearing of the involved muscle tendon. In this case, the teres minor tendon was intact. Other impingement syndromes such as spinoglenoid and suprascapular notch impingement syndromes would not be considered with findings of teres minor and deltoid muscle atrophy. Spinoglenoid notch syndrome results from impingement of the infraspinatus nerve as it passes through the spinoglenoid notch to innervate the infraspinatus muscle. Suprascapular notch syndrome results from impingement of the suprascapular nerve as it traverses over the suprascapular notch to innervate the supra- and infraspinatus muscles.

Although treatment and management modalities are dependent on the etiology of the impingement, the majority of patients with QSS will begin with conservative treatment, which includes physical therapy and pain control [2]. The most common etiology consists of fibrous bands which would benefit from surgical excision if conservative treatment fails. Any space-occupying lesion such as a paralabral cyst (the second most common), vascular lesion, mass-lesion (hematoma, lipoma, etc) or fracture would necessitate surgical excision or vascular treatment if conservative treatment failed [2].

Conclusion

Quadrilateral space syndrome is an uncommon, yet important diagnosis that must be considered when both clinically and radiographically evaluating an at-risk patient presenting with vague shoulder pain. While MRI findings of teres minor atrophy are helpful in establishing the initial suspicion for diagnosis, a radiologist must always diligently review all aspects of the study to ensure no soft tissue, bony or neurovascular findings were missed. High quality interpretation correlates with high quality outcomes, ensuring the best patient care and an earlier return to functional capacity following treatment of QSS. Early evaluation, investigation and intervention of this patient's shoulder pain could have altered the course of functional decline secondary to this degenerative osteophyte.

Patient consent statement

Unable to reach patient to obtain consent. All HIPPA/PHI removed.

REFERENCES

- [1] Brown SAN, Doolittle DA, Bohanon CJ, et al. Quadrilateral space syndrome: the mayo clinic experience with a new classification system and case series. *Mayo Clin Proc* 2015 Published online. doi:10.1016/j.mayocp.2014.12.012.
- [2] Cothran RL, Helms C. Quadrilateral space syndrome: incidence of imaging findings in a population referred for MRI of the shoulder. *Am J Roentgenol* 2005 Published online. doi:10.2214/ajr.184.3.01840989.
- [3] Linker CS, Helms CA, Fritz RC. Quadrilateral space syndrome: Findings at MR imaging. *Radiology* 1993 Published online. doi:10.1148/radiology.188.3.8351331.
- [4] Hong CC, Thambiah MD, Manohara R. Quadrilateral space syndrome: the forgotten differential. *J Orthop Surg* Published online 2019. doi:10.1177/2309499019847145
- [5] Millett PJ, Schoenahl JY, Allen MJ, Motta T, Gaskill TR. An association between the inferior humeral head osteophyte and teres minor fatty infiltration: evidence for axillary nerve entrapment in glenohumeral osteoarthritis. *J Shoulder Elb Surg* 2013 Published online. doi:10.1016/j.jse.2012.05.030.
- [6] Cahill BR, Palmer RE. Quadrilateral space syndrome. *J Hand Surg Am* 1983. Published online. doi:10.1016/S0363-5023(83)80056-2.
- [7] Mochizuki T, Isoda H, Masui T, Ohkawa Y, Takahashi M, Ichijo K, et al. Occlusion of the posterior humeral circumflex artery: detection with MR angiography in healthy volunteers and in a patient with quadrilateral space syndrome. *Am J Roentgenol* 1994. Published online. doi:10.2214/ajr.163.3.8079857.
- [8] Loomer R, Graham B. Anatomy of the axillary nerve and its relation to inferior capsular shift. *Clin Orthop Relat Res* 1989 Published online. doi:10.1097/00003086-198906000-00015.
- [9] Apaydin N, Tubbs RS, Loukas M, Duparc F. Review of the surgical anatomy of the axillary nerve and the anatomic basis of its iatrogenic and traumatic injury. *Surg Radiol Anat* 2010 Published online. doi:10.1007/s00276-009-0594-8.

- [10] Friend J, Francis S, McCulloch J, Ecker J, Bredahl W, McMenamin P. Teres minor innervation in the context of isolated muscle atrophy. *Surg Radiol Anat* 2010 Published online. doi:[10.1007/s00276-009-0605-9](https://doi.org/10.1007/s00276-009-0605-9).
- [11] McClelland D, Paxinos A. The anatomy of the quadrilateral space with reference to quadrilateral space syndrome. *J Shoulder Elb Surg* 2008 Published online. doi:[10.1016/j.jse.2007.05.013](https://doi.org/10.1016/j.jse.2007.05.013).
- [12] Francel TJ, Dellon AL, Campbell JN. Quadrilateral space syndrome: diagnosis and operative decompression technique. *Plast Reconstr Surg* 1991 Published online. doi:[10.1097/00006534-199105000-00016](https://doi.org/10.1097/00006534-199105000-00016).
- [13] McKowen HC, Voorhies RM. Axillary nerve entrapment in the quadrilateral space. Case report. *J Neurosurg* 1987 Published online. doi:[10.3171/jns.1987.66.6.0932](https://doi.org/10.3171/jns.1987.66.6.0932).
- [14] Sanders TG, Tirman PFJ. Paralabral cyst: an unusual cause of quadrilateral space syndrome. *Arthrosc - J Arthrosc Relat Surg* 1999 Published online. doi:[10.1053/ar.1999.v15.015063](https://doi.org/10.1053/ar.1999.v15.015063).
- [15] Amin MF, Berst M, el-Khoury GY. An unusual cause of the quadrilateral space impingement syndrome by a bone spike. *Skeletal Radiol* 2006 Published online. doi:[10.1007/s00256-006-0092-6](https://doi.org/10.1007/s00256-006-0092-6).
- [16] Cirpar M, Gudemez E, Cetik O, Uslu M, Eksioğlu F. Quadrilateral space syndrome caused by a humeral osteochondroma: a case report and review of literature. *HSS J* 2006 Published online. doi:[10.1007/s11420-006-9019-y](https://doi.org/10.1007/s11420-006-9019-y).
- [17] Cormier PJ, Matalon TAS, Wolin PM. Quadrilateral space syndrome: a rare cause of shoulder pain. *Radiology* 1988 Published online. doi:[10.1148/radiology.167.3.3363143](https://doi.org/10.1148/radiology.167.3.3363143).
- [18] Zurkiya O, Walker TG. Quadrilateral space syndrome. *J Vasc Interv Radiol* 2014;25(2):229. doi:[10.1016/j.jvir.2013.10.016](https://doi.org/10.1016/j.jvir.2013.10.016).
- [19] Brestas PS, Tsouroulas M, Nikolakopoulou Z, Malagari K, Drossos C. Ultrasound findings of teres minor denervation in suspected quadrilateral space syndrome. *J Clin Ultrasound* 2006 Published online. doi:[10.1002/jcu.20239](https://doi.org/10.1002/jcu.20239).
- [20] Scalf RE, Wenger DE, Frick MA, Mandrekar JN, Adkins MC. MRI findings of 26 patients with Parsonage-Turner syndrome. *Am J Roentgenol* 2007 Published online. doi:[10.2214/AJR.06.1136](https://doi.org/10.2214/AJR.06.1136).