

doi:10.3969/j.issn.1673-5374.2013.27.006 [http://www.nrronline.org; http://www.sjzsyj.org]

Zhong JM, Wu SY, Zhao Y, Chen H, Zhao NW, Zheng KW, Zhao Z, Chen WL, Wang B, Wu KH. Why psychosis is frequently associated with Parkinson's disease? *Neural Regen Res.* 2013;8(27):2548-2556.

Why psychosis is frequently associated with Parkinson's disease?

Jingmei Zhong¹, Shaoyuan Wu¹, Ying Zhao², Hui Chen¹, Naiwei Zhao¹, Kunwen Zheng¹, Zhong Zhao¹, Wenli Chen¹, Bo Wang², Kunhua Wu²

¹ Department of Neurology, First People's Hospital of Yunnan Province, Kunming 650032, Yunnan Province, China

² Department of Magnetic Resonance Imaging, First People's Hospital of Yunnan Province, Kunming 650032, Yunnan Province, China

Research Highlights

(1) Diffusion tensor imaging was used to explain the occurrence of psychosis associated with Parkinson's disease. Psychosis was associated with an imbalance in the ratio of white-matter fibers in psychosis-related brain regions to those in parts of the extrapyramidal motor system.

(2) The present study had some technical innovations. First, fractional anisotropy ratios between several brain regions were used to overcome the effects of brain volume on voxel acquisition. Thus, the relative degree of white-matter fiber injury in several brain regions could be compared well across patients.

(3) During voxel acquisition, the layer and voxel size were kept constant in each patient. Voxel shape was designed and varied across several brain regions, increasing the accuracy of fractional anisotropy. Moreover, a three-dimensional volumetric rendering technique was used for positioning, increasing the accuracy of positioning.

Abstract

Psychosis is a common non-motor symptom of Parkinson's disease whose pathogenesis remains poorly understood. Parkinson's disease in conjunction with psychosis has been shown to induce injury to extracortical tracts as well as within some cortical areas. In this study, Parkinson's disease patients with psychosis who did not receive antipsychotic treatment and those without psychosis underwent diffusion tensor imaging. Results revealed that in Parkinson's disease patients with psychosis, damage to the left frontal lobe, bilateral occipital lobe, left cingulate gyrus, and left hippocampal white-matter fibers were greater than damage to the substantia nigra or the globus pallidus. Damage to white-matter fibers in the right frontal lobe and right cingulate gyrus were also more severe than in the globus pallidus, but not the substantia nigra. Damage to frontal lobe and cingulate gyrus white-matter fibers was more apparent than that to occipital or hippocampal fiber damage. Compared with Parkinson's disease patients without psychosis, those with psychosis had significantly lower fractional anisotropy ratios of left frontal lobe, bilateral occipital lobe, left cingulate gyrus, and left hippocampus to ipsilateral substantia nigra or globus pallidus, indicating more severe damage to white-matter fibers. These results suggest that psychosis associated with Parkinson's disease is probably associated with an imbalance in the ratio of white-matter fibers between brain regions associated with psychiatric symptoms (frontal lobe, occipital lobe, cingulate gyrus, and hippocampus) and those associated with the motor symptoms of Parkinson's disease (the substantia nigra and globus pallidus). The relatively greater damage to white-matter fibers in psychiatric symptom-related brain regions than in extracortical tracts might explain why psychosis often occurs in Parkinson's disease patients.

Key Words

neural regeneration; brain injury; Parkinson's disease; psychosis; diffusion tensor imaging; fractional anisotropy; functional magnetic resonance; frontal lobe; occipital lobe; cingulate gyrus; hippocampus; extracortical tract; grants-supported paper; neuroregeneration

Jingmei Zhong, Master, Associate chief physician.

Corresponding author: Shaoyuan Wu, Chief physician, Department of Neurology, First People's Hospital of Yunnan Province, Kunming 650032, Yunnan Province, China, wu.shaoyuan@yahoo.com.cn.

Received: 2013-04-07

Accepted: 2013-07-23

(N20121108004)

Funding: This study was supported by the Applied Basic Research Foundation of Yunnan Province in China, No. 2009CD193.

Author contributions: Zhong JM was in charge of the study design and concept, provided data, ensured the integrity of the data, and wrote the manuscript. Wu SY obtained the funding, worked as a principal investigator, contributed to the study concept and design, provided data, and was in charge of manuscript authorization. Zhao Y was responsible for data collection and analysis. Chen H, Zhao NW, Zheng KW, and Chen WL provided data. Zhao Z was in charge of study design. Wang B and Wu KH provided technical support. All authors approved the final version of the paper.

Conflicts of interest: None declared.

Ethical approval: This study was approved by the Ethics Committee, First People's Hospital of Yunnan Province, China.

Author statements: The manuscript is original, has not been submitted to or is not under consideration by another publication, has not been previously published in any language or any form, including electronic, and contains no disclosure of confidential information or authorship/patent application/funding source disputations.

INTRODUCTION

Psychosis is a common non-motor symptom of Parkinson's disease^[1], and the combination of the two is listed separately in the Chinese Classification of Mental Disorders-3 as psychosis in Parkinson's disease (coded as 02.13)^[2]. Diagnostic criteria have been formulated by the National Institute of Neurological Disorders and Stroke and The National Institute of Mental Health on the basis of Diagnostic and Statistical Manual of Mental Disorder IV^[3]. Patients with psychosis in Parkinson's disease not only suffer from hypokinesia, tremor, and rigor, they also experience hallucinations and incongruous psychomotor excitation^[4-5]. These symptoms are associated with abnormalities in dopamine neuronal pathways^[6-7].

Parkinson's disease and schizophrenia are mediated by dopamine and are considered to result from neural circuit abnormalities^[1, 8-11]. The dopamine system includes the midbrain, mesolimbic, nigrostriatal, and tuberoinfundibular systems. Parkinson's disease is primarily associated with abnormalities in the nigrostriatal system^[12-13], while psychiatric symptoms are primarily associated with abnormalities in the midbrain and mesolimbic systems^[14-16]. The pathophysiological mechanism for Parkinson's disease is the degeneration and necrosis of neurons within the midbrain substantia nigra, which reduces the amount of dopamine in the nigrostriatal pathway and induces an imbalance of dopamine and acetylcholine in the corpus striatum^[17-20]. An imbalance in thalamocortical projection neurotransmitters causes hypokinesia and rigor, which is associated with disordered gait and posture^[21-22]. Previous studies have shown that psychiatric symptoms might be associated with increased levels of dopamine, increased density of D2 receptors, and hyperfunction of the substantia nigra and corpus striatum^[23-24]. Studies of neurological function have demonstrated that the temporal lobe, occipital lobe, limbic system, and frontal association areas are linked to psychosis^[25-26]. Injury to Brodmann areas 9 and 10 has been associated with cognitive

disorders, lack of insight, behavior disorders, over-excitation, lack of impulse control, and attacking behavior^[27-28]. Additionally, injury to Brodmann areas 18 and 19 has been associated with visual hallucinations^[27-28]. Injury to the limbic system, including the hippocampus, amygdala, and cingulate gyrus, has been associated with behavior disorders and emotional alterations^[27-28]. Therefore, Parkinson's disease with psychosis should be associated with the extrapyramidal motor system, frontal cortex, occipital cortex, and limbic systems. To understand the mechanism by which Parkinson's disease and psychosis co-occur, this study selected the substantia nigra, globus pallidus, frontal lobe, occipital lobe, and occipital lobe, cingulate gyrus, and hippocampus as research areas.

Diffusion tensor imaging is a functional nuclear magnetic resonance technique that can evaluate tissue integrity using water molecule diffusion anisotropy in directional tissue^[29-30]. Water molecule diffusion is identical in uniform homogenous tissues such as gray matter and cerebrospinal fluid, showing isotropy. However, diffusion of water molecules vertical to the direction of white-matter fibers is affected by the distribution and compactness of nerve-fiber bundles and the thickness of myelin sheaths. Diffusion under these conditions is markedly slower than diffusion along the direction of fibers, thus showing anisotropy. The degree of anisotropy is commonly determined by fractional anisotropy. Fractional anisotropy is measured by calculating diffusion tensor using diffusion tensor imaging. High fractional anisotropy shows uniform fiber distribution, tight arrangement, and normal myelin sheaths. Reduced fractional anisotropy indicates that the fine structure of fibers is damaged. Extracortical regions such as the substantia nigra, red nucleus, thalamus, lenticular nucleus, and caudate nucleus are important areas to consider when studying Parkinson's disease using diffusion tensor imaging^[31-36]. Fractional anisotropy in Parkinson's disease patients has been demonstrated to be lower in the substantia nigra and globus pallidus compared with healthy individuals^[31-36]. Similarly, the frontal

lobe, occipital lobe, cingulate gyrus, thalamus, and hippocampus are important areas to consider when studying psychosis using diffusion tensor imaging^[37-43]. White-matter tracts in the frontal lobe, occipital lobe, and cingulate gyrus have been reported to be reduced to varying degrees in several psychoses^[37-43]. While T1-weighted images are commonly used to position the structures in diffusion tensor imaging^[44], three-dimensional volumetric rendering techniques are also used^[45]. As no study has used diffusion tensor imaging to investigate psychosis in Parkinson's disease, we used diffusion tensor imaging to determine whether the degree of white-matter fiber injury in brain regions associated with psychiatric symptoms is different from that which occurs in the extrapyramidal motor system.

The methods for studying the pathogenesis of psychosis associated with Parkinson's disease included autopsy^[20], electrophysiology^[46], single-photon emission computed tomography^[47-48], and T2 weighted MRI^[49]. The occurrence of psychosis in Parkinson's disease patients has been associated with imbalances in dopamine, serotonin, and acetylcholine levels^[20, 50-51], and the affected regions are primarily the midbrain and cortex^[23-24]. Hallucination has been associated with increased activity of dopamine in the limbic lobe^[16]. Birkmayer and Hornykiewicz^[20] confirmed that cholinergic cell loss and imbalances in serotonergic and cholinergic transmitters occur in temporal and parietal cortices in Parkinson's disease patients with psychosis. Diederich and colleagues^[46] found that visually evoked potentials are prolonged in Parkinson's disease patients who experience visual hallucinations. While electrical activity in the frontal lobes of patients with psychosis in Parkinson's disease was relatively greater than that in Parkinson's patients without psychosis, activity in occipital cortex was relatively less. Oyishi and colleagues^[47] verified that visual hallucinations experienced by Parkinson's disease patients are associated with hypoperfusion of the right medial occipitotemporal gyrus and hypertransfusion of the superior temporal gyrus and inferior temporal gyrus. Regional cerebral blood flow has been shown to be less in the frontal lobes of patients with psychosis in Parkinson's disease, and to increase after electric shock therapy^[48]. An MRI study revealed that the occurrence of visual hallucinations was associated with injury to occipital cortex white matter^[49]. Here, we conjectured that the occurrence of psychosis in Parkinson's disease patients is associated with clear damage to psychiatric symptom-related brain regions, and used diffusion tensor imaging to determine whether it was associated with an imbalance in the ratio of white matter fibers in these regions to those in parts of the extrapyramidal motor system.

This study used diffusion tensor imaging to measure the fractional anisotropy in frontal cortex (Brodmann areas 9 and 10), occipital cortex (Brodmann areas 18 and 19), cingulate gyrus, hippocampus, substantia nigra, and globus pallidus. A three-dimensional volumetric rendering technique was employed for positioning. The frontal cortex, occipital cortex, cingulate gyrus, and hippocampus were considered regions of interest related to psychiatric symptoms^[52], and the substantia nigra and globus pallidus were considered regions of interest related to Parkinson's disease^[53]. The relative degree of white-matter fiber injury was determined by calculating the ratio of fractional anisotropy between the two brain-region groups. This ratio was then compared between Parkinson's disease patients with and without psychosis.

RESULTS

Quantitative analysis of subjects

Of 66 Parkinson's disease patients, 18 patients with psychosis who did not receive antipsychotic treatment comprised the Parkinson's disease with psychosis group. The remaining 48 patients without psychosis comprised the Parkinson's disease without psychosis group. Data from all subjects were used in the final analyses.

Baseline analysis of subjects

There was no significant difference in age or gender between the two groups. The course of disease was longer in Parkinson's disease patients with psychosis than in those without ($P < 0.01$; Table 1).

Table 1 Baseline analysis of subjects

Group	<i>n</i>	Gender (male/female)	Age (year)	Course (year)
Parkinson's disease				
With psychosis	18	11(61)/7(39)	56.3±23.7	4.8±2.8 ^a
Without psychosis	48	29(60)/19(40)	55.6±22.3	3.0±2.3
<i>t</i> / χ^2		0.054	0.110	2.797
<i>P</i>		0.817	0.913	0.007

No significant difference in age or gender was detected between the two groups (chi-square test). The course of disease was longer in the Parkinson's disease with psychosis group than in the Parkinson's disease without psychosis group (^a $P < 0.01$; two-sample *t*-test). Age and Course are expressed as mean ± SD and gender as *n*(%).

Ratio of fractional anisotropy in psychosis-related brain regions to that in the substantia nigra of Parkinson's disease patients with and without psychosis

Diffusion tensor imaging shows that the ratios of fractional anisotropy in the left frontal lobe, bilateral occipital

lobe, left cingulate gyrus, and left hippocampus to that in the ipsilateral substantia nigra were significantly lower in Parkinson's disease patients with psychosis than in those without ($P < 0.05$ or $P < 0.01$), indicating that the degree of white-matter fiber injury was relatively higher in these psychosis-related regions compared with that in the substantia nigra in Parkinson's disease patients with psychosis (Table 2).

Ratio of fractional anisotropy in psychosis-related brain regions to that in the globus pallidus of Parkinson's disease patients with and without psychosis

The ratio of fractional anisotropy in bilateral frontal lobe (areas 9 and 10), occipital lobe (areas 18 and 19), cingulate gyrus, and left hippocampus to that in ipsilateral globus pallidus was significantly lower in Parkinson's disease patients with psychosis than in those without ($P < 0.01$), indicating that the degree of white-matter fiber injury was more severe in these psychosis-related regions than in the globus pallidus (Table 3).

Comparison of fractional anisotropy in the substantia nigra and globus pallidus between Parkinson's disease patients with and without psychosis

Fractional anisotropy in the substantia nigra and globus pallidus did not significantly differ between the two

groups ($P > 0.05$; Table 4).

Comparison of fractional anisotropy in the psychiatric symptoms-related brain regions between Parkinson's disease patients with and without psychosis

Fractional anisotropy of the frontal lobe, occipital lobe, cingulate gyrus, and left hippocampus was significantly lower in patients with psychosis than in those without ($P < 0.01$ or $P < 0.05$; Table 5). Fractional anisotropy of the right hippocampus did not differ between the two groups.

DISCUSSION

Diffusion tensor imaging is a functional nuclear magnetic resonance technique that can evaluate tissue integrity using water molecule diffusion anisotropy in directional tissue^[29-30]. Fractional anisotropy measured by diffusion tensor imaging reflects the degree of fiber injury. A previous study using diffusion tensor imaging demonstrated that while depression associated with Parkinson's disease was associated with reduced numbers of amygdala-related white-matter fibers^[54], dementia associated with Parkinson's disease was primarily associated with reduced numbers of white matter in the temporal lobe and hippocampus^[55].

Table 2 Comparison of the ratio of fractional anisotropy between psychiatric symptoms-related brain regions and the substantia nigra in Parkinson's disease patients with and without psychosis

Group	n	Frontal lobe		Occipital lobe		Cingulate gyrus		Hippocampus	
		Right	Left	Right	Left	Right	Left	Right	Left
Parkinson's disease with psychosis	18	0.45±0.12	0.35±0.11	0.63±0.16	0.55±0.14	0.63±0.15	0.55±0.17	0.24±0.11	0.26±0.13
Parkinson's disease without psychosis	48	0.50±0.14	0.70±0.12	0.72±0.14	0.83±0.14	0.65±0.17	0.75±0.15	0.25±0.12	0.45±0.12
t		1.343	10.811	2.244	7.256	0.440	4.667	0.309	5.619
P		0.184	0.000	0.028	0.000	0.662	0.000	0.758	0.000

The ratio of fractional anisotropy found in the left frontal lobe, bilateral occipital lobe, left cingulate gyrus, and left hippocampus to that in the ipsilateral substantia nigra was significantly less in the Parkinson's disease with psychosis group than in the Parkinson's disease without psychosis group ($P < 0.05$ or $P < 0.01$; mean ± SD; two-sample t-test).

Table 3 Comparison of the ratio of fractional anisotropy between psychiatric symptoms-related brain regions and the globus pallidus in Parkinson's disease patients with and without psychosis

Group	n	Frontal lobe		Occipital lobe		Cingulate gyrus		Hippocampus	
		Right	Left	Right	Left	Right	Left	Right	Left
Parkinson's disease with psychosis	18	0.60±0.16	0.55±0.15	0.75±0.17	0.70±0.16	0.85±0.16	0.80±0.15	0.45±0.12	0.38±0.13
Parkinson's disease without psychosis	48	0.85±0.17	0.90±0.18	1.21±0.19	1.02±0.16	1.10±0.19	1.04±0.18	0.45±0.14	0.56±0.14
t		5.417	7.355	9.023	7.256	4.967	5.043	0.000	4.751
P		0.000	0.000	0.000	0.000	0.000	0.000	1.000	0.000

The ratio of fractional anisotropy found in bilateral frontal lobe, occipital lobe, cingulate gyrus, and left hippocampus, to that in the ipsilateral globus pallidus was significantly less in the Parkinson's disease with psychosis group than in the Parkinson's disease without psychosis group ($P < 0.01$; mean ± SD; two-sample t-test).

Table 4 Comparison of fractional anisotropy in the substantia nigra and globus pallidus of Parkinson's disease patients with and without psychosis

Group	n	Substantia nigra		Globus pallidus	
		Right	Left	Right	Left
Parkinson's disease					
With psychosis	18	0.61±0.06	0.67±0.07	0.44±0.06	0.44±0.15
Without psychosis	48	0.63±0.07	0.64±0.08	0.47±0.09	0.41±0.08
t		1.072	1.401	1.306	1.050
P		0.288	0.166	0.196	0.297

No significant difference in fractional anisotropy was detected in the substantia nigra or the globus pallidus between the two groups (two-sample t-test).

Our results confirmed that compared with Parkinson's disease patients without psychosis, those with psychosis suffered greater white-matter fiber damage in the left frontal lobe, bilateral occipital lobe, left cingulate gyrus, and left hippocampus than in either the substantia nigra or the globus pallidus. Additionally, for these patients, damage to white-matter fibers in the right frontal cortex and right cingulate gyrus was also more severe than in the globus pallidus, but not the substantia nigra. No significant difference in fractional anisotropy of the substantia nigra or globus pallidus was detected between Parkinson's disease patients with and without psychosis. However, fractional anisotropy of the frontal lobe, occipital lobe, cingulate gyrus, and left hippocampus was lower in Parkinson's disease patients with psychosis than in those without. These results indicate that the degree of white-matter fiber injury was more severe in psychiatric symptom-related brain regions than in the basal ganglia or midbrain, and could be the basis for psychosis in Parkinson's disease patients. The injuries to both the extrapyramidal motor system and psychiatric symptom-related brain regions should be associated with the long course of Parkinson's disease^[56] and extensive

neuronal damage induced by antiparkinsonian drugs^[57]. This is consistent with experimental data demonstrating that the course of disease in Parkinson's disease patients with psychosis is relatively long compared with those without psychosis. Results from the present study showed that compared with Parkinson's disease patients without psychosis, those with psychosis showed greater damage to white-matter fibers in the occipital lobe, left hippocampus, most regions of the frontal lobe and cingulate gyrus, but not the right hippocampus. The greater damage to white matter fibers was more apparent in frontal cortex and the cingulate gyrus than in occipital or left hippocampal regions. These phenomena were probably associated with visual hallucinations suffered by patients with psychosis in Parkinson's disease^[3]. Indeed, experimental data revealed that 12 patients (67%) with psychosis in Parkinson's disease also suffered from visual hallucinations. Occipital lobe abnormality is a major cause underlying visual hallucinations. Frontal lobe and cingulate cortex were associated with behavior disorders^[28]. Experimental data showed that eight patients (44%) with psychosis associated with Parkinson's disease experienced behavior disorders.

Similar to previous studies, this study used diffusion tensor imaging to investigate Parkinson's disease and psychosis. However, the present study employed several technical innovations. First, measuring the fractional anisotropy ratios of several brain regions was used to overcome the effects of brain volume on voxel acquisition. Thus, the relative degree of white-matter fiber injury in these brain regions could be compared well across patients. In addition, during voxel acquisition, the layer and voxel size were kept constant in each patient. Voxel shape was designed and varied across brain regions, increasing the accuracy of fractional anisotropy. Moreover, a three-dimensional volumetric rendering technique was also used for positioning, increasing the accuracy of positioning.

Table 5 Comparison of fractional anisotropy in the psychiatric symptoms-related brain regions in Parkinson's disease patients with and without psychosis

Group	n	Frontal lobe		Occipital lobe		Cingulate gyrus		Hippocampus	
		Right	Left	Right	Left	Right	Left	Right	Left
Parkinson's disease with psychosis	18	0.26±0.03	0.25±0.12	0.38±0.29	0.32±0.16	0.36±0.01	0.38±0.02	0.19±0.07	0.18±0.07
Parkinson's disease without psychosis	48	0.41±0.09	0.49±0.09	0.49±0.05	0.48±0.07	0.48±0.05	0.45±0.09	0.20±0.06	0.22±0.05
t		6.900	8.784	2.560	5.677	10.060	3.255	0.576	2.584
P		0.000	0.000	0.013	0.000	0.000	0.002	0.567	0.012

Fractional anisotropy of the frontal lobe, occipital lobe, cingulate gyrus, and left hippocampus was significantly less in the Parkinson's disease with psychosis group than in the Parkinson's disease without psychosis group ($P < 0.05$ or $P < 0.01$; mean ± SD; two-sample t-test).

Using fractional anisotropy ratios of several brain regions, diffusion tensor imaging can be used to observe the relative degree of injury in brain regions associated with mental diseases, information that is valuable in the clinic and in scientific research.

SUBJECTS AND METHODS

Design

A retrospective case analysis.

Time and setting

Experiments were performed at the Department of Neurology and Department of Magnetic Resonance Imaging, First People's Hospital of Yunnan Province in China from March 2010 to April 2012.

Subjects

Parkinson's disease patients from the resident Han population in Yunnan Province underwent diffusion tensor imaging. Of them, 18 patients had psychosis in Parkinson's disease, and did not receive antipsychotic treatment. Of these 18 patients, 12 (67%) had visual hallucinations, eight (44%) suffered from agitation, poor impulse control, and attacking behavior, and one (6%) suffered from thought disturbance. Mini-Mental State Examination showed that nine patients (50%) had cognitive dysfunction (above mild). Of the remaining 48 Parkinson's disease patients without psychosis, 20 patients (42%) had cognitive dysfunction (above mild) measured by the Mini-Mental State Examination^[58].

In accordance with *Administrative Regulations on Medical Institutions*, formulated by the State Council of China^[59], the purpose, scheme, and risks were explained to the patients before the experiment, and they then gave their signed consent.

Inclusion criteria for the Parkinson's disease with psychosis group

- (1) Have at least one of the following characteristic symptoms: perceptual errors, hallucinations, or delusions.
- (2) Meet the UK Brain Bank criteria for Parkinson's disease^[60].
- (3) The symptoms described in (1) appeared after onset of Parkinson's disease.
- (4) Recurrence or persistence of the symptoms described in (1) for at least 1 month.
- (5) No antipsychotic treatment.

Exclusion criteria for the Parkinson's disease with psychosis group

Patients with dementia with Lewy bodies, schizophrenia, affective disorder and schizophrenia, paranoia, mood disorder with psychiatric symptoms, or delirium were excluded.

Inclusion criteria for the Parkinson's disease without psychosis group

- (1) Meet the UK Brain Bank criteria for Parkinson's disease.
- (2) No perceptual errors, existing error perception, hallucinations, or delusions.

Methods

Diffusion tensor imaging

Examinations were performed on a Signa Excite 3.0 T scanner (GE Healthcare, Waukesha, WI, USA), at a gradient strength of 45 mT/m, gradient-switching rate of 200 mT/m per second, using an 8-channel array coil. Conventional scanning parameters were used for the axial position. Fast-spin echo-T1WI: A repetition/echo time of 1 827.0 ms/26.8 ms and a bandwidth of 31.2 kHz; Fast recovery fast spin-echo-XL-T2WI: A repetition/echo time of 2 820 ms/111 ms and a bandwidth of 41.7 kHz; T2-FLAIR: A repetition/echo time of 8 002 ms/146 ms, a bandwidth of 41.7 kHz, a slice thickness of 6.0 mm, an interslice gap of 1.0 mm, a matrix of 240 × 180, and one excitation. The scanning plane was parallel to the anterior commissure-posterior commissure line.

Three-dimensional volumetric rendering

Sagittal 3D-CUBE: A repetition/echo time of 6 000.0 ms/141.2 ms, a bandwidth of 31.2 kHz, a slice thickness of 1.2 mm, a matrix of 320 × 256, no interslice gap, and an echo train length of 140 ms. Substantia nigra, globus pallidus, frontal cortex (areas 9 and 10), occipital cortex (areas 18 and 19), cingulate gyrus, and hippocampus were positioned through cross-section of the hypothalamus, interventricular foramen, and two planes above the body of the corpus callosum.

Diffusion tensor imaging scanning

Transverse axial scanning was performed using single-shot spin echo echo-planar imaging sequences. The scanning plane was parallel to anterior commissure-posterior commissure line. The *b* value was 1 000 s/mm², and the number of diffusion-gradient directions was 15. Scanning parameters were as follows: The repetition/echo time was 8 000.0 ms/87.6 ms, the field of vision was 230 mm × 230 mm, the sampling matrix was 128 × 128, the reconstruction matrix was 256 × 256, there were

28 total slices each with a thickness of 3.5 mm, the interslice gap was 0 mm, and there was one excitation. Image reconstruction was analyzed and processed on an AW4.3 work station using Functool 4.5.5 software (General Electric Advantage Windows 4.5.5, Waukesha). Relative parameters were set to: An angle threshold of 27.0 and anisotropy threshold of 0.15. Fractional anisotropy and directionally encoded color maps were obtained through reconstruction by the same physician. Fractional anisotropy was collected at regions of interest using Functool software. The pixels were constant in each region of interest, with bilateral symmetry.

Establishment of locations and voxels for each region of interest

A three-dimensional volumetric rendering technique was used to position the substantia nigra, globus pallidus, frontal lobe areas 9 and 10, occipital lobe areas 18 and 19, cingulate gyrus, and the hippocampus. Voxel acquisition was done in the transverse plane (Figure 1).

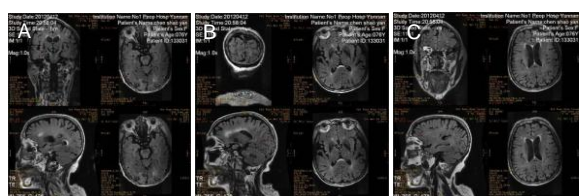


Figure 1 Three-dimensional volumetric rendered images of the head of a female 76-year-old patient with psychosis associated with Parkinson's disease.

(A) The plane through the hypothalamus. (B) The plane through the interventricular foramen. (C) Two planes above the body of the corpus callosum. During diffusion tensor imaging acquisition, the horizontal plane was primarily used for positioning, with coronal and sagittal planes also used for accurate positioning. Coronal planes, sagittal planes, and horizontal planes can be seen in each image (top left, bottom left, and bottom right, respectively).

In the cross-section through the hypothalamus, fractional anisotropy of the substantia nigra was obtained using an oval voxel (Figure 2A) that was 60 ± 10 . In the cross-section through the interventricular foramen, fractional anisotropy of the globus pallidus was obtained using a triangular-like voxel (Figure 2B) that was 100 ± 10 . In the two planes above the body of the corpus callosum, fractional anisotropy of frontal lobe areas 9 and 10 was obtained using a rectangular voxel (Figure 2C) that was 300 ± 10 . In the cross-section through the interventricular foramen, fractional anisotropy of the occipital areas 18 and 19 was obtained using a wedge-shaped voxel (Figure 2B) that was 250 ± 25 . In the two planes above the body of the corpus callosum, fractional

anisotropy of the cingulate gyrus was obtained using a rectangular voxel (Figure 2C) that was 1000 ± 100 . In the cross-section through the hypothalamus, fractional anisotropy of hippocampus was obtained using an oval voxel that was 150 ± 15 (Figure 2A).

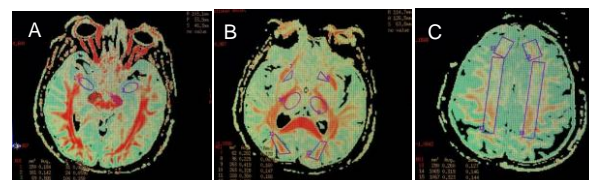


Figure 2 Establishment of locations and voxels (diffusion weighted imaging) of each region of interest in a female 76-year-old patient with psychosis associated with Parkinson's disease.

(A) Hippocampus (top ovals voxel), substantia nigra (bottom rectangles voxel); (B) globus pallidus (top triangles voxel), occipital lobe (bottom wedges voxel); (C) frontal lobe (top rectangles voxel), and cingulate gyrus (bottom rectangles voxel).

Relative conditions of white-matter fiber damage in different functional brain regions revealed by the ratio of fractional anisotropy

In both patient groups, fractional anisotropy of the cortical regions mentioned above was compared with the fractional anisotropy of ipsilateral substantia nigra or globus pallidus, thus obtaining group values that indicated the degree of white-matter fiber damage in the cortical regions relative to the substantia nigra or globus pallidus.

Statistical analysis

Data are expressed as mean \pm SD, and numeration data are represented as constituent ratio. All data were analyzed using SPSS 13.0 software (SPSS, Chicago, IL, USA). Intergroup comparison was done using two-sample *t*-test and chi-square tests. A value of $P < 0.05$ was considered statistically significant.

REFERENCES

- [1] Weintraub D, Comella CL, Horn S. Parkinson's disease-part 1: pathophysiology, symptoms, burden, diagnosis, and assessment. *Am J Manag Care*. 2008;14(2 Suppl): S40-48.
- [2] Chinese Psychiatric Association. Chinese Classification of Mental Disorders-3. Shandong: Shandong Publishing Company of Science and Technology, China. 2001.
- [3] Ravina B, Marder K, Fernandez H. Diagnostic criteria for psychosis in parkinson's disease. Report of an NINDS, NIMH Work Group. *Mov Disord*. 2007;22(8):1061-1068.

- [4] Ceravolo R, Frosini D, Rossi C, et al. Spectrum of addictions in Parkinson's disease: from dopamine dysregulation syndrome to impulse control disorders. *J Neurol*. 2010; 257(Suppl 2):S276-283.
- [5] Bayard S, Cochen De Cock V, Dauvilliers Y. Dopamine dysregulation syndrome in Parkinson's disease and restless legs syndrome. *Geriatr Psychol Neuropsychiatr Vieil*. 2011;9(2):227-235.
- [6] Wahlstrom D, White T, Luciana M. Neurobehavioral evidence for changes in dopamine system activity during adolescence. *Neurosci Biobehav Rev*. 2010;34(5):631-648.
- [7] Leh SE, Petrides M, Strafella AP. The neural circuitry of executive functions in healthy subjects and parkinson's disease. *Neuropsychopharmacology*. 2010;35(1):70-85.
- [8] Carod-Artal FJ, Martinez-Martin P. Independent validation of the non motor symptoms scale for Parkinson's disease in Brazilian patients. *Parkinsonism Relat Disord*. 2013; 19(1):115-119.
- [9] Zhong JM, Zhang KL, Wu SY, et al. The contrasting of the treatment in Psychiatric symptom of Parkinson's disease by olanzapine and clozapine. *Linchuang Shenjing Yixue Zazhi*. 2009;19(1):25-27.
- [10] National Collaborating Centre for Chronic Conditions (UK). Parkinson's Disease: National Clinical Guideline for Diagnosis and Management in Primary and Secondary Care. London: Royal College of Physicians (UK). 2006.
- [11] Eidelberg D. Metabolic brain networks in neurodegenerative disorders: a functional imaging approach. *Trends Neurosci*. 2009;32(10):548-557.
- [12] Ravina B, Marek K, Eberly S, et al. Dopamine transporter imaging is associated with long-term outcomes in Parkinson's disease. *Mov Disord*. 2012;27(11):1392-1397.
- [13] Wu T, Wang J, Wang C, et al. Basal ganglia circuits changes in Parkinson's disease patients. *Neurosci Lett*. 2012;524(1):55-59.
- [14] Meyer-Lindenberg A, Miletich RS, Kohn PD, et al. Reduced prefrontal activity predicts exaggerated striatal dopaminergic function in schizophrenia. *Nat Neurosci*. 2002;5(3):267-271.
- [15] Corlett PR, Fletcher PC. The neurobiology of schizotypy: fronto-striatal prediction error signal correlates with delusion-like beliefs in healthy people. *Neuropsychologia*. 2012;50(14):3612-3620.
- [16] Dichter GS, Damiano CA, Allen JA. Reward circuitry dysfunction in psychiatric and neurodevelopmental disorders and genetic syndromes: animal models and clinical findings. *J Neurodev Disord*. 2012;4(1):19.
- [17] Sulzer D. Multiple hit hypotheses for dopamine neuron loss in Parkinson's disease. *Trends Neurosci*. 2007;30(5): 244-250.
- [18] Bjorklund A, Dunnett SB. Dopamine neuron systems in the brain: an update. *Trends Neurosci*. 2007;30(5):194-202.
- [19] Kumar S, Soren S, Chaudhury S. Hallucinations: etiology and clinical implications. *Ind Psychiatry J*. 2009;18(2): 119-126.
- [20] Birkmayer W, Hornykiewicz O. The L-3,4-dioxyphenylalanine (DOPA)-effect in Parkinson-akinesia. *Wien Klin Wochenschr*. 1961;73:787-788.
- [21] Szot P, Franklin A, Sikkema C, et al. Sequential loss of lcnoradrenergic and dopaminergic neurons results in a correlation of dopaminergic neuronal number to striatal dopamine concentration. *Front Pharmacol*. 2012;3:184.
- [22] Du G, Lewis MM, Sen S, et al. Imaging nigral pathology and clinical progression in Parkinson's disease. *Mov Disord*. 2012;27(13):1636-1643.
- [23] Moore JW, Schneider SA, Schwingsenschuh P, et al. Dopaminergic medication boosts action-effect binding in Parkinson's disease. *Neuropsychologia*. 2010;48(4):1125-1132.
- [24] Park A, Stacy M. Dopamine-induced nonmotor symptoms of Parkinson's disease. *Parkinsons Dis*. 2011;2011:485063.
- [25] Meyer-Lindenberg A. From maps to mechanisms through neuroimaging of schizophrenia. *Nature*. 2010;468(7321): 194-202.
- [26] Fusar-Poli P, Howes OD, Allen P, et al. Abnormal frontostriatal interactions in people with prodromal signs of psychosis: a multimodal imaging study. *Arch Gen Psychiatry*. 2010;67(7):683-691.
- [27] Fudge JL, Emiliano AB. The extended amygdala and the dopamine system: another piece of the dopamine puzzle. *J Neuropsychiatry Clin Neurosci*. 2003;15(3):306-316.
- [28] Reetz K, Lencer R, Steinlechner S, et al. Limbic and frontal cortical degeneration is associated with psychiatric symptoms in PINK1 mutation carriers. *Biol Psychiatry*. 2008;64(3):241-247.
- [29] Kyriakopoulos M, Frangou S. Recent diffusion tensor imaging findings in early stages of schizophrenia. *Curr Opin Psychiatry*. 2009;22(2):168-176.
- [30] Nilsson C, Markenroth Bloch K, Brockstedt S, et al. Tracking the neurodegeneration of parkinsonian disorders-a pilot study. *Neuroradiology*. 2007;49(2):111-119.
- [31] Marumoto K, Koyama T, Hosomi M, et al. Diffusion tensor imaging in elderly patients with idiopathic normal pressure hydrocephalus or Parkinson's disease: diagnosis of gait abnormalities. *Fluids Barriers CNS*. 2012;9(1):20.
- [32] Prakash BD, Sitoh YY, Tan LC, et al. Asymmetrical diffusion tensor imaging indices of the rostral substantia nigra in Parkinson's disease. *Parkinsonism Relat Disord*. 2012;18(9):1029-1033.
- [33] Rolheiser TM, Fulton HG, Good KP, et al. Diffusion tensor imaging and olfactory identification testing in early-stage Parkinson's disease. *J Neurol*. 2011;258(7):1254-1260.
- [34] Ibarretxe-Bilbao N, Junque C, Marti MJ, et al. Olfactory impairment in Parkinson's disease and white matter abnormalities in central olfactory areas: a voxel-based diffusion tensor imaging study. *Mov Disord*. 2010;25(12): 1888-1894.
- [35] Boelmans K, Bodammer NC, Suchorska B, et al. Diffusion tensor imaging of the corpus callosum differentiates corticobasal syndrome from Parkinson's disease. *Parkinsonism Relat Disord*. 2010;16(8):498-502.

- [36] Chan LL, Rumpel H, Yap K, et al. Case control study of diffusion tensor imaging in Parkinson's disease. *J Neurol Neurosurg Psychiatry*. 2007;78(12):1383-1386.
- [37] Lee DY, Smith GN, Su W, et al. White matter tract abnormalities in first-episode psychosis. *Schizophr Res*. 2012;141(1):29-34.
- [38] Kunimatsu N, Aoki S, Kunimatsu A, et al. Tract-specific analysis of white matter integrity disruption in schizophrenia. *Psychiatry Res*. 2012;201(2):136-143.
- [39] Carletti F, Woolley JB, Bhattacharyya S, et al. Alterations in white matter evident before the onset of psychosis. *Schizophr Bull*. 2012;38(6):1170-1179.
- [40] Marengo S, Stein JL, Savostyanova AA. Investigation of anatomical thalamo-cortical connectivity and fMRI activation in schizophrenia. *Neuropsychopharmacology*. 2012;37(2):499-507.
- [41] Luck D, Buchy L, Czechowska Y, et al. Fronto-temporal disconnectivity and clinical short-term outcome in first episode psychosis: a DTI-tractography study. *J Psychiatr Res*. 2011;45(3):369-377.
- [42] Peters BD, Dingemans PM, Dekker N, et al. White matter connectivity and psychosis in ultra-high-risk subjects: a diffusion tensor fiber tracking study. *Psychiatry Res*. 2010;181(1):44-50.
- [43] Flügel D, Cercignani M, Symms MR, et al. Diffusion tensor imaging findings and their correlation with neuropsychological deficits in patients with temporal lobe epilepsy and interictal psychosis. *Epilepsia*. 2006;47(5):941-944.
- [44] Menke RA, Scholz J, Miller KL, et al. MRI characteristics of the substantia nigra in Parkinson's disease: a combined quantitative T1 and DTI study. *Neuroimage*. 2009;47(2):435-441.
- [45] Zhang K, Yu C, Zhang Y, et al. Voxel-based analysis of diffusion tensor indices in the brain in patients with Parkinson's disease. *Eur J Radiol*. 2011;77(2):269-273.
- [46] Diederich NJ, Goetz CG, Stebbins GT. Repeated visual hallucinations in Parkinson's disease a disturbed external/internal perceptions: focused review and a new integrative model. *Mov Disorders*. 2005;20(2):130-140.
- [47] Oishi N, Udaka F, Kameyama M. Regional cerebral blood flow in Parkinson disease with nonpsychotic visual hallucinations. *Neurology*. 2005;65(11):1708-1715.
- [48] Usui C, Hatta K, Doi N, et al. Improvements in both psychosis and motor signs in Parkinson's disease, and changes in regional cerebral blood flow after electroconvulsive therapy. *Prog Neuropsychopharmacol Biol Psychiatry*. 2011;35(7):1704-1708.
- [49] Kraft E, Winkelmann J, Trenkwalder C, et al. Visual hallucinations, white matter lesions and disease severity in Parkinson's disease. *Acta Neurol Scand*. 1999;99(6):362-367.
- [50] Alex KD, Pehek EA. Pharmacologic mechanisms of serotonergic regulation of dopamine neurotransmission. *Pharmacol Ther*. 2007;113(2):296-320.
- [51] Navailles S, De Deurwaerdère P. Imbalanced dopaminergic transmission mediated by serotonergic neurons in l-dopa-induced dyskinesia. *Parkinsons Dis*. 2012;2012:323686.
- [52] Ravina B, Marek K, Eberly S, et al. Dopamine transporter imaging is associated with long-term outcomes in Parkinson's disease. *Mov Disord*. 2012;27(11):1392-1397.
- [53] Fusar-Poli P, McGuire P, Borgwardt S. Mapping prodromal psychosis: a critical review of neuroimaging studies. *Eur Psychiatry*. 2012;27(3):181-191.
- [54] Surdhar I, Gee M, Bouchard T, et al. Intact limbic-prefrontal connections and reduced amygdala volumes in Parkinson's disease with mild depressive symptoms. *Parkinsonism Relat Disord*. 2012;18(7):809-813.
- [55] Lee JE, Park HJ, Park B, et al. A comparative analysis of cognitive profiles and white-matter alterations using voxel-based diffusion tensor imaging between patients with Parkinson's disease dementia and dementia with Lewy bodies. *J Neurol Neurosurg Psychiatry*. 2010;81(3):320-326.
- [56] Starkstein SE, Brockman S, Hayhow BD. Psychiatric syndromes in Parkinson's disease. *Curr Opin Psychiatry*. 2012;25(6):468-472.
- [57] Aarons S, Peisah C, Wijeratne C. Neuropsychiatric effects of Parkinson's disease treatment. *Australas J Ageing*. 2012;31(3):198-202.
- [58] Overall JE, Gorham DR. The Brief Psychiatric Rating Scale. *Psychol Rep*. 1962;10:799-812.
- [59] State Council of the People's Republic of China. Administrative Regulations on Medical Institution. *Gazette of the State Council of the People's Republic of China*. 1994.
- [60] Dickson DW, Braak H, Duda JE, et al. Neuropathological assessment of Parkinson's disease: refining the diagnostic criteria. *Lancet Neurol*. 1993;8(12):1150-1157.

(Reviewed by Phillips A, Yajima W, Zeng QS, Chen W)
(Edited by Wang J, Qiu Y, Li CH, Song LP, Liu WJ, Zhao M)