



Pediatric Stinger Syndrome: Acute Brachial Plexopathy After Minor Trauma

Whitney L. Quong, BSc*

Sally L. Hynes, MD,
FRCS(C)†‡

Jugal S. Arneja, MD, MBA,
FRCS(C)†‡

Summary: The “stinger” or “burner” is a form of transient brachial plexopathy termed for its characteristic knife-like pain extending from the neck to the fingertips. Muscle weakness and paresthesia are oftentimes associated symptoms and are similarly temporary. Commonly observed in athletes of contact sports, the stinger results from high force trauma causing either traction/direct compression to the brachial plexus or extension/compression of the cervical nerve roots. We describe a pediatric case of a stinger in a 14-year-old boy, which was caused by a relatively low force trauma accident. Our management strategy and recommendations are discussed. (*Plast Reconstr Surg Glob Open* 2015;3:e560; doi: 10.1097/GOX.0000000000000543; Published online 19 November 2015.)

Innervating the shoulder and upper extremity, the brachial plexus is one of the most intricate peripheral nervous system structures. However, despite its functional significance, the plexus’ large size, superficiality, and anatomic interposition between the mobile neck, shoulder, and arm make it uniquely susceptible to injury. Brachial plexopathies are classified by the particular component impaired, the injury mechanism, or the resulting symptoms.¹

First described in 1965,² the “stinger” or “burner,” is a neuropraxia of the brachial plexus, or its cervical nerve roots, named for distinctive burning pain and paresthesia.² Along with pain extending from the neck to the fingers, there may be associated muscle weakness, with deficits common in the deltoid, supraspinatus, and biceps and numbness in the upper extremity skin. The symptoms are typically transient, with pain resolution within 24 hours, and the weakness rarely persisting for weeks.³

Three main trauma mechanisms cause stingers: traction to the plexus from shoulder depression with contralateral neck bending; neck extension, rotation, or lateral flexion causing narrowing of the foramina and nerve root compression; and compression of the fixed brachial plexus between the shoulder pad and superomedial scapula at Erb’s point.⁴ The injury patterns are principally divided into traction/direct compression injury to the brachial plexus or extension/compression injury to the cervical nerve roots.

Stingers are relatively common and frequently reported in football, hockey, and boxing, sports typified by a high level of contact.^{5,6} However, low impact activities such as prolonged heavy backpack carriage may also produce stingers.⁷ We describe herein a stinger resulting from a relatively low force trauma in an adolescent boy, and we detail our management strategy in this accident-prone population.

CLINICAL CASE

A 14-year-old healthy, right hand dominant boy presented emergently with left upper extremity paralysis after falling forward from a rolling chair, and striking his right shoulder on a table. The paralysis was immediate, and associated with paresthesia. There was neither coincident head trauma, neck pain, nor deficits to the other extremities. There was no previous history of neurologic symptoms, upper extremity trauma, congenital anomalies, or surgeries.

Disclosure: The authors have no financial interest to declare in relation to the content of this article. The Article Processing Charge was paid for by the authors.

From the *Faculty of Medicine, †Division of Plastic Surgery, University of British Columbia, Vancouver, BC, Canada; and ‡Division of Plastic Surgery, Department of Surgery, British Columbia Children’s Hospital, Vancouver, BC, Canada.

Received for publication July 3, 2015; accepted September 17, 2015.

Copyright © 2015 The Authors. Published by Wolters Kluwer Health, Inc. on behalf of The American Society of Plastic Surgeons. All rights reserved. This is an open-access article distributed under the terms of the Creative Commons Attribution-Non Commercial-No Derivatives License 4.0 (CCBY-NC-ND), where it is permissible to download and share the work provided it is properly cited. The work cannot be changed in any way or used commercially.

DOI: 10.1097/GOX.0000000000000543

On examination, there were no open lesions; signs of inflammation; bony deformities; or point tenderness of the cervical spine, scapula, or upper extremities. Cervical spine range of motion was full and painless. Vascular supply to the hand was normal. The results of the Adson and reverse Adson tests were negative for thoracic outlet syndrome. Examination of cranial nerves II–X and XII demonstrated no deficits. There was, however, left trapezius weakness with grade 1 strength. There were no signs of Horner’s syndrome. The skin perspiration pattern, temperature, and color were normal and symmetric.

The peripheral neuromuscular examination revealed numerous left upper limb deficits (Fig. 1). Pronounced weakness was noted in shoulder abduction, flexion, and extension. On the Medical Research Council grading scale, the deltoid was rated grade 1 in strength. There was no movement on internal or external rotation of the arm. Flexion and extension of the elbow were impaired, with grade 1 strength of the biceps and triceps. The patient was unable to flex or extend either the wrist or fingers, and no contraction was apparent in these muscle groups. There was grade 2 power of the flexor pollicis longus, and extensor pollicis longus, but no motor function of the intrinsic hand muscles. Sensory evaluation demonstrated preserved light touch perception in the C3-4 dermatomes, but no sensation to either light touch or pinprick from C5-T1.

X-ray analysis verified that there were neither fractures nor dislocations of the cervical spine, clavicle, scapula, or glenohumeral joint, whereas magnetic resonance imaging confirmed that there was no nerve root avulsion. After 2 weeks observation, the patient recovered full motor and sensory functioning.

DISCUSSION

Classically resulting from acute high force trauma, the stinger is a common unilateral neuropraxia of the brachial plexus or its related cervical nerve roots. Herein, we described a low energy event triggering a stinger, also notable for its occurrence in a pediatric patient. To date, there has been no report of a pediatric stinger.

The initial pediatric workup should be thorough and aim to rule out alternative or comorbid diagnoses, subclavian or axillary vascular compromise, fractures to the cervical spine, shoulder girdle, or upper extremity, and space-occupying lesions. It is also important to recognize underlying structural anomalies including spinal canal stenosis, neuroforaminal stenosis, or other pathology, such as a tumor, which could predispose the patient to stingers.⁸ Ultimately, the postinjury period should involve close observation and achievement of complete recovery. The differential diagnosis for stingers may consist of clavicle fracture, shoulder dislocation, rotator cuff tear, acromioclavicular separation, intervertebral disk

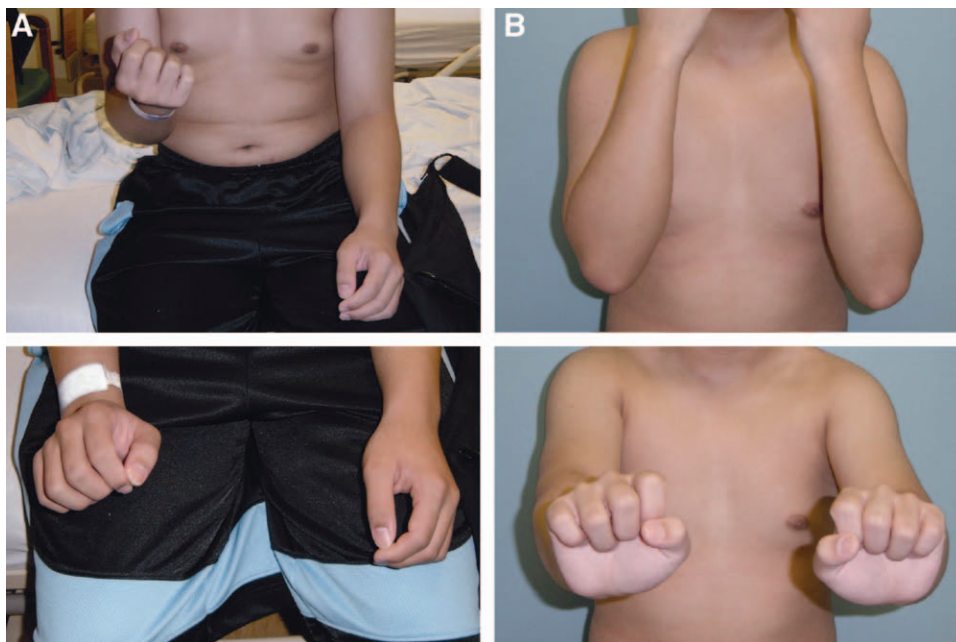


Fig. 1. Profound neuromuscular weakness was noted in the distribution of the left brachial plexus. A, Immediately after the accident, there was evident weakness in shoulder abduction, elbow flexion, wrist extension, and thumb extension. B, After 2 weeks of observation, the patient recovered full motor function and sensation to the left upper limb.

herniation, or other peripheral nerve injuries including cervical radiculopathy, thoracic outlet syndrome, suprascapular neuropathy, axillary neuropathy, and long thoracic neuropathy.

If the neurologic symptoms continue, or the plexopathy is a recurrence, magnetic resonance imaging to investigate neuroforaminal stenosis, mass lesions, nerve root avulsion, or vertebral disc herniation is recommended. Electrodiagnostic assessment including nerve conduction studies and electromyography is indicated where deficits persist beyond 3–4 weeks, to further quantify and characterize the lesion.¹ Both modalities can distinguish between cervical radiculopathy and brachial plexopathy, as well as preganglionic and postganglionic brachial plexus lesions.

With recurrent stinger injuries, chronic stinger/burner syndrome may develop. This has been most often seen in those who engage in ongoing high contact sports and who have preexisting anatomic anomaly. The chronic syndrome has an association with cervical canal stenosis, lordosis reversal, disk disease, foraminal stenosis, and a positive Spurling's sign, suggesting that alterations in pathomechanics may be exacerbating compression of dorsal nerve roots within the intervertebral foramina.

With regard to rehabilitation and symptom management, the approach should be conservative but multifaceted. Physiotherapy to encourage early mobilization may aid to restore function more rapidly and keep joints supple if recovery is delayed. Analgesics can be used as required. Ultimately, the patient's clinical progress should be carefully monitored, with weekly follow-up until full resolution of the stinger is confirmed.

CONCLUSIONS

As demonstrated in the current report, stingers can occur in the setting of low-velocity trauma, in

addition to the classic high force mechanism, and should, therefore, be considered as part of the differential diagnosis for any sudden unilateral upper extremity motor/sensory loss. Particularly when occurring in a child, the immediate workup should endeavor to exclude brain and spinal cord injury and determine if underlying anatomic anomalies were contributory. The management pathway should be conservative because full spontaneous recovery is expected. Clinical observation should be supplemented with electrodiagnostic study for persistent symptoms.

Jugpal S. Arneja, MD, MBA, FRCS(C)

Division of Plastic Surgery
University of British Columbia
British Columbia Children's Hospital, K3-131 ACB
4480 Oak Street, Vancouver, BC
Canada V6H 3V4
E-mail: jugpal.arneja@ubc.ca

REFERENCES

1. Ferrante MA. Brachial plexopathies: classification, causes, and consequences. *Muscle Nerve*. 2004;30:547–568.
2. Chrisman OD, Snook GA, Stanitis JM, et al. Lateral-flexion neck injuries in athletic competition. *JAMA*. 1965;192:613–615.
3. Rihn JA, Anderson DT, Lamb K, et al. Cervical spine injuries in American football. *Sports Med*. 2009;39:697–708.
4. Weinberg J, Rokito S, Silber JS. Etiology, treatment, and prevention of athletic “stingers”. *Clin Sports Med*. 2003;22:493–500, viii.
5. Shannon B, Klimkiewicz JJ. Cervical burners in the athlete. *Clin Sports Med*. 2002;21:29–35, vi.
6. Toth C. Peripheral nerve injuries attributable to sport and recreation. *Phys Med Rehabil Clin N Am*. 2009;20:77–100, viii.
7. Mäkelä JP, Ramstad R, Mattila V, et al. Brachial plexus lesions after backpack carriage in young adults. *Clin Orthop Relat Res*. 2006;452:205–209.
8. Kelly JD 4th, Aliquo D, Sitler MR, et al. Association of burners with cervical canal and foraminal stenosis. *Am J Sports Med*. 2000;28:214–217.