



Persistent pleuritic chest pain in a patient with cystic fibrosis

Stefanie Louey ¹, Shivanthan Shanthikumar ^{1,2,3}, Moya Vandeleur ^{1,2,3}, Amanda Gwee ^{2,3,4} and Phil Robinson ^{1,2,3}

¹Respiratory and Sleep Medicine, The Royal Children's Hospital, Melbourne, Australia. ²Dept of Paediatrics, University of Melbourne, Melbourne, Australia. ³Murdoch Children's Research Institute, Melbourne, Australia. ⁴Infectious Diseases, The Royal Children's Hospital, Melbourne, Australia.

Corresponding author: Stefanie Louey (steflouey@gmail.com)



Shareable abstract (@ERSpublications)

Pleural effusion is rare in cystic fibrosis. Infection leading to pleural effusion is likely to be polymicrobial, including contributory fungal infection; microbiology of pleural fluid is commonly discordant with sputum. <https://bit.ly/3MJXrhk>

Cite this article as: Louey S, Shanthikumar S, Vandeleur M, *et al.* Persistent pleuritic chest pain in a patient with cystic fibrosis. *Breathe* 2022; 18: 220007 [DOI: 10.1183/20734735.0007-2022].

Copyright ©ERS 2022

Breathe articles are open access and distributed under the terms of the Creative Commons Attribution Non-Commercial Licence 4.0.

Received: 14 Jan 2022
Accepted: 28 April 2022

Background and presentation

A 14-year-old girl with cystic fibrosis (CF), homozygous for the Phe508del mutation, was electively admitted for optimisation of lung disease. Her CF was complicated by bronchiectasis, gastrostomy feeding, liver disease, and diabetes. Sputum cultures had identified *Haemophilus parainfluenzae* and *Candida albicans* in the previous 12 months, but she had never cultured *Pseudomonas aeruginosa*. She also had comorbid osteogenesis imperfecta (OI), type 3 phenotype, which was complicated by multiple long bone fractures including four rib fractures at birth. Her baseline forced expiratory volume in 1 s (FEV₁) was 44% (0.78 L), forced vital capacity (FVC) 54% (1.06 L), and FEV₁/FVC ratio 81% predicted. The combination of CF and OI had resulted in severe restrictive lung disease with nocturnal hypoventilation managed with bilevel noninvasive ventilation.

Task 1

What are the contributory factors to this patient's respiratory failure?

- Chest wall deformity
- Chronic airway infection
- Reduced mucociliary clearance
- Nocturnal hypoventilation
- All of the above

[Go to Answers >>](#)

On admission, the patient had a history of increasing productive cough but was not febrile, tachypnoeic or hypoxaemic. Her height was 129 cm (<1st centile), weight 30.5 kg (<1st centile) and body mass index 17 kg·m⁻² (20th centile), which was stable when compared with previous measurements. She was noted to have blue sclera, digital clubbing and pectus carinatum. There were reduced breath sounds with bronchial breathing and scattered crepitations bilaterally in lower zones. Spirometry on day 1 of admission demonstrated a FEV₁ of 38% (0.7 L). As per local guidelines, she was commenced on intravenous ceftriaxone to cover *H. parainfluenzae*. On day 7 of admission, the patient developed pleuritic chest pain.

Task 2

What is the most suitable investigation to elicit the cause of pleuritic chest pain?

- Sputum microscopy and culture
- Computed topography pulmonary angiogram
- Chest radiography
- Transthoracic echocardiogram
- Chest ultrasonography

[Go to Answers >>](#)



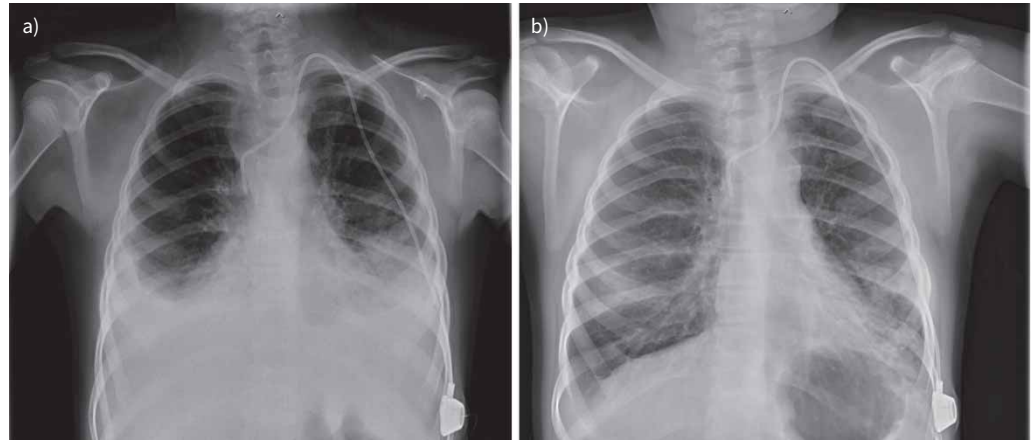


FIGURE 1 a) Chest radiography demonstrating bilateral pleural effusions on day 7 of admission for exacerbation of bronchiectasis in a patient with CF. b) Chest radiography with marked reduction in pleural fluid following 12 weeks of antifungal treatment.

Bilateral pleural effusions and features of bronchiectasis were identified on chest radiography (figure 1a). As the patient was unable to expectorate, upper airway samples were obtained and were negative for respiratory viruses and bacteria. A full blood count demonstrated a mildly elevated eosinophil count of $0.6 \times 10^9 \text{ L}^{-1}$ (normal range: $0\text{--}0.5 \times 10^9 \text{ L}^{-1}$). Renal and liver function, albumin level, and immune function tests were normal. Both total IgE and aspergillus-specific IgE were not raised. Chest ultrasonography demonstrated simple pleural fluid, echocardiography showed normal cardiac structure and function without evidence of pulmonary hypertension, and abdominal ultrasound showed liver disease without ascites. Antibiotic coverage was broadened to piperacillin/tazobactam and tobramycin.

Task 3

The most appropriate next step in management would be?

- a) Watch and wait
- b) Aspiration of pleural fluid for microscopy and culture
- c) Treatment for ABPA
- d) Treatment with diuretics

[Go to Answers >>](#)

The patient continued to deteriorate with worsening hypercapnia (peak of 62 mmHg on capillary gas on day 31 of admission) and development of daytime hypoxaemia requiring supplemental oxygen at $2 \text{ L} \cdot \text{min}^{-1}$. Combined bronchoscopy with lavage, and insertion of bilateral intercostal catheters was undertaken for both therapeutic and diagnostic purposes. Pleural fluid (450 mL) was straw coloured, cytology showed total white cell count of $300 \times 10^6 \text{ L}^{-1}$ (normal range: $0\text{--}5 \times 10^6 \text{ L}^{-1}$) with neutrophil predominance, and lactate dehydrogenase $199 \text{ U} \cdot \text{L}^{-1}$ (normal range: $140\text{--}230 \text{ U} \cdot \text{L}^{-1}$). Fungal elements were detected on wet preparation, but culture was negative. Culture from bronchoalveolar lavage was positive for *Stenotrophomonas maltophilia* and *Aspergillus fumigatus*. Mycobacterial culture was negative. Intravenous co-trimoxazole (for *S. maltophilia*) and oral voriconazole (for *A. fumigatus*) were added to the antimicrobial regimen.

The patient had a dramatic response to the antibiotic and antifungal treatment. Intravenous piperacillin/tazobactam and co-trimoxazole was continued for 2 weeks, followed by oral co-trimoxazole for a further 4 weeks. Oral voriconazole was continued for a period of 6 months. Pleural catheters were removed on days 3 and 9 following placement, the patient was weaned off daytime oxygen, lung function recovered to FEV₁ 70% predicted, and she resumed usual activities. Her repeat chest radiograph also demonstrated near complete resolution of the bilateral effusions (see figure 1a and b).

Task 4

The clinical entities that cause pleural effusion related to lung disease in CF include:

- a) Fungal infection
- b) Parapneumonic effusion/empyema
- c) Nontuberculous mycobacterial infection
- d) All of the above

[Go to Answers >>](#)

Discussion

The identification of pleural infection complicating CF is rare. Prior to newborn screening, TAUSSIG *et al.* [2] described the first case series of infants with CF complicated by *Staphylococcus aureus* empyema, where susceptibility was attributed to immaturity of the developing immune system. Impaired host immunity is thought to allow microbial translocation from the airway into the pleural space. This has been supported by subsequent case reports of bacteria or nontuberculous mycobacterium causing empyema in CF patients on immunosuppressive therapy [3, 4], with hypersplenism [5], or following lung transplantation [6, 7].

BELANGER *et al.* [8] described 17 non-transplanted adult patients with CF complicated by pleural effusion from several major US treatment centres. The calculated crude incidence of pleural effusion was 43 per 10 000 person-years in hospitalised CF patients [3]. Effusions typically occurred in older patients with advanced lung disease, with the cohort having a median age of 25 years and median FEV₁ of 41% predicted.

With regards to microbiology, 82% of patients isolated *P. aeruginosa* and 47% fungus in sputum in the 6 months prior to pleural effusion development [8]. Pleural culture was performed in six cases, most commonly identifying *S. aureus* and/or *P. aeruginosa* [9]. In three out of six cases, more than one organism was identified [3]. In only 50% of cases pathogens from pleural fluid were concordant with sputum bacteriology. One patient in this series who had comorbid acute lymphoblastic leukaemia had bilateral effusions [8]. To the authors' knowledge pleural effusion has not been described as a result of OI.

These data suggest that pleural effusions in people with CF are often caused by polymicrobial infection where sputum microbiology is frequently discordant with pleural fluid, as was the case for the patient described. Pleural fluid identified *S. maltophilia*, which is intrinsically resistant to both β -lactams and aminoglycosides. *S. maltophilia* is an emerging multidrug-resistant organism identified in the airway of patients with CF and has been associated with an increased rate of pulmonary exacerbations and hospitalisations [10]. It is not known whether antimicrobial treatment impacts on clinical outcome, however, this case demonstrates failure without directed treatment.

The understanding of fungal organisms in CF is evolving, with increasing recognition of their role in the development of structural lung disease [11]. There are several clinical entities involving fungal disease in CF including: asymptomatic colonisation or allergic sensitisation, invasive fungal disease in those with impaired immunity, fungal bronchitis in pulmonary exacerbation unresponsive to standard antimicrobial therapy, and the IgE-mediated inflammatory syndrome ABPA. Pleural effusion can rarely complicate ABPA [9, 12], and has been described in cases of bronchopleural/bronchoalveolar fistulae with pneumothorax and empyema where fungi has been isolated from pleural fluid [13, 14].

There has been longstanding interest in the interaction between bacterial and fungal pathogens that produce biofilms in the CF airway. In the described case, fungal elements were detected in pleural fluid and bronchoalveolar lavage culture yielded *A. fumigatus*, which is another potential reason for failure to improve with broad spectrum antibiotic therapy. This patient does not have any of the host risk factors commonly associated with invasive fungal lung disease such as immunosuppression or long-term steroid therapy [15], and they do not meet criteria for ABPA. It is likely that co-infection with *A. fumigatus* and *S. maltophilia* has resulted in greater severity bronchitis and airway inflammation [16] that has predisposed to the complication of empyema.

Conclusion

This case describes bilateral pleural effusions as a rare but serious complication in CF. The role of comorbid OI in causing pleural effusions is unknown, but it is likely to have contributed to the pre-existing restrictive lung disease.

This case highlights an approach to pleural effusion in CF, with the following key messages.

- Pleural effusion is a rare cause for pleuritic chest pain in CF.
- The aetiology may be due to primary pulmonary pathology or a secondary cause.
- As a complication of pulmonary exacerbation, pleural effusions are likely to be polymicrobial, and there should be a high index of suspicion for contributory fungal infection.
- Sampling of lower airways and pleural fluid can be useful for both diagnostic and therapeutic purposes.
- Culture from sputum and pleural effusions may reveal discordant results.

Answer 1

e. The combination of OI and CF has not previously been described. OI is an inherited bone dysplasia due to mutations in the collagen type I gene [1]. Pulmonary complications due to altered chest wall mechanics, skeletal deformity and possibly intrinsic lung disease, are the leading cause of mortality [1]. The combination of CF with bronchiectasis, altered chest wall mechanics and reduced cough efficacy, has resulted in an early progression to severe restrictive lung disease and nocturnal hypoventilation necessitating bilevel noninvasive ventilation.

[<< Go to Task 1](#)

Answer 2

c. The cause of pleuritic chest pain could be due to pathology from the lung pleura, skeletal system or chest wall muscles. The patient has risk factors for pathology at all of these sites. The pleura could be affected by inflammation secondary to exacerbation of bronchiectasis, pleural effusion, pneumothorax, or allergic bronchopulmonary aspergillosis (ABPA). The combined features of OI and CF could result in a rib or vertebral fracture as the source of pain. Cough due to CF could cause muscular pain. Other rare causes include pulmonary embolism or pericardial disease. The emergence of the pain despite 7 days of intravenous antibiotic therapy suggests that if an exacerbation of bronchiectasis is the cause of the pain, infection with resistant bacteria or an atypical pathogen (nontuberculous mycobacterium or fungus) should be considered. Chest radiograph would be an appropriate investigation as it would help identify the source of the pain.

[<< Go to Task 2](#)

Answer 3

b. The presence of bilateral pleural effusion warrants further investigation. Bilateral, as opposed to unilateral effusions, should raise suspicion of an extrapulmonary cause. However, given the normal echocardiography, renal function, and absence of signs of liver failure it is likely in this case that the cause is an exacerbation of bronchiectasis. To guide further treatment, aspiration of pleural fluid to identify pathogens would be the most appropriate next step in managing this patient.

[<< Go to Task 3](#)

Answer 4

d.

[<< Go to Task 4](#)

Conflict of interest: The authors do not identify any conflicts of interest.

References

- 1 Tam A, Chen S, Schaure E, *et al.* A multicentre study to evaluate pulmonary function in osteogenesis imperfecta. *Clin Genet* 2018; 94: 501–511.
- 2 Taussig L, Belmonte M, Beaudry P. *Staphylococcus aureus* empyema in cystic fibrosis. *J Pediatr* 1974; 84: 724–727.
- 3 Mestitz H, Bowes G. *Pseudomonas aeruginosa* empyema in an adult with cystic fibrosis. *Chest* 2011; 98: 485–487.
- 4 Coates A, Schaefer O, Uy K, *et al.* Empyema in a woman with cystic fibrosis: a cautionary tale. *Case Rep Pulmonol* 2013; 2013: 159508.
- 5 Griffiths A, Massie J. Pleural empyema in a 14 year old adolescent with cystic fibrosis. *J Paediatr Child Health* 2006; 42: 395–397.
- 6 Khan S, Gordon S, Stillwell P, *et al.* Empyema and bloodstream infection caused by *Burkholderia gladioli* in a patient with cystic fibrosis after lung transplantation. *Paediatr Infect Dis J* 1996; 15: 637–639.

- 7 Noyes B, Michael M, Kurland G, *et al.* *Pseudomonas cepacia* empyema necessitatis after lung transplantation in two patients with cystic fibrosis. *Chest* 1994; 105: 1888–1891.
- 8 Belanger A, Nguyen K, Osman U, *et al.* Pleural effusions in non-transplanted cystic fibrosis patients. *J Cyst Fibros* 2017; 16: 499–502.
- 9 Kirschner A, Kuhlmann E, Kuzniar T. Eosinophilic pleural effusion complicating allergic bronchopulmonary aspergillosis. *Respiration* 2010; 82: 478–481.
- 10 Amin R, Jahnke N, Waters V. Antibiotic treatment for *Stenotrophomonas maltophilia* in people with cystic fibrosis (review). *Cochrane Database Sys Rev* 2020; 3: CD009249.
- 11 Breuer O, Schultz A, Garratt L, *et al.* *Aspergillus* infections and progression of structural lung disease in children with cystic fibrosis. *Am J Respir Crit Care Med* 2020; 201: 688–696.
- 12 O'Connor T, O'Donnell A, Hurley M, *et al.* Allergic bronchopulmonary aspergillosis: a rare cause of pleural effusion. *Respirology* 2001; 6: 361–363.
- 13 Lord R, Jones A, Webb K, *et al.* Pneumothorax in cystic fibrosis: beyond the guidelines. *Paediatr Respir Rev* 2016; 20S: 30–33.
- 14 Bongers S, Cardenas J. Endobronchial valve treatment of persistent alveolopleural fistula in a patient with cystic fibrosis and empyema. *J Cyst Fibros* 2020; 19: e36–e38.
- 15 Massan J, Bitnum A, Solomon M, *et al.* Invasive aspergillosis in cystic fibrosis. *Pediatr Infect Dis J* 2011; 30: 178–179.
- 16 Melloul E, Luiggi S, Anais L, *et al.* Characteristics of *Aspergillus fumigatus* in association with *Stenotrophomonas maltophilia* in an *in vitro* model of mixed biofilm. *PLoS ONE* 2016; 11: e0166325.