

Lomustine induced acute pulmonary toxicity in a pediatric medulloblastoma survivor

DOI: 10.4103/2278-330X.202570

Dear Editor,

Pulmonary complications in long-term pediatric cancer survivors are rare and are associated with significant morbidity.^[1] Long-term survivors of pediatric central nervous system tumors have a higher incidence of pulmonary diseases such as emphysema, obliterative bronchiolitis, asthma, chronic cough, recurrent pneumonia, and pulmonary fibrosis.^[2] Craniospinal radiation, cyclophosphamide, and lomustine (CCNU) have been implicated in the causation of pulmonary dysfunction in children with brain tumors.^[2] Pulmonary dysfunction in pediatric cancer survivors tends to be gradual in onset with frequent remission and exacerbation. We here report a case of acute and fatal pulmonary toxicity in a pediatric medulloblastoma survivor that was most probably caused by CCNU induced lung damage. An 11-year-old male patient was diagnosed to have high-risk nonmetastatic medulloblastoma after incomplete resection of his cerebellar tumor. Postsurgery he received radiotherapy at a dose of 36 Gy to the brain and spinal cord and 18 Gy boost to the tumor bed. Radiotherapy was followed by eight cycles of prednisolone, CCNU and vincristine (PCV) chemotherapy, which was given once in 6 weeks.^[3] The total cumulative dose of CCNU that the patient received was 800 mg/m². Magnetic resonance imaging of the brain was normal after completion of eight cycles of PCV chemotherapy. Post 6 months of completion of treatment, the patient presented to the hospital with a history of dry nonproductive cough for 1 week. He had no fever or weight loss or previous history of chronic lung pathology. On admission, he was tachypenic, and his peripheral blood oxygen saturation was 80%. Chest auscultation revealed right

infra-axillary harsh vesicular breath sounds. Chest X-ray showed right lower lobe consolidation [Figure 1a]. The patient had rapid deterioration in his pulmonary status, and he required noninvasive ventilation at 24 h of admission and invasive ventilation at 90 h of admission. Chest X-ray taken at 72 h of admission showed consolidation of the whole right lung and left lung upper lobe [Figure 1b]. Bronchoscopy and computed tomographic scan of the chest could not be performed in view of the patient's critical illness. Blood cultures for bacteria and fungus were sterile, and serum galactomannan assay for aspergillosis was negative. His white blood cell counts, platelet counts, and differential blood counts were normal at admission and during the period of hospitalization. He was treated with a broad spectrum antibiotic and anti-fungal cover that included meropenem, linezolid, caspofungin, sulfamethoxazole-trimethoprim, and azithromycin. Intravenous hydrocortisone at a dose of 10 mg/kg every 6 hourly was added on day 2 of admission. The patient died on day 6 of admission due to respiratory failure. Postmortem lung biopsy showed diffuse alveolar damage in exudative phase [Figure 2a and b]. There has

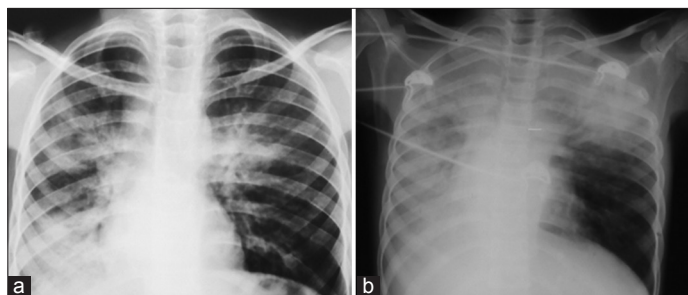


Figure 1: Chest X-ray. (a) On admission showing right lower lobe consolidation. (b) At 72 h showing progression of consolidation involving whole right lung and left upper lobe

Departments of Medical Oncology and ¹Pathology,
Adyar Cancer Institute, Chennai,
Tamil Nadu, India

Correspondence to: Dr.Venkatraman Radhakrishnan,
E-mail: venkymd@gmail.com

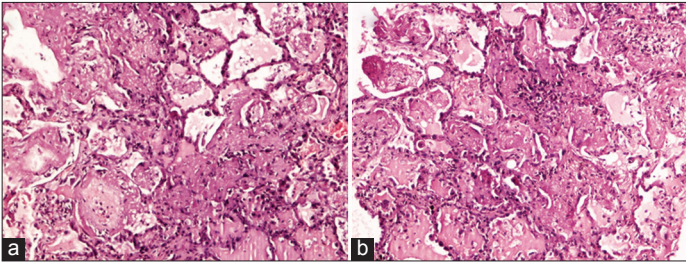


Figure 2: Postmortem lung biopsy. (a) Alveoli in the left lower hand corner are lined by hyaline membrane (H and E, x100). (b) Alveoli are filled with transudate and interstitium shows inflammatory infiltrate (H and E, x100)

been only one previous report of rapidly progressive, fatal CCNU pulmonary toxicity described in an adult patient with medulloblastoma.^[4] This case highlights the rare but fatal complication of CCNU induced lung damage and the fact that it can present acutely in a previously asymptomatic patient. Whether serial measurements of lung function could have predicted this complication is not known.

Financial support and sponsorship

Nil.

Conflicts of interest

There are no conflicts of interest.

**Venkatraman Radhakrishnan, Jayachandran Perumal,
Shirley Sundersingh¹, Tenali Sagar**

References

1. Mertens AC, Yasui Y, Liu Y, Stovall M, Hutchinson R, Ginsberg J, *et al.* Pulmonary complications in survivors of childhood and adolescent cancer. A report from the Childhood Cancer Survivor Study. *Cancer* 2002;95:2431-41.
2. Huang TT, Chen Y, Dietz AC, Yasui Y, Donaldson SS, Stokes DC, *et al.* Pulmonary outcomes in survivors of childhood central nervous system malignancies: A report from the Childhood Cancer Survivor Study. *Pediatr Blood Cancer* 2014;61:319-25.
3. Zeltzer PM, Boyett JM, Finlay JL, Albright AL, Rorke LB, Milstein JM, *et al.* Metastasis stage, adjuvant treatment, and residual tumor are prognostic factors for medulloblastoma in children: Conclusions from the Children's Cancer Group 921 randomized phase III study. *J Clin Oncol* 1999;17:832-45.
4. Dent RG. Fatal pulmonary toxic effects of lomustine. *Thorax* 1982;37:627-9.

This is an open access article distributed under the terms of the Creative Commons Attribution-NonCommercial-ShareAlike 3.0 License, which allows others to remix, tweak, and build upon the work non-commercially, as long as the author is credited and the new creations are licensed under the identical terms.

How to cite this article: Radhakrishnan V, Perumal J, Sundersingh S, Sagar T. Lomustine induced acute pulmonary toxicity in a pediatric medulloblastoma survivor. *South Asian J Cancer* 2017;6:38-9.