

This is an Open Access article licensed under the terms of the Creative Commons Attribution-NonCommercial-NoDerivs 3.0 License (www.karger.com/OA-license), applicable to the online version of the article only. Distribution for non-commercial purposes only.

Oral Propranolol for Circumscribed Choroidal Hemangioma

Empar Sanz-Marco^a Roberto Gallego^{a, b}
Manuel Diaz-Llopis^{a–c}

^aDepartment of Ophthalmology, New University and Polytechnic Hospital La Fe,

^bBiomedical Research Center for Rare Diseases Network (CIBERER), and ^cFaculty of Medicine, University of Valencia, Valencia, Spain

Key Words

Circumscribed choroidal hemangioma · Propranolol · β -Blocker

Abstract

Introduction: Several therapeutic approaches have been developed to treat choroidal hemangioma. However, all these therapies are associated with a potential risk of damaging the overlying retina.

Case Report: We report a case of circumscribed choroidal hemangioma (CCH) in a 59-year-old man refractory to laser treatment. Visual acuity was 20/200 and a serous macular detachment was present. The CCH was treated with oral propranolol, whereupon visual acuity improved to 20/20 and the macular detachment resolved without systemic or local adverse effects.

Discussion: Propranolol is a β -blocker commonly used in cardiology that may induce endothelium vasoconstriction and inhibit endothelial proliferation. It has been shown to be effective in infantile facial hemangiomas, and proved safe and effective for the CCH in our patient. Further studies are needed to confirm our observation.

Introduction

There are two types of choroidal hemangiomas: circumscribed choroidal hemangioma (CCH) and diffuse choroidal hemangioma (DCH).

CCH is a rare benign, commonly asymptomatic vascular tumor which is usually diagnosed in adulthood when it becomes symptomatic with visual acuity decline, visual field defect or metamorphopsia due to exudative retinal detachment. CCH appears as an orange choroidal mass with indistinct borders, usually within the macular area [1].

In contrast, DCH is usually evident at birth and typically occurs as part of neuro-oculocutaneous hemangiomatosis (Sturge-Weber syndrome), but it frequently does not become manifest until adolescence. DCH appears as a diffuse orange choroidal thickening. Despite this, focal regions of excessively thickened choroid may simulate CCH [2].

Choice of treatment for choroidal hemangiomas is based on tumor location, presence of subretinal fluid, extent of symptoms, and potential for visual recovery. Periodic observation alone is an optimal choice for asymptomatic cases without subretinal fluid. When vision loss occurs, different treatment options include: photodynamic therapy (PDT), transpupillary thermotherapy, vascular endothelial growth factor (VEGF), laser photocoagulation, episcleral plaque radiotherapy, cryotherapy, external beam radiotherapy, and stereotactic radiotherapy [2]. Despite their efficacy, inducing tumor atrophy, all these treatments are associated with the potential risk of damaging the overlying retina.

A new treatment has emerged for infantile hemangiomas: systemic propranolol [3]. Propranolol is a nonselective β -adrenergic receptor blocker commonly used for cardiologic indications. It seems to be safe and effective in orbital, eyelid and facial hemangiomas in children.

Case Report

A 59-year-old man with arterial hypertension (150/95 mm Hg) was seen in our department because of visual acuity (VA) decline and metamorphopsia of his left eye (OS) for 5 weeks. VA was 20/20 for his right eye and 20/200 for OS. A temporal superior CCH was evidenced in OS with foveal serous detachment ([fig. 1](#)).

We performed laser photocoagulation (the patient refused treatment with PDT) and 3 months later VA improved to 20/100 but foveal serous detachment persisted ([fig. 2](#)). Thereafter we decided to begin treatment with oral propranolol daily (120 mg). One month later, VA improved to 20/20 and serous foveal detachment disappeared ([fig. 3](#)). In addition, his arterial hypertension was under control (125/80 mm Hg). After 8 months of follow-up, both VA (20/20) and the macular thickness remained stable.

Discussion

Hemangiomas consist histologically of cavernous and capillary vascular networks. Their physiopathology is still poorly understood; nonetheless, VEGF and basic fibroblast growth factor (bFGF) have been involved in infantile hemangiomas growth [4]. Increased levels of these factors have been detected in cutaneous hemangiomas [5] and VEGF-receptors have been evidenced in proliferative infantile hemangiomas [6].

In addition, it has been shown that hypoxia-induced factors important for postnatal vasculogenesis like hypoxia-inducible factor 1 α (HIF-1 α), HIF-2 α and VEGF are up-regulated in children with proliferative infantile hemangiomas, leading to VEGF expression by endothelial cells [4–7].

Propranolol is a nonselective β -adrenergic receptor blocker, and the adrenergic system is the major regulator of cardiac and vascular function. Capillary endothelial cells express β_2 -adrenergic receptors [7, 8] which modulate the release of nitric oxide, causing endothelium-dependent vasodilatation. In addition, β -adrenergic receptor stimulation

can induce modifications of signal transduction pathways of angiogenic factors such as VEGF or bFGF, enhancing neoangiogenesis in ischemic events [7–9]. Moreover, a study of the use of β -adrenergic receptor blockers for the treatment of cardiac hypertrophy revealed that carvedilol reversed levels of HIF-1 α and VEGF to baseline values [10].

Therefore propranolol may induce endothelium vasoconstriction, decrease expression of bFGF, HIF-1 α and VEGF through the RAF–mitogen-activated protein kinase pathway [4, 8] and inhibit endothelial proliferation. Indeed, β -blockade induces apoptosis of cultured capillary endothelial cells [11].

Different treatments had been performed for this benign tumor. Laser photocoagulation induces resolution of subretinal fluid, exudative retinal detachment and tumor regression; however, subretinal fluid has a high tendency to recur, and 40% of patients require additional treatment [12]. Radiotherapy is effective in the majority of cases, but it is associated with significant treatment morbidity. Transpupillary therapy may avoid some of the limitations of laser photocoagulation (especially the failure to induce tumor regression) while avoiding complications of radiotherapy. PDT is the preferred treatment for subfoveal or juxtafoveal CCH. Verteporfin is an important vaso-occlusive treatment, and PDT may destroy the tumor without damaging the overlying retina and its vascularization. If the tumor or subretinal fluid persist further, PDT re-treatments can be performed, but repeated treatments and over-treatment or overlapping PDT spots may result in delayed choroidal atrophy and fibrosis, limiting the visual outcomes [2, 13]. Moreover, some authors suggest that it is preferable to avoid treatments within the fovea in order to decrease fibrosis and retinal pigment epithelium (RPE) changes [2].

Long-term visual prognosis for patients with CCH is guarded secondary to vision loss induced by subretinal fluid, macular edema, foveal distortion, and treatment side effects, like choroidal atrophy, fibrosis and RPE changes.

Nowadays, eyelid and orbital infantile hemangiomas can be treated successfully with oral and topical β -blockers [14, 15]. This may entail a new treatment for refractory hemangiomas, foveal hemangiomas, or hemangiomas the treatment of which implies high risk of scarring or RPE changes, like tumors that need PDT retreatment or hemangiomas with thin retinal detachments.

We hypothesized that this treatment would be useful in our patient, who showed no response to laser treatment, refused PDT, and presented poor VA. Although the treatment with β -blockers has been effective and safe in our patient, we are not able to determine whether laser treatment could have modified the final outcome.

The good visual results after treatment with oral β -blockers may open a new treatment research line for CCH. Nevertheless, further studies and more cases are required to confirm our observation.

Disclosure Statement

No authors have any financial/conflicting interests to disclose.

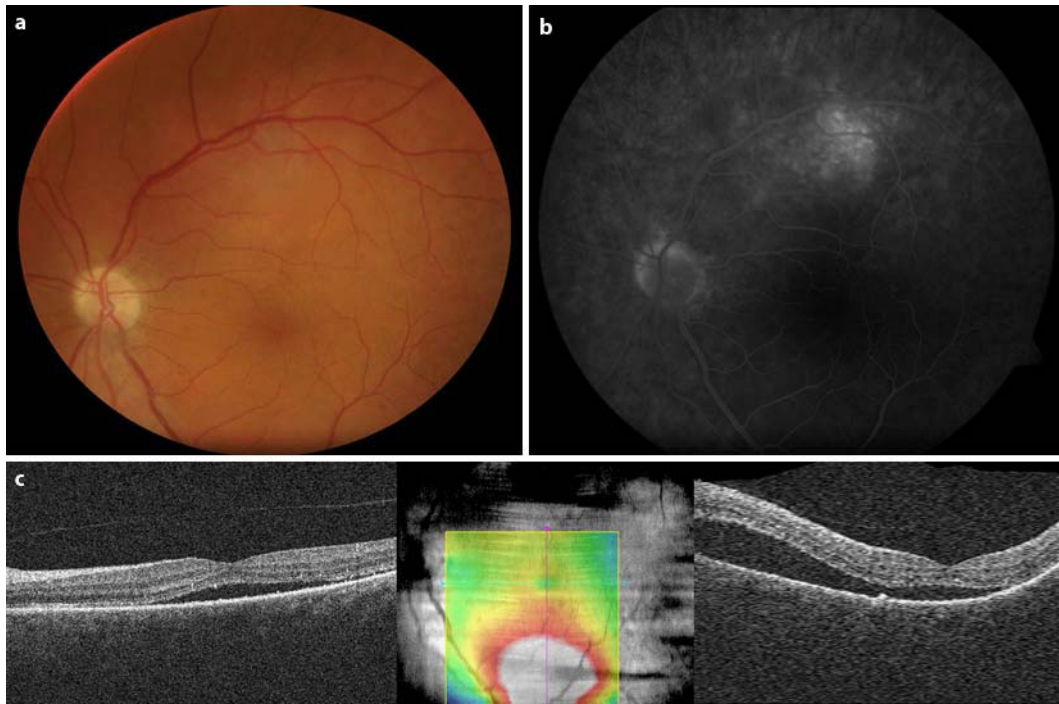


Fig. 1. Baseline appearance of the CCH: orange choroidal lesion with indistinct margins that blend with the surrounding choroid under the superior temporal arcade (**a**). Fluorescein angiography showing active leakage (**b**). Horizontal and vertical optical coherence tomography scans and retinal thickness map, showing serous macular detachment with foveal involvement (**c**).

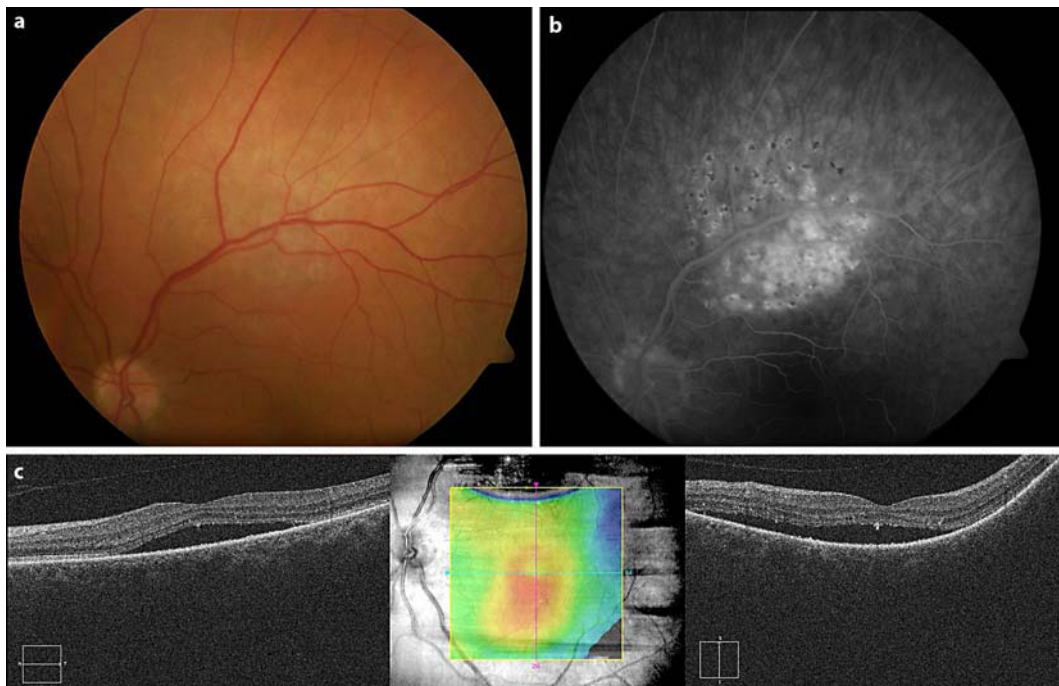


Fig. 2. Fundus appearance 3 months after laser treatment: CCH remained unchanged with laser scars (a). Fluorescein angiography showing persistent active leakage (b). Horizontal and vertical optical coherence tomography scans and retinal thickness map, showing persistent foveal serous detachment (c). The central macular thickness measured 354 μm .

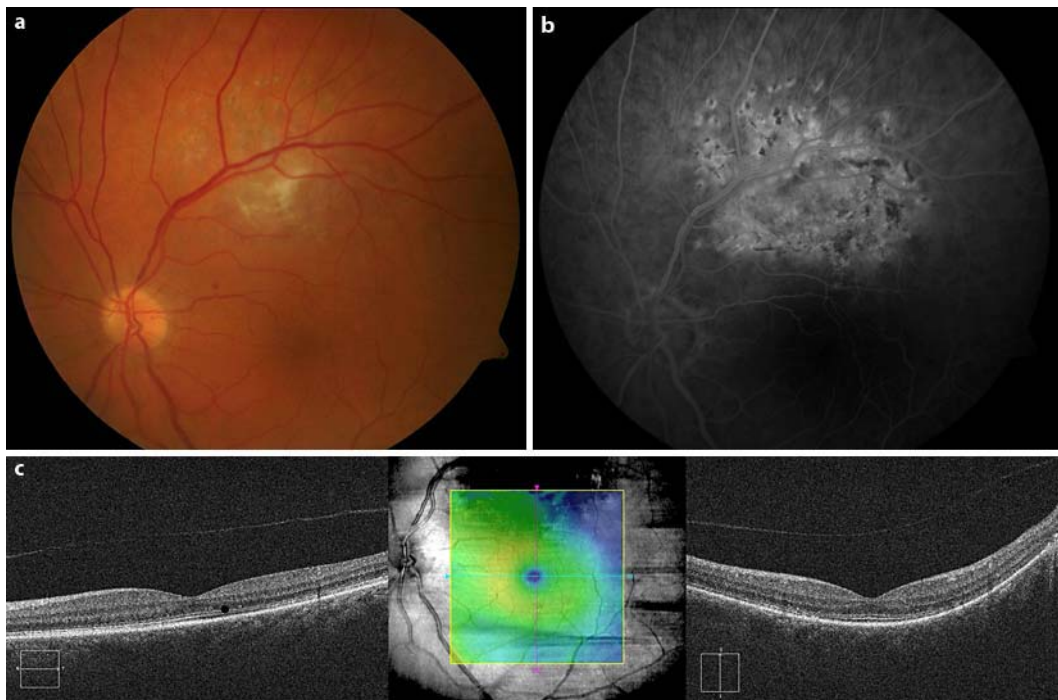


Fig. 3. Fundus appearance after 8 months of treatment with oral propranolol (a). Fluorescein angiography did not evidence active leakage (b). Horizontal and vertical optical coherence tomography scans and retinal thickness map, showing macular re-attachment with restitution of the photoreceptor layer integrity (c). The central macular thickness measured 280 μm.

References

- 1 Shields CL, Honavar SG, Shields JA, Cater J, Demirci H: Circumscribed choroidal haemangioma: clinical manifestations and factors predictive of visual outcome in 200 consecutive cases. *Ophthalmology* 2001;108:2237–2248.
- 2 Tsipursky MS, Golchet PR, Jampol LM: Photodynamic therapy of choroidal hemangioma in Sturge-Weber syndrome, with a review of treatments for diffuse and circumscribed choroidal hemangiomas. *Surv Ophthalmol* 2011;56:68–85.
- 3 Léauté-Labrèze C, Dumas de la Roque E, Hubiche T, Boralevi F, Thambo JB, Taïeb A: Propranolol for severe hemangiomas of infancy. *N Engl J Med* 2008;358:2649–2651.
- 4 Kleinman ME, Greives MR, Churgin SS, Blechman KM, Chang EI, Ceradini DJ, Tepper OM, Gurtner GC: Hypoxia-induced mediators of stem/progenitor cell trafficking are increased in children with haemangioma. *Arterioscler Thromb Vasc Biol* 2007;27:2664–2670.
- 5 Bielenberg DR, Bucana CD, Sanchez R, Mulliken JB, Folkman J, Fidler IJ: Progressive growth of infantile cutaneous hemangiomas is directly correlated with hyperplasia and angiogenesis of adjacent epidermis and inversely correlated with expression of the endogenous angiogenesis inhibitor, IFN-beta. *Int J Oncol* 1999;14:401–408.
- 6 Frieden IJ, Haggstrom AN, Drolet BA, Mancini AJ, Friedlander SF, Boon L, Chamlin SL, Baselga E, Garzon MC, Nopper AJ, Siegel DH, Mathes EW, Goddard DS, Bischoff J, North PE, Esterly NB: Infantile hemangiomas: current knowledge, future directions. Proceedings of a research workshop on infantile hemangiomas, April 7–9, 2005, Bethesda, Maryland, USA. *Pediatr Dermatol* 2005;22:383–406.
- 7 Giatromanolaki A, Arvanitidou V, Hatzimichael A, Simopoulos C, Sivridis E: The HIF-2/VEGF pathway activation in cutaneous capillary hemangiomas. *Pathology* 2005;37:149–151.
- 8 D'Angelo G, Lee H, Weiner RI: cAMP-dependent protein kinase inhibits the mitogenic action of vascular endothelial growth factor and fibroblast growth factor in capillary endothelial cells by blocking Raf activation. *J Cell Biochem* 1997;67:353–366.

- 9 Iaccarino G, Ciccarelli M, Sorriento D, Galasso G, Campanile A, Santulli G, Cipolletta E, Cerullo V, Cimini V, Altobelli GG, Piscione F, Priante O, Pastore L, Chiariello M, Salvatore F, Koch WJ, Trimarco B: Ischemic neoangiogenesis enhanced by beta2-adrenergic receptor overexpression: a novel role for the endothelial adrenergic system. *Circ Res* 2005;97:1182–1189.
- 10 Shyu KG, Liou JY, Wang BW, Fang WJ, Chang H: Carvedilol prevents cardiac hypertrophy and overexpression of hypoxia-inducible factor-1 and vascular endothelial growth factor in pressure-overloaded rat heart. *J Biomed Sci* 2005;12:409–420.
- 11 Sommers Smith SK, Smith DM: Beta blockade induces apoptosis in cultured capillary endothelial cells. *In Vitro Cell Dev Biol Anim* 2002;38:298–304.
- 12 Anand R, Augsburger JJ, Shields JA: Circumscribed choroidal hemangiomas. *Arch Ophthalmol* 1989;107:1338–1342.
- 13 Jurklics B, Anastassiou G, Ortman S, Schüler A, Schilling H, Schmidt-Erfurth U, Bornfeld N: Photodynamic therapy using verteporfin in circumscribed choroidal haemangioma. *Br J Ophthalmol* 2003;87:84–89.
- 14 Taban M, Goldberg RA: Propranolol for orbital haemangioma. *Ophthalmology* 2010;117:195–195.
- 15 Guo S, Ni N: Topical treatment for capillary haemangioma of the eyelid using beta-blocker solution. *Arch Ophthalmol* 2010;128:255–256.