

## Endocapsular hematoma as an uncommon early postoperative complication of phacoemulsification with intraocular lens implantation surgery

Mahmoud Nejabat, Mohammad Reza Khalili,  
Nasrin Masihpour, Mansoureh Mohammadpour,  
Shahla Hosseini, Mohammad Shirvani

Herein we describe a 55-year-old woman presented with a chief complaint of visual loss in the right eye of 3 days duration. The patient underwent uncomplicated phacoemulsification cataract surgery on the right eye 1 week ago. Slit lamp examination revealed accumulation of blood in the capsular bag behind the intraocular lens with blood level. The patient was diagnosed as endocapsular hematoma. Neodymium-doped: yttrium-aluminum-garnet laser posterior capsulotomy was performed. The patient's vision improved completely.

**Key words:** Cataract, endocapsular hematoma, laser capsulotomy, phacoemulsification

Endocapsular hematoma (ECH) is a rare intraocular hemorrhage in pseudophakic eyes. In this condition, blood accumulates in the capsular bag between the intraocular lens (IOL) and the posterior capsule.<sup>[1,2]</sup>

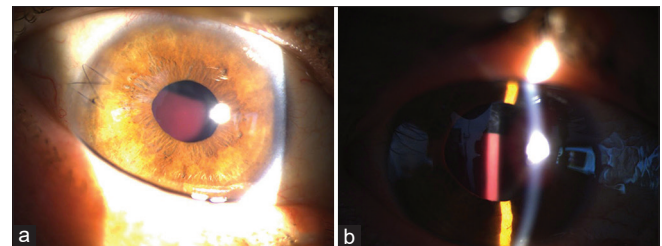
### Case Report

A 55-year-old well-controlled diabetic female presented with a chief complaint of decreased vision in the right eye (RE) 3 days prior to presentation. She had no history of hypertension and the usage of antiplatelet and anticoagulant drugs. She underwent uncomplicated cataract surgery (phacoemulsification) of RE under topical anesthesia with clear corneal incisions, circular capsulorhexis, and IOL implantation in the bag 1 week ago. There was no bleeding or iris trauma during operation, but at the end of surgery due to leakage of the main incision, it was sutured using a 10/0 nylon figure-of-8 suture. One day after the surgery, RE examination revealed the best-corrected visual acuity (BCVA) of 20/32, intraocular pressure (IOP) of 9 mm/Hg (Goldmann tonometer). Slit-lamp examination showed clear

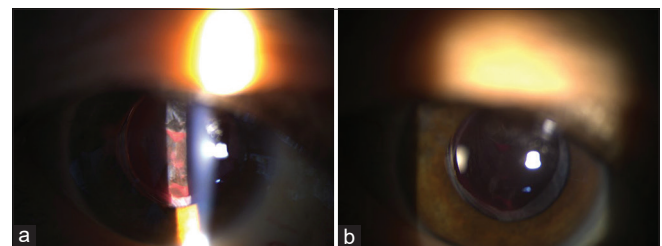
cornea, formed anterior chamber (AC), and in the bag IOL. One week after the surgery, the patient referred to us with gradual painless loss of vision in her RE of 3 days duration. RE examination revealed BCVA of 20/400, IOP of 14 mm/Hg, and accumulation of blood in the capsular bag behind the IOL with a blood level [Fig. 1a and b]. After 3 months of follow-up, there was no change in the BCVA, IOP, and ECH size. The neodymium-doped: yttrium-aluminum-garnet (Nd: YAG) laser posterior capsulotomy was performed [Fig. 2a], and 1 week later, the BCVA improved to 20/25 [Fig. 2b].

### Discussion

The sources of blood in ECH might be iris vessels, AC angle, ciliary sulcus, and surgical wound.<sup>[1-4]</sup> It seems that, during the suturing of corneal incision, the blood of limbus vessels enters the AC, passes from the margin of anterior capsule, and fills the capsular bag. When there is a need for suturing of corneal wounds, it is recommended to perform AC irrigation and air bubble injection at the end of the surgery. Therapeutic options for the management of ECH include observation and Nd: YAG capsulotomy.



**Figure 1:** Slit lamp photos of the right eye at the presentation, in diffuse illumination, shows a figure-of-8 suture and an accumulation of blood behind the IOL without AC hyphema (a), in slit illumination reveals an endocapsular blood collection, which fills 2/3 of the capsular bag space (b)



**Figure 2:** Slit lamp photos of the right eye after posterior laser capsulotomy; 30 minutes after the capsulotomy shows open posterior capsule and drainage of blood to the vitreous (a), and one week after the capsulotomy, shows nearly complete absorption of hematoma with a thin deposition of blood inferior of the capsular bag (b)

Access this article online	
Quick Response Code:	Website: www.ijo.in
	DOI: 10.4103/ijo.IJO_1873_19

Department of Ophthalmology, Poostchi Ophthalmology Research Center, Shiraz University of Medical Sciences, Shiraz, Fars, Iran

**Correspondence to:** Dr. Mohammad Shirvani, Poostchi Ophthalmology Research Center, Zand Street, Shiraz, Fars, Iran. E-mail: drshirvani69@gmail.com

Received: 12-Oct-2019

Revision: 26-Dec-2019

Accepted: 23-Mar-2020

Published: 23-Sep-2020

This is an open access journal, and articles are distributed under the terms of the Creative Commons Attribution-NonCommercial-ShareAlike 4.0 License, which allows others to remix, tweak, and build upon the work non-commercially, as long as appropriate credit is given and the new creations are licensed under the identical terms.

**For reprints contact:** WKHLRPMedknow\_reprints@wolterskluwer.com

**Cite this article as:** Nejabat M, Khalili MR, Masihpour N, Mohammadpour M, Hosseini S, Shirvani M. Endocapsular hematoma as an uncommon early postoperative complication of phacoemulsification with intraocular lens implantation surgery. Indian J Ophthalmol 2020;68:2282-3.

## Conclusion

Laser capsulotomy with Nd: YAG is an effective procedure for the management of ECH. It is recommended for patients who do not respond to conservative management or have impaired vision.<sup>[3-5]</sup>

### Declaration of patient consent

The authors certify that they have obtained all appropriate patient consent forms. In the form the patient(s) has/have given his/her/their consent for his/her/their images and other clinical information to be reported in the journal. The patients understand that their names and initials will not be published and due efforts will be made to conceal their identity, but anonymity cannot be guaranteed.

### Financial support and sponsorship

Nil.

### Conflicts of interest

There are no conflicts of interest.

## References

1. Thomas R, Aylward GW, Billson FA. 'In-the-bag' hyphaema--a rare complication of posterior chamber lens implantation. *Br J Ophthalmol* 1989;73:474-5.
2. Hater MA, Yung CW. Spontaneous resolution of an endocapsular hematoma. *Am J Ophthalmol* 1997;123:844-6.
3. Hagan JC III, Menapace R, Radax U. Clinical syndrome of endocapsular hematoma: Presentation of a collected series and review of the literature. *J Cataract Refract Surg* 1996;22:379-84.
4. Radax U, Menapace R. Endocapsular hematoma with biconvex posterior chamber intraocular lenses. *J Cataract Refract Surg* 1994;20:634-7.
5. Hagan JC, Gaasterland DE. Endocapsular hematoma: Description and treatment of a unique form of postoperative hemorrhage. *Arch Ophthalmol* 1991;109:514-8.